

BRAIN COMMUNICATIONS

The ‘creatures’ of the human cortical somatosensory system

Noam Saadon-Grosman,¹ Yonatan Loewenstein^{2,3,4,5,*} and Shahar Arzy^{1,6,*}

* These authors contributed equally to this work.

Penfield’s description of the ‘homunculus’, a ‘grotesque creature’ with large lips and hands and small trunk and legs depicting the representation of body-parts within the primary somatosensory cortex (S1), is one of the most prominent contributions to the neurosciences. Since then, numerous studies have identified additional body-parts representations outside of S1. Nevertheless, it has been implicitly assumed that S1’s homunculus is representative of the entire somatosensory cortex. Therefore, the distribution of body-parts representations in other brain regions, the property that gave Penfield’s homunculus its famous ‘grotesque’ appearance, has been overlooked. We used whole-body somatosensory stimulation, functional MRI and a new cortical parcellation to quantify the organization of the cortical somatosensory representation. Our analysis showed first, an extensive somatosensory response over the cortex; and second, that the proportional representation of body parts differs substantially between major neuroanatomical regions and from S1, with, for instance, much larger trunk representation at higher brain regions, potentially in relation to the regions’ functional specialization. These results extend Penfield’s initial findings to the higher level of somatosensory processing and suggest a major role for somatosensation in human cognition.

1 Department of Medical Neurobiology, Faculty of Medicine, The Hebrew University, Jerusalem 9112001, Israel

2 The Edmond and Lily Safra Center for Brain Sciences, The Hebrew University, Jerusalem, 9190401, Israel

3 The Alexander Silberman Institute of Life Sciences, The Hebrew University, Jerusalem, 9190401, Israel

4 Department of Cognitive Sciences, The Hebrew University, Jerusalem 9190401, Israel

5 The Federmann Center for the Study of Rationality, The Hebrew University, Jerusalem 9190401, Israel

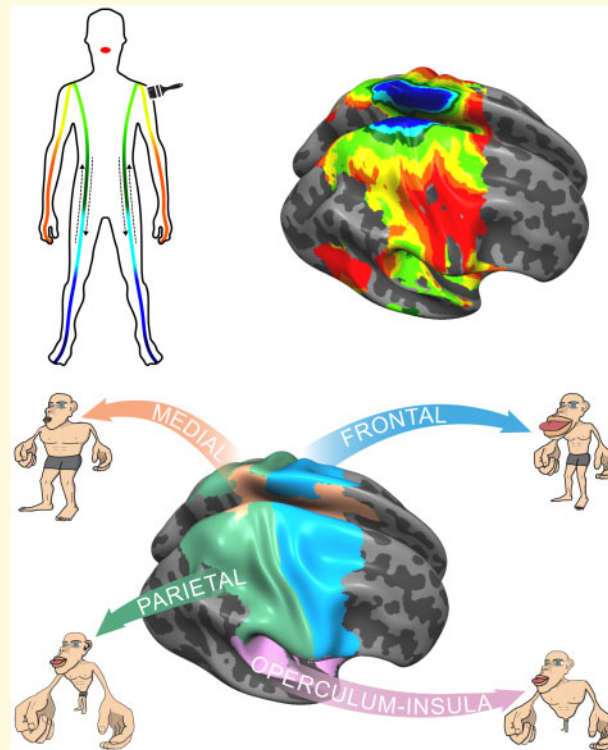
6 Department of Neurology, Hadassah Hebrew University Medical School, Jerusalem 9112001, Israel

Correspondence to: Noam Saadon-Grosman, Department of Medical Neurobiology, Faculty of Medicine, The Hebrew University, Ein Kerem Campus, Jerusalem 9112001, Israel, E-mail: noam.saadongros@mail.huji.ac.il

Keywords: Homunculus; Penfield; functional MRI; body representation

Abbreviations: BA =Brodmann area; CI =confidence interval; FWHM =full width half maximum; TR =repetition time

Graphical Abstract



Introduction

The establishment of the homunculus, a schematic drawing reflecting the disproportional representation of the parts of the human body on the motor and somatosensory cortex, was an important milestone for the neurosciences. Eighty years ago, Penfield and Boldrey electrically stimulated the cortical surface of patients undergoing brain surgery. They used the patients' subjective reports of somatosensory sensations to identify representation of different body parts in the post-central gyrus, known as the primary somatosensory cortex (S1, Penfield and Boldrey, 1937). One of their significant findings was that the cortical surface area associated with a body part ('spatial distribution' of body parts) is not proportional to the surface area of the body part itself. Instead, the face and hands are overrepresented, while the trunk and legs occupy disproportionately small cortical areas. A schematic drawing of a human figure with body parts corresponding to the size of their cortical (S1) representation, yielded the famous 'grotesque creature' with large hands and lips and rather small trunk and legs, known as the somatosensory homunculus (Penfield and Boldrey, 1937; Penfield and Rasmussen, 1950; Penfield and Jasper, 1954). Later, it was suggested that the spatial distribution depicted by the homunculus reflects the level of neuronal peripheral innervation (e.g. Woolsey *et al.*, 1942; Sur *et al.*, 1980; Catani, 2017).

The disproportionate spatial distribution of body parts is likely to be of functional significance, underlying the greater somatosensory discrimination ability for the enlarged body parts in the corresponding cortical homunculus.

Penfield and his colleagues also identified somatosensory representations in other cortical areas. These include the precentral gyrus (the primary motor area, M1; Penfield and Boldrey, 1937), the superior bank of the lateral fissure (the secondary somatosensory area, S2), the insular cortex and the medial cortex (supplementary motor area; Penfield, 1950; Penfield and Jasper, 1954; Penfield and Faulk, 1955). Later studies used electrophysiological recordings in non-human primates and functional neuroimaging in humans in response to somatosensory stimulation to further identify and characterize the cortical somatosensory system (e.g. Kaas *et al.*, 1979; Fox *et al.*, 1987; Burton *et al.*, 1993; Lim *et al.*, 1994; Nakamura *et al.*, 1998; Kaas and Collins, 2001; Ruben *et al.*, 2001; Fitzgerald *et al.*, 2004; Mazzola *et al.*, 2006). Additional somatosensory representations were detected in the superior and inferior parietal lobules (Sakata *et al.*, 1973; Ruben *et al.*, 2001; Young *et al.*, 2004; Huang *et al.*, 2012), inferior frontal gyrus, frontal operculum (Hagen *et al.*, 2002) and the cingulate cortex (Arieno *et al.*, 2006). Large body of works focused on specific localizations of body-parts representations across the different cortical regions. In contrast, surprisingly

little attention has been given to the spatial distribution of body parts across the cortical surface, the property that gave Penfield's homunculus of S1 its famous characteristic 'grotesque' appearance.

The goal of this research is to quantify the spatial distribution of body parts across the entire somatosensory cortex. We first characterized the somatosensory cortex by measuring its response to a bilateral whole-body continuous tactile stimulation, using functional magnetic resonance imaging. Interestingly, our measurements revealed extended somatosensory cortical response to tactile stimulation. Second, we quantified the spatial distribution of body parts in different anatomically distinct cortical regions. Spatial distribution of body parts substantially varied between regions and S1. We interpret the differences in these distributions as reflecting functional specialization.

Materials and methods

Participants

The study included 20 healthy participants [as standard in the field; 9 females, age: 27.45 ± 3.33 years old (mean \pm SD)]. Participants did not report any history of neurological, psychiatric or systemic disorder. All participants gave written informed consent, and the study was approved by the ethics committee of the Hadassah Medical Center.

Experimental paradigm

A light-touch somatosensory stimulation was applied to the lips, hand (dorsal part), forearm, upper arm, shoulder, lateral trunk, hip, thigh (medial part), knee, shin, foot (dorsal part) and the toes (Fig. 1A; Saadon-Grosman *et al.*, 2015; Tal *et al.*, 2016). The stimulation was delivered using a 4-cm-wide paint-brush (with extended handle of 65-cm plastic stick) by an experimenter, who was well-trained before the scans to maintain a constant pace and pressure. The stimulation was unilateral and continuous (without lifting the brush from the skin), except for one discontinuity between the lips and the hand. To control the timing of the body-part sequence, the experimenter wore MRI-compatible headphones, delivering pre-programmed auditory cues (Presentation; Neurobehavioral Systems). Stimulation duration was 15 s and the interval between stimulations was 12 s. Each scanning run included seven repetitions of stimulation of one body side (right/left), followed by seven repetitions of stimulation of the other body side (left/right). The order (right/left) was counter-balanced between participants. To control for time order and directionality effect, each participant was measured in two scanning runs that differed in the order of body-parts stimulations, from lips-to-toes and from toes-to-lips. Run duration was 423 s [282

repetition time (TR)], which included a 30 s of measurement before the onset of the first repetition and 4.5 s measurement after the last repetition, in addition to 12 s delay between the stimulation of the two body sides.

Functional MRI image acquisition procedures and pre-processing

All participants were scanned at the same site using a Siemens Skyra 3T system (32-channel head coil) with the same imaging sequence. Blood oxygen level-dependent functional magnetic resonance imaging was acquired using a whole-brain, gradient-echo (GE) echoplanar (EPI) [TR/time echo (TE) = 1500/27 ms, flip angle = 90, field of view (FOV) = 192×192 mm, matrix = 64×64 (in-plane resolution 3×3 mm²), 26 axial slices, slice thickness/gap = 4 mm/0.8 mm]. In addition, high resolution ($1 \times 1 \times 1$ mm) T1-weighted anatomical images were acquired to aid spatial normalization to standard atlas space. The anatomic reference volume was acquired along the same orientation as the functional images [TR/TE = 2300/2.98 ms, matrix = 256×256 , 160 axial slices, 1-mm slice thickness, inversion time (TI) = 900 ms]. Pre-processing was performed using the BrainVoyager QX 20.4.0.3188 software package (Brain Innovation) and NeuroElf (<http://neuroelf.net>), including head motion correction (trilinear interpolation for detection and sinc for correction), slice scan time correction and high-pass filtering (cut-off frequency, two cycles per scan: 0.005 Hz). Temporal smoothing (FWHM = 4 s) and spatial smoothing (FWHM = 4 mm) were additionally applied (Saadon-Grosman *et al.*, 2015). Functional and anatomical datasets for each participant were co-registered and normalized to standardized MNI (ICBM-152) space. All further analyses were performed using in-house custom Matlab (Mathworks, Inc.) scripts.

Cross-correlation analysis

To identify the cortical distribution of the somatosensory system, we used a cross-correlation analysis. Each body side was analysed separately by splitting voxels' time course (137 TR each: 27 s per repetition, 7 repetitions, 1.5 s per TR: $27 \times 7/1.5 = 126 + 8$ TR prior to beginning of stimulation and 3 TR after stimulation). A boxcar function (3 s) was convolved with a two gamma hemodynamic response function, to derive a predictor for the analysis. This predictor and the time course of each voxel were cross-correlated to measure responses to different parts of the stimulation cycle (body parts). The first TR in the stimulation block was excluded to avoid any effects of expectancy or surprise. The predictor was cross-correlated across all TR in the block except the last to allow averaging of the two opposite stimulation directions ('start lips' and 'start toes'). Stimulation duration of each cycle had 10 TR, thus, cross-correlation analysis produced eight correlation values for each voxel,

indicating correlation to different parts of the stimulation cycle (each TR was assigned to a specific body part by its stimulation time: 1-lips, 2-distal upper limb, 3-proximal upper limb, 4-upper trunk, 5-lower trunk, 6-proximal lower limb, 7-mid-lower limb, 8-distal lower limb). For each voxel of each participant, we flipped the order of the correlation values of the start toes paradigm and then averaged the correlation distributions of both start lips and start toes directions. The averaged distribution maximum defined the preferred body part (lag value) of each voxel. A correlation threshold of $r > 0.251$ was applied to identify voxels responding significantly to the stimulation (two-tailed t -test, $\alpha = 0.05$, Bonferroni corrected for multiple correlations; 8 lag values \times two paradigms, 135 degrees of freedom, $P < 0.003$). To generate a group map, all correlation distributions across participants were averaged in each voxel. Only voxels that were above the significance threshold in $>2/3$ of the participants were included in the analysis (random effect yielded similar results, [Supplementary Fig. 1](#)).

Cortical parcellation and identification of somatosensory responsive areas

In this study, we applied a recently introduced multi-modal data-driven parcellation ([Glasser et al., 2016](#)). This parcellation uses multi-modal magnetic resonance images from the Human Connectome Project (HCP) and an objective semi-automated neuroanatomical approach to delineate 180 areas per hemisphere, bounded by sharp changes in cortical architecture, function, connectivity and/or topography ([Glasser et al., 2016](#)). Since this parcellation is surface-based, cross-correlation maps were projected on an averaged inflated cortical surface (Trilinear interpolation, data in depth along vertex normal from -1 mm to 3 mm of grey-white matter border; FreeSurfer's, fsaverage template brain; [Desikan et al., 2006](#)). Parcellation areas containing $>50\%$ of vertices responding to body stimulation were defined as somatosensory responsive areas ([Supplementary Table 1](#)). Only significant vertices were considered, this threshold was used to eliminate areas which did not pass majority rule (i.e. areas with $<50\%$ significant vertices). Yet, we did not include insignificant vertices in the analysis, even in supra-threshold parcellation areas.

Gross-anatomy classification

The somatosensory system as found here lies over four gross-anatomical regions, including the anterior part of the parietal lobe [from Brodmann area (BA) 3a to the ventral and medial intraparietal areas (BA 7)], the posterior part of the frontal lobe (from BA 4 to the anterior end of BA 6), the superior part of the medial wall (from the medial end of the pre- and post-central gyri to the middle cingulate gyrus) and the operculum-insular cortex

(from parietal and frontal operculum to temporal operculum through the posterior insula). In order to define these regions precisely, we utilized the above-mentioned parcellation. We classified each of the somatosensory parcellation areas according to the following criteria: the parietal region includes all areas on the lateral surface posterior to the central sulcus, the frontal region includes all areas on the lateral surface anterior to the central sulcus, the medial region includes all areas on the medial wall, and the operculum-insula region includes areas inferior to the parietal and frontal lobes of the operculum and insular cortex ([Supplementary Table 1](#), 'Neuroanatomical results for a multi-modal parcellation of human cerebral cortex'; [Glasser et al., 2016](#)). Note that areas 4, 6 mp and 7 Am ([Glasser et al., 2016](#)) on the lateral surface extend into the medial wall and that area 5L is somehow different from Brodmann's original definition, part of the medial region. Additional parcellation areas that were not included in these anatomical regions as part of the spatial continuous representation were found in the area of the temporo-occipital parietal junction and in the inferior-temporal gyrus (eight in the right hemisphere and seven in the left hemisphere, see [Supplementary Table 1](#)). Relative proportions of each body part within the entire somatosensory system and in specific anatomical regions (gross and parcellation areas) were calculated according to the percentage of significant vertices with a given lag value (lips-1, upper limb-2,3, trunk-4,5, lower limb-6,7,8). To estimate the level of confidence, we applied bootstrapping by resampling participants to create 1000 cross-correlation maps. Confidence intervals (CI) correspond to 2.5% and 97.5% percentiles and errors are represented by the standard deviation of body-parts proportions. In addition, we created a schematic drawing of the relative proportions of body parts by modifying Penfield's S1 homunculus drawn by 'Cortical Homunculus', The Homunculus mapper, license CC-BY-NC-SA 4.0 (<https://creativecommons.org/licenses/by-nc-sa/4.0/>; <https://www.maxplanckfl.org/fitzpatricklab/homunculus/science/>). Body parts of S1 schematic drawing were rescaled (using *Adobe Illustrator*® CS6) following the results presented in [Supplementary Fig. 2](#). The body parts were then reconnected into a modified homunculus schematic drawing. Note that not all body parts were stimulated (e.g. tongue and forehead). Therefore, these body parts are represented according to the schematic figure of S1 homunculus, similar to the illustration by [Penfield and Boldrey \(1937\)](#).

Statistical analysis

Spatial distribution of body parts in the somatosensory responsive cortex, S1 and the four gross-anatomical regions were computed for each participant. Significance of differences between regions was tested by a paired sample two-tailed t -test across participants (19 degrees of freedom).

Data availability

Single subjects' maps can be found in [Supplementary Fig. 3](#) and spatial distribution of body parts in each parcellation area of the somatosensory responsive cortex can be found in [Supplementary Table 1](#). Raw data and codes are available from the corresponding author upon request.

Results

For each participant, we identified cortical voxels that responded significantly to the somatosensory stimulation (two-tailed t -test, $P < 0.003$, corrected for multiple correlations, see Materials and methods section; [Supplementary Fig. 3](#)). Overall, group map (20 participants) shows that somatosensory representation in the contralateral hemisphere (which we operationally define as the somatosensory responsive cortex; ipsilateral maps, [Supplementary Fig. 4](#)) spans $>30\%$ of the cortical surface (35.7%, 95% CI 30.6%–50.6% of the right hemisphere and 30.4%, 95% CI 23.6%–45.9% of the left hemisphere, surface area). The somatosensory map includes the previously identified somatosensory regions in S1, M1, S2, supplementary motor area, posterior insular cortex, superior and inferior parietal lobules, inferior frontal gyrus, frontal operculum and the cingulate cortex ([Fig. 1B](#)).

The quantification of the spatial distribution of body parts in S1 [defined according to Brodmann's areas (BAs) 1, 2, 3a, 3b; [Glasser et al., 2016](#)] was found to be comparable with Penfield's somatosensory homunculus ([Penfield and Boldrey, 1937](#); [Catani, 2017](#)). That is, extensive representation of the upper limb (46.3%, 95% CI 41.5%–51.6%) and lips (28.9%, 95% CI 23.0%–33.5%), and lesser representation of the trunk (15.8%, 95% CI 13.7%–19.0%) and lower limb (9.1%, 95% CI 7.2%–10.6%; [Fig. 1C](#), left). However, when we quantified the entire somatosensory cortex, the spatial distribution was significantly different. While the fractions of the cortical area devoted to the upper (41.1%, 95% CI 33.1%–46.0%) and lower (7.6%, 95% CI 6.5%–10.2%) limbs are both slightly smaller (but significant, paired sample two-tailed t -test, upper limb $P = 3 \times 10^{-5}$, lower limb $P = 3 \times 10^{-3}$) than those in S1, the area devoted to the lips (20.1%, 95% CI 13.3%–26.2%) is only 70% of that in S1 (two-tailed t -test, $P = 1 \times 10^{-2}$), and the trunk area (31.1%, 95% CI 22.8%–43.6%) is almost double than in S1 (two-tailed t -test, $P = 6 \times 10^{-6}$). Adopting Penfield's homunculus representation, S1 and the entire somatosensory responsive cortex are represented by very different homunculi ([Fig. 1D](#)). These differences imply that principles other than the level of neuronal peripheral innervation, which is believed to underlie this distribution in S1 ([Woolsey et al., 1942](#); [Sur et al., 1980](#); [Catani,](#)

[2017](#)), determine the spatial distribution of body parts in the cortex as a whole.

To study these principles, we asked whether anatomically distinct regions are characterized by different spatial distributions. According to fundamental subdivisions of the cortex' gross anatomy, somatosensory representations are found within the parietal lobe (S1 and posteriorly), the frontal lobe (anterior to S1), the medial wall (medial to S1) and operculum and insula (inferior to S1) regions. To precisely segment the cortex into these four regions, we capitalized on a recently introduced, data-driven multi-modal cortical parcellation that divides each hemisphere into 180 anatomically and functionally defined areas ([Glasser et al., 2016](#)). By using these areas to draw the borders between the four regions ([Fig. 2A](#)), we were able to associate each vertex with its corresponding region (see also [Supplementary Table 1](#)).

The anterior parietal region, the somatosensory part of the parietal cortex (including S1), was found to encompass 32% of the somatosensory responsive cortex. Somatosensory representation in this region was dominated by the upper limb (53.5%, 95% CI 45.0%–59.6%), more than any other region (paired sample two-tailed t -test, frontal, $P = 9 \times 10^{-5}$, medial, $P = 8 \times 10^{-10}$, operculum-insula, $P = 2 \times 10^{-2}$). This was followed by a substantial representation of the trunk (25.1%, 95% CI 15.5%–35.3%), which is almost 60% greater than its representation in S1 (two-tailed t -test, $P = 7 \times 10^{-4}$). The representation of these two body parts come at the expense of the lips (16.6%, 95% CI 13.2%–22.7%) and the lower limb (4.8%, 95% CI 3.9%–5.9%; [Fig. 2B](#), see also [Supplementary Fig. 2](#)). In fact, the latter two representations are almost absent outside S1 in the parietal cortex ([Fig. 1B](#) and [Supplementary Table 2](#)).

The posterior part of the frontal cortex comprises 18% of the somatosensory responsive cortex. The rank order of body-parts representation in the frontal region is identical to that in S1 (upper limb $>$ lips $>$ trunk $>$ lower limb). However, there are quantitative differences in their relative sizes. The representation of the upper limb (34.0%, 95% CI 27.7%–44.3%) is smaller than its representation in S1 (two-tailed t -test, $P = 1 \times 10^{-3}$), allowing for a larger representation of the trunk (22.6%, 95% CI 11.5%–32.1%) and lower limb (14.9%, 95% CI 12.6%–16.9%). The relative representation of the lips (28.5%, 95% CI 21.8%–34.0%) is comparable to that in S1 ([Fig. 2B](#) and [Supplementary Fig. 2](#)).

The medial region (12% of the somatosensory responsive cortex) is the most different from S1. The spatial distribution of body parts in this region is most similar to their veridical proportion (skin area; [Catani, 2017](#)). The medial region is dominated by the trunk (40.3%, 95% CI 30.6%–49.3%), followed by the upper limb (28.9%, 95% CI 21.4%–36.1%), lower limb (23.4%, 95% CI 20.1%–28.5%) and lips (7.4%, 95% CI 4.4%–11.2%). The trunk and lower limb are highly represented in the medial region. The lower limb, significantly more than all

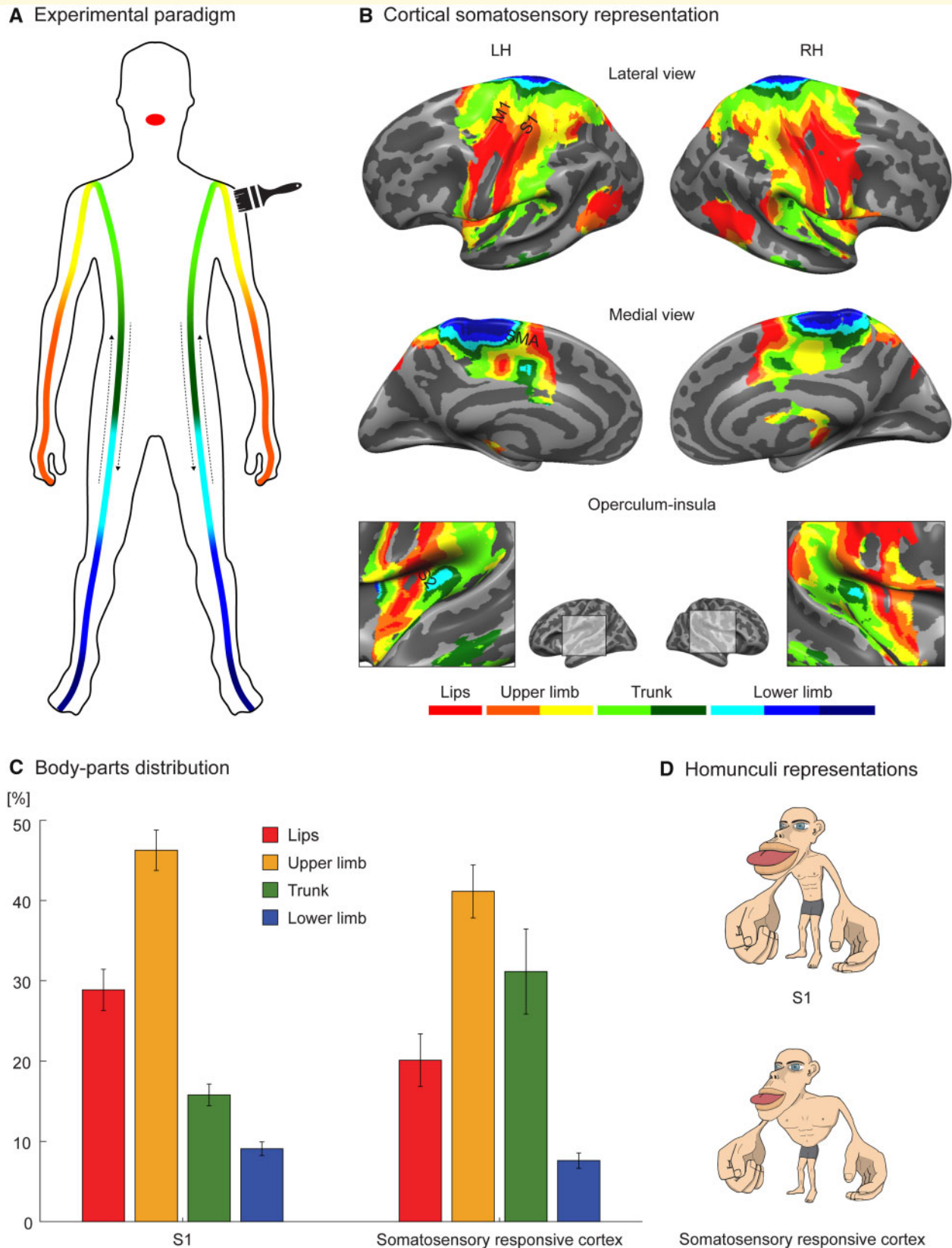


Figure 1 Experimental paradigm, somatosensory cortical representation and body-parts spatial distribution. **(A)** Scheme of whole-body continuous brush movement from lips-to-toes and from toes-to-lips (black arrows) bilaterally in two different scanning runs. Body parts defined along the continuous stimulation: lips (red), distal upper limb (orange), proximal upper limb (yellow), upper trunk (light green), lower trunk (green), proximal lower limb (light blue), mid-lower limb (blue) and distal lower limb (dark blue). **(B)** Cross-correlation group maps ($N = 20$; see colour code in A) corresponding to stimulation of the contralateral body side are shown on the lateral and medial surfaces as well

(continued)

other regions (paired sample two-tailed *t*-test, parietal, $P = 1 \times 10^{-8}$, frontal, $P = 1 \times 10^{-6}$, operculum-insula, $P = 4 \times 10^{-5}$), whereas the upper limb and lips are the least represented (paired sample two-tailed *t*-test, upper limb: parietal, $P = 8 \times 10^{-10}$, frontal, $P = 1 \times 10^{-3}$, operculum-insula, $P = 6 \times 10^{-6}$, lips: parietal, $P = 9 \times 10^{-6}$, frontal, $P = 3 \times 10^{-9}$, operculum-insula, $P = 2 \times 10^{-3}$; Fig. 2B and Supplementary Fig. 2).

Finally, the operculum-insular cortex (16% of the somatosensory responsive cortex) is dominated by the upper limb (42.2%, 95% CI 35.9%–48.1%) and trunk (37.4%, 95% CI 28.2%–45.3%). There is less representation of the lips (17.7%, 95% CI 12.5%–24.1%) and the representation of the lower limb is nearly absent (2.7%, 95% CI 1.7%–4.8%; Fig. 2B and Supplementary Fig. 2). We also found somatosensory representations in the area of the temporo-occipital parietal junction and at the inferior-temporal gyrus (22% of the somatosensory responsive cortex) that are topologically disconnected from S1 along the somatosensory cortex (Supplementary Fig. 6). Taken together, the spatial distributions of body parts in the four anatomical regions are substantially different from one another, as well as from S1, as represented by the different homunculi corresponding to the four regions (Fig. 2C). These differences may be related to different functional specializations of these regions as discussed below.

Discussion

Data-driven quantification of the somatosensory system revealed that it comprises a large fraction of the human cortex, which includes high-order regions, suggests that the somatosensory system plays a role in high-cognitive processing (which may be entitled ‘somatosensory cognition’). Quantification of the four gross-anatomical regions (parietal, frontal, medial and operculum-insula) revealed that the somatosensory responsive areas differ from each other, and from the primary somatosensory cortex (BAs 1, 2, 3a, 3b). Specifically, they are characterized by different distributions of body-parts representations, manifested in different homunculi (Fig. 2C) that are distinctive from Penfield’s classical S1 homunculus (Fig. 1D). This heterogeneity in the distribution of body-parts representations implies different functional roles of the four homunculi.

The parietal somatosensory region is comprised of S1 and the anterior part of the inferior and superior parietal lobules. Upper limb and trunk representations dominate the parietal somatosensory region. This is particularly pronounced in the anterior parietal lobules (S1 excluded, Supplementary Table 2). There, lower limb and lips representation are minimal. The higher proportion of upper limb and trunk representations in the parietal lobules (compared with S1) is consistent with their role in body-processing-related functions such as multisensory integration and bodily self-consciousness (Tsakiris *et al.*, 2007; Kammers *et al.*, 2009; Petkova *et al.*, 2011; Blanke, 2012). The posterior parietal cortex is considered an area of sensorimotor interface for visually guided movements (Begliomini *et al.*, 2007; Binkofski *et al.*, 1998). Many studies in non-human primates and humans indicate that neurons in the posterior parietal cortex encode grasping and reaching movements (e.g. Andersen and Buneo, 2002; Jeannerod *et al.*, 1995; Konen *et al.*, 2013). Reaching, and more so grasping, entails somatosensory information. Consistent with these results is the prominent representation of the upper limb in the posterior parietal region (Supplementary Table 2).

The frontal region includes all vertices that responded to somatosensory stimulation anterior to the central sulcus, including M1 (BA 4), the premotor cortex (BA 6) and parts of the frontal eye field. Body-parts representation in M1 is dominated by the lower limb and lips with little representation of upper limb and trunk (Supplementary Table 2). By contrast, lower limb representation is almost absent anterior to M1. This increased upper limb and trunk representation is compatible with high-order functions of this region, since the premotor cortex is important not only for motor planning but also for body agency and embodiment (Blanke, 2012). Electrophysiological studies in non-human primates showed that neurons in the anterior superior parietal lobule and the premotor cortex integrate visual and somatosensory stimuli involving the arm and the trunk (Fogassi *et al.*, 1996; Graziano *et al.*, 1997, 2000; Maravita and Iriki, 2004). Premotor-parietal orchestrated activity was highlighted by functional neuroimaging studies in humans as well as lesion studies in patients demonstrating the putative role of these regions in body processing of the hand and trunk (Blanke, 2012). These results are compatible with the substantial upper limb and trunk

Figure 1 Continued

as the operculum and insula cortices (LH: left hemisphere; RH = right hemisphere; level of significance: at least 2/3 of the participants with significance $P < 0.003$, corrected for multiple correlations, see Materials and methods section; random effect yielded similar results, Supplementary Fig. 1). Landmarks: M1 = primary motor cortex; S1 = primary somatosensory cortex; S2 = secondary somatosensory cortex; SMA = supplementary motor area. (C) Quantification of body parts [lips, upper limb (proximal and distal combined), trunk (upper and lower combined) and lower limb (proximal, mid and distal combined)] spatial distribution in S1 (left, BA: 3a, 3b, 1, 2) and in the entire somatosensory responsive cortex (right) averaged across two hemispheres (error bars are standard deviation, computed by bootstrapping over participants). Note the different percentage of trunk and lips between S1 and the entire somatosensory responsive cortex. (D) The original schematic homunculus representation of S1 adopting Penfield’s homunculus (top) and a modified version for the entire somatosensory responsive cortex (bottom).

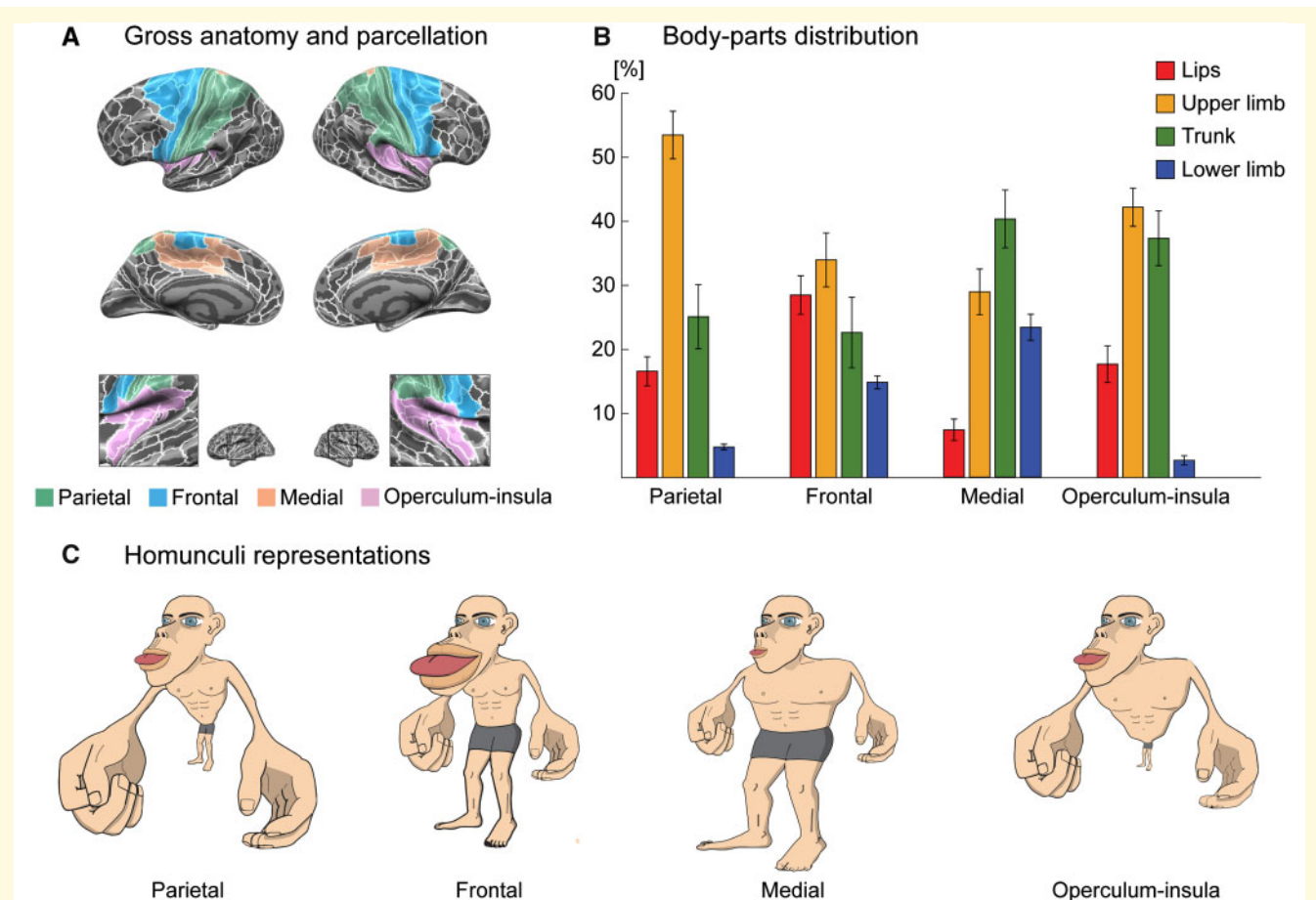


Figure 2 Quantitative differences in the spatial distributions of body parts ('homunculi'). (A) Subdivisions of the somatosensory responsive cortex into four gross-anatomical regions: parietal (S1 and posteriorly), frontal (anterior to S1), medial (medial to S1) and operculum-insula (inferior to S1). (B) Distribution of the different body parts [lips, upper limb (proximal and distal combined), trunk (upper and lower combined) and lower limb (proximal, mid and distal combined)] within each gross-anatomical region averaged across two hemispheres (error bars are standard deviation, computed by bootstrapping over participants). (C) Homunculi proportional representation of body parts in each gross-anatomical region as modified versions of Penfield's original homunculus (S1), as in Fig. 1D.

representations in both the anterior parietal lobules and the regions anterior to M1 found in our study.

Body-parts distribution in the medial region is closest to human veridical proportions (unlike S1's 'grotesque creature'), as evident in the homunculi illustrations (Fig. 2C). The large representation of the lower limb, the highest of all regions, is consistent with clinical observations of leg-related pathologies (Schneider and Gautier, 1994). Lower limb representation is particularly pronounced in the supplementary motor area. As in M1, the dominance of lower limb representation is consistent with the substantial role of the lower limb in motor actions.

Our finding of somatosensory representations in the middle cingulate cortex (Fig. 1B and Supplementary Table 1) is consistent with previous findings of somatosensory response elicited by electrical stimulation of peripheral nerves (Arieno *et al.*, 2006) and evoked somatosensory sensation by direct intracranial stimulation of the middle cingulate cortex (Lim *et al.*, 1994).

Somatosensory representation was found in the posterior insula which is known to be involved in the processing of body ownership, visceral effects and emotional modulations (Craig, 2002; Tsakiris *et al.*, 2007; Taylor *et al.*, 2009; Cauda *et al.*, 2012; Grecucci *et al.*, 2013). We find that the representation of the trunk occupies one-third of the posterior insula (Supplementary Table 2). The large proportion of the trunk in this region hints at the trunk's special role in the emotional aspects of somatosensory processing.

We have also identified somatosensory response in the temporal operculum (Fig. 1B and Supplementary Table 1) which includes parts of the auditory cortex. This finding is in agreement with the large body of research regarding multisensory integration (e.g. Kayser *et al.*, 2005). Interestingly, somatosensory representation in the associative auditory areas was restricted to the right hemisphere (Supplementary Table 1). This asymmetry, we speculate, may be related to the more dominant role of the right

hemisphere in auditory spatial processing (Tiitinen *et al.*, 2006).

Our results first and foremost establish that the distribution of body parts varies between regions and specifically from the distribution in S1. Our interpretations, to a certain degree, depend on the grouping of parcellation areas into gross-anatomical regions. While the frontal, parietal and insular areas are well-defined, the operculum can either be divided and grouped with the frontal and parietal regions or can be grouped with the insula. The newly defined large number of parcellation areas (Glasser *et al.*, 2016) enabled distinction between lateral and medial regions with four exceptions: areas 4, 6mp, 5L and 7Am (with both medial and lateral parts). Most of area 4 (M1) and most of area 6mp reside in the lateral part, and therefore, they were taken as part of the frontal region. Areas 7Am and 5L were added to the corresponding somatosensory sub-areas of BA 5 (medial) and 7 (parietal), respectively. [Supplementary Table 1](#), which depicts the spatial distribution of body parts in each somatosensory parcellation area (see also [Supplementary Fig. 5](#)) allows the reader to study the consequences of a different segmentation.

This study confronts several limitations. First, due to the difficulty in the accessibility within the MRI apparatus and the continuous stimulation applied, we did not cover the entire skin surface of the body. While the classical S1 homunculus presents prominent lips representation, we cannot exclude more prominent representation of upper face/head in homunculi outside of S1, as we have shown for the trunk. Nevertheless, the fact that body-parts spatial distribution in S1 was found comparable with Penfield's somatosensory homunculus suggests that this did not significantly affect the final results. Further research with a wider MRI machines and additional body coverage may elaborate our findings. Second, the experimental paradigm investigates whole-brain response to stimulation of each body part separately, in a continuous manner, and not multiple body parts or body sides simultaneously. Further studies may address questions regarding the linearity of the somatosensory response and bilateral interactions as was suggested previously (e.g. [Reed *et al.*, 2011](#)).

In conclusion, using a novel approach, the current work has demonstrated how large fraction of the human cortex, including high-order regions, is involved in processing light touch somatosensory stimulation. The spatial distributions of body parts in different anatomical regions were found to differ substantially from S1. Spatial distributions were unique to each region and are likely related to the region's functional specialization. Our findings suggest that somatosensation plays a major role in human cognition. Future research should further develop these findings and incorporate them into a joint framework of 'somatosensory cognition'.

Supplementary material

[Supplementary material](#) is available at *Brain Communications* online.

Acknowledgements

We thank N. Klein for critical assistant with figure graphics and to M. Peer for fruitful discussions. We thank the ELSC MRI unit, Assaf Yohalashet, Lee Ashkenazi and Yuval Porat for their dedicated work.

Funding

This work was supported by The Israel Science Foundation (Grants No. 757/16, 1306/18) and the Gatsby Charitable Foundation. N.S.-G. was supported by the Evelyn Royal scholarship.

Competing interests

The authors report no competing interests.

References

- Andersen RA, Buneo CA. Intentional maps in posterior parietal cortex. *Annu Rev Neurosci* 2002; 25: 189–220.
- Arieno D, Babiloni C, Ferretti A, Caulo M, Del Gratta C, Tartaro A, et al. Somatotopy of anterior cingulate cortex (ACC) and supplementary motor area (SMA) for electric stimulation of the median and tibial nerves: an fMRI study. *Neuroimage* 2006; 33: 700–5.
- Begliomini C, Wall MB, Smith AT, Castiello U. Differential cortical activity for precision and whole-hand visually guided grasping in humans. *Eur J Neurosci* 2007; 25: 1245–52.
- Binkofski F, Dohle C, Posse S, Stephan KM, Hefter H, Seitz RJ, et al. Human anterior intraparietal area subserves prehension: a combined lesion and functional MRI activation study. *Neurology* 1998; 50: 1253–9.
- Blanke O. Multisensory brain mechanisms of bodily self-consciousness. *Nat Rev Neurosci* 2012; 13: 556–71.
- Burton H, Videen TO, Raichle ME. Tactile-vibration-activated foci in insular and parietal-opercular cortex studied with positron emission tomography: mapping the second somatosensory area in humans. *Somatosens Mot Res* 1993; 10: 297–308.
- Catani M. A little man of some importance. *Brain* 2017; 140: 3055–61.
- Cauda F, Costa T, Torta DME, Sacco K, D'Agata F, Duca S, et al. Meta-analytic clustering of the insular cortex: characterizing the meta-analytic connectivity of the insula when involved in active tasks. *Neuroimage* 2012; 62: 343–55.
- Craig AD. How do you feel? Interoception: the sense of the physiological condition of the body. *Nat Rev Neurosci* 2002; 3: 655–66.
- Desikan RS, Ségonne F, Fischl B, Quinn BT, Dickerson BC, Blacker D, et al. An automated labeling system for subdividing the human cerebral cortex on MRI scans into gyral based regions of interest. *Neuroimage* 2006; 31: 968–80.
- Fitzgerald PJ, Lane JW, Thakur PH, Hsiao SS. Receptive field properties of the macaque second somatosensory cortex: evidence for multiple functional representations. *J Neurosci* 2004; 24: 11193–204.

- Fogassi L, Gallese V, Fadiga L, Luppino G, Matelli M, Rizzolatti G. Coding of peripersonal space in inferior premotor cortex (area F4). *J Neurophysiol* 1996; 76: 141–57.
- Fox PT, Burton H, Raichle ME. Mapping human somatosensory cortex with positron emission tomography. *J Neurosurg* 1987; 67: 34–43.
- Glasser MF, Coalson TS, Robinson EC, Hacker CD, Harwell J, Yacoub E, et al. A multi-modal parcellation of human cerebral cortex. *Nature* 2016; 536: 171–8.
- Graziano MS, Cooke DF, Taylor CS. Coding the location of the arm by sight. *Science* 2000; 290: 1782–6.
- Graziano MS, Hu XT, Gross CG. Visuospacial properties of ventral premotor cortex. *J Neurophysiol* 1997; 77: 2268–92.
- Grecucci A, Giorgetta C, van't Wout M, Bonini N, Sanfey AG. Reappraising the ultimatum: an fMRI study of emotion regulation and decision making. *Cereb Cortex* 2013; 23: 399–410.
- Hagen MC, Zald DH, Thornton TA, Pardo JV. Somatosensory processing in the human inferior prefrontal cortex. *J Neurophysiol* 2002; 88: 1400–6.
- Huang R-S, Chen C, Tran AT, Holstein KL, Sereno MI. Mapping multisensory parietal face and body areas in humans. *Proc Natl Acad Sci USA* 2012; 109: 18114–9.
- Jeannerod M, Arbib MA, Rizzolatti G, Sakata H. Grasping objects: the cortical mechanisms of visuomotor transformation. *Trends Neurosci* 1995; 18: 314–20.
- Kaas J, Collins CE. The organization of sensory cortex. *Curr Opin Neurobiol* 2001; 11: 498–504.
- Kaas JH, Nelson R, Sur M, Lin C, Merzenich M. Multiple representations of the body within the primary somatosensory cortex of primates. *Science* 1979; 204: 521–3.
- Kammers MPM, Verhagen L, Dijkerman HC, Hogendoorn H, De Vignemont F, Schutter D. Is this hand for real? Attenuation of the rubber hand illusion by transcranial magnetic stimulation over the inferior parietal lobule. *J Cogn Neurosci* 2009; 21: 1311–20.
- Kayser C, Petkov CI, Augath M, Logothetis NK. Integration of touch and sound in auditory cortex. *Neuron* 2005; 48: 373–84.
- Konen CS, Mruzczek REB, Montoya JL, Kastner S. Functional organization of human posterior parietal cortex: grasping- and reaching-related activations relative to topographically organized cortex. *J Neurophysiol* 2013; 109: 2897–908.
- Lim SH, Dinner DS, Pillay PK, Lüders H, Morris HH, Klem G, et al. Functional anatomy of the human supplementary sensorimotor area: results of extraoperative electrical stimulation. *Electroencephalogr Clin Neurophysiol* 1994; 91: 179–93.
- Maravita A, Iriki A. Tools for the body (schema). *Trends Cogn Sci* 2004; 8: 79–86.
- Mazzola L, Isnard J, Mauguière F. Somatosensory and pain responses to stimulation of the second somatosensory area (SII) in humans. A comparison with SI and insular responses. *Cereb Cortex* 2006; 16: 960–8.
- Nakamura A, Yamada T, Goto A, Kato T, Ito K, Abe Y, et al. Somatosensory homunculus as drawn by MEG. *Neuroimage* 1998; 7: 377–86.
- Penfield W. The supplementary motor area in the cerebral cortex of man. *Arch F Psychiatr U Z Neur* 1950; 185: 670–4.
- Penfield W, Boldrey E. Somatic motor and sensory representation in the cerebral cortex of man as studied by electrical stimulation. *Brain* 1937; 60: 389–443.
- Penfield W, Faulk ME. The insula: further observations on its function. *Brain* 1955; 78: 445–70.
- Penfield W, Jasper H. *Epilepsy and the functional anatomy of the human brain*. Oxford: Little, Brown & Co; 1954.
- Penfield W, Rasmussen T. *The cerebral cortex of man; a clinical study of localization of function*. New York: Hafner; 1950.
- Petkova VI, Björnsdotter M, Gentile G, Jonsson T, Li T-Q, Ehrsson HH. From part- to whole-body ownership in the multisensory brain. *Curr Biol* 2011; 21: 1118–22.
- Reed JL, Qi H-X, Kaas JH. Spatiotemporal properties of neuron response suppression in owl monkey primary somatosensory cortex when stimuli are presented to both hands. *J Neurosci* 2011; 31: 3589–601.
- Ruben J, Schwiemann J, Deuchert M, Meyer R, Krause T, Curio G, et al. Somatotopic organization of human secondary somatosensory cortex. *Cereb Cortex* 2001; 11: 463–73.
- Saadon-Grosman N, Tal Z, Itshayek E, Amedi A, Arzy S. Discontinuity of cortical gradients reflects sensory impairment. *Proc Natl Acad Sci USA* 2015; 112: 16024–9.
- Sakata H, Takaoka Y, Kawarasaki A, Shibutani H. Somatosensory properties of neurons in the superior parietal cortex (area 5) of the rhesus monkey. *Brain Res* 1973; 64: 85–102.
- Schneider R, Gautier J-C. Leg weakness due to stroke Site of lesions, weakness patterns and causes. *Brain* 1994; 117: 347–54.
- Sur M, Merzenich MM, Kaas JH. Magnification, receptive-field area, and “hypercolumn” size in areas 3b and 1 of somatosensory cortex in owl monkeys. *J Neurophysiol* 1980; 44: 295–311.
- Tal Z, Geva R, Amedi A. The origins of metamodality in visual object area LO: bodily topographical biases and increased functional connectivity to S1. *Neuroimage* 2016; 127: 363–75.
- Taylor KS, Seminowicz DA, Davis KD. Two systems of resting state connectivity between the insula and cingulate cortex. *Hum Brain Mapp* 2009; 30: 2731–45.
- Tiitinen H, Salminen NH, Palomäki KJ, Mäkinen VT, Alku P, May P. Neuromagnetic recordings reveal the temporal dynamics of auditory spatial processing in the human cortex. *Neurosci Lett* 2006; 396: 17–22.
- Tsakiris M, Hesse MD, Boy C, Haggard P, Fink GR. Neural signatures of body ownership: a sensory network for bodily self-consciousness. *Cereb Cortex* 2007; 17: 2235–44.
- Woolsey CN, Marshall WH, Bard P. Representation of cutaneous tactile sensibility in the cerebral cortex of the monkey as indicated by evoked potentials. *Johns Hopkins Hosp Bull* 1942; 70: 399–441.
- Young JP, Herath P, Eickhoff S, Choi J, Grefkes C, Zilles K, Roland PE. Somatotopy and attentional modulation of the human parietal and opercular regions. *J Neurosci* 2004; 24: 5391–9.