



OPEN ACCESS

Evaluation of the extent of ketamine-induced uropathy: the role of CT urography

Li-Kuo Huang,¹ Jia-Hwia Wang,^{1,2} Shu-Huei Shen,^{1,2} Alex T L Lin,^{2,3}
Cheng-Yen Chang^{1,2}

¹Department of Radiology,
Taipei Veterans General
Hospital, Taipei, Taiwan

²School of Medicine, National
Yang-Ming University, Taipei,
Taiwan

³Division of Urology,
Department of Surgery, Taipei
Veterans General Hospital,
Taipei, Taiwan

Correspondence to

Dr Shu-Huei Shen, Department
of Radiology, Taipei Veterans
General Hospital, 201, Sec 2,
Shih-Pai Road, Taipei 112,
Taiwan;
shshen@vghtpe.gov.tw

Received 12 January 2013
Revised 12 December 2013
Accepted 1 January 2014
Published Online First
17 January 2014

ABSTRACT

Background With growing ketamine abuse, ketamine-induced uropathy (KIU) has become more prevalent in recent years. This research evaluates the presence, distribution and extent of KIU in the upper and lower urinary tracts by retrospectively reviewing CT urography (CTU) images.

Methods Patients diagnosed with KIU who underwent CT scanning from 1 January 2006 to 31 December 2011 were recruited. The CT protocols included three-phase CTU in six patients, split-bolus CTU in 17, two-phase CTU in one and unenhanced CT in three. The CT images were retrospectively reviewed by two radiologists.

Results A total of 27 patients participated in this study. The common CT findings included diffuse bladder wall thickening (88.9%), small bladder volume (66.7%) and perivesical inflammation (44.4%). Twelve patients (44.4%) were diagnosed with hydronephrosis, including three patients with unilateral hydronephrosis and nine with bilateral hydronephrosis. Of these patients, nine had ureteral wall thickening (33.3%) and two (7.4%) had ureterovesical junction involvement (ie, they had hydronephrosis but no ureteral wall thickening). One patient had a ureteral obstruction because of a ureter stone. The correlation between upper urinary tract involvement and grading of the interstitial cystitis was statistically non-significant ($p=0.33$). Four patients (14.8%) had a vesicovaginal fistula which could be detected in the excretory phase only.

Conclusions Upper urinary tract involvement is common in patients with KIU. CTU might aid evaluation of the extent of KIU and prompt adequate management.

The diagnosis of KIU is primarily established by the clinical presentation of severe lower urinary tract symptoms and a history of ketamine abuse, and can be further confirmed by a urine examination and urodynamic studies. Cystoscopy, which evaluates the severity of cystitis by using visual inspection⁶ and biopsy,⁵ has played a considerable role in diagnosing KIU. However, although the lower urinary tract is the primary site affected by KIU, the upper urinary tract can be involved separately or concomitantly.^{2 7 8} The incidence of KIU involving the upper urinary tract is rarely reported and varies widely in the existing literature, ranging from 13% to 51%.^{2 8} Data on the factors contributing to the extent of the disease including the dose and frequency of ketamine abuse, the severity of symptoms and radiological findings are unavailable. Cystography alone cannot evaluate the existence of upper urinary tract involvement. Ancillary imaging studies are mandatory to identify the extent of the involvement and potential complications. If the upper urinary tract is involved, nephrostomy might be necessary for relieving obstructions and early preservation of renal function. Of the various imaging tools, CT urography (CTU) is considered the most useful because it allows simultaneous assessment of both the upper and lower urinary tracts and can directly show the ureters.^{5 8}

In this study we evaluated the presence, distribution and extent of KIU in the upper and lower urinary tracts by retrospectively reviewing the CTU images of patients with KIU and correlating the images with cystoscopic findings.

INTRODUCTION

Ketamine, an anaesthetic agent introduced in the 1960s, is an N-methyl-D-aspartic acid receptor antagonist with a rapid onset of action of short duration.¹ However, it has become a recreational drug in the past 10–20 years because of its 'dissociative effect' and highly addictive nature.² Ketamine abuse has gained popularity in the Taiwanese nightclub scene. Urine analysis yielded ketamine-positive rates of 47.0% in samples collected from participants in a nightclub.³ Street ketamine abuse is a drug problem which is associated with a substantial burden to healthcare resources. In 2007 Shahani *et al*⁴ were the first to report a new clinical entity—namely, ketamine-associated ulcerative cystitis—which presented with lower urinary tract symptoms such as severe dysuria, frequency, urgency and gross haematuria. To date, at least 110 cases of ketamine-induced uropathy (KIU) have been reported in the literature.⁵

METHODS

Patients

From 1 January 2006 to 31 December 2011, the hospital records of all patients who presented to our institute with severe and intractable lower urinary tract symptoms following chronic recreational ketamine abuse were retrospectively reviewed (in non-consecutive order). Only those who had undergone CT scanning were enrolled. If the patient had more than one CT scan, only the first CT scan was analysed in this study. Clinical information including renal function, urine analysis, urinary bladder biopsy and urodynamic studies was recorded for each patient.

CT techniques

CTU was performed using a 16-MDCT scanner (Somatom Sensation 16 scanner; Siemens Medical Solutions). The CTU protocols included three-phase CTU and split-bolus CTU. Three-phase CTU



Open Access
Scan to access more
free content



CrossMark

To cite: Huang L-K,
Wang J-H, Shen S-H, *et al*.
Postgrad Med J
2014;**90**:185–190.

Table 1 Clinical features and CT findings of patients with ketamine-induced uropathy

Patient number	Age/ gender	Ketamine use duration (year)	IC grade	CT protocol	Diffuse bladder wall thickening	Small bladder volume	Enhanced bladder mucosa	Perivesical inflammation	Ureteral wall thickening	Enhanced ureteral mucosa	Hydro-nephrosis	Other significant findings
1	24/F	6	4	Three-phase CTU	+	+	+	–	–	–	–	V-V fistula
2	28/F	6	4	Three-phase CTU	+	+	+	+	+	+	+	V-V fistula
3	28/F	3	2	Three-phase CTU	+	+	+	+	+	+	+	–
4	22/M	1	4	Three-phase CTU	+	+	+	+	+	+	+	–
5	29/F	2	NA	Three-phase CTU	+	+	+	–	–	–	–	–
6	28/F	4.5	NA	Three-phase CTU	+	+	+	+	–	–	–	–
7	23/F	2	4	Split-bolus CTU	+	+	NA	–	+	NA	+	V-V fistula
8	29/F	3	3	Split-bolus CTU	+	+	NA	+	–	NA	–	V-V fistula
9	25/M	7	3	Split-bolus CTU	+	+	NA	–	–	NA	–	–
10	27/F	12	4	Split-bolus CTU	+	+	NA	–	+	NA	+	–
11	21/M	3	3	Split-bolus CTU	–	–	NA	–	–	NA	–	–
12	31/F	1.5	4	Split-bolus CTU	+	+	NA	–	–	NA	–	–
13	20/F	2	2	Split-bolus CTU	+	–	NA	+	–	NA	–	–
14	27/M	5	NA	Split-bolus CTU	+	+	NA	+	–	NA	–	–
15	20/F	0.5	3	Split-bolus CTU	+	+	NA	+	+	NA	+	–
16	28/F	6	2	Split-bolus CTU	+	+	NA	–	–	NA	–	–
17	27/F	3	3	Split-bolus CTU	+	–	NA	+	–	NA	–	–
18	26/F	4.5	2	Split-bolus CTU	+	+	NA	+	–	NA	+	–
19	22/M	1	2	Split-bolus CTU	+	+	NA	–	–	NA	+	–
20	25/M	3	3	Split-bolus CTU	+	+	NA	+	–	NA	–	–
21	24/F	2	NA	Split-bolus CTU	–	–	NA	–	–	NA	–	–
22	26/F	2.5	4	Split-bolus CTU	–	–	NA	–	+	NA	+	RK duplication
23	20/M	2	4	Split-bolus CTU	+	+	NA	–	–	NA	+	LK duplication
24	27/M	2	4	Two-phase CT	+	–	+	–	+	+	+	Blood clot*
25	37/M	3	3	Unenhanced CT	+	–	NA	+	–	NA	–	–
26	25/M	2	2	Unenhanced CT	+	–	NA	–	+	NA	+	–
27	38/M	3	NA	Unenhanced CT	+	–	NA	–	–	NA	–	–

*Blood clot in urinary bladder and bilateral ureters.

CTU, CT urography; IC, interstitial cystitis; LK, left kidney; NA, not applicable; RK, right kidney; V-V, vesicovaginal.

included unenhanced imaging from the kidney to the bladder, nephrographic phase imaging scanned 90 s after intravenous administration of 100 mL iopamidol (Iopamiro 370 mg I/mL; Bracco, Italy) at a rate of 2 mL/s of the same scan range and an excretory phase imaging 15 min after injecting the contrast medium of the same scan range. Each phase scan was reconstructed into coronal multiplanar reformation images of 3 mm thickness.

In split-bolus CTU, after acquisition of the unenhanced scan from the kidney to the bladder, 30 mL iopamidol was administered. During the delay period the patient was encouraged to change position or walk around. After a 15 min interval the patient was brought back to the scan table. Another 70 mL of iopamidol was administered at a rate of 2 mL/s and the second scan was performed after an interval of 90 s for the same scan range. The coronal multiplanar reformation images were generated using a multislice volumetric dataset of both phases at a thickness of 3 mm.

Image interpretation

The CT images were retrospectively reviewed by two radiologists (one with 3 years of general radiology experience and the other with 10 years of urology experience). Both radiologists examined the findings individually and assessed them for interobserver agreement. The CT images were assessed

specifically for the presence, distribution and extent of the following abnormalities: bladder wall thickening, bladder volume, bladder mucosal enhancement, perivesical inflammation, ureteral wall thickening, ureteral mucosal enhancement and the presence of hydronephrosis. Perivesical inflammation was defined as increased fat stranding or fascial thickening in the perivesical space, or the presence of perivesical ground glass opacity. For patients receiving three-phase CTU, the findings of the nephrographic and excretory phases were compared.

Data interpretation

To further explore the relationship between the severity of cystitis and the presence of upper urinary tract involvement in KIU, we correlated the severity of interstitial cystitis observed by cystoscopy with the presence of upper urinary tract involvement observed in CT images. The severity of interstitial cystitis was recorded according to the cystoscopic findings using the grading system of the European Society for the Study of Interstitial Cystitis (ESSIC)⁶: Grade 0, normal mucosa; Grade I, petechiae in at least two quadrants; Grade II, large submucosal bleeding (ecchymosis); Grade III, diffuse global mucosal bleeding; Grade IV, mucosal disruption, with or without bleeding or oedema. Upper urinary tract involvement observed in CT images was considered present when either ureteral wall thickening or

ureteral mucosal enhancement was noted. The correlation between interstitial cystitis grading and the presence of upper urinary tract involvement was analysed as categorical data using a χ^2 test (SPSS V.15.0; SPSS, Chicago, Illinois, USA). Furthermore, for a statistically non-significant result, a Mantel–Haenszel χ^2 test was conducted to evaluate the trend between the two groups. The statistical significance was defined as $p < 0.05$ (two-tailed).

RESULTS

Clinical features

Twenty-seven patients of mean age 25.9 years (range 20–38 years) diagnosed with KIU were recruited. The duration of ketamine abuse was 0.5–12 years. Most patients complained of frequency ($n=27$, 100%) and suprapubic pain ($n=20$, 74.1%), while some patients had other lower urinary tract symptoms including urgency ($n=14$, 51.9%), dysuria ($n=10$, 50%), nocturia ($n=9$, 33.3%) and gross haematuria ($n=8$, 29.6%). Two patients had symptoms of urine incontinence and four patients (14.8%) were confirmed to have a vesicovaginal fistula according to the CT and cystoscopic study. Cystoscopic and histopathological findings indicative of interstitial cystitis were noted in all of the 22 patients who underwent cystoscopy with a transurethral resection biopsy. Of these, six (27.3%) were ESSIC Grade II, seven (31.8%) were Grade III and nine (40.9%) were Grade IV. A urodynamic study of 14 patients was conducted. The mean bladder capacity was 66.2 mL (range 13–187 mL), with only one patient having a bladder capacity larger than 150 mL. Finally, 12 of the 14 patients showed detrusor muscle overactivity.

CT features

CT studies were performed to evaluate the disease extent, the cause of the haematuria and the presence of other complications. The time interval between the CT scans and cystoscopy ranged from 1 day to 1 month. In the 27 patients, six underwent three-phase CTU and 17 underwent split-bolus CTU. One patient had only a regular two-phase CT scan, including the unenhanced and contrast-enhanced nephrographic phases (90 s after the intravenous contrast medium was administered), because the first in-charge physician was unaware of the urological complaints. Finally, three patients (11.1%) with impaired renal function underwent only unenhanced CT scans.

The cystoscopic and CT features of the 27 patients are shown in table 1. Diffuse bladder wall thickening ($n=24$, 88.9%) and small bladder volume ($n=18$, 66.7%) were the predominant CT findings (figure 1). Twelve patients (44.4%) had perivesical inflammation and 12 (44.4%) were diagnosed with hydronephrosis (three with unilateral hydronephrosis and nine with bilateral hydronephrosis). Ureteral wall thickening, indicating upper urinary tract abnormalities, was demonstrated in nine patients (33.3%; figure 1). In one of the nine patients the initial split-bolus CTU study showed a vesicovaginal fistula without upper urinary tract involvement (figure 1A,B). However, a follow up three-phase CTU study conducted 6 months later (not included in the statistical analysis) showed bilateral ureteral wall thickening and hydronephrosis, indicating the rapid progression of the inflammatory process (figure 1C). Two patients (7.4%) had ureterovesical junction involvement and therefore were diagnosed with hydronephrosis, but they had no ureteral wall thickening. One patient had hydronephrosis because of a ureteral stone rather than KIU involvement (figure 2). Other incidental findings included a renal stone in one patient, blood clots in the urinary bladder and bilateral ureters in one patient, and ureteral duplication in two patients.

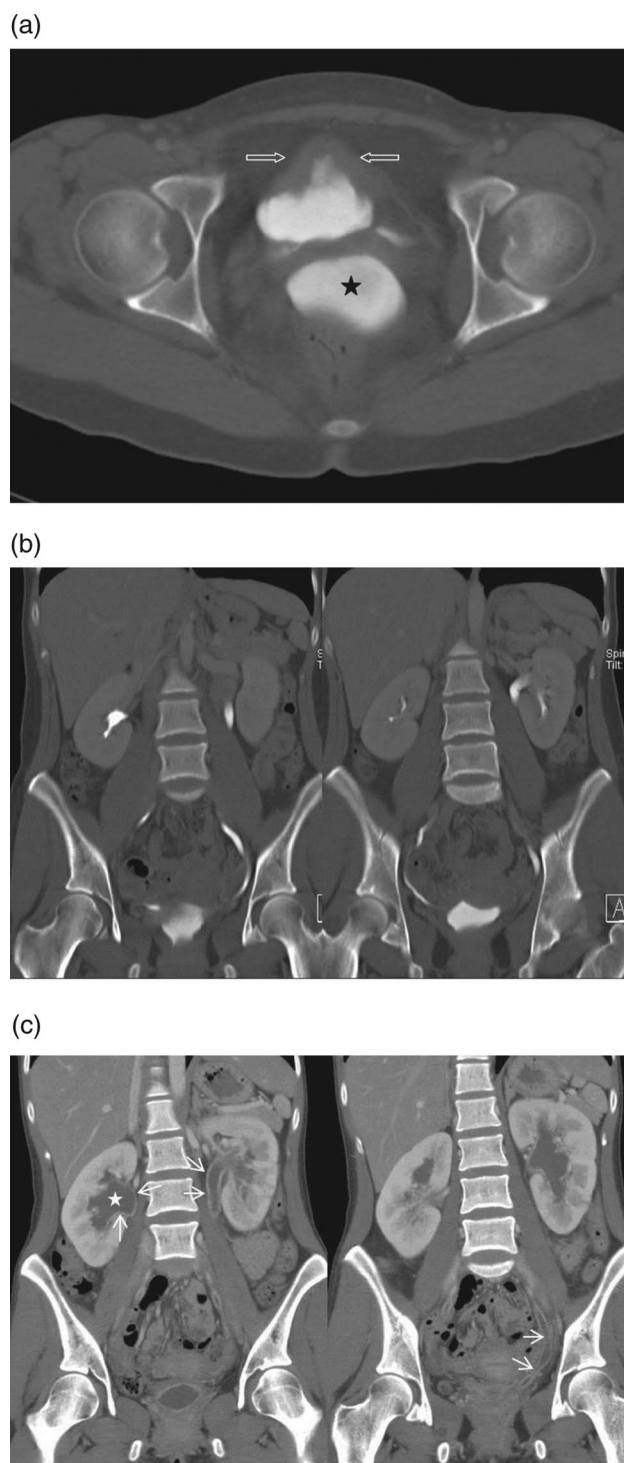
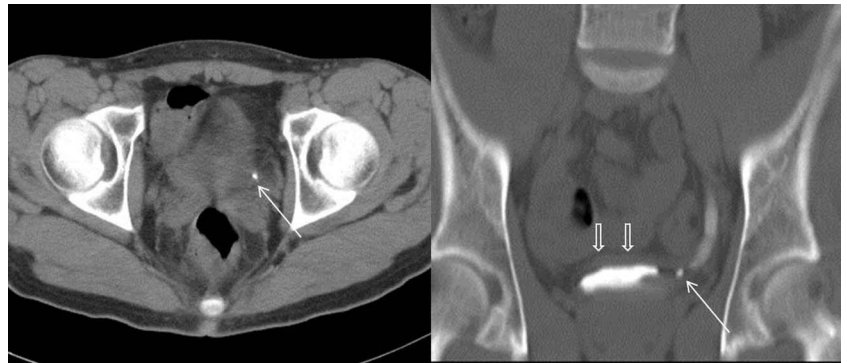


Figure 1 CT urography (CTU) study of a 24-year-old woman with a 2-year history of ketamine abuse. (A) Split-bolus CTU study. The axial image of the combined nephrographic and excretory phase shows bladder wall thickening (open arrows) and a small bladder volume. The contrast medium accumulates in the vagina, indicating the presence of a vesicovaginal fistula (black star). (B) Coronal reformatted image. The same examination shows no hydronephrosis. (C) Three-phase CTU examination after 6 months shows dilated bilateral ureters and renal collecting systems (white star) with diffuse mucosal enhancement (arrows), indicating rapid disease progression.

In the six patients who underwent three-phase CTU, the image findings in the nephrographic and excretory phases were compared. Although mucosal enhancement in the urinary

Figure 2 CT urography study of a 22-year-old man with a 1-year history of ketamine abuse, observed to have hydronephrosis and suspected of having ureteral involvement of ketamine-induced uropathy (KIU). The axial images of the unenhanced phase (left) and coronal reformation of the combined nephrographic and excretory phases (right) show a left lower ureter stone (arrows) with hydroureter. The diffusely thickened bladder wall (open arrows) is caused by KIU.



bladder (n=6) and ureter (n=3) were only demonstrated in the nephrographic phase, ureteral wall thickening in the affected segments and ureteral dilation or hydronephrosis proximal to the affected segments were invariably observed in the corresponding excretory phase. Therefore, no differences were observed regarding the disease distribution and extent of the involvement between the nephrographic and excretory phases. Furthermore, dilation of the collecting system was more apparent in the excretory phase than in the nephrographic phase. Two of the six patients had a vesicovaginal fistula which could only be detected in the excretory phase (figure 3).

In the 17 patients who underwent split-bolus CTU, perivesical changes and ureteral wall thickening could be justifiably appreciated; however, mucosal enhancement was obscured by the intraluminal contrast medium. Two of the 17 patients had a vesicovaginal fistula and were successfully diagnosed.

Clinical and imaging correlation

Upper urinary tract involvement was noted in four of the nine patients (44.4%) in the Grade IV group, one of seven (14.3%) in the Grade III group and three of six (50%) in the Grade II group. A statistically significant correlation was not noted between upper urinary tract involvement and the severity of interstitial cystitis ($p=0.33$), nor in the trend between the two groups ($p=0.96$).

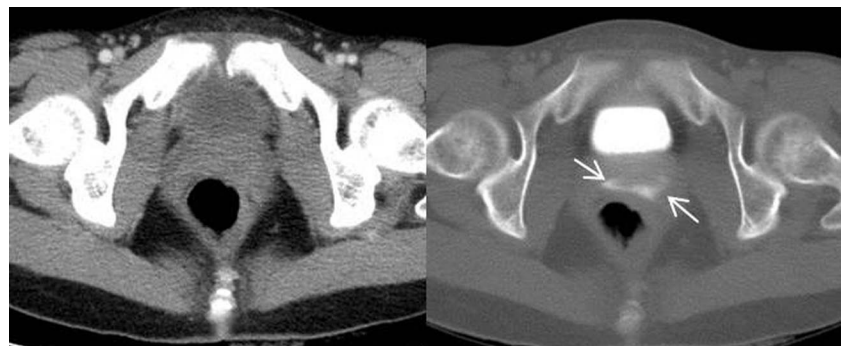
DISCUSSION

Lower urinary tract symptoms are the principal presenting symptoms in patients with KIU and, thus, lower urinary tract studies including urodynamic studies and cystoscopy have been emphasised in evaluating these patients. Rigid cystoscopy is considered an essential diagnostic tool for evaluating the cause of haematuria and the severity of interstitial cystitis in patients with KIU.⁵ However, cystoscopy is invasive and unable to demonstrate the extent of the disease. Detecting the presence of

upper urinary tract involvement is critical because the consequence of upper urinary tract involvement might be devastating and lead to irreversible renal failure. In this study we demonstrate that hydronephrosis is common in patients with KIU. Up to 44.4% of our patients with KIU had hydronephrosis, which is concordant with the findings of Chu *et al*² who reported that 51% of their study population had hydronephrosis. We observed no significant correlation between the severity of interstitial cystitis and upper urinary tract involvement of KIU. As demonstrated in figure 1, the inflammatory process of KIU might progress rapidly so cystoscopy alone is insufficient for evaluating patients with KIU. Close monitoring of renal function and imaging studies are necessary for these patients.

The underlying mechanism for urinary tract destruction in KIU remains obscure. Studies have postulated that high concentrations of ketamine and its metabolites in urine might have a direct toxic effect on urothelial cells, inducing microvascular changes and neurogenic inflammation or the evocation of an autoimmune response.²⁻⁹ The histopathological findings of a loss of muscular proportion in the bladder wall accompanying an increase in fibrotic tissue, principally in the lamina propria and the muscular layer in experimental mice treated with ketamine, could be clinically correlated with small bladder volume and limited dilation.¹⁰ Although the lower urinary tract is the primary site affected in patients with KIU, researchers have found that both the lower and upper urinary tract can be involved in KIU through the same mechanism, either separately or concomitantly.²⁻⁸ Selby *et al*¹¹ reported a case of KIU complicated by bilateral hydronephrosis; in addition, ketamine metabolites were detected in the gelatinous debris aspirated from both the pelvicalyceal systems and the ureter. A study of ketamine addiction in mice demonstrated the foci of mononuclear cell infiltration around the glomeruli and the blood vessels within the kidney and ureter, suggesting that a chronic interstitial inflammatory process is induced by ketamine.¹²

Figure 3 Three-phase CT urography study of a 24-year-old woman with a 6-year history of ketamine abuse. Axial images of the nephrographic phase (left) and the excretory phase (right). Contrast medium accumulation within the vagina (arrows) suggests that a vesicovaginal fistula can only be detected in the excretory phase.



In this study the CT images showed that most patients with hydronephrosis (9/12) had ureteral wall thickening, indicating direct involvement of the ureter by the inflammatory process. This finding is different from previous studies which suggested that, in most patients, hydronephrosis was the result of a long-term decrease in bladder compliance and vesicoureteral reflux.^{2, 13} In our study, whether vesicoureteral reflux co-existed with or aggravated the presence of upper urinary tract involvement remains unknown. However, our results suggest that Foley catheterisation alone or augmenting enterocystoplasty might not be the ideal solution for these patients. Early decompression by percutaneous nephrostomy is mandatory for renal function preservation.

Imaging studies play a critical role in delineating the extent of urinary tract involvement. Ultrasound can detect hydronephrosis; however, the level of urinary tract involvement might not be delineated clearly. Intravenous urography is another imaging modality used to evaluate KIU. However, the evaluation might be unsatisfactory when the obstruction is excessively severe or renal function is impaired. In addition, patients with lower urinary tract symptoms might find the long procedure period difficult to tolerate. CT is considered the most useful imaging tool in evaluating patients with KIU.⁸ This study shows that CT demonstrates the extent of the disease and also the cause of the obstruction and complications. Ureteral duplication was observed in 7.4% of this study population. In one patient the cause of hydronephrosis was ureter stone impaction rather than KIU. A vesicovaginal fistula is a rare but devastating complication of severe cystitis. Neither reported cases nor the exact prevalence of the vesicovaginal fistula in the population of patients with KIU has been mentioned in the relevant literature. In this study, four of the patients with KIU (14.8%) were observed to have a vesicovaginal fistula. In two of the four cases a vesicovaginal fistula was not suspected before the CT examination, possibly because the patients typically exhibited numerous concurrent lower urinary tract symptoms leading to urinary incontinence being overlooked. Detection of a vesicovaginal fistula should therefore be emphasised when interpreting the CT study for patients with KIU.

CTU has been commonly used to evaluate patients diagnosed with urinary tract symptoms, particularly those with haematuria. Conventionally, three-phase CTU comprises the non-contrast phase, the nephrographic phase and the excretory phase.^{14–16} Based on recent concerns about radiation dosages, split-bolus CTU has been introduced. By administering two separate boluses of contrast medium before the scan, both tissue perfusion information and luminal contrast can be obtained in a single scan. The radiation dose can be effectively reduced without sacrificing the ability to detect lesions in the urinary tract.^{15–19} Split-bolus CTU has been adapted as a standard protocol in numerous institutions and has been particularly emphasised for young patients. In this study we observed that the delayed phase is mandatory because a vesicovaginal fistula could be demonstrated only in the excretory phase (figure 3). Regarding the evaluation of patients with KIU, the principal concern regarding split-bolus CTU is that the mucosal enhancement would be obscured by the intraluminal contrast medium. This study showed that, in the segment of mucosal enhancement in the nephrographic phase, wall thickening and dilation of the proximal ureter were invariably observed in the corresponding segment in the excretory phase. We therefore speculate that the absence of information about mucosal enhancement does not interfere with the ability of split-bolus CTU to evaluate the extent of involvement of the inflammatory process.

This study has certain limitations. First, the number of patients is small and the power of the statistical analysis is limited. Second, this is a retrospective study and unintended selection bias inevitably exists. The clinical symptoms and signs of those receiving CTU might therefore be more severe among the ketamine abusers. The effects of patient heterogeneity, including factors such as patient age, sex, body size and duration and dose of ketamine addiction, were not taken into account, which might also have influenced the results. Third, only about half of the patients underwent a urodynamic study so the statistical correlation could not be supported.

In conclusion, given the growing and widespread use of ketamine for non-medical purposes, KIU might become more prevalent in the future. We observed that upper urinary tract involvement is common in patients with KIU. CTU might aid evaluation of the extent of KIU and prompt adequate management before the deterioration of renal function. Further observation should be continued as the number of patients presenting with KIU increases.

Main messages

- ▶ Both the upper and lower urinary tract can be damaged by ketamine-induced uropathy (KIU). The involvement of the upper urinary tract and the grading of interstitial cystitis are not significantly related.
- ▶ Upper urinary tract involvement is common in KIU, and detecting the cause of the hydronephrosis is critical for managing KIU. CT urography (CTU) is valuable in aiding the diagnosis.
- ▶ A vesicovaginal fistula is a severe complication of KIU which might be overlooked when accounting for clinical symptoms alone. CTU images aid the detection of a vesicovaginal fistula and prompt management.
- ▶ Split-bolus CTU is the appropriate protocol used to delineate the extent of the disease, to exclude other causes of the symptoms and to identify potential complications in patients with KIU.

Current research questions

- ▶ When should CT urography be introduced to evaluate patients with ketamine-induced uropathy (KIU)?
- ▶ What is the prevalence rate of vesicovaginal fistula in KIU?
- ▶ Does a correlation exist between the severity of interstitial cystitis and the occurrence of vesicovaginal fistula?

Key references

- ▶ Huang YC, Jeng CM, Cheng TC. Ketamine-associated ulcerative cystitis. *Tzu Chi Med J* 2008;20:144–6.
- ▶ Shahani R, Streutker C, Dickson B, *et al.* Ketamine-associated ulcerative cystitis: a new clinical entity. *Urology* 2007;69:810–12.
- ▶ Middela S, Pearce I. Ketamine-induced vesicopathy: a literature review. *Int J Clin Pract* 2011;65:27–30.

Contributors L-KH, J-HW and S-HS were jointly responsible for the conception and design of the study and preparation of the manuscript. L-KH was responsible for collection of the clinical data. L-KH and S-HS were responsible for interpreting the findings of CTU. ATLL was responsible for performing cystoscopy and assessing the associated findings. SHS was responsible for statistical analysis of the data, conducting the processing of the study and preparation of the final manuscript.

Competing interests None.

Ethics approval The Institutional Review Board (IRB) of Taipei Veterans General Hospital.

Patient consent Obtained.

Provenance and peer review Not commissioned; externally peer reviewed.

Open Access This is an Open Access article distributed in accordance with the Creative Commons Attribution Non Commercial (CC BY-NC 3.0) license, which permits others to distribute, remix, adapt, build upon this work non-commercially, and license their derivative works on different terms, provided the original work is properly cited and the use is non-commercial. See: <http://creativecommons.org/licenses/by-nc/3.0/>

REFERENCES

- Wood D, Cottrell A, Baker SC, et al. Recreational ketamine: from pleasure to pain. *BJU Int* 2011;107:1881–4.
- Chu PS, Ma WK, Wong SC, et al. The destruction of the lower urinary tract by ketamine abuse: a new syndrome? *BJU Int* 2008;102:1616–22.
- Lua AC, Lin HR, Tseng YT, et al. Profiles of urine samples from participants at rave party in Taiwan: prevalence of ketamine and MDMA abuse. *Forensic Sci Int* 2003;136:47–51.
- Shahani R, Streutker C, Dickson B, et al. Ketamine-associated ulcerative cystitis: a new clinical entity. *Urology* 2007;69:810–12.
- Middela S, Pearce I. Ketamine-induced vesicopathy: a literature review. *Int J Clin Pract* 2011;65:27–30.
- Nordling J, Anjum FH, Bade JJ, et al. Primary evaluation of patients suspected of having interstitial cystitis (IC). *Eur Urol* 2004;45:662–9.
- Huang YC, Jeng CM, Cheng TC. Ketamine-associated ulcerative cystitis. *Tzu Chi Med J* 2008;20:144–6.
- Mason K, Cottrell AM, Corrigan AG, et al. Ketamine-associated lower urinary tract destruction: a new radiological challenge. *Clin Radiol* 2010;65:795–800.
- Nazif O, Teichman JM, Gebhart GF. Neural upregulation in interstitial cystitis. *Urology* 2007;69:24–33.
- Tan S, Chan WM, Wai MS, et al. Ketamine effects on the urogenital system: changes in the urinary bladder and sperm motility. *Microsc Res Tech* 2011;74:1192–8.
- Selby NM, Anderson J, Bungay P, et al. Obstructive nephropathy and kidney injury associated with ketamine abuse. *NDT Plus* 2008;1:310–12.
- Yeung LY, Rudd JA, Lam WP, et al. Mice are prone to kidney pathology after prolonged ketamine addiction. *Toxicol Lett* 2009;191:275–8.
- Chiang I-N, Chang S-J, Yang SS-D, et al. Ketamine abuse associated with vesicoureteral reflux. *Incont Pelvic Floor Dysfunct* 2010;4:57–8.
- Kawashima A, Vrtiska TJ, LeRoy AJ, et al. CT urography. *Radiographics* 2004;24:S35–54.
- O'Connor OJ, Maher MM. CT urography. *AJR* 2010;195:W320–4.
- Van Der Molen AJ, Cowan NC, Mueller-Lisse UG, et al. CT Urography Working Group of the European Society of Urogenital Radiology (ESUR). CT urography: definition, indications and techniques. A guideline for clinical practice. *Eur Radiol* 2008;18:4–17.
- Chow LC, Kwan SW, Olcott EW, et al. Split-bolus MDCT urography with synchronous nephrographic and excretory phase enhancement. *AJR* 2007;189:314–22.
- O'Connor OJ, McSweeney SE, Maher MM. Imaging of hematuria. *Radiol Clin N Am* 2008;46:113–32.
- Dillman JR, Caoili EM, Cohan RH, et al. Comparison of urinary tract distension and opacification using single-bolus 3-phase vs split-bolus 2-phase multidetector row CT urography. *J Comput Assist Tomogr* 2007;31:750–7.