

Management of a difficult airway in Hunter's syndrome

Dear Editor,

We would like to report a 10-year old, 21 kg boy with a recurrent umbilical hernia scheduled for surgery. He was a diagnosed case of mucopolysaccharidosis (MPS) type 2 – Hunter's syndrome. Preoperative evaluation revealed dysmorphic face, flattened nasal bridge, macroglossia, limited mobility of the mandible, and short neck [Figure 1]. Airway imaging revealed hypertrophy with narrowed airway passages.

We decided on general anesthesia as the contents of the hernia involved bowel loops whose manipulation increased the risk of aspiration. Sedative premedication was avoided. The airway was nebulized with 4% xylocaine. Inhalational induction with preservation of spontaneous ventilation followed by supraglottic airway device (SGAD) placement and fiberoptic bronchoscope (FOB)–guided intubation was planned. A video laryngoscope (VL) (C-Mac) and a tracheostomy were kept as a backup. After induction with sevoflurane, nasopharyngeal airway insertion of sizes 4 and 5 was attempted but failed; thus, nasal fiberoptic was not attempted. A reasonable chest-rise and capnography tracing were obtained using a jaw-thrust maneuver. Neither I-gel nor Proseal- laryngeal mask airways (LMA) could be seated properly. Laryngoscopy with VL revealed that the epiglottis could be visualized but not lifted. We then decided to attempt oral FOB under C-MAC guidance. The FOB was loaded and its tip was maneuvered into the trachea. During airway manipulation, passive oxygen insufflation was maintained. After securing the tube, the anesthesia was maintained with fentanyl, atracurium,

and 1% isoflurane. The maneuver took 7 min, and the minimum saturation recorded was 84%. Extubation was performed after the child was fully awake, over an airway exchange catheter [Figure 2]. The perioperative course was uneventful.

MPS type 2 is a rare inherited disorder in which lysosomal storage defect leads to accumulation of glycosaminoglycans in soft tissue and the central nervous system.^[1] which increase with age.

Pediatric patients are unwilling candidates for awake intubation. In this case, the nasopharyngeal airway could not be maneuvered because of probable hypertrophied adenoids, and we did not force the same to avoid trauma and loss of visualization of the airway. Our patient had three of the four risk factors described by Saito *et al.*^[2] for difficult ventilation via SGAD. This is in contrast to results quoted by Madoff *et al.*^[3] who documented easy placement of SGADs in patients of MPS. This highlights that no single strategy is failsafe for the management of such a case.

Combined FOB along with VL has been used previously in Cormack-Lehane grade 3 and 4 airways in adults.^[4] There are a few case reports in children describing their combined use.^[5] The VL acts as an airway adjunct for providing airway space for manipulation of FOB and a more panoramic view. The advantage offered by the fibroscope is its increased maneuverability. Simultaneous utilization of these two devices helps combine their advantages for securing the airway.

We would like to highlight that although the plan for airway management should be premediated upon, changing or unanticipated circumstances might need a change in their

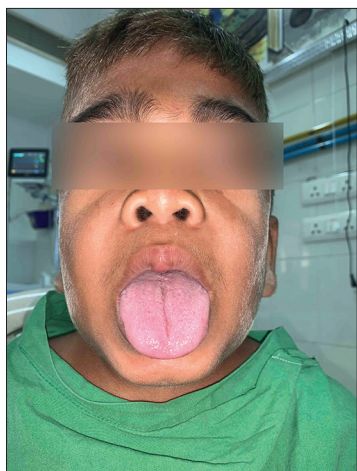


Figure 1: Preoperative image of the child illustrating macroglossia

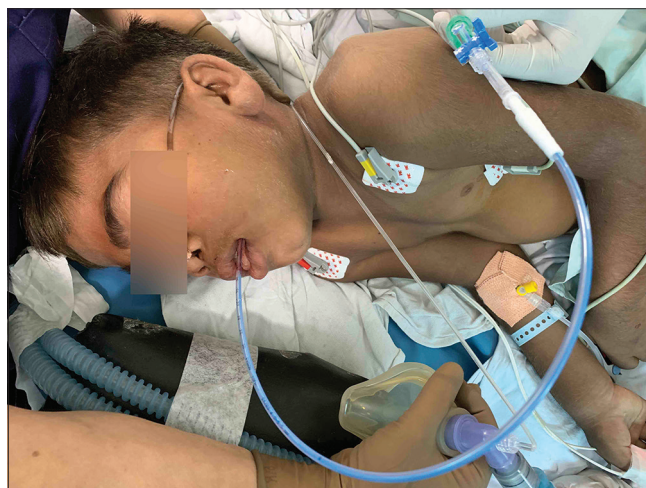

Figure 2: Postextubation image with airway exchange catheter *in situ*

order or might warrant a combination of techniques for optimum results.

Declaration of patient consent

The authors certify that they have obtained all appropriate patient consent forms. In the form the patient (s) has/have given his/her/their consent for his/her/their images and other clinical information to be reported in the journal. The patients understand that their names and initials will not be published and due efforts will be made to conceal their identity, but anonymity cannot be guaranteed.

Financial support and sponsorship

Nil.

Conflicts of interest

There are no conflicts of interest.

**Aditi Jain, Ajay Singh, Neerja Bhardwaj,
Indu M. Sen**

Department of Anaesthesia, Postgraduate Institute of Medical
Education and Research, Chandigarh, India

Address for correspondence: Dr. Aditi Jain,
8H/4; PGIMER, Chandigarh - 160 012, India.
E-mail: aditi.jain.the1@gmail.com

References

- Moretto A, Bosatra MG, Marchesini L, Tesoro S. Anesthesiological risks in mucopolysaccharidoses. *Ital J Pediatr* 2018;44:116.
- Saito T, Liu W, Chew STH, Ti LK. Incidence of and risk factors for difficult ventilation via a supraglottic airway device in a population of 14 480 patients from South-East Asia. *Anaesthesia* 2015;70:1079-83.
- Madoff LU, Kordun A, Cravero JP. Airway management in patients with mucopolysaccharidoses: The progression toward difficult intubation. *Pediatr Anesth* 2019;29:620-7.
- Liew GHC, Wong TGL, Lu A, Kothandan H. Combined use of the glidescope and flexible fibroscope as a rescue technique in a difficult airway. *Proc Singap Healthc* 2015;24:117-20.
- Fitzmaurice BC, Lambert BG. Failed fiberoptic intubation in a child with epidermolysis bullosa, rescued with combined use of the Glidescope®. *Paediatr Anaesth* 2016;26:455-6.

This is an open access journal, and articles are distributed under the terms of the Creative Commons Attribution-NonCommercial-ShareAlike 4.0 License, which allows others to remix, tweak, and build upon the work non-commercially, as long as appropriate credit is given and the new creations are licensed under the identical terms.

Access this article online	
Quick Response Code:	Website: https://journals.lww.com/joacp
	DOI: 10.4103/joacp.JOACP_260_20

How to cite this article: Jain A, Singh A, Bhardwaj N, Sen IM. Management of a difficult airway in Hunters syndrome. *J Anaesthesiol Clin Pharmacol* 2022;38:503-4.
Submitted: 22-May-2020 **Revised:** 20-Apr-2021
Accepted: 22-Apr-2021 **Published:** 02-May-2022
 © 2022 Journal of Anaesthesiology Clinical Pharmacology | Published by Wolters Kluwer - Medknow