

THE anti-inflammatory effect of microalgae *Spirulina* was studied in zymosan-induced arthritis in mice. Four days after the intra-articular injection of zymosan (15 mg/ml), *Spirulina* (100 and 400 mg/kg per orally) was administered to animals for 8 days. The mice were then killed and β -glucuronidase was measured in the synovial fluid. Each knee joint was totally removed for histopathological studies. *Spirulina* significantly reduced the levels of β -glucuronidase that had been increased by zymosan. Histopathological and ultrastructural studies showed inhibition of the inflammatory reaction, whereas no destruction of cartilage, well-preserved chondrocytes, and normal rough endoplasmic reticulum and mitochondria were seen. The anti-arthritis effect exerted by *Spirulina* as shown in this model may be at least partly due to the previously reported anti-inflammatory and antioxidative properties of its constituent, phycocyanin. To our knowledge, this is the first report on the anti-inflammatory effect of *Spirulina* in an experimental model of arthritis.

Key words: *Spirulina*, Anti-inflammatory, Zymosan, Mice, Arthritis

Inhibitory effects of *Spirulina* in zymosan-induced arthritis in mice

Diadelis Ramirez^{CA}, Ricardo González, Nelson Merino, Sandra Rodriguez and Odelsa Ancheta

Ozone International Center, Postbox 6412, Havana, Cuba

^{CA}Corresponding Author

Fax: +53 7 210233

E-mail: ozono@infomed.sld.cu

Introduction

Spirulina is an unbranched, helicoidal, filamentous blue green algae or cyanobacterium that has a long history of use as food. There are reports that *Spirulina* was used traditionally by Mexicans during the Aztec civilization for over 1000 years and also used as food by the natives in the Lake Chad Area.¹ Early interest in *Spirulina* focused mainly on its potential as a source of protein and vitamins, but recently more attention has been made to study its therapeutic use, and a number of published reports suggest beneficial effects of this microalgae in hypertension, its anti-cancer and immune suppressing actions,^{2–4} and its antioxidant properties.⁵

Recently, we reported that phycocyanin, a biliprotein found in *Spirulina*, exerts a scavenging action against reactive oxygen species (ROS) as well as anti-inflammatory activity demonstrated in various *in vitro* and *in vivo* models.^{6–8}

Furthermore, phycocyanin also exerted anti-inflammatory and anti-arthritis effects in zymosan-induced arthritis in mice.⁹ Taking into account the former findings and the fact that phycocyanin is the most abundant pigment of *Spirulina* that represents approximately 20% of algal dry weight,¹⁰ we decided to elucidate whether *Spirulina* may exert similar inhibitory effects in this zymosan-induced arthritis model as that observed for phycocyanin.

Materials and methods

Animals

Female 6-week-old OF1 mice from National Center for Production of Laboratory Animals (CENPALAB, Havana, Cuba) were used in this study. They were housed under a 12 h light-dark cycle with room temperature maintained at 23°C, humidity at 55%, and food and water available *ad libitum*. The experiments were conducted in accordance with the ethical guidelines for investigations in laboratory animals and were approved by the Ethical Committee for Animal Experimentation of the National Center for Scientific Research. All reagents not specifically described were purchased from Sigma (St Louis, MO, USA). Microalgae *Spirulina* available with the trade name Spirulan was kindly provided by Genix Enterprise (Havana, Cuba).

Zymosan-induced arthritis in mice

The mice (10 per group) were injected intra-articularly with 10 μ l of a 15 mg/ml sterile suspension of zymosan.¹¹ Four days after zymosan injection, a water suspension of *Spirulina* (100 and 400 mg/kg) or triamcinolone (10 mg/kg), which was used as a reference drug, were administered orally on a daily basis, from days 4 to 12. Mice were then killed by cervical dislocation and the synovial fluid of knee joints was sampled to measure the level of β -glucuronidase

enzyme. Afterwards the knee joints were totally removed for histological and ultrastructural studies.

Appropriate controls of mice only treated with *Spirulina* and the vehicle were used.

Determination of β -glucuronidase activity

β -Glucuronidase activity was measured in the synovial fluid of knee joints of mice.¹² The patellar ligament was cut and the synovial cavity incised, the total synovial fluid was then absorbed by means of small pieces of filter paper (No. 1575; Prolabo). The paper tips impregnated with synovial fluid were cut and deposited at the bottom of tubes containing 0.9 ml of 50 mM acetate buffer (pH 4.5). The enzyme was measured in presence of its substrate (phenolphthalein mono- β -glucuronic acid, 20 mM), after incubation for 17 h at 37°C. Then 2.5 vol of 200 mM glycine buffer (pH 10.45) was added to induce the coloration of the phenolphthalein produced by the enzymatic cleavage of the substrate. Samples were read at 540 nm, the coloration being stable for at least 1 h. Titers were based on comparisons with standard curves obtained with β -glucuronidase (type B-1 from bovine liver). The values are expressed in units of enzymatic activity.

Histological processing

Knee joints were removed and fixed in phosphate-buffered formalin (10%). The tissues were decalcified with 5% formic acid solution and thereafter they were processed and embedded in paraffin. Total joint sections (6 μ m) were prepared and stained with hematoxylin and eosin. Arthritis was assessed semi-quantitatively in a standardized frontal section of the knee joint that included the presence of subsynovial inflammation, destruction of articular cartilage, and general destruction of the joint with pannus formation and bone erosion.¹³ These parameters were scored on a scale of 0–4 as described elsewhere:^{9–13} 0, no abnormalities, normal joint feature; 1, marginal destruction of cartilage only and slight inflammation in the articular tissue; 2, extensive inflammation and moderate cartilage destruction with slight bone erosion, usually on one side of the joint only; 3, extensive

inflammation and significant destruction of both cartilage and bone; and 4, almost complete cartilage destruction with no intact cartilage left, almost complete loss of the general joint architecture with extensive pannus formation and bone erosion, extensive inflammation in the articular tissue, mainly by mononuclear cells (lymphocytes, plasma cells, macrophages), often accompanied by polymorphonuclear granulocytes. The score given to each joint is an average for the three histological sections through that joint.

Thus, the pathologist examined the parameters by a blinded procedure and classified the severity of the knee joint lesions in each mouse into five grades: grade 0, normal; grade 1, slight; grade 2, moderate; grade 3, marked; grade 4, severe.

Transmission electron microscopy

Samples of articular cartilage were fixed in 3.2% glutaraldehyde in cacodilate buffer, post-fixed in 2% osmium tetroxide and embedded in Spurr resin.¹⁴ Sections were stained with lead citrate and uranyl acetate,¹⁵ and observed in a JEOL JEM-100s Electron Microscope (Japan).

Statistical analysis

Data are presented as mean \pm standard deviation. Mean differences between groups were compared by one-way analysis of variance with the Duncan's test. The level of statistical significance was taken at $p < 0.05$.

Results

Spirulina effect on zymosan-induced arthritis

Zymosan-induced arthritis resulted in a significant increase of β -glucuronidase levels, which were decreased by *Spirulina* at doses of 100 and 400 mg/kg per-orally (p.o.). This effect was dose dependent (Table 1). Triamcinolone almost completely abolished enhanced β -glucuronidase activity in the synovial fluid of zymosan-treated animals. Daily doses of 100 and 400 mg/kg suppressed the enzymatic activity by 78.7 and 89.2%, respectively (Table 1).

Table 1. Effect of *Spirulina* on β -glucuronidase activity in mice knee joint synovial fluid

Kind of treatment	Doses	β -Glucuronidase (U)	Inhibition (%)
Saline		0.70 \pm 0.25	–
Zymosan	15 mg/ml	5.15 \pm 1.20	–
Triamcinolone + zymosan	10 mg/kg	1.00 \pm 0.20*	94.1
<i>Spirulina</i> + zymosan	100 mg/kg + 15 mg/kg	2.82 \pm 0.68*	78.7
<i>Spirulina</i> + zymosan	400 mg/kg + 15 mg/kg	1.80 \pm 0.19*	89.2

Mice were killed 24 h after the last administration of *Spirulina*. It was administered 4 days after zymosan treatment for 12 days. Triamcinolone was used as a positive control drug in this test. Values are means from groups of 10 mice \pm standard error.

* $p < 0.05$ versus group treated only with zymosan.

Histopathological studies

In agreement with these findings, histological evaluation revealed that the group treated with zymosan showed severe destruction of cartilage with loss of the general joint architecture and pannus formation. There was erosion of bone structures accompanied by severe inflammation of articular tissues (Grades 3 and 4) (Fig. 1a and Table 2).

Spirulina treatment (100 and 400 mg/kg p.o.) revealed a marked decrease of histology score (Grades 1 and 2), the inflammatory reaction was substantially reduced and there was no destruction of general joint architecture or pannus formation. Also, a reduction of bone erosion was observed (Fig. 1b). At the Spirulina doses of 100 and 400 mg/kg, 60 and 80% of the treated mice, respectively, only showed slight lesions on the joints (Table 2). Even greater protective effects were observed with the reference drug, triamcinolone (Table 2).

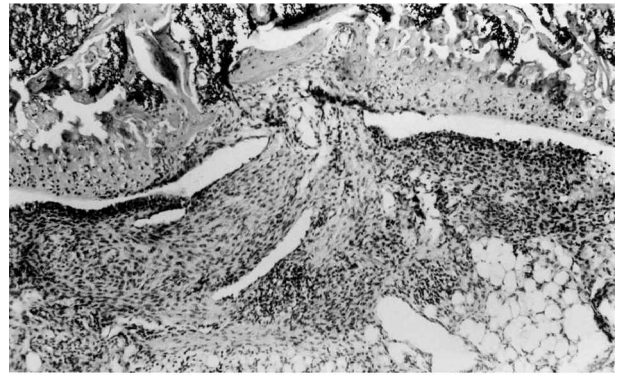
Ultrastructural studies

Tibial articular cartilage of mice treated with zymosan showed chondrocytes with ultrastructural changes in the mitochondria, loss of cristae and swollen matrix. Separation between collagen fiber bundles were also observed (Fig. 2a).

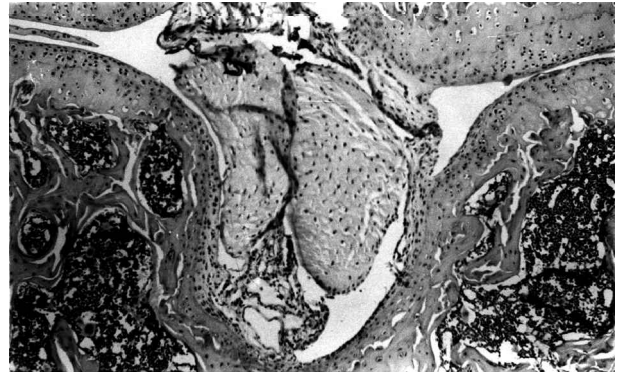
On the contrary, the cartilage of mice treated with zymosan plus Spirulina (400 mg/kg p.o.) showed well-preserved chondrocytes with normal rough endoplasmic reticulum. The collagen fibers present a normal arrangement (Fig. 2b).

Discussion

Rheumatoid arthritis is a chronic systemic autoimmune inflammatory disease characterized by progressive joint damage and, in its later stages, cartilage destruction. The current concept of the pathophysiology of this disease is that the inflammation and tissue destruction result from an unregulated cascade of complex cell-to-cell interactions, initiated by macrophage activation and induced by some inflammatory triggers.¹⁶ Zymosan, a product consisting of purified



(a)



(b)

FIG. 1. (a) Histological section of the knee joint infected with 15 mg/ml of zymosan. Extensive pannus formation with erosion of joint cartilage and bone. Hematoxylin and eosin, 100 \times . (b) Mouse treated with zymosan plus Spirulina, 400 mg/kg p.o. Histology of the knee shows only minimal inflammatory reaction. Hematoxylin and eosin, 100 \times .

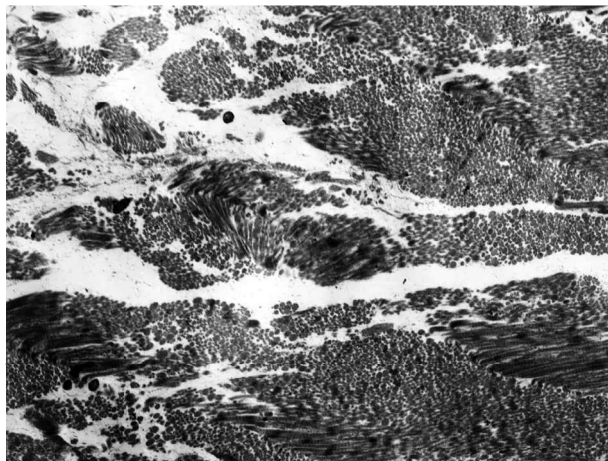
baker's yeast ghost cells, induces inflammatory processes in which the macrophages play an important role, and the activation of the synthesis of cytokines and various pro-inflammatory mediators such as prostaglandins and leukotrienes occurs.¹⁷ Zymosan also activates complement via an alternative pathway, and induces secretion of lysosomal enzymes and ROS generation from the macrophages.¹⁸ Currently, it is recognized that ROS such as OH \cdot , H $_2$ O $_2$ and HOCl are strongly involved in RA.¹⁹

In accordance with these findings, some antioxidant agents such as *N*-acetylcysteine,²⁰ ketoprofen²¹ and


Table 2. Articular histological lesions of the knee in zymosan-induced arthritis in mice treated with Spirulina

Kind of treatment	Dose	Grade 0 (%)	Grade 1 (%)	Grade 2 (%)	Grade 3 (%)	Grade 4 (%)
Saline		100	–	–	–	–
Zymosan	15 mg/ml	–	–	–	50	50
Triamcinolone + zymosan	10 mg/kg	90	10	–	–	–
Spirulina + zymosan	100 mg/kg	–	60	40	–	–
Spirulina + zymosan	400 mg/kg	–	80	20	–	–

Histological studies were read and scored on a scale of 0–4 according to the severity of the lesions: grade 0, normal; grade 1, slight; grade 2, moderate; grade 3, marked; grade 4, severe. The animals in each group were assessed for lesions. Triamcinolone was used as reference drug.



(a)



(b)

FIG. 2. (a) Transmission electron microscopy image of tibial cartilage treated with 15 mg/ml of zymosan. Edema between the collagen fibrils package is shown. 12,000 \times . (b) Transmission electron microscopy image of tibial cartilage treated with 15 mg/ml of zymosan plus 400 mg/kg Spirulina. A normal arrangement of collagen fibrils is observed. 12,000 \times .

ebesen²² exerted protective effects in some arthritis models.

Recently, we reported that phycocyanin has antioxidant properties.⁶ It was able to scavenge alkoxy and hydroxyl radicals, and also inhibited hepatic microsomal lipid peroxidation induced by Fe⁺²-ascorbic acid, the luminol-amplified chemiluminescent response of PMNs stimulated with opsonized zymosan. Phycocyanin also inhibited, in a dose-dependent fashion, the inflammatory response in zymosan-induced arthritis in mice. Furthermore, the biliprotein also inhibited edema and leukotriene B₄ and prostaglandin E₂ generation in arachidonic acid-induced ear edema in mice.^{23,24}

Taking into account the former findings, it is conceivable that the anti-inflammatory and anti-arthritic effects of Spirulina already described may be due mainly to antioxidant and anti-inflammatory activities of its constituent phycocyanin. Some evidence support this view: (1) in our hands, phycocyanin

exerted protective effects in zymosan-induced arthritis at doses of 25, 50 and 100 mg/kg p.o., whereas under the same experimental conditions Spirulina exerted its inhibitory effects in this model at greater doses (100 and 400 mg/kg, p.o.), which correlates with 20–25% that represents phycocyanin in the composition of Spirulina;¹⁰ (2) our results do not provide any evidence in favor of pharmacological synergism of phycocyanin with other constituents of Spirulina with antioxidant and anti-inflammatory properties such as β -carotene, phenolic compounds and the essential polyunsaturated fatty acids. However, these substances are available in Spirulina in much lower concentrations than phycocyanin.^{5,25} Nevertheless, a minor contribution of the former compounds to anti-inflammatory effects of Spirulina cannot be excluded.

In conclusion, Spirulina exerts anti-inflammatory effects in experimental arthritis and, taking into account that the microalgae is commonly used as food supplement and its safety as human food has been established through various toxicological studies,^{26,27} we believe that Spirulina merits further pre-clinical and clinical studies to determine its place as potential drug for the treatment of rheumatoid arthritis and other inflammatory diseases.

References

- Ciferri O, Tiboni O. The biochemistry and industrial potential of Spirulina. *Ann Rev Microbiol* 1985, **39**: 503–526.
- Iwata K, Inayama T, Kato T. Effects of Spirulina platensis on plasma lipoprotein lipase activity in fructose-induced hyperlipidemic rats. *J Nutr Sci Vitaminol* 1990, **36**: 165–171.
- Belay A, Ota Y, Miyakawa K, Shimamatsu H. Current knowledge on potential health benefits of Spirulina. *J Appl Phycol* 1993, **5**: 235–241.
- Hayashi O, Katoh T, Okuwaki Y. Enhancement of antibody production in mice by dietary Spirulina. *J Nutr Sci Vitaminol* 1994, **40**: 431–441.
- Miranda MS, Cintra RG, Barros SBM, Mancini-Filho J. Antioxidant activity of the microalgae Spirulina maxima. *Braz J Med Biol Res* 1998, **31**: 1075–1079.
- Romay Ch, Armesto J, Ramirez D, González R, Ledón N, García I. Antioxidant and anti-inflammatory properties of c-phycocyanin from blue-green algae. *Inflamm Res* 1998, **47**: 36–41.
- Romay Ch, Ledón N, González R. Further studies on anti-inflammatory activity of phycocyanin in some animal models of inflammation. *Inflamm Res* 1998, **47**: 334–338.
- González R, Rodríguez S, Romay Ch, Ancheta O, González A, Armesto J, Ramirez D, Merino N. Anti-inflammatory activity of phycocyanin extract in acetic acid-induced colitis in rats. *Pharmacol Res* 1999, **39**: 55–59.
- Ramirez D, González A, Merino N, González R, Ancheta O, Romay Ch, Rodríguez S. Effect of phycocyanin in zymosan-induced arthritis in mice. *Drug Dev Res* 1999, **48**: 70–75.
- Richmond A. Large scale microalgal culture and applications. In: Chapman R, ed. *Progress in Phycollogical Research*, Vol. 7. Biopress Ltd, 1990.
- Keystone EC, Schorlemmer HU, Pope C, Allison AC. Zymosan-induced arthritis. A model of chronic proliferative arthritis following activation of the alternative pathway of complement. *Arthritis Rheum* 1977, **20**: 1396–1401.
- Follard F, Terlain A. A novel method for the sampling of synovial fluid in mice. Assay of a synovial lysosomal enzyme in zymosan induced arthritis. *Agents Actions* 1998, **25**: 139–145.
- Beckman N, Bruttel K, Schuurman H, Mir A. Effects of sandimmune neoral on collagen-induced arthritis in DA rats: characterization by high resolution three-dimensional magnetic resonance imaging and by histology. *J Magn Reson* 1998, **131**: 8–16.
- Spurr ERA. A low viscosity epoxy resin embedding medium for electron microscopy. *J Ultrastr Res* 1969, **26**: 31–35.
- Reynold ES. The use of lead citrate at high pH as an electron-opaque stain in electron microscopy. *J Cell Biol* 1963, **17**: 208–213.
- Chikanza IC, Jawed S, Naughton D, Blake DR. Why do we need new treatments for rheumatoid arthritis? *J Pharm Pharmacol* 1998, **50**: 357–369.

17. Cuzzocrea S, Costantino G, Caputi AP. Protective effect of *N*-acetylcysteine on cellular energy depletion in a non-septic shock model induced by zymosan in the rat. *Sbock* 1999, **11**: 143-148.
18. Allison AC. Role of macrophage activation in the pathogenesis of chronic inflammation and its pharmacological control. *Adv Inflamm Res* 1984, **7**: 201-216.
19. Miesel R, Zuber M. Elevated levels of xanthine oxidase in serum of patients with inflammatory and autoimmune diseases. *Inflammation* 1993, **17**: 551-561.
20. Kröger H, Miesel R, Dietrich A, Ohde M, Altrichter S, Braun C, Ockenfels H. Suppression of type II collagen-induced arthritis by *N*-acetyl-L-cysteine in mice. *Gen Pharmacol* 1997, **29**: 671-674.
21. Billany MR, Denman S, Jameel S, Sugden JK. Topical anti-rheumatic agents as hydroxyl radical scavengers. *Int J Pharm* 1995, **124**: 279-283.
22. Schewe T. Molecular actions of ebselen, an anti-inflammatory anti-oxidant. *Gen Pharmacol* 1995, **26**: 1153-1169.
23. Romay Ch, Ledón N, González R. Phycocyanin extract reduces leukotriene B₄ levels in arachidonic acid-induced mouse ear inflammation test. *J Pharm Pharmacol* 1991, **51**: 641-642.
24. Romay Ch, Ledón N, González R. Effects of phycocyanin extract on prostaglandin E₂ levels in mouse ear inflammation test. *ArzneimForsch/DrugRes* 2000, **50**: 1106-1109.
25. Henrikson R. *Microalgae Spirulina*. Barcelona: Urano, 1994.
26. Chamorro GA, Salazar M. Dominant letal assay of *Spirulina máxima* in male CD-1 mice after short-term and prolonged-term feeding. *J Food Protect* 1989, **52**: 125-127.
27. Salazar M, Chamorro GA. Effect of *Spirulina máxima* consumption on reproduction and peri- and postnatal development in rats. *Food Chem Toxicol* 1996, **34**: 353-359.

Received 25 September 2001

Accepted 21 January 2002