

When the diagnosis is written in the DNA: a case of erythropoietic protoporphyria in a patient with a chromosome-18 deletion

Sara Rovaris,¹ Giuseppe La Rosa,¹ Sara Mezzana,¹ Francesco Tonon,¹ Luigi Mori,² Eugenio Monti,² Giuseppe Mazzeo,² Piergiacomo Calzavara-Pinton,¹ Mariachiara Arisi¹

¹Department of Dermatology, University of Brescia, Spedali Civili Hospital, Brescia; ²Department of Molecular and Translational Medicine, University of Brescia, Italy

Abstract

In this case study, we describe a 21-year-old man with erythropoietic protoporphyria who sought medical attention in April 2022 for diffuse edema and erythema of the hands. These symptoms had been present since childhood and usually occurred soon after sun exposure. The patient's medical history showed that chromosome 18's long arm had partially deleted. We performed a number of tests, including measuring total erythrocyte protoporphyrin levels and utilizing a spectrofluorometer to assess the fluorometric emis-

sion peak of plasma porphyrins, based on the patient's medical history and clinical symptoms. Furthermore, a genetic analysis identified an intronic variant on one allele, c.315-48T>C (IVS3-48T>C), which is categorized as a susceptibility polymorphism, and a complete deletion of the ferrochelatase gene on the other allele. The patient's clinical condition improved following the June 2022 afamelanotide implant procedure.

Correspondence: Sara Rovaris, Department of Dermatology, University of Brescia, Piazzale Spedali Civili 1, 25121, Brescia, Italy.
E-mail: s.rovaris@unibs.it

Key words: erythropoietic protoporphyria; chromosome 18; afamelanotide.

Conflict of interest: the authors declare no potential conflict of interest.

Funding: none.

Ethics approval and consent to participate: no ethical committee approval was required for this case report by the Department, because this article does not contain any studies with human participants or animals. Informed consent was obtained from the patient included in this study.

Consent for publication: the patient gave his written consent to use his personal data for the publication of this case report and any accompanying images.

Received: 28 June 2023.

Accepted: 1 July 2023.

This work is licensed under a Creative Commons Attribution-NonCommercial 4.0 International License (CC BY-NC 4.0).

©Copyright: the Author(s), 2023

Licensee PAGEPress, Italy

Dermatology Reports 2024; 16:9784

doi:10.4081/dr.2023.9784

Publisher's note: all claims expressed in this article are solely those of the authors and do not necessarily represent those of their affiliated organizations, or those of the publisher, the editors and the reviewers. Any product that may be evaluated in this article or claim that may be made by its manufacturer is not guaranteed or endorsed by the publisher.

Introduction

Erythropoietic protoporphyria (EPP) is a rare metabolic disorder caused by a deficiency of the ferrochelatase (FECH) gene, which, in most cases, results from inherited mutations in the FECH gene.¹ EPP has a prevalence ranging between 1:75,000 and 1:180,000 in Europe. Due to low levels of FECH, excessive amounts of protoporphyrin IX accumulate in the skin, the bone marrow, blood plasma, and red blood cells.² The major symptom associated with this disorder is acute phototoxicity upon sun exposure, as a result of an excited energy states of the accumulated porphyrins causing tissue and endothelial damage. Some patients may also develop some grades of hepatotoxicity and, eventually, liver failure due to deposition in bile and/or hepatocytes.³ Over 190 mutations have been reported in the FECH gene, and genetically driven cases typically present in early childhood. Onset in adulthood has rarely been reported, usually in association with myelodysplastic syndrome.⁴

Case Report

We present the case of a 21-year-old man who came to our attention in April 2022 due to diffuse edema and erythema of the hands (Figure 1). The patient complained of a burning, stinging sensation and intense pain, occurring after a few minutes upon sun exposure, and which would be followed by redness and swelling that persisted for several days. He also described a worsening of the symptoms upon heat exposure. This condition significantly impacted his quality of life, avoiding any light-associated behavior. The patient's clinical history was significant as he presented psychomotor retardation and facial dysmorphisms, attributed to a partial deletion of the long arm of chromosome 18.⁵ In previous dermatological evaluations, solar urticaria was primarily suspected, but the atypical appearance of the skin lesions and their painful nature led us to consider EPP as the primary diagnosis. We conducted several tests, including erythrocyte protoporphyrin levels and fluorometric emission peak of plasma porphyrins, which confirmed our suspect (Figure 2). To confirm the diagnosis, we conducted a genetic analysis on the patient's peripheral blood that

showed the deletion of the entire FECH-gene on one allele, while on the other allele was found an intronic variant, which is classified in the literature as a susceptibility polymorphism: c.315-48T>C (IVS3-48T>C). Our patient underwent an afamelanotide – an α -melanocyte-stimulating hormone analog – implant in June

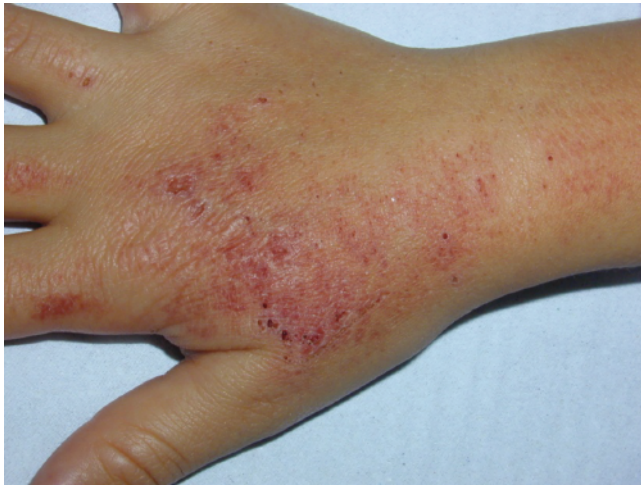

Figure 1. Intense painful lesions on the right hand of the patient.

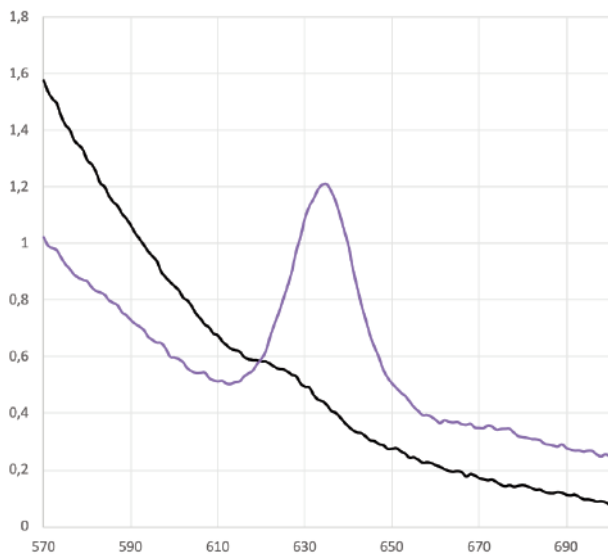


Figure 2. Fluorimetric emission curve of a healthy subject (black) and a subject affected by erythropoietic protoporphyria (purple).

2022. About 3 weeks after implantation, at the first follow-up visit, the patient reported an improvement in his clinical condition.

Discussion and Conclusions

Genetic analysis revealed a complete deletion of the FECH gene on one patient's allele, resulting from the partial deletion of the long arm of chromosome 18. The other allele exhibited an intronic variant (IVS3-48T>C), classified as a susceptibility polymorphism.¹ These findings definitively confirmed the diagnosis of EPP due to FECH variants, with an autosomal recessive pattern of inheritance. Traditionally, EPP management focused on light avoidance, photoprotection, and symptomatic treatment.⁵ However, a recent breakthrough in treatment options is the use of afamelanotide, an α -melanocyte-stimulating hormone analog, administered as a subcutaneous implant.⁶ Afamelanotide improves light tolerance and overall quality of life in EPP patients by activating eumelanogenesis and providing photoprotection.⁷ In summary, the authors presented this case as a case of EPP caused by a rare form of a severe FECH variant (complete deletion of the gene caused by the partial deletion of the long arm of chromosome 18) paired with the common low-expression variant allele (IVS3-48T/C) which had a good response to the treatment with afamelanotide.

References

- Balwani M. Erythropoietic protoporphyria and X-linked protoporphyria: pathophysiology, genetics, clinical manifestations, and management. *Mol Genet Metab* 2019;128:298-303.
- Snast I, Kaftory R, Sherman S, et al. Acquired erythropoietic protoporphyria: a systematic review of the literature. *Photodermatol Photoimmunol Photomed* 2020;36:29-33.
- Ventura P, Brancaleoni V, Di Pierro E, et al. Clinical and molecular epidemiology of erythropoietic protoporphyria in Italy. *Eur J Dermatol* 2020;30:532-40.
- Lecha M, Puy H, Deybach JC. Erythropoietic protoporphyria. *Orphanet J Rare Dis* 2009;4:19.
- Magness ST, Tugores A, Christensen SR, et al. Deletion of the ferrochelatase gene in a patient with protoporphyria. *Hum Mol Genet* 1994;3:1695-7.
- Kim ES, Garnock-Jones KP. Afamelanotide: a review in erythropoietic protoporphyria. *Am J Clin Dermatol* 2016;17:179-85.
- Wensink D, Wagenmakers MAEM, Langendonk JG. Afamelanotide for prevention of phototoxicity in erythropoietic protoporphyria. *Expert Rev Clin Pharmacol* 2021;14:151-60.