

Pediatrics

Unusual Presentation of Renal Vein Thrombosis in a Preterm Infant

Chang-Yo Yang^{a,b,*}, Ren-Huei Fu^b, Reyin Lien^b, Peng-Hong Yang^b^a Division of Newborn Medicine, Department of Pediatrics, University of Southern California, Children's Hospital, Los Angeles, CA, USA^b Division of Neonatology, Chang Gung Children's Hospital and Chang Gung Memorial Hospital, Chang Gung University College of Medicine, Taoyuan, Taiwan

ARTICLE INFO

Article history:

Received 29 January 2014

Accepted 6 February 2014

Available online 22 March 2014

Keywords:

Prematurity

Renal vein thrombosis

Hematuria

Hypertension

ABSTRACT

Neonatal renal vein thrombosis is the most common vascular condition in the newborn kidney, which could lead to serious complication in infants undergoing intensive care. In this study, we report the case of a preterm infant with left renal vein and inferior vena cava thrombosis, presented with gross hematuria, thrombocytopenia, transient hypertension, and adrenal hemorrhage. Supportive care was offered instead of heparin therapy or thrombolytic agents. In conclusion, our case teaches that, despite the lack of a clinically obvious shock event, renal vein thrombosis should be considered in a macro-hematuric newborn without renal failure.

© 2014 The Authors. Published by Elsevier Inc. Open access under [CC BY-NC-ND license](https://creativecommons.org/licenses/by-nc-nd/4.0/).

Introduction

Renal vein thrombosis (RVT) is the most common vascular condition in the newborn kidney. Factors predisposing a neonate to RVT include prematurity, dehydration, sepsis, birth asphyxia, shock, maternal diabetes, polycythaemia, cyanotic congenital heart disease, and the presence of indwelling umbilical venous catheters.¹ Possible mechanisms include reduced renal blood flow, hyperosmolality, hypercoagulability, and increased blood viscosity. RVT typically presents with a flank mass, hematuria, hypertension, and renal failure. These signs are frequently masked in a sick neonate. Neonates with RVT have significant morbidity, particularly hypertension and renal failure. Therefore, the prognosis depends on the time of diagnosis.

Case presentation

The patient was a 1730-g male baby, born at 31 weeks gestation to a 37-year-old mother by cesarean section because of placenta previa with maternal bleeding and fetal distress. Initial chest radiograph showed respiratory distress syndrome. The baby required 1 dose of surfactant and 2 days of ventilation support. Umbilical venous catheterization was set for administration of intravenous fluids, nutrition, and medication.

A sepsis episode happened on day 6 of life. Blood culture was positive for *Escherichia coli* and *Acinetobacter baumannii*. After 4 days of amikacin treatment, the baby stabilized. Percutaneous central venous catheterization through right femoral vein was established on day 14 of life. On day 21, the baby became lethargy but afebrile, accompanying with nonbilious vomiting and blood clot in urine. Blood culture and the tip culture of right femoral catheter were negative. The complete blood count showed leukocytosis (white blood cell = 32,000/ μ L) and thrombocytopenia (platelet = 99,000/ μ L). C-reactive protein was 10.2 mg/L. Serum creatinine and blood urea nitrogen concentrations were normal. Urine sediments revealed red blood cell count to be 340 (normal <20/ μ L). The renal ultrasound scan (Fig. 1) showed marked enlargement of left kidney with anechoic cyst-like lesion over the left suprarenal area, compatible with adrenal hemorrhage. The left kidney became echogenic with prominent echobright intermedullary streaks. Abdominal computed tomographic (CT) scan (Fig. 2) revealed left RVT extending to inferior vena cava (IVC), in addition to left adrenal hemorrhage. Hypertension with systolic blood pressure (BP) >100 mm Hg occurred 3 days later, which gradually subsided after 4 days of hydralazine usage. At 36th day of age, repeat ultrasonography showed that left kidney returned to normal size, and left adrenal hemorrhage was in regression. No azotemia happened during this period.

The patient was discharged 6 weeks later. The condition of the patient was rather stable with normal BP when followed up in the outpatient department at age 6 months. Serial follow-up of renal echo showed left kidney atrophy. Follow-up CT angiography 3 months later revealed small contracted left kidney with poor function and nonvisualization of left renal vein.

* Corresponding author. Tel.: +1-886-3-328-1200x8203; fax: +1-886-3-328-8957.

E-mail address: changyo@adm.cgmh.org.tw (C.-Y. Yang).

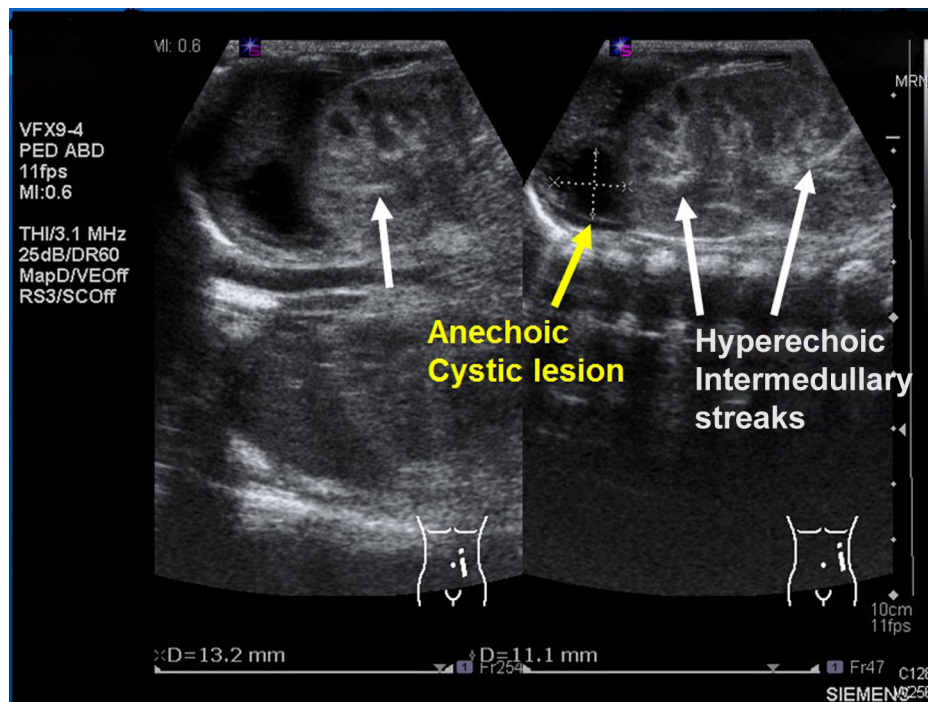


Figure 1. Longitudinal ultrasound scan shows a swollen left kidney with a suprarenal anechoic cyst-like lesion and hyperechoic intermedullary streaks (arrows) in the initial phase of renal vein thrombosis.

Discussion

The incidence of RVT in term neonates based on clinical data is estimated at 2.2/100,000 live births. There is a 6-fold higher rate in preterm infants, which may account for one half of neonate cases. In up to 30% of cases, RVT extends to the IVC. In about 10%, it is associated with adrenal hemorrhage.¹ The epidemiologic database of neonatal RVT in Taiwan shows lack of information.

Acquired risk factors that have been described in association with neonatal RVT include catheters insertion, asphyxia, dehydration, shock, sepsis, surgery, trauma, and infants of diabetic mothers. Application of a central venous line plays the most important role.²

In our case, elevated BP and gross hematuria seemed to be the first sign to notify the clinician. In another report, 11 of 12 newborns with hypertension had renovascular disease. BP became normal with therapy and remained normal after discontinuation of treatment. During follow-up at a mean age of 5.75 years, scans remained

abnormal, and 5 patients had unilateral renal atrophy.³ In this case, the follow-up renal echo 15 days after gross hematuria revealed that the kidney size recovered; nevertheless, it is necessary to arrange long-term follow-up because some focal scarring or atrophic kidney has been reported.⁴

The image of renal echo revealed highly echogenic intermedullary radial streak, which is a typical finding in the initial stage of RVT. In most neonatal RVT, the thrombosis commences in the arcuate or interlobular veins when venous stasis occurs.⁵ As a result of the free anastomoses within the renal venous system, thrombosis may spread to the renal cortex or medulla or more often IVC. The hyperechoic radial streaks represent interlobular or interlobar thrombus only in the initial phase of RVT for a few days.⁴ After the acute stage of RVT, there may be a hypoechoic halo around the affected pyramids or decreased echogenicity at the apex of the renal papilla.

Gray-scale ultrasonography is recognized as the modality of choice in neonate with suspected RVT or adrenal hemorrhage.^{4,6,7}

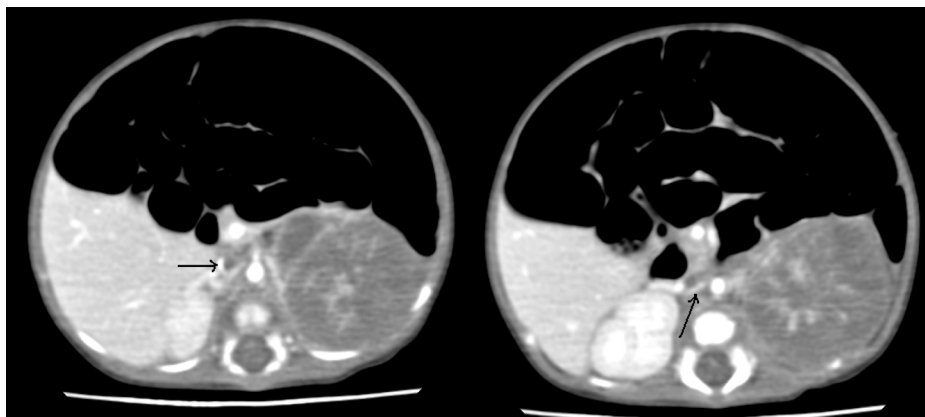


Figure 2. Computed tomographic scan shows filling defect in left renal vein and inferior vena cava. Left kidney is enlarged and hypodensity.

Although abdominal CT scan stands for an alternative tool, it can offer more detailed information about whether thrombosis extend to the hepatic vein or even higher level. CT scan is also helpful in hematuria concerning malignancy. This patient underwent abdominal CT scan 3 days after gross hematuria, and the image finding displayed the enlarged and heterogeneous left kidney, similar to mesoblastic nephroma. Owing to the obvious thrombus within the left renal vein and IVC caught in the horizontal view, the possibility of malignancy was not considered. It has been described that prematurity with left side RVT has an increased risk to be associated with adrenal hemorrhage, resulting from the drainage of the left adrenal vein directly to the left renal vein.⁷

The primary care of RVT is correction of the fluid, electrolytes, and acid-base imbalance. Hypertonic or hyperosmolar agents resulting in hemoconcentration should be avoided. The use of anticoagulation or thrombolytic agents remains controversial, as no eligible research was found based on evidence-based medicine.⁸ In the absence of clinical trials, the therapeutic ranges in newborns are extrapolated from adult studies, and the duration of therapy is uncertain.⁹ Considering the risk of intracranial hemorrhage, we did not choose heparin therapy or thrombolytic agents in this case. It has been demonstrated that kidney atrophy is already present at age 1 year in two thirds of the newborn with RVT.¹ Rapid renal atrophy happened at 2 month later in our case, despite conservative treatment being done. Further aggressive treatment may be considered in such case. Long-term follow-up for evaluation of BP and renal function is crucial for our patient.

Conclusion

The predisposing factors of RVT include sepsis and a central catheter placement through the femoral vein. In addition to clinical

features of gross hematuria, thrombocytopenia, and transient hypertension, ultrasonography and abdominal CT scan offered detailed information for diagnosis. Infants and children with extensive IVC thrombosis are at high risk for persisting venous disease and serious long-term complications. Prospective trials are urgently needed to establish effective treatment strategies and improve long-term prognosis. Central venous catheters, contributing to IVC thrombus in most cases reported here, should be inserted only if necessary. Despite no renal insufficiency at present time, follow-up of this patient is mandatory.

Reference

1. Bokenkamp A, von Kries R, Nowak-Gottl U, et al. Neonatal renal venous thrombosis in Germany between 1992 and 1994: epidemiology, treatment and outcome. *Eur J Pediatr*. 2000;159:44–48.
2. Edstrom CS, Christensen RD. Evaluation and treatment of thrombosis in the neonatal intensive care unit. *Clin Perinatol*. 2000;27:623–641.
3. Adelman RD. Long-term follow-up of neonatal renovascular hypertension. *Pediatr Nephrol*. 1987;1:35.
4. Hibbert J, Howlett DC, Greenwood KL, et al. The ultrasound appearances of neonatal renal vein thrombosis. *Br J Radiol*. 1997;70:1191–1194.
5. Messinger Y, Sheaffer JW, Mrozek J, et al. Renal outcome of neonatal renal venous thrombosis: review of 28 patients and effectiveness of fibrinolytics and heparin in 10 patients. *Pediatrics*. 2006;118:e1478–e1484.
6. Kosch A, Kuwertz-Broking E, Heller C, et al. Renal venous thrombosis in neonates: prothrombotic risk factors and long-term follow-up. *Blood*. 2004;104:1356–1360.
7. Orazi C, Fariello G, Malena S, et al. Renal vein thrombosis and adrenal hemorrhage in the newborn: ultrasound evaluation of 4 cases. *J Clin Ultrasound*. 1993;21:163–169.
8. John CM, Harkensee C. Thrombolytic agents for arterial and venous thromboses in neonates. *Cochrane Database Syst Rev*. 2005;1:CD004342.
9. Lau KK, Stoffman JM, Williams S, et al. Canadian Pediatric Thrombosis and Hemostasis Network. Neonatal renal vein thrombosis: review of the English-language literature between 1992 and 2006. *Pediatrics*. 2007;120:e1278–e1284.