

Morphology of the Leather Defect Light Flecks and Spots

By O. Nafstad¹, H. Wisløff² and H. Grønstøl¹

¹Department of Large Animal Clinical Sciences, Norwegian School of Veterinary Science; P.O.Box 8146 Dep, 0033 Oslo, Norway. ²National Veterinary Institute, P.O.Box 8156 Dep, 0033 Oslo, Norway.

Nafstad O, Wisløff H, Grønstøl H: Morphology of the leather defect light flecks and spots. Acta vet. scand. 2001, 42, 107-112.

– The skin histology and the scanning electron microscope morphology of the hide defect light flecks and spots after tanning were studied in 11 steers infested with biting lice (*Damalinia bovis*). Nine steers from herds free of lice were used as controls. Skin biopsies from 6 of the animals in the lice infested group showed mild to moderate hyperkeratosis and moderate perivascular to diffuse dermatitis with infiltration of mainly mononuclear cells and some eosinophilic granulocytes. The steers were slaughtered at an age of 18 to 23 months. Light flecks and spots occurred on all examined hides from the infested group after tanning. No examined hides from the control group demonstrated similar damage. Both light microscopic examination of sections of tanned hide with light flecks and spots and scanning electron microscopy of the same defects showed superficial grain loss and craters with a irregular fibre base encircled by smooth and intact grain.

The association between louse infestation at an early age and damage of hides following slaughter 6 to 15 months later, suggested that louse infestations lead to a prolonged or lifelong weakening in the dermis. This weakening may cause superficial grain loss during the tanning process.

leather; light flecks and spots; biting lice; morphology.

Introduction

The leather defect, light flecks and spots, is defined as areas of grain loss up to 3 mm in diameter. This damage is closely associated with lice (*Webster & Bugby 1990, Bugby et al. 1990, Nafstad & Grønstøl 2001a, Nafstad & Grønstøl 2001b*). Other authors have demonstrated that similar damage can be caused by other ectoparasite species (*Everett et al. 1977, Rotz et al. 1983, George et al. 1986*). In general, the mechanisms responsible for the light flecks and spots can be attributed to a host response to ectoparasites. Host responses to ectoparasites are recognised as immunologic or allergic in addition to being traumatic, toxic, or directly irritant (*Nelson et al. 1977*). The relative importance of these 4 types of response associated with lice is not clear, but all may be significant.

Both long-nosed sucking lice (*Linognathus vituli* (Linnaeus 1758)) and biting lice (*Damalinia (Bovicola) bovis* (Linnaeus 1758)) cause light flecks and spots, but the latter species seems to be the most important (*Bugby et al. 1990, Nafstad & Grønstøl 2001a*). This observation is surprising considering the biology of the 2 species. The feeding mechanism of *L. vituli* involves a more intimate contact with the host than the feeding mechanism of *D. bovis* and would be expected to cause more damage. As *D. bovis* appear to be the major cause of the leather defect, light flecks and spots, the damage caused by this species was studied. The purpose of this investigation was to study the association between the skin reaction at the age with heaviest *D. bovis* infestations and the morphology of the leather after tanning.

Materials and methods

Animals

Twenty steers from herds that took part in an eradication study (Nafstad & Grønstøl 2001c) were included in the investigation. The herds and selection criteria have been described previously (Nafstad & Grønstøl 2001c). The eleven animals in the louse infested group were selected from three different herds infested with *D. bovis*. The nine animals in the control group were selected from two herds for the pilot group in the eradication study and all controls were born after eradication of lice from the herds and slaughtered before any of the herds had been reinfected. The animals were between 8 and 12 months at age when the biopsies were obtained and between 18 and 23 months at age when slaughtered.

Skin biopsies

Three skin tissue samples were taken from the neck and shoulder region of each animal. The biopsies were collected using a 6 mm biopsy punch under medicamental immobilisation and local anaesthesia. All samples from the louse infested group were taken with a feeding louse in the centre of the biopsy. The biopsies were fixed in 10% buffered formalin, embedded in paraffin, sectioned at 5 µm and stained with haematoxylin and eosin (HE) for light microscopy.

Dyed crust leather examination

Eight of the hides from the louse infested group were collected and identified after tanning. Samples of the hides containing typical light flecks and spots were collected from two of these hides. The hides were tanned in a commercial tannery, chrome tanned, vegetable retanned and evaluated as aniline dyed crust leather. The specimens were taken from the neck and shoulder region of the hides and with a typical light fleck or spot in the grain in the

centre of the sample. Areas of unaffected grain from the same hide were used as control. The leather specimens were rehydrated in 12 hours before they were frozen and sectioned in 50 µm sections. To strip out the chrome tannage, the samples were placed in 1% potassium permanganate solution for one hour, rinsed in distilled water, placed in 2% sodium metabisulphite solution until the sections appeared white. Finally, the sections were rinsed in distilled water before staining.

The stain solutions were prepared after the following procedure: Solution A, consisting of 0.01 g azure A and 0.05 g cresyl violet acetate dissolved in 50 ml distilled water, was mixed with solution B, based on 0.05 M Tris in 45 ml distilled water, to which was added dropwise concentrated hydrochloric acid until pH 7.5 was achieved. To the mixed solution of A and B, distilled water was added until the total volume was 100 ml. The sections were placed in the staining solution for 2 min, rinsed in distilled water to remove excess stain, dehydrated in 70% ethanol and cleared in xylene.

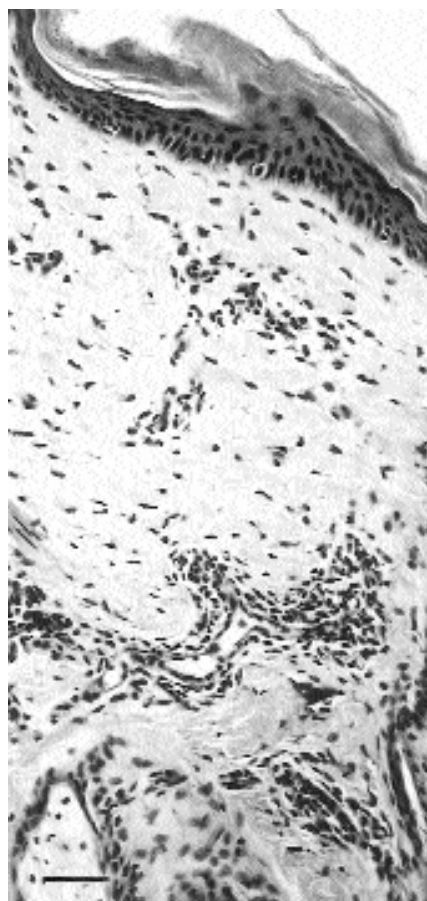
Scanning electron microscopy

For environmental scanning electron microscopy (ESEM) (Philips XL30 ESEM), typical light flecks and spots from the same two hides as used for light microscopy were selected. This scanning electron microscopy method takes advantage of studying specimens without previous fixation or coating. Areas of unaffected grain from the same hides were used as controls.

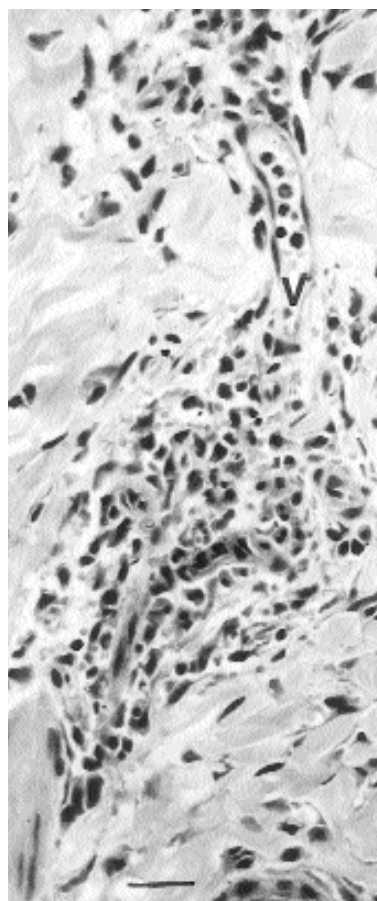
Results

Histology of skin biopsies

Biopsies from six of the eleven animals in the biting lice infested group showed mild to moderate orthokeratotic hyperkeratosis (Fig. 1A). In the dermis, there were varying degrees of perivascular infiltration of mononuclear cells



← Figure 1 A.
Skin from calf infested with biting lice. Moderate orthokeratotic hyperkeratosis and perivascular leucocytic infiltrations. HE. Bar = 50 μ m.



→ Figure 1 B. → Skin from calf infested with biting lice. Aggregating mononuclear cells and eosinophilic granulocytes in and around a blood vessel (V). HE. Bar = 50 μ m.

and eosinophilic granulocytes (Fig. 1B). In the biopsies from the remaining 5 animals in the infested group, only very slight skin changes of the same type were seen.

The skin biopsies from animals in the control group did not show any significant skin changes.

Findings on dyed crust leather samples

All collected hides from the louse infested group had a moderate or severe occurrence of light flecks and spots in the neck and shoulder region, including the 5 hides from animals that

only showed very slight histological changes in the skin biopsies. The light microscopic examination showed superficial grain loss and a irregular fibre base in the affected areas as compared with the intact grain in the surrounding tissues (Fig. 2).

Scanning electron microscopy of dyed crust leather

The scanning electron microscopy examination of a single spot showed grain loss and a superficial crater with a irregular fiber base encircled by smooth and intact grain (Fig. 3A and 3B).

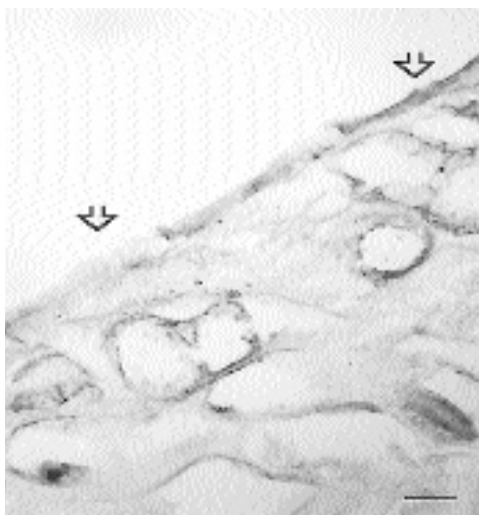


Figure 2. Dye crust leather. Area with superficial grain loss (arrow left) and normal area (arrow right). Transitional zone in between. HE. Bar = 100 μ m.

Discussion

The skin biopsies examined in the present study were taken from the predilection site of *D. bovis* (Chalmers & Charleston 1980 b, DeVaney et al. 1988) and collected during the age period

when the animals probably had the most severe infestations (Chalmers & Charleston 1980 a, Christensson et al. 1994, Nafstad 1998). These biopsies showed varying degrees of hyperkeratosis and perivascular dermatitis dominated by mononuclear cells and eosinophilic granulocytes. Other authors have found similar changes in connection to lice infestations (Rotz et al. 1983, Scott 1988, Webster & Bugby 1990), in addition to other lesions such as epidermal necrosis, exocytosis and epidermal microabscesses (Scott 1988). Webster and Bugby (1990) also found distorted hair follicles with signs of inflammation and degeneration of the follicular wall and enlarged sebaceous and sweat glands. As the reports of Scott (1988) and Webster and Bugby (1990) did not differentiate between reactions caused by different lice species, some of their findings not found in the present study may be due to changes caused by sucking lice species. Short-nosed sucking lice (*Haematopinus eurysternus* Denny 1842) are reported to cause severe histological changes such as stasis, arteriolar vasoconstrictions and perivascular cuffing (Nelson et al. 1977).

The findings on dyed crust leather with small

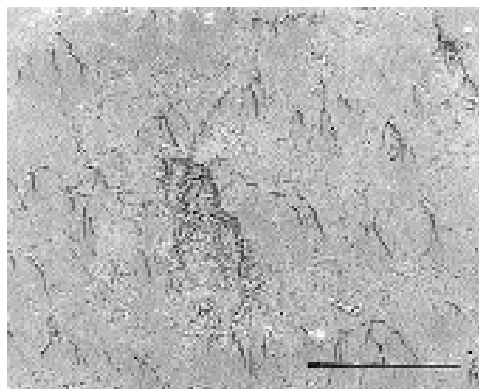


Figure 3 A. Dye crust leather. Scanning electron microscopy. White spot (arrow) surrounded by normal leather. Bar = 1 mm.

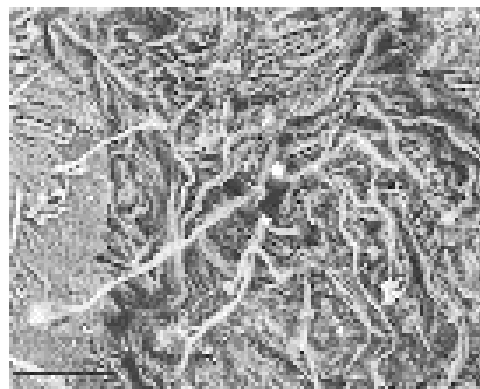


Figure 3 B. Dye crust leather. Higher magnification of the white spot in figure 3 A, showing a dermal crater with roughened surface. Bar = 100 μ m.

areas of superficial grain loss were similar to those described by *Webster & Bugby* (1990). The mechanisms responsible for this damage are not completely understood. *Webster & Bugby* suggested that the infiltration of inflammatory cells and vacuolisation led to possible weakening of the dermis beneath the spots. Their investigation was based upon samples of raw hides taken at the abattoirs, and the findings in these sections represented the situation just before tanning. In the present investigation, the samples of raw hides were obtained months before the time of slaughter, when the lice infestation was probably at its height. Nevertheless, both the findings on raw hides and on dyed crust leather were similar to those found by *Webster & Bugby*. This result suggested that inflammations caused by lice led to partly irreversible changes in the dermis resulting in grain loss when the epidermis was removed during the liming in the tanning process. A similar irreversible effect on leather quality is also known to be induced by infections with *Tricophyllum verrucosum* (*Gudding & Lund* 1995). The age independent prevalence of the leather defect light flecks and spots may also suggest prolonged or irreversible changes in the skin caused by lice (*Nafstad & Grønstøl* 2001a).

Host immune response to cattle lice is poorly understood, and hypersensitivity may be an additional mechanism contributing to damage. Calves and young animals usually have the heaviest lice infestations (*Chalmers & Charleston* 1980 a, *Christensson et al.* 1994, *Nafstad* 1998). Adult animals, however are also usually infested with small populations of lice. It is possible that animals develop hypersensitivity to the lice, and that this very small populations of lice may cause, the damage which occurs in older animals.

Any reaction in the skin that leads to changes in or destruction of dermis, basal membrane or dermal/epidermal junction may give rise to

damage in the grain after tanning. During liming in the tanning process, the hair and epidermis are removed and the dermis and hair follicles remain to form the grain. It should be noted that the tanning process itself can influence the presence or absence of damage and may also explain differences in the findings of *Rotz et al.* (1983), *Webster and Bugby* (1990) and the present study. All three investigations found similar change in the raw hides caused by *D. bovis*, but *Rotz et al.* did not find any significant changes in the leather after tanning. The exact tanning method was not described by *Rotz et al.* The liming in the beginning of the tanning process, when hairs and epidermis are removed, are probably the most important stage that may cause superficial grain loss. The finishing of the leather at the end of the tanning process may partly cover defects which have been caused previously in the processing of the leather.

Acknowledgement

The authors thank A. Bugby in British Leather Confederation for assistance with the stain method for tanned leather, I.T. Solbakk, National Veterinary Institute for staining of the tanned leather samples and P. O. Nergård, Philips Norway for access to and assistance with the ESEM.

References

- Bugby A, Webster RM, Tichener RN*: Light spot and fleck, part 2, animal infestation studies. Laboratory report 186. British Leather Confederation, Northampton, 1990.
- Chalmers K, Charleston WAG*: Cattle lice in New Zealand: observations on prevalence, distribution and seasonal patterns of infestation. N. Z. vet. J. 1980a, 28, 198-200.
- Chalmers K, Charleston WAG*: Cattle lice in New Zealand: observations on the biology and ecology of *Damalinea bovis* and *Linognathus vituli*. N. Z. vet. J. 1980b, 28, 214-216.
- Christensson D, Gyllensvaan C, Skiöldebrand E, Virring S*: Löss på nötkreatur i Sverige - en inventering (Lice in Swedish cattle - a survey). Svensk Vet. -Tidn. 1994, 46, 119-121.
- DeVaney JA, Rowe LD, Craig TM*: Density and distri-

- bution of three species of lice on calves in Central Texas. South-western Entomol. 1988, 13, 125-130.
- Everett AL, Miller RW, Gladney WJ, Hannigan MV: Effects of some important ectoparasites on the grain quality of cattle hide leather. J. Amer. Leath. Chem. Ass. 1977, 72, 6-23.
- Geden CJ, Rutz DA, Bishop DR: Cattle lice (Anoplura, Mallophaga) in New York: Seasonal population changes, effects of housing type on infestations of calves, and sampling efficiency. J. econ. Entomol. 1990, 83, 1435-1438.
- George JE, Wright FC, Guillot FS, Buechler PR: Observations on the possible relationship between psoroptic mange of cattle and white spot damage on leather. J. Amer. Leath. Chem. Ass. 1986, 81, 296-304.
- Gudding R, Lund A: Immunoprophylaxis of bovine dermatophytosis. Can. vet. J. 1995, 36, 302-306.
- Nafstad O: Forekomsten av lus hos norske storfe (Prevalence of lice in Norwegian cattle). Norsk Vet. -T. 1998, 110, 261-265.
- Nafstad O, Grønstøl H: Variation in level of grain defect light flecks and spots on cattle hides. Acta Vet. Scand. 2001a, 42, 91-98.
- Nafstad O, Grønstøl H: The effect of eradication of lice on the occurrence of the grain defect light flecks and spots on cattle hides. Acta Vet. Scand. 2001b, 42, 99-106.
- Nafstad O, Grønstøl H: Eradication of lice in cattle. Acta Vet. Scand. 2001c, 42, 81-89.
- Nelson WA, Bell JF, Clifford CM, Keirans JE: Interactions of ectoparasites and their hosts. J. med. Entomol. 1977, 13, 389-428.
- Rotz A, Mumcuoglu Y, Pohlenz JFL, Suter M, Brosard M, Barth D: Experimentelle Infestation von Rindern mit Ektoparasiten und deren Einfluss auf die Lederqualität (Experimental infestation of cattle with ectoparasites and their effect on leather quality). Zbl. Vet. Med. 1983, 30, 397-407.
- Scott DW: Large animal dermatology. W.B. Saunders Company, Philadelphia, 1988, 235-238.
- Webster RM, Bugby A: Light spot and fleck grain defects of economic importance to the UK leather industry, part 1, identification of causal agent. Laboratory report 184. British Leather Confederation, Northampton, 1990.

Sammendrag

Lærskaden lyse flekker og prikkers morfologi.

Histologiske og morfologiske forandringer knyttet til lærskaden lyse flekker og prikker ble undersøkt hos 11 okser infisert med pelslus (*Damalinea bovis*). Ni okser fra besetninger som var fri for lus ble benyttet som kontroll. Hudbiopsier ble tatt når dyrene var mellom 8 og 12 måneder gamle. Biopsier fra 6 dyr i den luseinfiserte gruppa viste forandringer med mild til moderat hyperkeratose og moderat perivaskulær til diffus dematitt med infiltrasjon av mononukleære celler og eosinofile granulocytter. Biopsier fra 5 dyr i den luseinfiserte gruppa viste bare sparsomme forandringer av samme type. Ingen dyr i kontrollgruppa viste tilsvarende hudforandringer. Dyra ble slaktet mellom 18 og 23 måneders alder. Alle huder fra dyr i den luseinfiserte gruppa hadde skaden lyse flekker og prikker etter garving. Skaden forekom ikke på huder fra kontrollgruppa. Både lysmikroskopi og scanningelektronmikroskopi av prøver fra lær med lyse flekker og prikker viste at skaden framstår som grunne kratre der narven er tapt, omgitt av intakt narv. Sammenhengen mellom luseangrep i ungdyrperioden og skader på læret ved slaktning 6 til 15 måneder seinere, tyder på at luseangrep medfører en langvarig eller livsvarig svekkelse i dermis. Denne svekkelsen fører til tap av narv, og dermed skader i læroverflaten ved garving.

(Received February 1, 2000; accepted September 26, 2000).

Reprints may be obtained from O. Nafstad, Norwegian meat Research Centre. B.O. Box 396, Økern, 0513 Oslo, Norway. E-mail: ola.nafstad@fagkjott.no, tel: +47 22 09 23 42, fax: +47 22 22 00 16.