

Case Report

Recurrent Nerve Palsy due to a Giant Vertebral Artery Aneurysm

Pushpa Raj Puri Michael Anders Petersen

Department of Neurosurgery, Odense Universitetshospital, Odense C, Denmark

Keywords

Vertebrobasilar artery · Dysphagia · Computed tomography angiography · Fiberoptic endoscopic evaluation of swallowing · Recurrent nerve palsy

Abstract

Vertebral artery aneurysms are rare and challenging as they are usually asymptomatic and, therefore, often overlooked. We report the case of a 73-year-old man with a history of progressive dysphagia for 1 year. Computed tomography (CT) and computed tomography with angiography (CTA) of the cerebrum revealed a giant vertebral artery aneurysm compressing the medulla. Fiberoptic endoscopic evaluation of swallowing (FEES) revealed recurrent nerve paralysis. The patient was managed conservatively since the aneurysm was completely thrombosed.

© 2018 The Author(s)
Published by S. Karger AG, Basel

Introduction

Vertebral artery (VA) aneurysms are rare. They constitute 0.5–3% of intracranial aneurysms and 20% of posterior circulation aneurysms [1]. These aneurysms are considered challenging in terms of both diagnosis and treatment. A timely diagnosis of such aneurysms is considered difficult due to either lack of symptoms or presence of unusual symptoms [2]. Furthermore, treatment is challenging due to difficult surgical approach and relative inexperience of most neurosurgeons with these lesions due to their rarity. We present a very unusual case

presentation of a patient who had sudden-onset severe dizziness after intense episodes of coughing followed by diplopia, nausea, and discoordination of motor functions. Computed tomography with angiography (CTA) of the cerebrum showed a giant VA aneurysm compressing the medulla. The patient also had a history of difficulty in swallowing solid food over the last year. Fiberoptic endoscopic evaluation of swallowing (FEES) revealed paralysis of the recurrent laryngeal nerve. To our knowledge, this is the first ever reported case of a recurrent nerve paralysis due to a VA aneurysm.

Case Report

A 73-year-old man with a history of chronic obstructive pulmonary disease (COPD) and hypertension, who had a pacemaker due to 2nd degree AV block, was admitted due to sudden-onset severe dizziness, diplopia, and nausea after an intense episode of coughing. He had difficulty in walking and could not stand without support. There was no history of neck manipulation, trauma, or pain. The patient had a history of difficulty in swallowing solid food for the last year and stated that he had to cough often to make the airway free.

On arrival, the patient was conscious with a Glasgow coma score of 15. He was examined in sitting position due to dizziness. The patient was slightly aphonic. Cranial nerve examinations revealed slight anisocoria right > left, although it was uncertain if he had had this symptom before. There was both vertical and horizontal nystagmus. He had diplopia while looking straight and upwards, and there was improvement in dizziness while lying down with eyes closed. There was paresthesia in the left arm with left-sided positive finger-nose test, positive left-sided dysdiadochokinesis, and deviation of the left arm to the left in the stretched arm test. He had difficulty in standing up from a sitting position. Gait function could not be examined due to dizziness. Computed tomography (CT) of the cerebrum (Fig. 1) showed a calcified process measuring 2.6 × 1.5 cm, ventral to the medulla oblongata, in the junction between the VA and the basilar artery; presumably a large aneurysm. This process seemed to compress the medulla oblongata. Later, the patient was transferred to our hospital for neurosurgical intervention. After arrival, CTA of the cerebrum was performed, which showed a gigantic VA aneurysm on the left side in the V4 segment with complete thrombosis and partial calcification (Fig. 2). Since the aneurysm was found to be completely thrombosed, no further indications for coils or clips were found.

The patient was then transferred to the neurological department for further observation and rehabilitation for his gait dysfunction and diplopia, since no neurosurgical intervention was required and performed. There was improvement in diplopia and dizziness over the following days. The patient continued to have intermittent nausea with constant cough and signs of dysphagia. As mentioned above, the patient was slightly aphonic during admission, and there was gradual weakness in his voice. Chest X-ray examinations were normal, and there was normal auscultation of the lungs. Later, FEES was performed, which showed normal rhino-, oro-, and hypopharynx but complete paralysis of the left-sided recurrent nerve. Few spontaneous swallowing was observed with normal sensation in the epiglottis and hypopharynx. The patient had been admitted 2 months ago due to an exacerbation of COPD, where a chest CT showed no sign of malignancy. So, recurrent nerve palsy due to the aneurysm was confirmed. The patient was later discharged with follow-up after 3 months in the Phoniatic Department and was also referred to the laryngologist. There was slight improvement in motor functions with moderate discoordination of the left arm with imbalance, and the patient is

in rehabilitation now. There was also improvement in his gait and he could walk without support.

Discussion

VA aneurysms are rare and constitute 0.5–3% of intracranial aneurysms and 20% of posterior circulation aneurysms [1]. VA aneurysms include VA-PICA (posterior inferior cerebellar artery) aneurysms, vertebrobasilar junction aneurysms, distal PICA aneurysms, and those located along the distal VA [2]. Distal VA aneurysms and giant aneurysms in this location are rare as in our case [3–5]. VA aneurysms and dissections are uncommon and usually asymptomatic. They rarely become large and thrombosed, causing a mass effect with subsequent medullary compression as well as cranial neuropathy; otherwise, they most commonly present as subarachnoid hemorrhage [6, 7].

The consequent mass effect can result in direct compression of the medulla, ischemia of the brainstem from occlusion of either arterial perforator or veins, as well as hydrocephalus from fourth ventricular outlet obstruction. A wide spectrum of signs and symptoms can be caused by compression on the neuronal tracts and nuclei that lie within the medulla regardless of the etiology, from sudden transient events to persistent deficits and from lower cranial nerve findings to respiratory and autonomic changes. The most severe signs and symptoms can include respiratory failure or anoxic seizures [8]. Due to its rarity and unusual asymptomatic nature, a timely diagnosis of this fatal disease is usually missed. The common symptoms are often overlooked. Central lesions are rarely ruled out until and unless there is presence of neurological deficits.

The torturous VA aneurysm in our case was found on the diagnostic CT of the head and neck which was performed to rule out stroke due to the sudden-onset symptoms of diplopia and dizziness.

Out of the 20 cases of VA compression of the medulla reported in a meta-analysis by Savitz et al. [9], the majority of patients presented with hemiparesis and cranial nerve dysfunction. The most common clinical presentation as reported by Ravi Kumar et al. [2] had been headache, vomiting, and neck pain with hemiplegia. One of the patients had altered sensorium, and another had tinnitus with deafness. Gorton et al. [10] presented a very rare presentation with intractable nausea and vomiting in a patient due to VA aneurysm. None of the patients had dysphagia. Our patient had similar symptoms with sudden-onset dizziness after intense coughing, followed by difficulty in walking due to discoordination and dysphagia. However, he had no signs of hemiplegia/hemiparesis. But none of the cases reported had dysphagia as in our case, where the patient had difficulty in swallowing solid food and had to cough to make the airway free, which is the interesting part. The patient had no apparent hoarseness of voice, though he was unsure if his voice had changed overtime. Because of his prolonged dysphagia, he was referred to the Ear, Nose, and Throat Department for FEES, which revealed total recurrent nerve palsy. Since there were no other underlying causes for this, it was concluded that recurrent nerve palsy was due to the VA aneurysm.

Damage or disruption of the recurrent laryngeal nerve may result from a variety of causes and can occur anywhere along its course. Traditionally, the etiology of recurrent laryngeal nerve paralysis has been divided into thirds: one-third tumor, one-third trauma (surgery), and one-third idiopathic [11]. Yumoto et al. [12] quoted the idiopathic rate of recurrent laryngeal nerve paralysis in the English literature as 1.5–14%, whereas the Japanese published rate was 25.9–41.3%. One group has estimated that as many as 30–50% of patients with paralysis may

be asymptomatic as in our case [13]. Although various causes for recurrent nerve palsy have been reported, compression due to a VA aneurysm has not been reported as a cause before.

The axons of the recurrent laryngeal nerve are myelinated and are grouped within the vagus nerve. As the vagus nerve exits the medulla oblongata, this group is anteriorly situated along the vagus nerve [11]. The medullary compression at this level is the most likely cause in our case causing the recurrent nerve paralysis. Injury to the recurrent laryngeal nerve or vagus nerve anywhere along its course usually results in impaired vocal function. Vascular insults, viruses, bacterial infections, neurotoxic drugs, tumors, and trauma have all been implicated in nerve injury. The exact incidence of recurrent laryngeal nerve paralysis is unknown. Recovery is dependent on the type, extent, and site of nerve lesions [11]. As in our case, since the cause is most likely due to compression, good prognosis is expected, although the patient continues to have dysphagia to date.

Management of VA aneurysms remains controversial. Microsurgical clipping of the aneurysm and endovascular embolization could be an option; however, the safety and effectiveness of these techniques remain unclear [3–5]. The criteria for difficulty and associated risk in the treatment of an aneurysm are various. Whereas anatomic location and the required surgical exploration and exposure contribute to the morbidity of clipping, the angiographic determinants, such as neck size and aneurysm morphology, primarily affect the risk of endovascular therapy [14]. Total thrombosis of the aneurysm can also occur, as in our case, where no intervention is required.

Conclusion

This report demonstrates the importance of neurological examinations and investigations to rule out central lesions in a patient with long-term dysphagia and to timely diagnose fatal diseases, such as VA aneurysm, which are often overlooked due to their rarity and lack of symptoms. Conservative treatment was done in our case since the aneurysm was totally thrombosed.

Statement of Ethics

Informed consent was obtained from the patient for being included in this case report.

Disclosure Statement

The authors declare that they have no conflicts of interest. The corresponding author is the guarantor of submission.

References

- 1 Ausman JI, Sadasivan B. Posterior inferior cerebellar artery vertebral artery aneurysms. In: Apuzzo MLJ, editor. Brain surgery complication avoidance and management. Volume 2. New York: Churchill Livingstone; 1993. p. 1879–94.
- 2 Ravi Kumar CV, Palur RS, Satish S, Rao BR. Vertebral artery aneurysms. *Neurol India*. 2000 Jun;48(2):161–3.
- 3 Day DJ, Giannotta SL. Surgical management of vertebro-PICA aneurysms. In: Schmidek HH, Sweet WH, editors. Operative neurosurgical techniques. Philadelphia: WB Saunders Company; 1995. p. 1103–11.

- 4 Kurokawa Y, Okamura T, Watanabe K. Transcerebellar thrombectomy for the successful clipping of thrombosed giant vertebral artery-posterior inferior cerebellar artery aneurysm: case report. *Surg Neurol.* 1990 Mar;33(3):217–20.
- 5 Madsen JR, Heros RC. Giant peripheral aneurysm of the posterior inferior cerebellar artery treated with excision and end-to-end anastomosis. *Surg Neurol.* 1988 Aug;30(2):140–3.
- 6 Sato K, Ezura M, Takahashi A, Yoshimoto T. Fusiform aneurysm of the vertebral artery presenting hemifacial spasm treated by intravascular embolization: case report. *Surg Neurol.* 2001 Jul;56(1):52–5.
- 7 Shiraishi S, Fujimura M, Kon H, Motohashi O, Kameyama M, Ishii K, et al. Thrombosed vertebral artery aneurysm presenting with hemorrhage and bulbar compression: report of two cases. *Clin Neurol Neurosurg.* 2005 Feb;107(2):123–7.
- 8 Treacy A, Redmond M, Lynch B, Ryan S, Farrell M, Devaney D. Schwannosis induced medullary compression in VACTERL syndrome. *Clin Neuropathol.* 2009 Sep-Oct;28(5):384–6.
- 9 Savitz SI, Ronthal M, Caplan LR. Vertebral artery compression of the medulla. *Arch Neurol.* 2006 Feb;63(2):234–41.
- 10 Gorton L, Ashour AM, Lebovitz J, Cosola Di A, Abdulrauf SI. Intractable vomiting caused by vertebral artery compressing the medulla: A case report. *J Craniovertebr Junction Spine.* 2015 Apr-Jun;6(2):89–91.
- 11 Myssiorek D. Recurrent laryngeal nerve paralysis: anatomy and etiology. *Otolaryngol Clin North Am.* 2004 Feb;37(1):25–44.
- 12 Yumoto E, Minoda R, Hyodo M, Yamagata T. Causes of recurrent laryngeal nerve paralysis. *Auris Nasus Larynx.* 2002 Jan;29(1):41–5.
- 13 Collazo-Clavell ML, Gharib H, Maragos NE. Relationship between vocal cord paralysis and benign thyroid disease. *Head Neck.* 1995 Jan-Feb;17(1):24–30.
- 14 Nichols DA, Brown RD Jr, Thielen KR, Meyer FB, Atkinson JL, Piepgras DG. Endovascular treatment of ruptured posterior circulation aneurysms using electrolytically detachable coils. *J Neurosurg.* 1997 Sep;87(3):374–80.

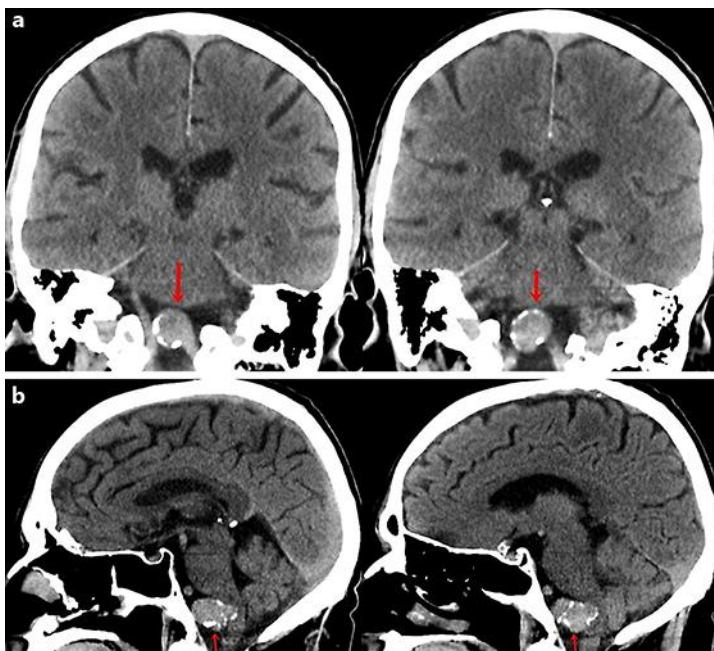


Fig. 1. Computed tomography of the head without contrast showing a giant vertebral artery aneurysm (red arrow). **a** Coronal view. **b** Sagittal view. In the sagittal view, the giant aneurysm is seen compressing the medulla oblongata ventrally measuring 2.6×1.5 cm.

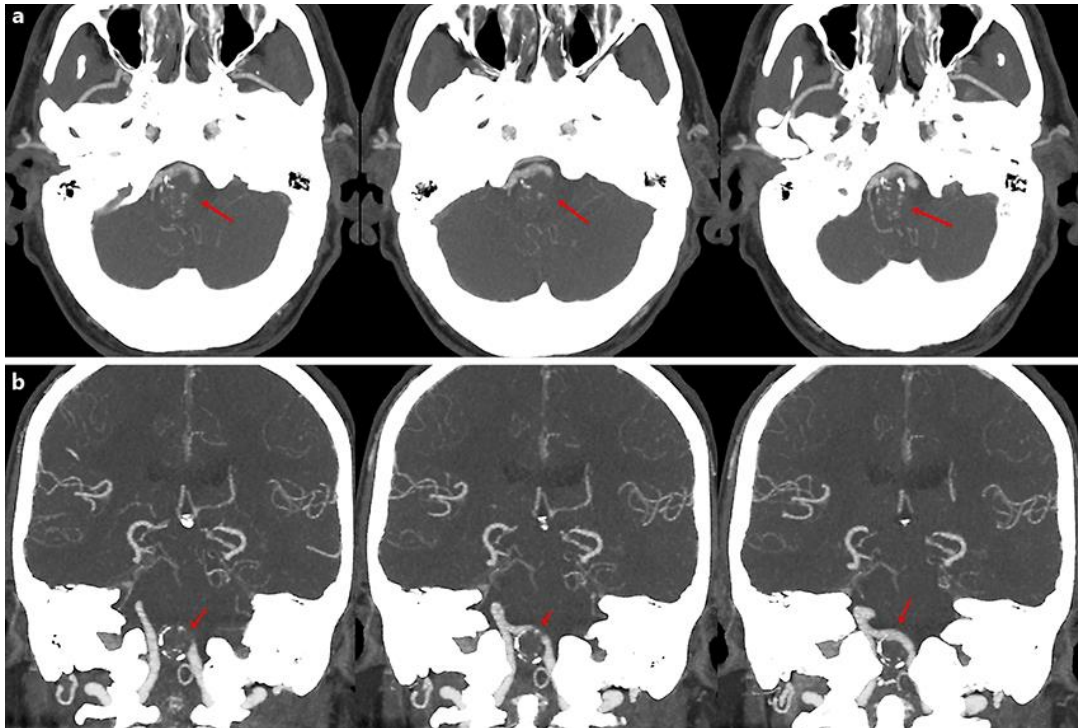


Fig. 2. Computed tomography with angiography demonstrating a completely thrombosed gigantic aneurysm with partial calcification (red arrow) in the left V4 segment of the vertebral arteries. **a** Axial view. **b** Sagittal view. The right vertebral artery is unaffected with excellent fill of the basilar artery.