

# Bilateral occlusive retinal vasculitis associated with primary sclerosing cholangitis

Abdus S. Ansari, Catrin Bertalot, Divya Mathews, John P. Mathews<sup>1</sup>

<b>Access this article online</b>
Quick Response Code:

<b>Website:</b> www.saudijophthalmol.org
<b>DOI:</b> 10.4103/1319-4534.322598

## Abstract:

We present the case of a 46-year-old man who presented with bilateral panuveitis and occlusive retinal vasculitis 6 months after being acutely admitted with abnormal liver function and diagnosed with primary sclerosing cholangitis (PSC). Initial investigations by the medical and ophthalmic departments including all autoimmune investigations were within normal parameters. Of particular interest was the high likelihood of inadvertent androgenic-anabolic steroid self-suppression of disease. As a lifelong bodybuilder, the patient had been taking oral and intramuscular steroids for years. He became symptomatic upon cessation of these recreational medications. There remains a significant paucity of information describing the relationship between uveitis and PSC. Given the poorly understood aetiology of this rare cholestatic disease, we review the current literature and highlight the diagnostic and therapeutic challenges for such a patient. PSC may predispose patients to an occlusive panuveitis with androgenic-anabolic steroids suppressing ocular autoimmune disease.

## Keywords:

Primary sclerosing cholangitis, uveitis, vasculitis

## INTRODUCTION

Uveitis is an autoimmune disease affecting the uveal component of the eye. Uveitis can be purely idiopathic or a co-manifestation of various autoimmune/infective conditions. It is often classified by location of inflammatory response, however, given its prevalence, it can often be overlooked while managing the extraocular manifestations of autoimmune disease. Recurrent and posterior forms of disease may lead to permanent visual impairment. Underlying autoimmune conditions may complicate both presentation and disease course, lending to the complexities of treatment and necessitating a multidisciplinary approach.<sup>[1]</sup> With a mean age of onset noted to be <40 years and a prevalence of 38 cases/100,000, uveitis is a rare condition that remains poorly understood. Recent efforts have focused on identifying potential risk factors and associated conditions, and a more recent example includes primary sclerosing cholangitis (PSC).<sup>[2]</sup> While the potential relationship between PSC and uveitis has been previously hypothesized, the current evidence dedicated to

establishing this potential association is limited. Paucities in the current literature may be driven by our limited understanding of the etiology of this rare cholestatic liver condition. Current studies highlight the elevation of hypergammaglobulinemia, and autoantibodies observed in this condition, suggesting an immune mediated pathology.<sup>[3]</sup> We present the first reported case of bilateral panuveitis with occlusive vasculitis in a patient after being diagnosed with PSC.

## CASE REPORT

A 46-year-old Caucasian male patient was referred to the acute eye casualty department with a 10-day history of bilateral floaters and blurring of vision. Although ophthalmic history was unremarkable, previous medical history identified an acute episode of jaundice 6 months before presentation. Medical investigations at this point identified a raised alkaline phosphatase (>900), and magnetic resonance cholangiopancreatography confirmed a diagnosis of PSC. There was no history of inflammatory bowel disease (IBD) and his autoantibodies and hepatitis screen were all noted to be normal. He had previously been of good

This is an open access journal, and articles are distributed under the terms of the Creative Commons Attribution-NonCommercial-ShareAlike 4.0 License, which allows others to remix, tweak, and build upon the work non-commercially, as long as appropriate credit is given and the new creations are licensed under the identical terms.

For reprints contact: WKHLRPMedknow\_reprints@wolterskluwer.com

**How to cite this article:** Ansari AS, Bertalot C, Mathews D, Mathews JP. Bilateral occlusive retinal vasculitis associated with primary sclerosing cholangitis. Saudi J Ophthalmol 2020;34:310-2.

Department of Ophthalmology,  
Stanley Eye Unit, Betsi  
Cadwaladr University  
Health Board United  
Kingdom, <sup>1</sup>Department of  
Ophthalmology, Stanley  
Eye Unit, Abergele Hospital,  
Abergele, Wales, UK

**Address for correspondence:**  
Mr. John P. Mathews,  
Stanley Eye Unit, Abergele  
Hospital, Llanfair Road,  
Abergele, Conwy LL22 8DP,  
Wales, UK.  
E-mail: john.mathews@wales.  
nhs.uk

Submitted: 31-May-2019

Revised: 27-Oct-2019

Accepted: 05-Dec-2019

Published: 29-Jul-2021

health and was a keen amateur bodybuilder. However, due to family commitments, he had given up this hobby 9 months preceding his attendance. He was local to the area, with no history of travel abroad. He smoked 5 cigarettes a day, and there was no history of alcohol intake. He was not on any medication at the time of presentation. His mother suffered from inflammatory arthropathy and his sister from multiple sclerosis.

On examination, the unaided logarithm of the minimum angle of resolution (logMAR) visual acuity (VA) in the right eye (RE) was 0.38 and the left eye (LE) 0.30. He had a bilateral nongranulomatous uveitis, extensive posterior synechiae, and normal intraocular pressures. There was a limited fundal view with vitreous cells noted in each eye. This was indeed more marked and active in the RE with an associated hyperemic optic disc. The LE revealed occlusive retinal vasculitis of the superior retinal vasculature [Figures 1a and 1b]. This subsequently progressed to involve the right retinal vasculature upon the patient's next clinic attendance 5 days later, however, due to significant anterior chamber inflammation, fundal photos were not possible for this eye. There was no macular involvement in either eye, as was confirmed by optical coherence tomography. Systemic examination revealed possible early clubbing but was otherwise unremarkable.

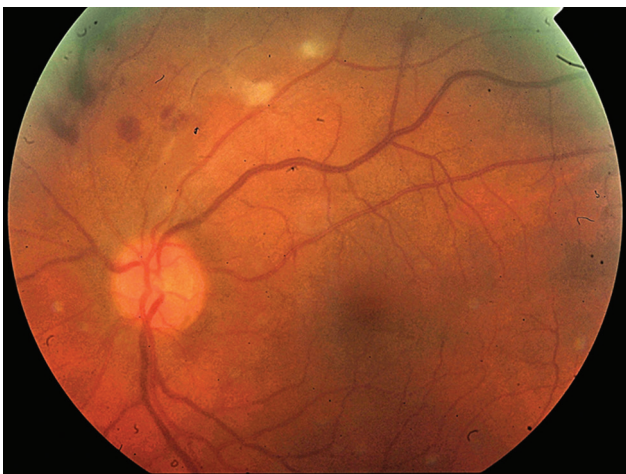The patient was commenced on hourly topical steroids with cycloplegic agents in each eye pending urgent investigations. The results of these showed a normal erythrocyte sedimentation rate and C-reactive protein, negative septic screen, and normal chest X-ray. There was mild thrombophilia, but this was much reduced from his inpatient tests, 6 months previously. Blood tests including angiotensin-converting enzyme, antineutrophil cytoplasmic antibodies, antinuclear antibodies, HIV, syphilis screen, herpes simplex virus, herpes zoster virus, immunoglobulin G4, and alpha-fetoprotein were all noted to be negative or within normal parameters. He was subsequently commenced on oral prednisolone 60 mg a day and omeprazole 20 mg a day and referred for a gastroenterology, rheumatology, and tertiary uveitis center review with a planned fundus fluorescein angiogram and review in our own department.

At 1-week follow-up, the anterior chamber in each eye was quiet, with some of the posterior synechiae showing release and improved pupillary dilation. The patient unfortunately did not attend the tertiary uveitis appointment due to the distance he needed to travel. Unaided logMAR VA improved to  $-0.10$  RE and  $-0.14$  LE. The vitritis and vasculitis continued to settle with a reducing regime of oral steroids. With time, topical medication was discontinued and the posterior segment was stabilized with residual vascular occlusion evident in the left superior retina (ghost vessels). With the last recorded vision 6 months after initial attendance, of logMAR  $-0.10$  in the RE and  $-0.14$  in the LE, neovascularization at this point had not been seen.

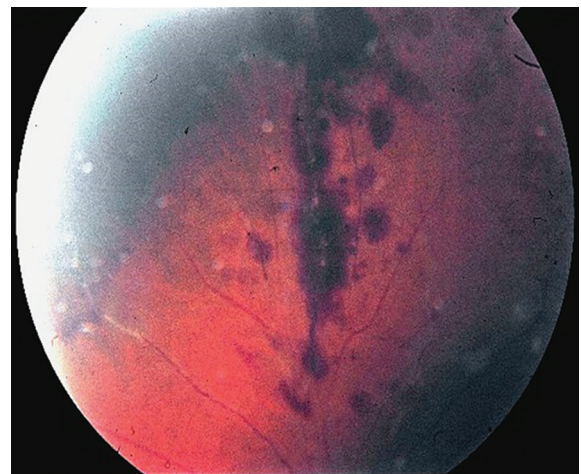
## DISCUSSION

PSC is characterized by progressive inflammation and fibrosis of the intrahepatic bile ducts leading to cholestasis and potentially end-stage liver failure with a high risk of cholangiocarcinoma.<sup>[4]</sup> The etiology is believed to be autoimmune and is most frequently seen as an extraintestinal manifestation of IBD.<sup>[5]</sup> At least 75% of PSC patients have coexisting ulcerative colitis. Another 5%–10% of PSC patients have Crohn's disease.<sup>[6,7]</sup> Approximately one-third of these patients will demonstrate symptomatic PSC before a diagnosis of IBD. While our patient could theoretically develop IBD in the future, it is unusual to have no clinical evidence of IBD on investigation.<sup>[7]</sup> Ocular features include episcleritis, scleromalacia, corneal ulcers, uveitis/iritis, and retinal vascular disease.<sup>[8,9]</sup> Our patient had both uveitis and retinal vascular disease.

To our knowledge, the association between PSC and uveitis has been reported once previously. In this case series of six patients, a postulated relationship between uveitis and PSC is demonstrated. All identified patients in their cohort had a history of bowel and/or musculoskeletal disease. They identified only one case of unilateral panuveitis involving the retina in a male patient aged 51 years.<sup>[2]</sup> Of these cases, four demonstrate unilateral inflammation. Five cases report an



**Figure 1a:** Left eye fundal images showing retinal hemorrhages and cotton wool spots along the superior temporal arcade



**Figure 1b:** Left eye fundal image showing hemorrhages and cotton wool spots of the superior retinal vasculature extending into the periphery

insidious onset of symptoms, yet all were identified to have a persistent duration. A temporal association was also theorized, as the early stages of PSC are often asymptomatic; this could potentially explain the delay in diagnosis relative to uveitis. Extrahepatic manifestations associated with autoimmune liver disease (ALD) have reported individual associations to PSC and uveitis, respectively, with the most common ocular findings including that of cataract and dry eyes.<sup>[10,11]</sup> ALD, however, shows a marked preponderance of females contrasting to PSC, and it is also commonly seen in those with IBD.<sup>[3]</sup>

It was interesting that the patient had been a bodybuilder and that his onset of systemic illness had coincided with abandoning this hobby. On questioning, he had been using high doses of intramuscular and oral anabolic steroids for many years and only experienced symptoms after ceasing this activity. This would raise the possibility of inadvertent androgenic-anabolic steroid (AAS) self-suppression of disease with reactivation upon cessation of activity. Reports have highlighted how this alteration in androgens and expression of functional androgen receptors can affect immune cells and have stressed the alteration of immune cell response can alter immune response and consequently progression and incidence of autoimmune disease.<sup>[12,13]</sup>

The use of AAS among bodybuilders and professional athletes became particularly common in the mid-1980s with the aim of these fitness enthusiasts to increase muscle mass and physical appearance. More recently, its use has spread to casual fitness enthusiasts given the ease of procurement with online distribution becoming considerably more prevalent. Despite its popularity, the long-term effects of abuse remain equivocal. Common side effects include that of gynecomastia, acne, testicular atrophy, and even loss of libido. Rarer complications include hepatic dysfunction, reduction of thyroid hormone production, infertility, cardiovascular complications, and psychogenic and immunomodulatory effects.<sup>[14]</sup>

The mechanism of action of AAS remains very similar to other forms of steroid hormones. It binds to intracellular androgen receptors in target tissues, thus forming an androgen receptor complex within the cell nucleus.<sup>[15]</sup> Ultimately, this leads to the production of proteins causing the lasting physiological effects, known as genomic effects. The authors have also postulated nongenomic effects including the direct alteration of physiochemical properties of the cell membrane.<sup>[15]</sup>

A recent review of AAS highlighted that supraphysiological doses of AAS with an intact steroid nucleus are indeed immunosuppressive.<sup>[15]</sup> They have the ability to reduce immune cell number and function. In particular, they adversely affect T-lymphocyte differentiation and proliferation and antibody production, produce certain cytokines, and thus alter immune reaction.<sup>[16]</sup> These effects can be overwhelming and long lasting, however, this is likely dependent on the dosing regimen, type/combination/form of AAS, and the duration of use. Finally, given the mechanism of action, it would be pertinent to highlight that the use of glucocorticoids in the suppression of autoimmune conditions including PSC has been reported.<sup>[17]</sup>

To date, there remains a significant lack of information describing the relationship between uveitis and PSC. In addition, no reports of AAS-associated immunosuppression of ocular disease have been made. Further efforts must be made in both evaluating the temporal relationship between these diseases and the ocular side effects of AAS, given the increasing prevalence of use and the possibility of inadvertent suppression of disease. PSC may theoretically predispose patients to an occlusive panuveitis with AAS suppressing ocular autoimmune disease.

### Acknowledgments

We kindly thank the patient who generously consented for their medical history and clinical experience to be written up and repurposed for academic use.

### Financial support and sponsorship

Nil.

### Conflicts of interest

There are no conflicts of interest.

### REFERENCES

1. Barisani-Asenbauer T, Maca SM, Mejdoubi L, Emminger W, Machold K, Auer H. Uveitis- a rare disease often associated with systemic diseases and infections-a systematic review of 2619 patients. *Orphanet J Rare Dis* 2012;7:57.
2. Hoang LT, Lim LL, Walton RC, Goldstein DA, Chalmers B, Rosenbaum JT. Primary sclerosing cholangitis and uveitis: A case series. *Am J Ophthalmol* 2007;143:534-6.
3. Saich R, Chapman R. Primary sclerosing cholangitis, autoimmune hepatitis and overlap syndromes in inflammatory bowel disease. *World J Gastroenterol* 2008;14:331-7.
4. Lazaridis KN, Gores GJ. Primary sclerosing cholangitis and cholangiocarcinoma. *Semin Liver Dis* 2006;26:42-51.
5. Kujundzić M. The role of biologic therapy in the treatment of extraintestinal manifestations and complications of inflammatory bowel disease. *Acta Med Croatica* 2013;67:195-201.
6. Vavricka SR, Schoepfer A, Scharl M, Lakatos PL, Navarini A, Rogler G. Extraintestinal manifestations of inflammatory bowel disease. *Inflamm Bowel Dis* 2015;21:1982-92.
7. Broomé U, Bergquist A. Primary sclerosing cholangitis, inflammatory bowel disease, and colon cancer. *Semin Liver Dis* 2006;26:31-41.
8. Levine JS, Burakoff R. Extraintestinal manifestations of inflammatory bowel disease. *Gastroenterol Hepatol (N Y)* 2011;7:235-41.
9. Mady R, Grover W, Butrus S. Ocular complications of inflammatory bowel disease. *ScientificWorldJournal* 2015;2015:438402.
10. Wong GW, Heneghan MA. Association of extrahepatic manifestations with autoimmune hepatitis. *Dig Dis* 2015;33 Suppl 2:25-35.
11. Citirik M, Berker N, Kacar S, Kekilli M. Ocular findings in patients with autoimmune liver disease. *Ocul Immunol Inflamm* 2012;20:438-42.
12. Gubbels Bupp MR, Jorgensen TN. Androgen-induced immunosuppression. *Front Immunol* 2018;9:794.
13. Hughes TK, Fulep E, Juelich T, Smith EM, Stanton GJ. Modulation of immune responses by anabolic androgenic steroids. *Int J Immunopharmacol* 1995;17:857-63.
14. Unai S, Miessau J, Karbowski P, Baram M, Cavarocchi NC, Hirose H. Caution for anabolic androgenic steroid use: A case report of multiple organ dysfunction syndrome. *Respir Care* 2013;58:e159-63.
15. Marshall-Gradisnik S, Green R, Brenu E, Weatherby R. Anabolic androgenic steroids effects on the immune system: A review. *Open Life Sci* 2009;4:19-33.
16. Brenu EW, McNaughton L, Marshall-Gradisnik SM. Is there a potential immune dysfunction with anabolic androgenic steroid use? A review. *Mini Rev Med Chem* 2011;11:438-45.
17. Goode EC, Rushbrook SM. A review of the medical treatment of primary sclerosing cholangitis in the 21<sup>st</sup> century. *Ther Adv Chronic Dis* 2016;7:68-85.