



Open Access

LETTER TO THE EDITOR

Male Health

Unusual presentation of urachal adenocarcinoma with genitourinary cutaneous metastasis

Yin-Hui Yang^{1,2,*}, Yan Zhu^{3,*}, Xiang-Wei Zhu¹, Hong-Juan Tang¹, Jian-Guo Hou², Wan-Hai Xu¹

Asian Journal of Andrology (2015) 17, 339–340; doi: 10.4103/1008-682X.139257; published online: 26 September 2014

Dear Editor,

The urachus, which is a vestigial structure between the dome of the bladder and umbilicus, usually, retracts from the bladder before birth. However, the urachal remnant was continuous with the bladder cavity even in adults in 32% of bladder in one autopsy study.¹ For this reason, tumors may develop from the remnants, most of which are well-differentiated mucinous adenocarcinomas, which is a rare form of vesical malignancy, accounting for <1% of all bladder cancers. Although local spread to the peritoneum is common at presentation, distant metastases without local recurrence are rarely detected following surgical excision of clinically localized disease. To the best of our knowledge, distant metastases have been reported in a number of organs, including the lung, omentum, liver, bone, brain, ovarian, and maxilla.^{1–4} Now we report the first case of genitourinary cutaneous metastasis resulting from urachal adenocarcinoma.

We report a urachal adenocarcinoma metastatic to genitourinary skin in a 53-year-old Chinese man. In May 2008, after admission to Changhai Hospital in Shanghai, imageological examination revealed 2.0 by 1.5 cm mass extending from the vertex of the urinary bladder to the median umbilical ligament, and there was no evidence of metastasis on B-ultrasonic wave and computed tomography. Then a partial cystectomy with urachal remnant resection was performed. Surgical findings indicated no invasion of surrounding bladder tissues and no local extension into the abdominal wall, peritoneum or any viscera other than the bladder. Pathologic examination identified urachal adenocarcinoma that limited to the shallow muscle layer and showed morphologically enteric type differentiation (**Figure 1a**), mucinous adenocarcinoma (**Figure 1b**) and ring cell carcinoma (**Figure 1c**).

Two months after surgery, for this complaint a 2 cm diameter mass originated from penile and scrotum was made nothing of. And 5 years later, he was diagnosed with a 10 cm as the longest meridian erysipeloid-like mass on physical examination (**Figure 2a**). The total resection of penis, scrotum and groin skin, was performed to confirm the origin of the tumor, besides radical total cystectomy and urinary diversion. And postoperative incision was shown as

Figure 2b. Histopathological diagnosis of all resected tumors showed mucinous adenocarcinoma that was morphologically similar to the patient's original tumor (**Figure 1d**). Immunohistochemical studies using the following antibodies (monoclonal; DAKO, Glostrup, Denmark) demonstrated that the neoplastic epithelial cells to be positive for CAM5.2, CDX2, CA199 (**Figure 3a–3c**) and negative for p63 (**Figure 3d**), p53, p16 (data not shown). Currently, the patient (because of poor physical condition) without chemotherapy or radiotherapy remains disease free after 7 months of follow-up.

Primary urachal adenocarcinoma is extremely rare, accounting for <1% of all malignant bladder cancers. Approximately, 20%–30% of these are urachal in origin.⁵ They may show a variety of histopathological glandular patterns but are most commonly the mucinous type. Age at diagnosis is in the late fifties with a little over 1:1 male: female ratio.⁴ It may be asymptomatic leading to the diagnosis, but can present with hematuria, pelvic pain, pelvic neoplasm, and urinary infection.⁶ Unfortunately, no absolute consensus exists regarding diagnostic criteria now. Local recurrence is frequent after surgery. Distant metastases usually occur late in the natural history of the disease. And so it carries a dismal prognosis especially for carcinoma cell metastasis to the skin.⁷ Cutaneous involvement due to urological malignancy is uncommon, the incidence of cutaneous metastasis from bladder malignancies ranges from 0.84% to 3.60%.⁸ And this patient is the first to present with genitourinary cutaneous metastasis from urachal adenocarcinoma. They represent a significant challenge because of no consensus on how to manage those cases.

Unlike other cancers, there is currently no standard adjuvant or metastatic chemotherapy or radiotherapy regimen for the treatment of urachal carcinoma.⁹ Undoubtedly, surgical approach represents the mainstay of treatment for urachal carcinoma, especially for recurrent or metastatic urachal cancer.¹⁰ And recently, complete laparoscopic removal of complicated urachal adenocarcinoma seems to be a safe, effective approach. However, the question as to whether partial or radical cystectomy is suitable for localised disease is difficult to answer since urachal tumors are rare.

In general, cutaneous metastases tend to most frequently occur in the vicinity of the primary cancer. Whereas for genitourinary cutaneous metastasis resulting from urachal adenocarcinoma, direct invasion by hematogenous metastasis may be thought to be one of the most important pathways. Currently, because of the limitation of the number of total patients with skin metastasis, there were lots of questions to answer, such as the approach and timing of surgery, the

¹Department of Urology, The Fourth Hospital of Harbin Medical University, Harbin, China; ²Department of Urology, ³Department of Pathology, Changhai Hospital, Second Military Medical University, Shanghai, China.

*The authors contributed equally to this work.

Correspondence: Prof. WH Xu (xuwanghai@163.com)

Received: 21 April 2014; Accepted: 27 June 2014

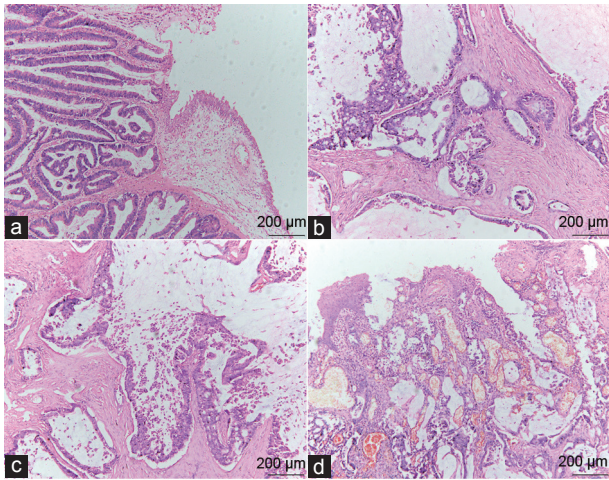


Figure 1: Histopathology showed the original and metastatic urachal tumor. (a) The overlying urothelium was involved by enteric adenocarcinoma. (b) Well-differentiated mucinous adenocarcinoma was seen. (c) There were signet ring cells floating within the mucinous material. (d) Metastatic urachal adenocarcinoma destroyed the skin of scrotum (H and E) (scale bars = 200 μ m).

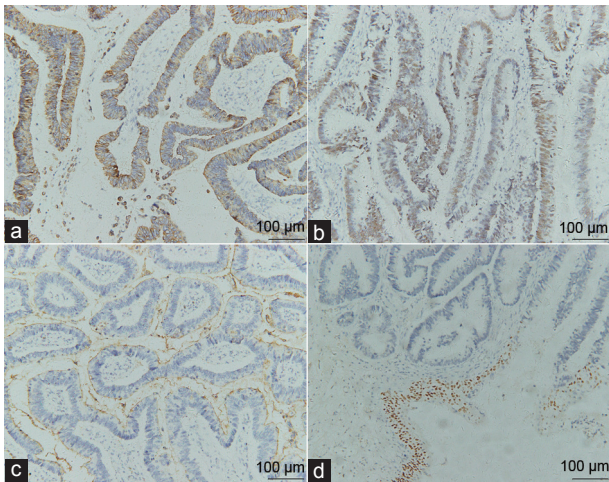


Figure 3: Immunohistochemical staining patterns in urachal carcinoma: (a) Strong, diffuse cytoplasmic staining for CAM5.2. (b) Strong, diffuse nuclear staining for CDX2. (c) Diffuse membranous staining for CA199. (d) The neoplastic epithelial cells stain negative for p63, whereas urothelium stain positive (scale bars = 100 μ m).

choice of radiotherapy or chemotherapy regimens and the underlying mechanism of cutaneous metastasis.

In summary, our case experience and literature review suggest that the early finding of the urachal mass and complete resection, besides, combined modalities treatment are required for patients

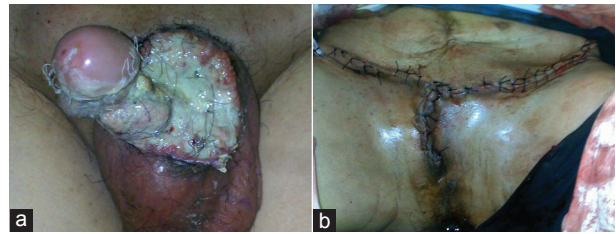


Figure 2: Traces of the patient for pre- and post-surgery (a) ulcerative lesions located on the prepuce and scrotum; (b) postoperative changes of perineum.

with genitourinary cutaneous metastasis resulting from urachal adenocarcinoma.

AUTHOR CONTRIBUTIONS

YHY was responsible for the acquisition of data, drafting and editing the manuscript; XWZ, JGH, HJT were involved in clinical management of the patient and interpretation of data; YZ was responsible for the interpretation of pathology; WHX was the supervisor of clinical management of the patient and interpretation of data.

COMPETING INTERESTS

The authors declare that they have no competing interests.

ACKNOWLEDGMENTS

This work was supported by the Youth fund of Heilongjiang Province of China (No. QC2014C111) and the National Natural Science Foundation of China (No. 81270022).

REFERENCES

- Ohira S, Shiohara S, Itoh K, Ashida T, Fukushima M, *et al.* Urachal adenocarcinoma metastatic to the ovaries: case report and literature review. *Int J Gynecol Pathol* 2003; 22: 189–93.
- Bastian HL, Jensen EK, Jylling AM. Urachal carcinoma with metastasis to the maxilla: the first reported case. *J Oral Pathol Med* 2001; 30: 378–80.
- Gopalan A, Sharp DS, Fine SW, Tickoo SK, Herr HW, *et al.* Urachal carcinoma: a clinicopathologic analysis of 24 cases with outcome correlation. *Am J Surg Pathol* 2009; 33: 659–68.
- Piégay F, Mornex JF. Combined modalities treatment of pulmonary metastasis from an urachal adenocarcinoma. *Rare Tumors* 2013; 5: e32.
- Thomas DG, Ward AM, Williams JL. A study of 52 cases of adenocarcinoma of the bladder. *Br J Urol* 1971; 43: 4–15.
- Singh I, Prasad R. Primary urachal mucinous adenocarcinoma of the urinary bladder. *J Clin Diagn Res* 2013; 7: 911–3.
- Mueller TJ, Wu H, Greenberg RE, Hudes G, Topham N, *et al.* Cutaneous metastases from genitourinary malignancies. *Urology* 2004; 63: 1021–6.
- Block CA, Dahmouh L, Konety BR. Cutaneous metastases from transitional cell carcinoma of the bladder. *Urology* 2006; 67: 846.e15–7.
- Elser C, Sweet J, Cheran SK, Haider MA, Jewett M, *et al.* A case of metastatic urachal adenocarcinoma treated with several different chemotherapeutic regimens. *Can Urol Assoc J* 2012; 6: E27–31.
- El-Ghobashy A, Ohadike C, Wilkinson N, Lane G, Campbell JD. Recurrent urachal mucinous adenocarcinoma presenting as bilateral ovarian tumors on cesarean delivery. *Int J Gynecol Cancer* 2009; 19: 1539–41.