



---

## Case Report

# The modified bilobed flap for reconstructing sacral decubitus ulcers

Xiangong Jiao<sup>1,#</sup>, Chunxiao Cui<sup>2,3,4,#</sup>, Sally Kiu-Huen Ng<sup>5,#</sup>,  
Zhangjia Jiang<sup>1,\*</sup>, Chihui Tu<sup>1</sup>, Jiemin Zhou<sup>1</sup>, Xiandong Lu<sup>1</sup>,  
Xianwen Ouyang<sup>1</sup>, Tong Luo<sup>1</sup>, Ke Li<sup>6,\*</sup> and Yixin Zhang<sup>6,\*</sup>

<sup>1</sup>Plastic, Reconstructive and Burn Centre, Liuyang People's Hospital, 49 Renmin Middle Road, Liuyang 410300, Hunan, China, <sup>2</sup>ENT Institute, Eye & ENT Hospital, Fudan University, 83 Fenyang Road, Shanghai 200011, China, <sup>3</sup>Department of Facial Plastic and Reconstructive Surgery, Eye & ENT Hospital, Fudan University, 83 Fenyang Road, Shanghai 200011, China, <sup>4</sup>NHC Key Laboratory of Hearing Medicine, Fudan University, 83 Fenyang Road, Shanghai 200011, China, <sup>5</sup>Department of Plastic Surgery, Austin Hospital, 145 Studley Road, Melbourne 3084, Australia and <sup>6</sup>Department of Plastic and Reconstructive Surgery, Shanghai Ninth People's Hospital, Shanghai JiaoTong University School of Medicine, 639 Zhi Zao Ju Road, Shanghai 200011, China

\*Correspondence. Zhangjia Jiang, Email: jz0012035@163.com; Ke Li, Email: 18817821624@163.com; Yixin Zhang, Email: zhangyixin6688@hotmail.com

#These authors contributed equally to this work

Received 25 October 2019; Revised 12 December 2019; Editorial decision 17 February 2020

## Abstract

**Background:** Sacral pressure ulcers are associated with high morbidity and, in some cases, result in mortality from severe sepsis. Local flaps are frequently used for reconstruction of stage III and IV pressure ulcers. An ideal flap should be simple to design, have a reliable vascular supply and minimal donor site morbidity. Our study evaluates the use of a bilobed flap based on the superficial branch of the superior gluteal artery or the posterior branch of the fourth lumbar artery to reconstruct the sacral pressure ulcer.

**Case presentation:** We performed a retrospective analysis of paraplegic patients with sacral pressure ulcers treated with our bilobed flaps from January 2015 to December 2019. A description of our management, operative protocol, outcome and complications is outlined. Seven paraplegic patients (6 male, 1 female; average age 53.1 years) with sacral pressure ulcers were treated with our bilobed flap based on the superficial branch of the superior gluteal artery or the posterior branch of the fourth lumbar artery. The average size of the pressure ulcers was 7 × 5 cm (range 6.2 × 4.5 cm to 11 × 10 cm). All 7 flaps survived. The patients were followed up for 12 months without significant complications, such as flap necrosis or recurrence.

**Conclusions:** The superficial branch of the superior gluteal artery or the posterior branch of the fourth lumbar artery reliably supplies the bilobed flap. The superior cluneal nerve can be included in the design. The technique is simple and reliable. It should be included in the reconstructive algorithm for the management of sacral pressure ulcers.

**Key words:** Sacrococcygeal, Pressure sore, Superior cluneal nerve, Bilobed flap, Superior gluteal artery, Fourth lumbar artery

---

## Background

Sacral pressure ulcers are frequently seen in paraplegic patients. For stage I and II superficial ulcers, nonsurgical treatment with meticulous pressure care and frequent dressings can be effective [1, 2]. For stage III and IV ulcers, surgical intervention is often required. Current treatments include debridement to healthy vascularized tissue, the use of negative-pressure therapy and reconstruction with either skin graft or, preferably, local flap [3, 4].

Common flaps used for the reconstruction of sacral pressure ulcers include unilateral or bilateral fasciocutaneous flaps (V-Y advancement or rotation), myocutaneous gluteus maximus flaps and perforator flaps based on the superior or inferior gluteal artery [5–8]. V-Y advancement flaps and rotation flaps are more suitable for small pressure areas because of their restricted range of movement. Myocutaneous gluteus maximus flaps are more traumatic and may affect gluteus maximus function, depending on the amount of muscle sacrificed. The superior and inferior gluteal artery perforator flap requires knowledge of the perforator location and more complex planning and dissection [9, 10]. For larger stage III and IV pressure ulcers, it would be ideal to have a reliable flap which is simple to design and elevate with minimal donor site morbidity. We feel that the bilobed flap based on the superficial branch of the superior gluteal artery or the posterior branch of the fourth lumbar artery meets these criteria.

In this study, we evaluate the technique and outcome of reconstructing the sacral pressure ulcer with the bilobed flap design.

## Case presentation

### Patients

Seven patients with spinal cord injury (SCI) presented with either stage III or stage IV pressure ulcers to our hospital between January 2015 and December 2019. Pressure sores were staged according to the National Pressure Ulcer Advisory Panel [11]. All patients who met the following eligibility criteria were included in the study: (1) traumatic SCI (thoracolumbar fracture) resulting in a sacral pressure sore; (2) failure of conservative treatment to heal the pressure ulcer; (3) provision of signed informed consent; (4) age older than 18 years; and (5) a minimum follow-up of 6 months.

Patients with chronic medical illness and/or neuropsychological disorder with little potential for rehabilitation were excluded. Table 1 summarizes the demographic details of the 7 patients.

### Preoperative preparation

**Optimize medical conditions** Patients with pressure ulcers were generally anemic with low albumin due to long-term wound consumption. Any electrolyte disorders and nutritional deficiencies were corrected to maximize wound healing prior to any surgical intervention.

**Wound preparation** The area that required debridement was marked with methylene blue. Adequate debridement entailed removal of all the necrotic tissue, which may have included surrounding scars, bursas and sequestra within the sacrum. Tissue samples were sent for culture to determine the appropriate antibiotic treatment. After careful hemostasis, the wound was washed with hydrogen peroxide, saline and bromogeramine. Negative-pressure therapy was applied to encourage granulation tissue prior to reconstruction.

### Surgical methods

The patient was positioned prone. The wound was debrided and washed. According to Lui's research [11], we could know the locations of perforators from lumbar and superior gluteal artery. The flap was designed depending on the anatomy of the lumbar and superior gluteal artery perforators; this was verified by ultrasound imaging. The bilobed flap was designed according to the method described by Xue *et al.* [12], as illustrated in Figure 1. The first lobe was designed along the lateral edge of the defect. The axis of the flap was along the vertical line that joins the posterior superior iliac spine and the midpoint of the gluteal crease. The superficial branch of the superior gluteal artery or the posterior branch of the fourth lumbar artery enters the proximal part of the first lobe with the superior cluneal nerves. The central axis of the flap and the central axis of the defect were at 45° to each other. The width of the first lobe was same as the width of the defect but was longer in length. The tip had a semi-spindle design to minimize potential dog ears when the distal part of the donor site was closed. The second lobe had an axis that lay along the line joining the posterior superior iliac spine and greater trochanter, at 45° from the central axis of the first flap. The width of the second lobe was between one-third and half that of the first lobe. A Pinch test was performed to ensure primary closure of the donor site.

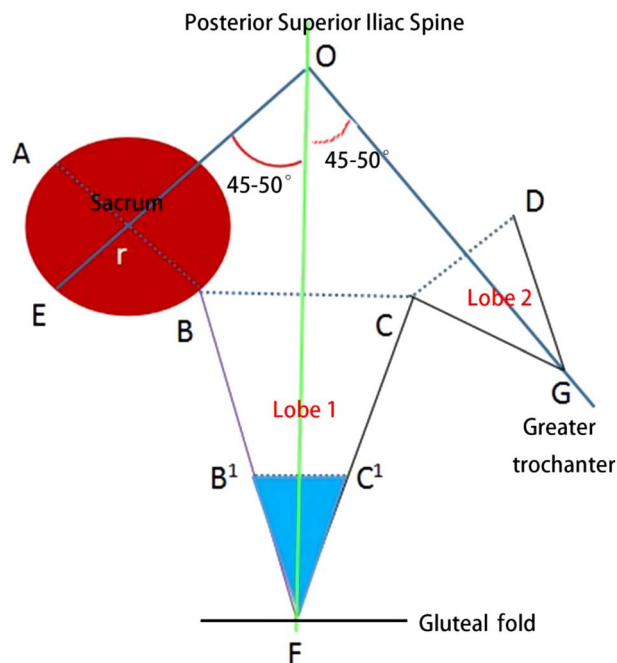
### Flap dissection

The flap was elevated from the distal end at the subfascial level, as illustrated in Figure 2. Some gluteal perforators were preserved to ensure a reliable blood supply, so long as the preservation of these perforators did not limit the flap's arc of transposition. The pedicle was dissected carefully, so as not to damage the posterior branch of the fourth lumbar artery, the perforator of the superior gluteal artery or the superior cluneal nerves. The first lobe was transposed into the defect and the second lobe was transposed to cover the donor site. According to the boundary of the defect area, surgeons could decide the exact area of de-epithelialized tissues in the tip of the first lobe. The de-epithelialized tissues were folded and put into dead space. The flap was inset and closed in three layers (deep fascia, dermis and subcuticular layer). Two drains were placed under the flap to maintain negative pressure and close off the dead space.

**Table 1.** Demographic profiles for the included cases

Patient	Age (years)	Sex	Area (mm)	Grade of NPUAP	Follow-up
1	46	Male	70 × 80	IV	12 months
2	48	Male	70 × 50	IV	12 months
3	50	Male	100 × 110	IV	13 months
4	63	Male	91 × 55	IV	12 months
5	62	Female	63 × 45	IV	12 months
6	47	Male	60 × 57	III	11 months
7	46	Male	62 × 45	IV	12 months

All patients had paraplegia caused by traumatic thoracolumbar fractures. NPUAP National Pressure Ulcer Advisory Panel



**Figure 1.** The design of the bilobed flap supplied by the superficial branch of the superior gluteal artery or the posterior branch of the fourth lumbar artery. O: posterior superior iliac spine; F: the middle of the gluteal fold; r: sacrum; G: greater trochanter. The red circular area represents the defect range formed after debridement of the pressure ulcer in the sacrococcygeal region. The blue area represents the expectedly de-epithelized range of Lobe 1; OF represents the axis of Lobe 1; OG represents the axis of Lobe 2;  $AB=BC > CD$ ;  $OG > OE$ . The area of Lobe 2 is one-third to one-half that of Lobe 1

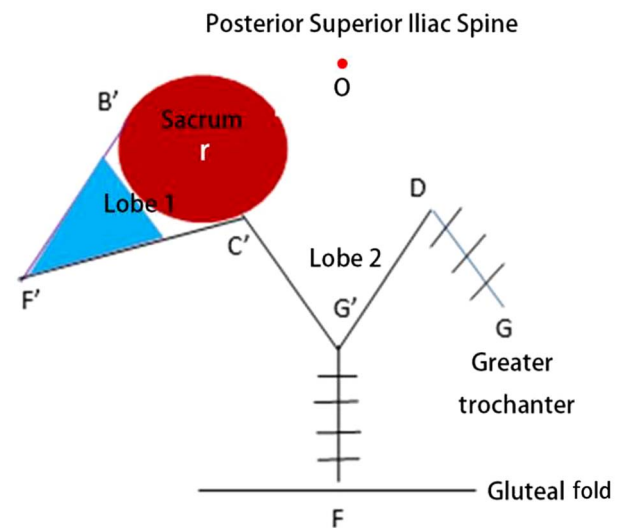
### Postoperative care and follow-up

After the operation, the patient was nursed in the prone or lateral position with an air mattress for at least 4 weeks. The hip joint on the affected side was maintained neutral to minimize any tension across the inset. The drain was removed when it was draining less than 10 ml over 24 hours a day.

Follow-up was carried out every 3 months to monitor for complications, including infection, hematoma/seroma, partial flap necrosis, sacral decubitus ulcer recurrence and hypertrophic scar formation.

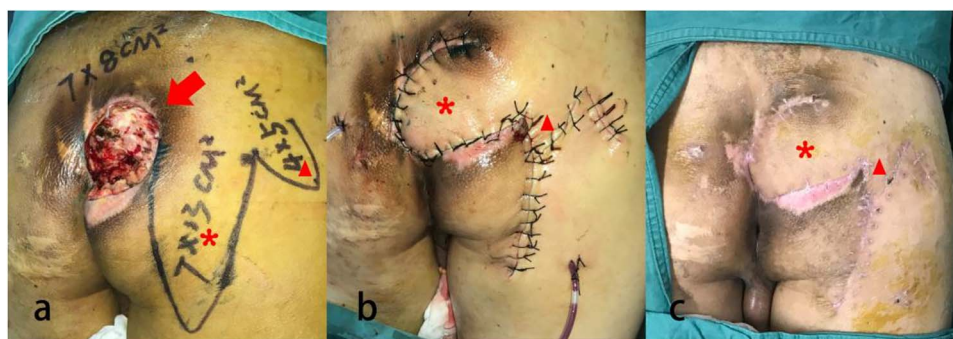
### Cases

A total of 7 patients with paraplegia were treated with the bilobed flap based on the superficial branch of the superior

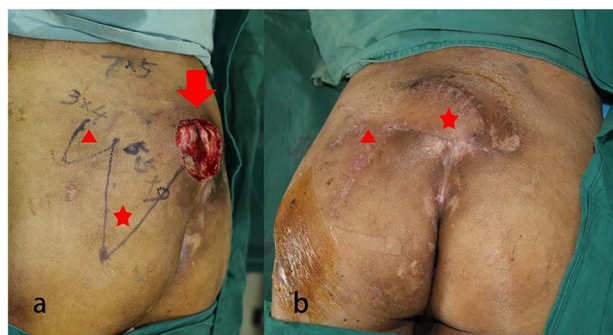

**Figure 2.** The sacral decubitus ulcer is reconstructed by the bilobed flap supplied by the superficial branch of superior gluteal artery or the posterior branch of the fourth lumbar artery. O: posterior superior iliac spine; F: middle of the gluteal fold; r: sacrum; G: greater trochanter. The red circular area, which represents the defect range formed after debridement of the pressure ulcer in the sacrococcygeal region, has been covered by Lobe 1. The blue area represents the de-epithelized range of Lobe 1, and this part would be folded and inset into the deep defect of the pressure ulcer. DG and FG: direct closure of the rest of the defect

gluteal artery or the posterior branch of the fourth lumbar artery to repair their sacral pressure defect. These included 6 males and 1 female with an average age of 53.1 years (range 46–63 years). All cases of paraplegia were due to traumatic thoracolumbar fractures. The size of the defect averaged  $7 \times 5$  cm (range  $6.2 \times 4.5$  cm to  $11 \times 10$  cm). All the flaps survived. Mean operation time was 146.17 minutes (range 97–203 minutes). Mean blood loss during the operation was 170.83 ml (range 50–500 ml). The drains were removed at a mean time of 9.42 days (range 3–11 days) after surgery. The mean duration of hospital stay was 16.58 days (range 10–21 days). The average duration of follow-up was 12 months (range 11–13 months) (Table 1). No complications were observed after surgery, such as hematoma/seroma under the flap, superficial infection, partial flap necrosis, sacral decubitus ulcer recurrence over the flap or sacral decubitus ulcer recurrence over the new site.



**Figure 3.** A 44-year-old man with pressure ulcer (stage IV) was treated by the bilobed flap supplied by the superficial branch of superior gluteal artery or the posterior branch of the fourth lumbar artery, (a) before operation; (b) after operation; (c) one year later. Arrow: ulcer position; asterisk: Lobe 1; triangle: Lobe 2



**Figure 4.** A 63-year-old man with pressure ulcer (stage IV) was treated by the bilobed flap supplied by the superficial branch of superior gluteal artery or the posterior branch of the 4th lumbar artery, (a) before operation; (b) one year later. Arrow: ulcer position; asterisk: Lobe 1; triangle: Lobe 2

**Case 1** The first case was a 44-year-old paraplegic male patient who had been bed-bound for 5 years. He presented with a stage IV pressure sore measuring  $7 \times 8$  cm. After initial debridement, he underwent a bilobed flap repair based on the superficial branch of the superior gluteal artery or the posterior branch of the fourth lumbar artery. The first lobe measured  $7 \times 13$  cm and the second lobe measured  $4 \times 5$  cm. His postoperative course was unremarkable. At one-year follow-up there was no recurrent pressure ulcer or hypertrophic scar (Figure 3).

**Case 2** The second case was a 63-year-old paraplegic male patient who had been bed-bound for 3 years. He presented with a stage IV pressure sore measuring  $7 \times 5$  cm. After initial debridement, a bilobed flap based on the superficial branch of the superior gluteal artery or the posterior branch of the fourth lumbar artery was raised. The size of the first lobe was  $5.5 \times 9$  cm and the second lobe was  $3 \times 4$  cm. The postoperative course was uncomplicated. At one year, the wound had healed with no recurrence (Figure 4).

## Discussion

Sacral pressure ulcers remain a reconstructive challenge. A split skin graft is occasionally used but is prone to recurrence

and hypertrophic scarring [5, 13]. A local flap is the main option and examples of local flap include the fasciocutaneous flap (V-Y advancement flap and rotation flap), myocutaneous gluteus maximus flap and perforator flap based on the superior and inferior gluteal arteries [6–8].

The bilobed flap, originally described by Esser, is a special type of transposition flap. It is an extremely useful technique as it effectively transfers tissue from areas of abundance to areas of deficiency. In the original description, the angle between the long axis of the defect and the first lobe was  $90^\circ$ , which significantly distorted the skin with poor aesthetic outcome [14, 15]. In the 1980s, McGregor and Soutar introduced the concept that a reduced pivot angle would result in better cosmesis and reduce pin-cushioning [16]. In 1989, Zitelli [17] modified the design and limited the angle between the long axis of the defect and the first lobe to about  $45^\circ$ , which greatly improved the aesthetic result of the flap. In 2009, Xue *et al.* [12] proposed a modified bilobed based on Zitelli's design. The length of the first lobe was 10% longer than the distance of the distal defect edge to primary pivot point, and the width of the first lobe was equal to the width of the defect. The length of the second lobe was 130% of the length of the distal defect edge to the flap's pivot point, and the width of the second lobe was two-thirds of the width of the primary lobe.

The superior cluneal nerve originates from the lateral branch of the posterior rami of T12 to L3 spinal nerve and travels approximately 1 cm above the lateral margin of the iliac spine and along the posterior branch of the fourth lumbar artery [18]. The flap is designed based on the position of the superior cluneal nerve and the posterior branch of the fourth lumbar artery. The neurovascular plexuses and the vascular networks of the deep fascia, subcutaneous tissue, superficial vein and skin have abundant anastomoses to form the arteriovenous chain [19]. In addition, the superior cluneal nerve has the posterior branch of the fourth lumbar artery adjacent to it and is nourished by it. In the upper part of the gluteus maximus, there are also perforators from the superior gluteal artery that are involved in the vascular network over the gluteal fascia. The para-neural vascular network provides a rich vascular plexus that forms the basis of the flap [20] and

provides robust blood supply. In patients without SCI, it has the additional benefit of being a sensate flap.

The other advantage of the bilobed flap repair based on the superficial branch of the superior gluteal artery or the posterior branch of the fourth lumbar artery is the abundant subcutaneous tissue in the region. The flap design is simple and reproducible. There is no dissection through the gluteal maximus and therefore the muscle fibers are preserved. There is no dissection required for the neurovascular bundle and it is, therefore, relatively straightforward to learn. The flap contains the superior cluneal nerve. Protective sensation can be preserved, thereby reducing the risk of recurrent pressure sore. As a local flap, it is also more robust than a skin graft, with acceptable cosmesis.

Most of the pressure sores in the sacrum are of an ulcer or sinus type and located superficial to the sacrum. Reconstruction requires sufficient tissue volume to fill the defect. The distal tip of the first lobe can be de-epithelized, folded and sutured to the sacrum to fill the dead space [21].

Due to the position of the pedicle in the superior part of the gluteal region, the flap is most suitable for pressure sores at the sacrum specifically, rather than pressure sores at other locations. Other local flaps, such as the posterior thigh flap or rotation flap, are required for pressure sores in the lower half of the buttock. Previous scar over the gluteal region where the flaps are to be designed is a relative contraindication.

## Conclusions

The bilobed flap based on the superficial branch of superior gluteal artery or the posterior branch of the fourth lumbar artery is an ideal method for reconstruction of sacral pressure ulcers. Its blood supply is abundant. The design is simple and easy to learn. Most importantly, it has a low complication profile. It should be considered as part of the local flap armamentarium for sacral pressure ulcers.

## Abbreviations

SCI: spinal cord injury

## Funding

This study was supported by funding from the following programs: The National Natural Science Foundation of China (Grant Number:81772098); the Clinical Multi-Disciplinary Team Research Program of the Ninth People's Hospital, Shanghai Jiao Tong University School of Medicine; the Clinical Research Program of the Ninth People's Hospital, Shanghai Jiao Tong University School of Medicine; and the Shanghai Municipal Education Commission Gaofeng Clinical Medicine Grant Support.

## Availability of data and materials

The database used during the current study is available from the corresponding author upon reasonable request.

## Authors' contributions

ZYX, LK and JZJ designed the research. JXG, CCX and NSK carried out the analysis of the data for this study with the database provided by TCH, ZJM and LXD. JXG, OXW and LT participated in drafting the manuscript. All the authors read and approved the final manuscript.

## Ethics approval and consent to participate

The study was conducted in accordance with the guidelines of the Declaration of Helsinki stated in 1964. The study protocol was agreed by the local ethics committee of the Liuyang People's Hospital. Every patient provided written informed consent.

## Consent for publication

All presentations of case reports in this article have consent for publication.

## Conflicts of interest

The authors declare that they have no competing interests.

## References

1. Ruan CM, Escobedo E, Harrison S, Goldstein B. Magnetic resonance imaging of nonhealing pressure ulcers and myocutaneous flaps. *Arch Phys Med Rehabil.* 1998;79:1080–8.
2. Walker RM, Gillespie BM, Thalib L, Higgins NS, Whitty JA. Foam dressings for treating pressure ulcers. *Cochrane Database Syst Rev.* 2017;10:CD011332.
3. Allam RC. Micronized, particulate dermal matrix to manage a non-healing pressure ulcer with undermined wound edges: a case report. *Ostomy Wound Manage.* 2007;53:78–82.
4. Westby MJ, Dumville JC, Soares MO, Stubbs N, Norman G. Dressings and topical agents for treating pressure ulcers. *Cochrane Database Syst Rev.* 2017;6:CD011947.
5. Singh R, Singh R, Rohilla RK, Magu NK, Goel R, Kaur K. Improvisations in classic and modified techniques of flap surgery to improve the success rate for pressure ulcer healing in patients with spinal cord injury. *Int Wound J.* 2013;10:455–60.
6. Rubayi S, Gabbay J, Kruger E, Ruhge K. The modified Girdlestone procedure with muscle flap for management of pressure ulcers and heterotopic ossification of the hip region in spinal injury patients: a 15-year review with long-term follow-up. *Ann Plast Surg.* 2016;77:645–52.
7. Wang CY, Wu CJ, Chu TS, Chen CY, Chou CY, Chiao HY, et al. Reconstruction of a sacral pressure ulcer with an inferior gluteal artery perforator flap after failed reconstruction using bilateral V-Y advancement flaps. *Ostomy Wound Manage.* 2018;64:45–8.
8. Lin CT, Ou KW, Chiao HY, Wang CY, Chou CY, Chen SG, et al. Inferior gluteal artery perforator flap for sacral pressure ulcer reconstruction: a retrospective case study of 11 patients. *Ostomy Wound Manage.* 2016;62:34–9.
9. Saeed A, Narayan N, Troisi L. A propeller SGAP flap raised from a previous gluteus maximus myocutaneous flap to reconstruct a recurrent type IV sacral pressure ulcer. *Microsurgery.* 2018;38:924–5.

10. Andrianasolo J, Ferry T, Boucher F, Chateau J, Shipkov H, Daoud F, *et al.* Pressure ulcer-related pelvic osteomyelitis: evaluation of a two-stage surgical strategy (debridement, negative pressure therapy and flap coverage) with prolonged antimicrobial therapy. *BMC Infect Dis.* 2018;18:166.
11. Liu KW, Hu S, Ahmad N, Tang M. Three-dimensional angiography of the superior gluteal artery and lumbar artery perforator flap. *Plast Reconstr Surg.* 2009;123:79–86.
12. Xue CY, Li L, Guo LL, Li JH, Xing X. The bilobed flap for reconstruction of distal nasal defect in Asians. *Aesthetic Plast Surg.* 2009;33:600–4.
13. Fujiwara H, Isogai Z, Irisawa R, Otsuka M, Kadono T, Koga M, *et al.* Wound, pressure ulcer and burn guidelines - 2: guidelines for the diagnosis and treatment of pressure ulcers, second edition. *J Dermatol.* 2018;127:1933–88.
14. Mole RJ, Badri T. Bilobed flaps. 2018; Available at: <https://www.ncbi.nlm.nih.gov/books/NBK470355>.
15. Zimany A. The bi-lobed flap. *Plast Reconstr Surg (1946).* 1953;11:424–34.
16. McGregor JC, Soutar DS. A critical assessment of the bilobed flap. *Br J Plast Surg.* 1981;34:197–205.
17. Zitelli JA. The bilobed flap for nasal reconstruction. *Arch Dermatol.* 1989;125:957–9.
18. Kimura H, Nasu W, Kashiwa K, Kobayashi S. Reconstruction of the sacral region using the lumbo-gluteal sensory flap. *J Plast Reconstr Aesthet Surg.* 2013;66:239–42.
19. Sa M, Graca R, Reis H, Cardoso JM, Sampaio J, Pinheiro C, *et al.* Superior gluteal nerve: a new block on the block? *Rev Bras Anesthesiol.* 2018;68:400–3.
20. Mirilas P, Skandalakis JE. Surgical anatomy of the retroperitoneal spaces, part IV: retroperitoneal nerves. *Am Surg.* 2010;76:253–62.
21. Chang JW, Oh SW, Oh J, Choi MSS. Treatment of deep cavities using a perforator-based island flap with partial de-epithelization. *BMC Surg.* 2018;18:96.