

Infundibulocystic basal cell carcinoma: dermoscopic findings and histologic correlation

Rodrigo Roldán-Marín¹, Sergio Leal-Osuna¹, Lorena Lammoglia-Ordiales¹, Sonia Toussaint-Caire¹

¹ Dermatology Department, Hospital General “Dr. Manuel Gea González,” Mexico City, Mexico

Keywords: infundibulocystic, basal cell carcinoma, dermoscopy, histopathology

Citation: Roldán-Marín, R, Leal-Osuna S, Lammoglia-Ordiales L, Toussaint-Caire S. Infundibulocystic basal cell carcinoma: dermoscopic findings and histologic correlation. *Dermatol Pract Concept*. 2014;4(3):9. <http://dx.doi.org/10.5826/dpc.0403a09>

Received: February 18, 2014; **Accepted:** March 15, 2014; **Published:** July 31, 2014

Copyright: ©2014 Roldán-Marín et al. This is an open-access article distributed under the terms of the Creative Commons Attribution License, which permits unrestricted use, distribution, and reproduction in any medium, provided the original author and source are credited.

Funding: None.

Competing interests: The authors have no conflicts of interest to disclose.

All authors have contributed significantly to this publication.

Corresponding author: Rodrigo Roldán-Marín, MD, Dermatology Department, Hospital General “Dr. Manuel Gea González,” Calzada de Tlalpan 4800, Col. Sección XVI, Tlalpan 14080, Mexico City, Mexico. Tel: +52-55-56043636. E-mail: roroderm@yahoo.com

ABSTRACT Infundibulocystic basal cell carcinoma is a rare variant. It was first described in 1987 and proposed as a new basal cell carcinoma (BCC) subtype by Ackerman and Walsh in 1990. Dermoscopy is a non-invasive diagnostic technique that allows prompt identification of many types of BCC. However, dermoscopic findings for the infundibulocystic variant have not been reported. In our patient the dermoscopic findings were maple leaf-like areas in the periphery of the tumor, multiple scattered blue-gray dots and globules, short, fine telangiectasia and chrysalis or white-shiny streaks. All these structures had an underlying anatomopathological correlation.

Conclusion: According to our case report, dermoscopy findings may aid to clearly diagnose this unusual BCC variant with proper histopathological correlation.

Introduction

Infundibulocystic basal cell carcinoma is a rare subtype of the most frequent form of human skin cancer (basal cell carcinoma). It was first described in 1987 and proposed as a new basal cell carcinoma (BCC) variant by Ackerman and Walsh in 1990 [1,2]. This unusual variant has been described to occur as a solitary entity or as part of nevoid basal cell carcinoma syndrome [3].

Histopathologically it is a well circumscribed, superficially located, basaloid cell tumor with hyperchromatic, pleomorphic nuclei and rare mitoses, multiple tiny cysts

containing cornified cells lined by infundibular epithelium. It typically lacks follicular bulbs and papillae or papillary mesenchymal bodies. The stroma usually has abundant connective tissue mucin [4].

Dermoscopy is a non-invasive diagnostic technique that has become an integrative part of the clinical approach of skin tumors since it significantly improves the early diagnosis of melanoma and non-melanoma skin cancer (NMSC) compared to the naked eye examination [5]. Dermoscopy has also been used to improve pre-operative margin evaluation and monitoring treatment response to topical therapy [6,7]. Dermoscopic criteria for BCC have been clearly established

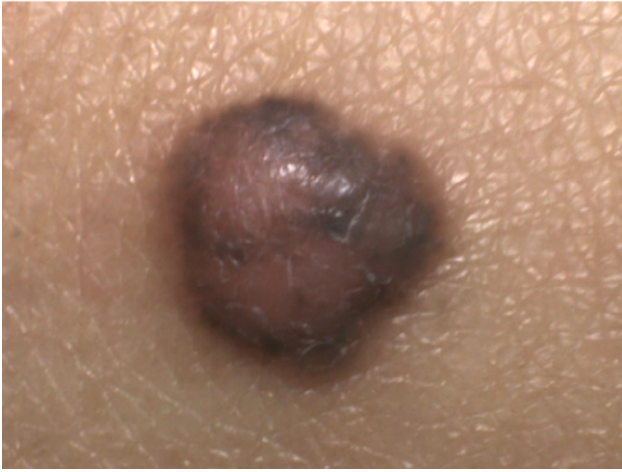

Figure 1. Clinical examination revealed a 4 mm, well-circumscribed, pigmented skin tumor affecting the medial aspect of her anterior right thigh. The neoplasm had a pale center with a peripheral pigmented rim with superficial scale, and it was firm to palpation. [Copyright: ©2014 Roldán-Marín et al.]

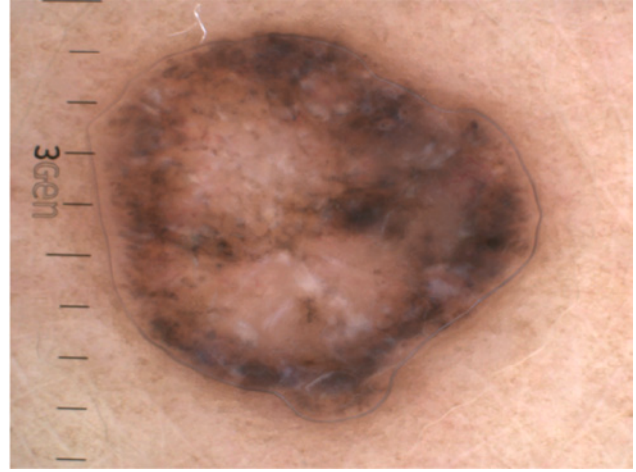


Figure 2. Dermoscopy revealed the presence of maple leaf-like areas on the periphery, multiple scattered blue-gray dots and globules, short, fine telangiectasia and chrysalis or white-shiny streaks. [Copyright: ©2014 Roldán-Marín et al.]

and its value in discriminating superficial BCC from other subtypes was recently reported [8].

However, there is no previous dermoscopic description of the infundibulocystic variant.

Case presentation

A 49-year-old, female patient, skin phototype V, presented to the outpatient dermatology clinic for evaluation. The derma-

tological examination revealed a 4 mm, well-circumscribed, pigmented skin tumor affecting the medial aspect of her anterior right thigh. The neoplasm had a pale center with a peripheral pigmented rim with superficial scale, and it was firm to palpation. Clinically, the lesion resembled a dermatofibroma (Figure 1). Dermoscopic evaluation revealed the presence of maple leaf-like areas on the periphery, multiple scattered blue-gray dots and globules, short, fine telangiectasia and chrysalis or white-shiny streaks (Figure 2).

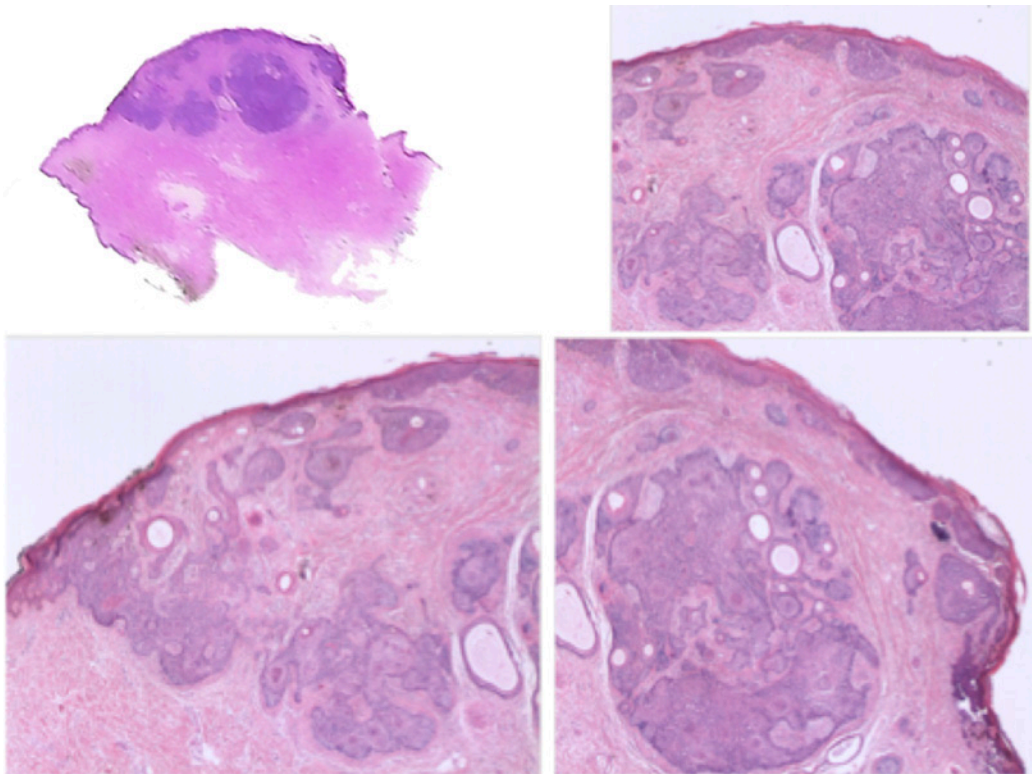


Figure 3. At low magnification histopathological showed a well circumscribed, superficially located tumor, formed by anastomosing cords of basaloid keratinocytes with several tiny cornifying cysts. [Copyright: ©2014 Roldán-Marín et al.]

Due to the inconsistency between the clinical appearance and the dermoscopic findings, an excisional biopsy was performed. The histopathological examination at low magnification showed a well circumscribed, superficially located tumor, formed by anastomosing cords of basaloid keratinocytes with several tiny cornifying cysts (Figure 3). At higher magnification, tumor cells had scant cytoplasm with hyperchromatic, pleomorphic nuclei with rare mitoses and few necrotic cells. Some keratinocytes had granular melanin in their cytoplasm. There was a lymphocytic peritumoral inflammatory infiltrate. At the upper reticular dermis there was an increased number of collagen bundles horizontally arranged and aligned parallel to the epidermis. Lateral and deep margins were tumor free.

Discussion

We present a case of infundibulocystic basal cell carcinoma, meaning a BCC with upper follicular differentiation. Basal cell carcinoma rarely shows differentiation toward epithelial

structures of adnexa including follicular, sebaceous, eccrine and apocrine. BCC was originally considered a neoplasm derived from the basal cells of the epidermis. Later, it was proposed that it could derive from primary epithelial germ cells or from any part of the equipotential ectoderm of the skin in combination with organized mesodermal stroma [9]. Thus basaloid cells in BCC have the potential for differentiation toward various epidermal appendages. A combination of different kinds of follicular differentiation toward infundibula and follicular germ cells is unique in the infundibulocystic variant of BCC.

Histopathologically, differential diagnosis includes basaloid follicular hamartoma and trichoepithelioma [2].

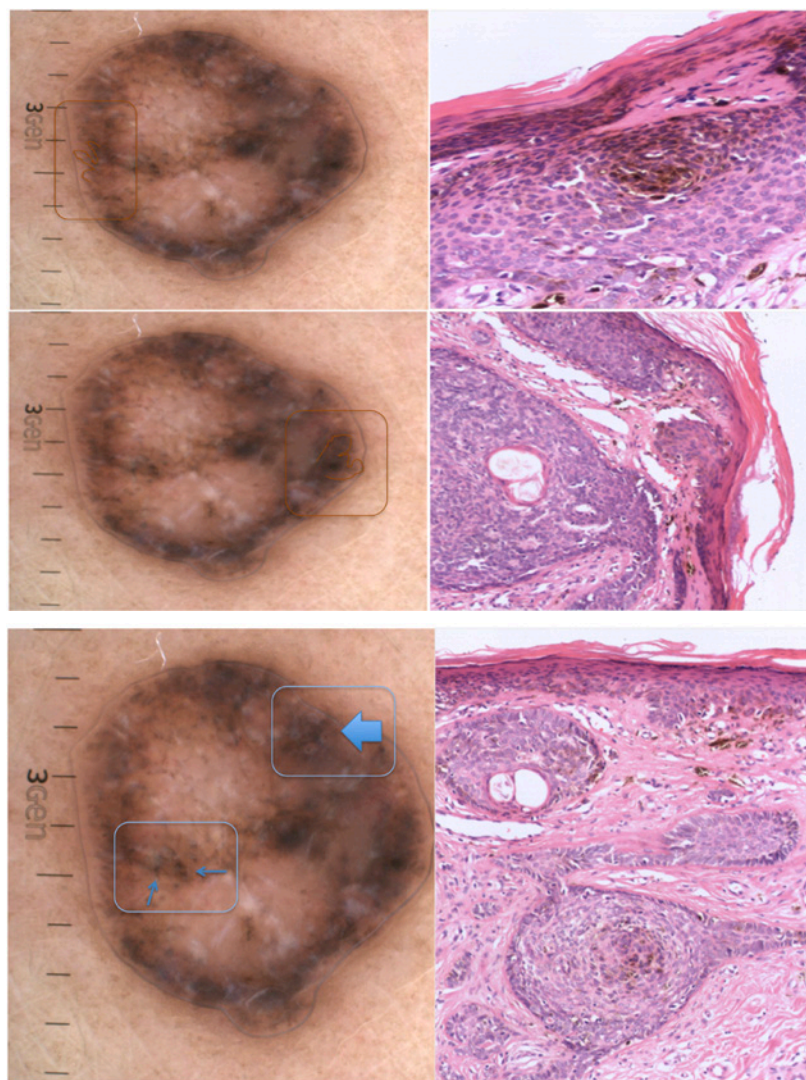
Dermoscopy is a powerful, non-invasive, diagnostic tool, which greatly increases diagnostic accuracy. It has demonstrated to help diagnose BCC and its various subtypes with high sensitivity and specificity [5,7]. In our patient, dermoscopy clearly showed criteria compatible with basal cell carcinoma. The maple leaf-like areas in the periphery as well as the

scattered blue-gray dots and globules were due to the presence of pigmented epithelial nests in the papillary dermis (Figures 4 and 5). Short, fine telangiectasia was consistent with the presence of dilated blood vessels in the superficial dermis (Figure 6). The presence of chrysalis or white shiny structures was in agreement with the presence of an increased number of collagen bundles horizontally disposed and aligned parallel to the epidermis [10] (Figure 7).

This case illustrates the benefit of dermoscopy in establishing the diagnosis of basal cell carcinoma, even in this rare subtype. It also serves to exemplify how dermoscopy clearly aids the approach in the differential diagnosis between trichoepithelioma and BCC, which histologically can sometimes only be determined with immunohistochemistry staining. However, the most prominent dermoscopic findings in trichoepithelioma are arborizing telangiectasia and in desmoplastic lesions, an ivory-white background throughout [11,12].

Conclusion

This case report clearly exemplifies the usefulness of dermoscopy in the detection of BCC, even in this unusual subtype. It also serves to demonstrate once more how dermoscopy may bridge the gap between clinical and histopathological correlation, since



Figures 4 and 5. Maple leaf-like areas in the periphery as well as the scattered blue-gray dots and globules linked to the presence of pigmented epithelial nests in the papillary dermis. [Copyright: ©2014 Roldán-Marín et al.]

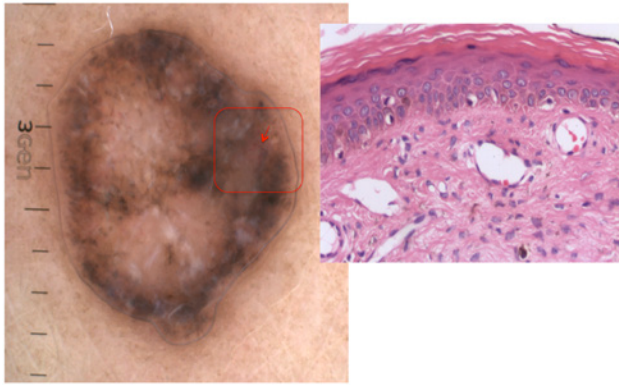


Figure 6. Short, fine telangiectasia due to the presence of dilated blood vessels in the superficial dermis. [Copyright: ©2014 Roldán-Marín et al.]

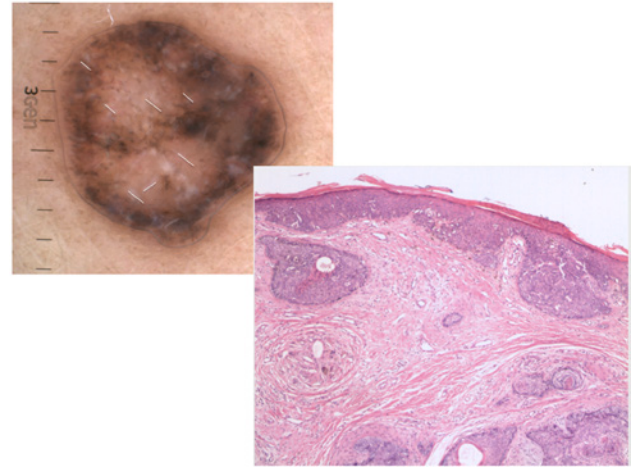


Figure 7. White shiny structures related to the presence of an increased number of collagen bundles horizontally arranged and aligned parallel to the epidermis. [Copyright: ©2014 Roldán-Marín et al.]

each dermoscopic structure is related to a specific underlying anatomopathological correlate.

References

1. Tozawa T, Ackerman AB. Basal cell carcinoma with follicular differentiation. *Am J Dermatopathol.* 1987;9:474-82.
2. Walsh N, Ackerman AB. Infundibulocystic basal cell carcinoma: a newly described variant. *Mod Pathol.* 1990;3:599-608.
3. Requena L, Fariña MC, Robledo M, et al. Multiple hereditary infundibulocystic basal cell carcinomas: a genodermatosis different from nevoid basal cell carcinoma syndrome. *Arch Dermatol.* 1999;135:1227-35.
4. Kato N, Ueno H. Infundibulocystic basal cell carcinoma. *Am J Dermatopathol.* 1993;15:265-7.
5. Lallas A, Argenziano G, Zandri E, et al. Update on non-melanoma skin cancer and the value of dermoscopy in its diagnosis and treatment monitoring. *Expert Rev Anticancer Ther.* 2013;13:541-58.
6. Caresana G, Gardini R. Dermoscopy-guided surgery in basal cell carcinoma. *J Eur Acad Dermatol Venereol.* 2010;24:1395-9.
7. Fargnoli MC, Kostaki D, Piccioni A, Micantonio T, Peris K. Dermoscopy in the diagnosis and management of non-melanoma skin cancers. *Eur J Dermatol.* 2012;22:456-63.
8. Lallas A, Tzellos T, Kyrgidis A, et al. Accuracy of dermoscopic criteria for discriminating superficial from other subtypes of basal cell carcinoma. *J Am Acad Dermatol.* 2014;70:303-11.
9. Lever WF, Schaumburg-Lever G. Basal cell epithelioma. In: Lever WF, Schaumburg-Lever G. (eds.). *Lever's Histopathology of the Skin.* 7th ed. Philadelphia: JB Lippincott, 1990:622-34.
10. Liebman TN, Rabinovitz HS, Balagula Y, Jaimes-Lopez N, Marghoob AA. White shiny structures in melanoma and BCC. *Arch Dermatol.* 2012;148:146.
11. Ardigo M, Zieff J, Scope A, et al. Dermoscopic and reflectance confocal microscope findings of trichoepithelioma. *Dermatology.* 2007;215:354-8.
12. Khelifa E, Masouyé I, Kaya G, Le Gal FA. Dermoscopy of desmoplastic trichoepithelioma reveals other criteria to distinguish it from basal cell carcinoma. *Dermatology.* 2013;226:101-4.