


## SCIENTIFIC ARTICLE

# Arthroscopic Reconstruction of Posterior Cruciate Ligament with Embedded Tibial Tendon Bolt

Hua-zhe Li, MM<sup>1,2</sup>, Cong Yu, BM<sup>1</sup>, Zhi-tao Zhang, MM<sup>1,2</sup>, Shi Yan, MM<sup>1</sup>, Yun-jian Liao, MM<sup>1,2</sup>, Dai-feng Lu, MD<sup>1,2</sup> 

<sup>1</sup>Department of Orthopaedics, The Fourth Affiliated Hospital of Harbin Medical University and <sup>2</sup>Heilongjiang Academy of Medical Sciences, Harbin, China

**Objective:** To evaluate the effect of newly designed arthroscopic reconstruction of posterior cruciate ligament (PCL) using tibial tendon bolt.

**Methods:** The effects of embedded tendon pin were observed by X-ray of knee joint. From October 2010 to September 2015, 51 PCL injury patients who met the inclusion criteria were enrolled in this retrospective study. The arthroscopically assisted reconstruction of the PCL with tibial tendon bolt was performed on all patients. Visual Analog Scale (VAS) pain score, Tegner activity score, Lysholm score, International Knee Documentation Committee (IKDC) assessment, posterior drawer test (PDT), and KT-1000 activity score were evaluated preoperatively and at 1-year postoperative and 3-year postoperative.

**Results:** The preoperative, 1-year postoperative, and 3-year postoperative IKDC score ( $15.8\% \pm 14.8\%$ ,  $89.6\% \pm 5.8\%$ , and  $86.8\% \pm 5.4\%$ ), Lysholm score ( $17.4 \pm 10.7$ ,  $91.2 \pm 2.8$ , and  $88.2 \pm 3.1$ ), VAS score ( $5.8 \pm 1.2$ ,  $1.3 \pm 0.5$ , and  $0.6 \pm 0.5$ ), Tegner activity score ( $1.2 \pm 0.8$ ,  $8.1 \pm 0.8$ , and  $7.4 \pm 0.8$ ), and KT-1000 score ( $15.6 \pm 3.6$ ,  $4.5 \pm 2.4$ , and  $5.4 \pm 1.8$ ) were obtained. There were significant differences in these outcomes among preoperative, 1-year postoperative, and 3-year postoperative (all  $P < 0.0001$ ). After 1- and 3-year surgery, 31 (60.8%) and 26 (51.0%) patients had the negative PDT, indicating that the PCL injury was improved. There were no postoperative complications.

**Conclusion:** The application of tendon pin fixed by tibial inlay 8-shaped tibial tunnel to reconstruct PCL was an effective, simple, and safe surgical procedure for PCL injury.

**Key words:** Arthroscopy; Knee joint; Posterior cruciate ligament; Reconstruction

## Introduction

The posterior cruciate ligament (PCL), one of the four major ligaments of the knee, connects the posterior intercondylar area of the tibia to the medial condyle of the femur<sup>1</sup> and helps to maintain knee stability during flexion and rotation. PCL injury is one of the most common knee injuries, with over 100,000 cases occurring annually in the United States<sup>2</sup>. PCL injuries may cause knee instability that make the tibia move in the posterior direction, hindering the

back of knee joint to stay straight and resulting in degenerative changes of knee in the long term<sup>3</sup>. Early surgical treatment of displaced bony avulsion of the PCL is considered as a necessary measure to restore knee stability<sup>4, 5</sup>. Nevertheless, there is considerable controversy in the optimal surgical treatment for isolated tibial avulsion fractures of the PCL. Because the conservative treatment has poor outcomes in PCL injury, the reconstructive surgery is needed on most PCL injury patients<sup>6</sup>. Despite early diagnosis and appropriate

**Address for correspondence** Dai-feng Lu, MD, Department of Orthopaedics, Fourth Affiliated Hospital of Harbin Medical University, No. 37 Yiyuan Street, Nangang District, Harbin, Heilongjiang Province, China 150001 Tel: +86-15246776189; Fax: +86-15246776189; Email: deka0390naxin@163.com

**Grant Sources:** This work was supported by The General Program Foundation of the Fourth School of Clinical Medicine, Harbin Medical University (Program No. HYDSYJQ201606); Scientific Research Project of Heilongjiang Health and Family Planning Commission (Program No. 2014-375), and Scientific Research Program for Heilongjiang Academy of Medical Sciences (Program No. 201807).

Received 27 February 2020; accepted 14 October 2020

operative treatments, the postoperative recovery was not satisfactory in PCL injury patients<sup>7</sup>.

In recent years, PCL surgery has significantly developed and rapidly evolved in recent years. Single-bundle or double-bundle PCL reconstruction has been carried out using a tibial tunnel or inlay technique<sup>8</sup>. The tibial tunnel reconstruction of the PCL is a classical technique which can be completed in arthroscopic surgical trauma with a short operation time<sup>9</sup>. The tibial tunnel technique requires the tunnel to be placed into the retrospinal area, and the precise placement of a tibial tunnel is crucial for successful reconstruction of the PCL using arthroscopic tibial tunnel techniques<sup>10</sup>. A previous study shows that PCL reconstruction is necessary in order to prevent postoperative dissatisfaction despite a successful operation in the surgeons' point of view<sup>11</sup>. Based on clinical research, Loh *et al.* showed that there was a good knee stability following anterior cruciate ligament reconstruction on PCL injury patients<sup>12</sup>. However, the presence of graft in the tunnel fixed invalid distance results in graft tunnel horizontal and vertical relative motion in a "wiper effect" (windshield wiper effect) and a "bungee effect"<sup>13</sup>. Despite that, the angle between the tunnel and the graft is less than 90°, which further leads to thinning of the grafts at the tunnel portal, decrease in tension, and the gradual relaxation ("killer turn" effect)<sup>14, 15</sup>. Thus, the current tibial tunnel reconstruction has not obtained uniformly predictable results. Besides, other factors that contribute to the failure of tibial tunnel reconstruction of PCL include ligament instabilities and incorrect tunnel placement<sup>16</sup>. With regard to the factors influencing the success of operation, great emphasis on reconstruction for ligament relaxation is needed.

Thus, in this study, we designed a new PCL reconstruction technique with tibial tendon pin through tibia cruciate ligament reconstruction on PCL injury patients. The tibial side arthroscopic reconstruction effect of posterior cruciate ligament with tibial reconstruction was evaluated by postoperative recovery evaluation and follow-up data. The purpose of this retrospective study was as follows: (i) we aimed to investigate the effect of the newly designed arthroscopic reconstruction of the PCL using tibial tendon bolt by evaluating the Visual Analog Scale (VAS) pain score, Tegner

activity score, Lysholm score, International Knee Documentation Committee (IKDC) assessment, and KT-1000 activity score; (ii) we intended to report the surgical skills of this newly designed arthroscopic reconstruction of the PCL using tibial tendon bolt, such as the application of tendon pin fixed by tibial inlay 8-shaped tibial tunnel and the adjustment of the diameter and length of an effective intra-articular tendon graft; and (iii) we hoped to provide an effective, simple, and safe fixation method for PCL reconstruction surgery.

## Materials and Methods

### Inclusion and Exclusion Criteria

The patients with the following clinical manifestations were enrolled in this study: (i) patients presented with PCL rupture alone or combined with posterolateral complex (PLC) injury, with tibial retrograde exceeding 10–15 mm; (ii) patients underwent the arthroscopic reconstruction of PCL with embedded tibial tendon bolt from October 2010 to September 2015; (iii) PCL injury was significantly improved after surgery by evaluating IKDC score, Lysholm score, VAS pain score, Tegner activity score, posterior drawer test (PDT), and KT-1000 activity score; and (iv) retrospectively recruited. Meanwhile, patients with the following surgical manifestations were excluded from current study: (i) previous knee surgery history, and (ii) severe osteoporosis.

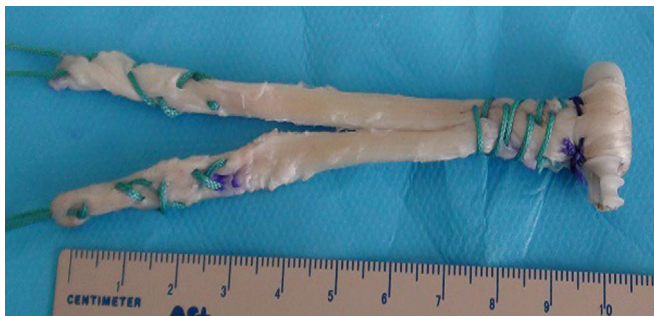### Patients' Information

A total of 51 patients (men: 40, women: 11, age range: 15–74 years, average age: 44.5 ± 29.5 years) were enrolled in this retrospective study. Among these patients, there were 13 cases of meniscus injury (six cases for partial meniscus resection, and seven cases for suture surgery), two cases of posterolateral structure damage (treated with Fanelli's reconstruction methods<sup>17</sup>), and nine cases of anterior cruciate ligament injuries repaired by suture and suture fixation. Written informed consent was obtained for each participant according to institutional guidelines. The study was approved by the ethics committee of the Fourth Affiliated Hospital of Harbin Medical University and approval (no. 2020-SCILLSC-08) was obtained by institutional review board (IRB).

### Surgical Technique

#### Knitted and Sutured "Tendon Pin" Tendon

The materials of rebuilt tendons were all from the autologous femoris and semitendinosus. The semitendinosus tendon was reflexed at one-third of total length and combined with gracilis tendon. Two ends of the tendon (30 mm for each end) were knitted and fixed with the MB66 (Johnson) tendon suture. Then, a 15 mm tendon extrusion nail (Smith & Nephew Inc., Largo, FL, USA) with nail head cut was used for the PEEK pin preparation. The folded ends of the tendon were sutured together with surgical suture, forming a "tendon pin" fixed body. The effective length of the tendon was 85 mm. The



**Fig 1** Knitted and sutured "tendon pin" tendon by wrapping the PEEK nail using a hamstring tendon.

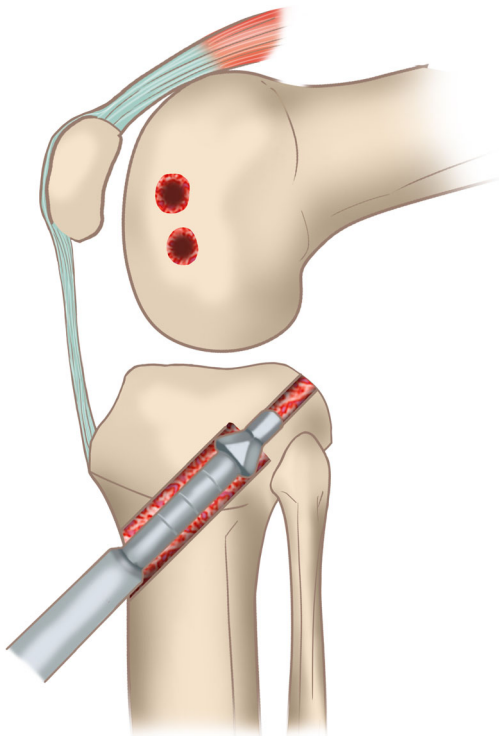
tendon bolt (tibial side) was a single beam and the end of the tendon (the femoral condyle side) was double bundled (Fig. 1).

#### *Construction of the 8-shaped Tibial Tunnel*

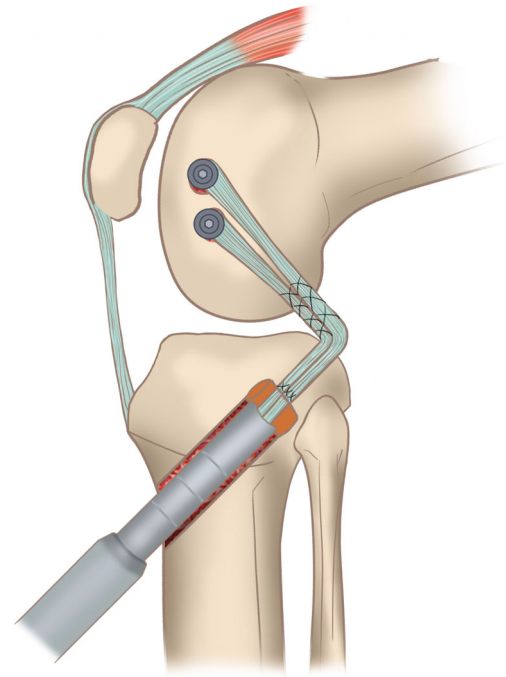
The PCL was exposed in the tibial insertion and placed with PCL tunnel locator (locator angle: 60°). The tip points to the tibia platform at 15 mm and the outer end points to 10 mm before the tibial stop of a medial knee ligament tibial bone. Then the needle was drilled into the tunnel locator, followed by a hollow drill expanding the tunnel to the back of the tibia. Moreover, the transverse “8” zigzag lateral groove (Fig. 2) was made by extending the tibia tunnel with two wings through the external entrance of the tibia tunnel. Lateral groove was 15 mm spacing and 8 mm width, which could accommodate the “spigot tendon pin” fixed body. The “8” character tunnel was based on the actual tibial tunnel, and 10 mm bone was retained in the rear wall of the tibial tunnel. The femoral condyle tunnel was made by outside-to-inside dual beam tunnel, and the bone between the tunnels was kept at 6 mm.

#### *Introduction and Immobilization of Tendon Pin*

The woven “tendon of pin” tendon graft was introduced through the front entrance of the tibia tunnel. Insert the bolt at the side of the “tendon bolt” into the groove of the “8” tibia tunnel. The U-shaped “tendon bolt” (Fig. 3) was used



**Fig 2** The transverse “8” zigzag lateral groove. Lateral groove is 15 mm spacing and the thin bone tunnel is 8 mm in width.



**Fig 3** The U-shaped “tendon bolt”, which is used to insert the “tendon bolt” fixation into the tibia 8-shaped tunnel.

to insert the “tendon bolt” fixation into the tibia 8-shaped tunnel. Finally, the end of PCL double tendon of the femoral side was fixed by extruding nail and door nail. Moreover, in order to reduce the phenomenon of “killer turn,” the tibial side was close to the PCL stop point. The whole operation was done by the same operator.

#### *Postoperative Management*

Patient was bandaged for 7 days by the full length elastic bandage of the lower extremity. The knee orthosis (KO) (Nanjing shule prosthetics and orthotics co. LTD, Nanjing, China) was used for outside immobilization (0° position) for 3 weeks. The KO in patient was intermittently removed with the help of knee flexion exercises (angle: 0°–60°, 30 min each time, two times a day). The isometric contraction of the four quadriceps and dorsiflexion of foot-plantar flexion exercises were performed 1 day after surgery. Then the knee flexion exercises were performed 3 weeks after surgery (angle: 0°–45°). Patients were given the full weight-bearing lower limb until knee flexion angle gradually to 90°. When KO was removed at 10 weeks, patients were able to walk for muscle-strength training and joint-activity training. Finally, the flexibility exercises and jogging were added to the patients’ rehabilitation training at 12–20 weeks.

#### *Outcome Measures*

The position and healing of embedded tendon pin were observed by X-ray of knee joint. The IKDC<sup>18</sup> assessment,

VAS pain score<sup>19</sup>, Lysholm score<sup>20</sup>, Tegner activity score<sup>21</sup>, PDT (negative/positive I/II/III)<sup>22</sup>, and tendon activity score measured by MEDmetric KT-1000 Arthrometer (MED metric Corporation, San Diego, CA)<sup>23</sup> were evaluated at the last time of follow-up.

#### *International Knee Documentation Committee (IKDC) Assessment*

The IKDC subjective evaluation form is a standardized international documentation system for knee surgery, which consists of 18 questions that stress the effects of symptoms, daily living activities, and sports activities on the knee. Meanwhile, this form also assesses total knee function on a converted scale from 0 to 100. A score of 100 represents the absence of symptoms and no limitation with activities of daily living or sports activities.

#### *Visual Analog Scale (VAS) Pain Score*

VAS is a subjective assessment tool used to measure the intensity of knee pain. VAS pain score ranges from 0 to 10 points. A score of 0 represents no pain and 10 indicates severe pain.

#### *Lysholm Score*

The Lysholm score is used to document outcomes after cruciate ligament injuries. The Lysholm score ranges from 0 to 100 points and is based on eight domains: pain, limp, stair-climbing, locking, support, swelling, instability, and squatting. A score of 95–100, 84–94, 65–83, and < 65 is considered to be excellent, good, fair, and poor.

#### *Tegner Activity Score*

The Tegner activity scale is a numerical scale ranging from an activity level from 0 to 10. A score of 0 indicates sick leave or disability pension due to knee problems, and 10 indicates competitive sports on a very high level.

#### *Posterior Drawer Test (PDT) Assessment*

PDT is the most sensitive diagnostic test for PCL injury. This test is performed with the knee flexed to 90° and a posteriorly directed force is applied to the proximal tibia. In a grade I injury, the tibia is still located anterior to the medial femoral condyle. The tibia can only be translated 0 to 5 mm posterior to the femoral condyle. In a grade II injury, the tibia is situated flush with the medial femoral condyle. The tibia can be translated 5 to 10 mm posterior to the femoral condyle. In a grade III injury, the tibia is displaced posterior to the medial femoral condyle. The tibia can be translated greater than 10 mm posterior to the femoral condyle.

#### *KT-1000 Arthrometer Test*

The KT-1000 examination was taken as a supplement to the manual PDT. The KT-1000 is an objective instrument to measure the antero-posterior tibial translation. The maximum manual displacement test with the KT-1000 arthrometer was performed by pushing the tibia posteriorly

before performing a maximum manual anterior drawer test with the knee flexed to 70°.

#### **Statistical Analysis**

Statistical analysis was performed using Statistical Package for the Social Sciences (SPSS, Chicago, IL, version: 19.0). Normality of continuous variables, including age, body mass index (BMI), injury duration before surgery, IKDC score, Lysholm score, VAS, Tegner activity score, and KT-1000 score were evaluated using One-Sample Kolmogorov–Smirnov Test. If  $P > 0.05$ , the data conform to normal distribution. The continuous variables were demonstrated in the form of range and mean  $\pm$  SD (standard deviation), and the differences between the two groups were compared: the paired  $t$ -test was used if data conform to normal distribution, otherwise, the nonparametric rank sum test (Mann–Whitney Test) was used. Repeated measures of variance were applied to the postoperative indicators. Chi-square test was used to compare the classification variables. If  $P < 0.05$ , the difference was statistically significant.

#### **Results**

##### **General Results**

All patients had swelling of the knee joint, the posterior drawer test (+) III degree, and MRI posterior cruciate ligament defect. A total of 17 patients had ACL image bending. Meanwhile, the eversion stress test, Lachman test, and dial test were positive in 15, 16, and two patients, respectively. MRI showed absence of posterior cruciate ligament image, flexion of anterior cruciate ligament image, and injury in some patients. There were nine cases of medial meniscus injury, 10 cases of lateral meniscus injury, two cases of posterolateral complex (PLC) injury, 16 cases of ACL injury, 15 cases of medial collateral ligament (MCL) injury, and 11 cases of meniscal suture. The detailed baseline and outcome information was shown in Table 1. All the 51 patients were followed up for 3 years. The operations in all patients were successful.

##### **Clinical Evaluation**

##### *International Knee Documentation Committee (IKDC) Score*

The preoperative, 1-year postoperative, and 3-year postoperative IKDC scores were  $15.8\% \pm 14.8\%$ ,  $89.6\% \pm 5.8\%$ , and  $86.8\% \pm 5.4\%$ , respectively (Table 2). Significant difference existed among them ( $F = 1197.36$ ,  $P < 0.0001$ , Table 2). Compared with that before surgery, the 1-year and 3-year postoperative KT-1000 scores were significantly increased by  $73.8\% \pm 12.90\%$  and  $71.0\% \pm 13.0\%$ , respectively..

##### *Visual Analog Scale (VAS) Pain Score*

The preoperative, 1-year postoperative, and 3-year postoperative VAS score was  $5.8 \pm 1.2$ ,  $1.3 \pm 0.5$ , and  $0.6 \pm 0.5$ , respectively, and remarkable difference existed among them

**TABLE 1** Baseline and outcome information for patients

Index	Median (range)	Mean ± SD	Frequency (n)	Percentage (%)
Age	44 (15, 74)	42.71 ± 11.93	-	-
BMI	24.80 (16.14, 34.72)	24.83 ± 2.92	-	-
Injury duration before surgery	17 (3, 225)	42.84 ± 51.50	-	-
Preoperative IKDC score	7.90% (1.15%, 54.02%)	15.84% ± 14.77%	-	-
Postoperative IKDC score	90.81% (70.12%, 97.70%)	89.44% ± 6.27%	-	-
Preoperative Lysholm score	14 (4, 47)	17.37 ± 10.68	-	-
Postoperative Lysholm score	91 (85, 97)	91.20 ± 2.79	-	-
Preoperative VAS score	6 (4, 8)	5.78 ± 1.21	-	-
5-day postoperative VAS score	1 (1, 2)	1.33 ± 0.48	-	-
Preoperative Tegner activity score	1 (0, 3)	1.20 ± 0.85	-	-
3-year postoperative Tegner activity score	7 (6, 9)	7.35 ± 0.82	-	-
Preoperative KT-1000 (mm)	15 (10, 28)	15.57 ± 3.61	-	-
1-year postoperative KT-1000 (mm) score	4 (1, 10)	4.55 ± 2.35	-	-
3-year postoperative KT-1000 (mm) score	5 (3, 11)	5.39 ± 1.75	-	-
Gender (male/female)	-	-	40/11	78.4/21.6
Knee (left/right)	-	-	20/31	39.2/60.8
Preoperative PDT (negative/positive I/II/III)	-	-	0/0/0/51	0/0/0/100
Postoperative PDT (negative/positive I/II/III)	-	-	31 /18/2/0	60.8/35.3/3.9/0

BMI, body mass index; IKDC, International Knee Documentation Committee; PDT, posterior drawer test; VAS, visual analogue scale/score.

**TABLE 2** The results of treatment outcome

	Preoperative	1-year Postoperative	3-year postoperative
IKDC score	15.8% ± 14.8%	89.6% ± 5.8%*	86.8% ± 5.4%*
Lysholm score	17.4 ± 10.7	91.2 ± 2.8*	88.2 ± 3.1*
VAS score	5.8 ± 1.2	1.3 ± 0.5*	0.6 ± 0.5*
Tegner activity score	1.2 ± 0.8	8.1 ± 0.8*	7.4 ± 0.8*
PDT (negative/positive I / II/III)	0/0/0/51	31/18/2/0*	26/20/5/0*

\* Indicated  $P < 0.0001$ , which was considered to be significant different compared to preoperative indicators.

( $F = 873.15$ ,  $P < 0.0001$ , Table 2). The 1-year and 3-year postoperative VAS scores were decreased by  $4.5 \pm 1.0$  and  $5.2 \pm 1.0$  compared to those before surgery.

#### Lysholm Score

The 1-year postoperative ( $91.2 \pm 2.8$ ) and 3-year postoperative ( $88.2 \pm 3.1$ ) Lysholm scores were all dramatically improved by  $73.8 \pm 9.6$  and  $70.8 \pm 9.5$  compared to those before operation ( $17.4 \pm 10.7$ ) (Table 2). There was significant difference among them ( $F = 2348.06$ ,  $P < 0.0001$ ).

#### Tegner Activity Score

Tegner activity scores after 1-year surgery ( $8.1 \pm 0.8$ ) and 3-year surgery ( $7.4 \pm 0.8$ ) were significantly increased by  $6.9 \pm 0.8$  and  $6.2 \pm 0.8$  compared with those before surgery ( $1.2 \pm 0.8$ ) (Table 2). Significant difference existed among them ( $F = 2047.43$ ,  $P < 0.0001$ ).

#### Posterior Drawer Test (PDT) Results

After 1-year surgery, 31 patients (60.8%) had a negative PDT, 18 (35.3%) had a positive I PDT, and two (4.9%) had a

positive II PDT (Table 2). After 3-year surgery, 26 patients (51.0%) had a negative PDT, 20 (39.2%) had a positive I PDT, and five (9.8%) had a positive II PDT (Table 2). There was remarkable difference in PDT results among different time points ( $\chi^2 = 113.63$ ,  $P < 0.0001$ ). These data indicated that the PCL injury of all patients was improved.

#### KT-1000 Score

There were significant differences in the KT-1000 score among preoperative ( $15.6 \pm 3.6$ ), 1-year postoperative ( $4.5 \pm 2.4$ ), and 3-year postoperative ( $5.4 \pm 1.8$ ) ( $F = 352.2$ ,  $P < 0.0001$ , Table 2) scores. The 1-year and 3-year postoperative KT-1000 score was decreased by  $11.1 \pm 3.2$  and  $10.2 \pm 3.1$  relative to that before surgery, respectively.

#### Complications

There were no postoperative complications. All incisions in patients were primary healing without infections. The suture was taken out at 12 days post operation. The knee flexions of all patients were more than  $90^\circ$ , and the straight degree was  $0^\circ$ . No joint stiffness was observed in all patients.

## Discussion

Although the tibial tunnel reconstruction is a classical technique for PCL in clinical treatment, the surgery effect for PCL injury patients is still not ideal<sup>24</sup>. In this study, a newly designed arthroscopic reconstruction of PCL with embedded tibial tendon bolt was evaluated. The results showed that the postoperative IKDC score, Lysholm score, VAS score, Tegner activity score, and KT-1000 score were significantly different preoperatively (all  $P < 0.0001$ ). A previous study of 21 patients with grade III PCL injuries treated with arthroscopic PCL reconstruction suggested that 75% had a normal/near-normal findings according to IKDC score after surgery<sup>25</sup>. In this paper, the 1-year postoperative and 3-year postoperative IKDC score of patients was  $89.6\% \pm 5.8\%$  and  $86.8\% \pm 5.4\%$ , which was higher than the previous report. It is reported that the preoperative and postoperative evaluation of patients treated with arthroscopically assisted PCL reconstruction showed that the mean Lysholm values were 51.8, and 90.9, respectively<sup>26</sup>, which were comparable to the results of our study ( $17.4 \pm 10.7$  vs  $91.2 \pm 2.8$  or  $88.2 \pm 3.1$ ). Besides, there were no complications in any of the patients in our study. All these suggested that the newly designed arthroscopic reconstruction of PCL with embedded tibial tendon bolt in our study was effective and safe for patients with PCL injury.

Reconstruction of tibial side fixation has been one of the key issues discussed by the majority of scholars<sup>27, 28</sup>. A previous study shows that different technique and fixation devices influence bone tunnel enlargement during the reconstruction of cruciate ligament with hamstrings<sup>29</sup>. Fanelli and Miller indicated that the wide-angle and low-order bone tunnel (1.2–1.5 cm articular surface) could avoid sharp corners by increasing bone angle between tunnel and graft<sup>30</sup>. Although modified operation on posterolateral corner and PCL can achieve knee stability, there are remaining abnormalities in range of motion, posterior drawer, and rotational laxity, suggesting that normal knee laxity is not restored<sup>31</sup>. Actually, it is difficult to ensure the precise location of the inner orifice of bone tunnel and the best bone tunnel direction at the same time during PCL reconstruction<sup>32</sup>. A previous study indicates that tendon junction embedded in the tunnel (the material in the junction is bone) can be constructed into a bottleneck like tunnel blockage, which effectively reduces the invalid fixed length of the tendon in the tunnel<sup>33</sup>. However, the material selection, repair, and compression resistance of the plug are limited. In this study, the body of the tendon pin bolt was an elliptical solid, formed by extrusion of the tendon. It was convenient to use materials that were simple to repair, of fixed size, with strong deformation resistance to pressure, and that could be fully integrated with bone in the long term. Meanwhile, the tendon pin fixed in the 8-shaped tibial tunnel could reduce the invalid fixation distance of tendon body in tunnel, which further avoided the “wiper effect” and “bungee effect.” Furthermore, commonly, the

diameter of transplanted tendons is smaller than the diameter of tunnels<sup>34</sup>. Thus, every movement of the joints causes tiny movements between the tendons and bones. In the present study, a tight stopper was formed on the base of the tendon and the outlet of the tibial tunnel, which further closed the pore traffic in the joint cavity and the tunnel. Meanwhile, the tendon bolt was close to the posterior wall of the tibial tunnel, which further reduced the corner of the tendon base and appearance of the “killer turn” effect.

In the process of PCL reconstruction, the diameter and length of an effective intra-articular tendon graft is the basis for providing internal biomechanical support for the knee joint<sup>35, 36</sup>. Autologous tendons of Asian race are rather slender, and cannot be effectively woven into suitable tendon graft during PCL reconstruction. It is also a result of the long-term effect of reduction after PCL reconstruction<sup>37, 38</sup>. In this study, the gracilis and semitendinosus tendons were folded three times to increase the diameter of the tendon graft. The tendon pin could reduce the invalid length of the tendon graft in the tunnel, and increase the effective length of the tendon graft, which meets the mechanical requirements of PCL reconstruction.

There are some limitations to this study. Firstly, the tibial side tunnel is large. The tunnel should be constructed by core drill and the bone substance should be stored or used for backfilling the tunnel. Secondly, there was no comparative group and the postoperative imagings such as X-rays and MRI were insufficient. Furthermore, there is lack of longer-term outcomes. Thus, further studies with large sample sizes are needed in the future.

## Conclusion

In conclusion, the application of tendon pin fixed by tibial inlay 8-shaped tibial tunnel to reconstruct PCL was an effective, simple, and safe surgical procedure for PCL injury.

## Acknowledgement

None.

## Declarations

### Ethics Approval and Consent to Participate

This study was approved by Ethics Committee of the Fourth Affiliated Hospital of Harbin Medical University and Heilongjiang Academy of Medical Sciences.

### Consent for Publication

Not applicable.

### Availability of Supporting Data

Not applicable. This study was only the primary research, and further study is in progress.

### Competing Interests

The authors declare that they have no competing interests.

**Authors' Contributions**

Conception and design of the research: DFL; Acquisition of data: HZL; Analysis and interpretation of data: YJL; Statistical analysis: ZTZ; Obtaining funding: DFL; Drafting the

manuscript: CY; Revision of manuscript for important intellectual content: HZL. All authors read and approved the final manuscript.

**References**

1. Amis AA, Gupta CM, Bull AM, Edwards A. Anatomy of the posterior cruciate ligament and the meniscomemor ligaments. *Knee Surg Sports Traumatol Arthrosc*, 2006, 14: 257–263.
2. Sanders TL, Pareek A, Barrett IJ, et al. Incidence and long-term follow-up of isolated posterior cruciate ligament tears. *Knee Surg Sports Traumatol Arthrosc*, 2017, 25: 3017–3023.
3. Chen W, Luo W, Chen Z, Jiang Y. Treatment of posterior cruciate ligament avulsion fractures of the tibia using a toothed plate and hollow lag screw. *Singap Med J*, 2016, 57: 39–44.
4. Jung TM, Höher J, Weiler A. Screw fixation of a 4 1/2-year-old PCL avulsion injury. *Knee Surg Sports Traumatol Arthrosc*, 2006, 14: 469–472.
5. Logan M, Williams A, Lavelle J, Gedroyc W, Freeman M. The effect of posterior cruciate ligament deficiency on knee kinematics. *Am J Sports Med*, 2004, 32: 1915–1992.
6. Wind WM Jr, Bergfeld JA, Parker RD. Evaluation and treatment of posterior cruciate ligament injuries: revisited. *Am J Sports Med*, 2004, 32: 1765–1775.
7. Griffin LY, Albohm MJ, Arendt EA, et al. Understanding and preventing noncontact anterior cruciate ligament injuries: a review of the Hunt Valley II meeting, January 2005. *Am J Sports Med*, 2006, 34: 1512–1532.
8. Voos JE, Mauro CS, Wentz T, Warren RF, Wickiewicz TL. Posterior cruciate ligament: anatomy, biomechanics, and outcomes. *Am J Sports Med*, 2012, 40: 222–231.
9. Bhatia S, Korth K, Van Thiel GS, et al. Effect of tibial tunnel diameter on femoral tunnel placement in transtibial single bundle ACL reconstruction. *Knee Surg Sports Traumatol Arthrosc*, 2016, 24: 1–7.
10. Nicodeme J-D, Löcherbach C, Jolles B. Tibial tunnel placement in posterior cruciate ligament reconstruction: a systematic review. *Knee Surg Sports Traumatol Arthrosc*, 2014, 22: 1556–1562.
11. Feucht MJ, Cotic M, Saier T, et al. Patient expectations of primary and revision anterior cruciate ligament reconstruction. *Knee Surg Sports Traumatol Arthrosc*, 2016, 24: 201–207.
12. Loh JC, Fukuda Y, Tsuda E, Steadman RJ, Fu FH, Woo SL. Knee stability and graft function following anterior cruciate ligament reconstruction: comparison between 11 o'clock and 10 o'clock femoral tunnel placement. 2002 Richard O'Connor Award Paper. *Arthroscopy*, 2003, 19: 297–304.
13. Goyal A, Tanwar M, Joshi D, Chaudhary D. Practice guidelines for the management of multiligamentous injuries of the knee. *Indian J Orthop*, 2017, 51: 537–544.
14. Weimann A, Wolfert A, Zantop T, Eggers A-K, Raschke M, Petersen W. Reducing the “killer turn” in posterior cruciate ligament reconstruction by fixation level and smoothing the tibial aperture. *Arthroscopy*, 2007, 23: 1104–1111.
15. Huang T-W, Wang C-J, Weng L-H, Chan Y-S. Reducing the “killer turn” in posterior cruciate ligament reconstruction. *Arthroscopy*, 2003, 19: 712–716.
16. Noyes FR, Barber-Westin SD. Posterior cruciate ligament revision reconstruction, part 1: causes of surgical failure in 52 consecutive operations. *Am J Sports Med*, 2005, 33: 646–654.
17. Fanelli GC, Edson CJ. Combined posterior cruciate ligament-posterolateral reconstructions with Achilles tendon allograft and biceps femoris tendon tenodesis: 2- to 10-year follow-up. *Arthroscopy*, 2004, 20: 339–345.
18. Anderson AF, Irgang JJ, Kocher MS, Mann BJ, Harrast JJ, Committee IKD. The international knee documentation Committee subjective knee evaluation form: normative data. *Am J Sports Med*, 2006, 34: 128–135.
19. Burckhardt CS, Jones KD. Adult measures of pain: the McGill pain questionnaire (MPQ), rheumatoid arthritis pain scale (RAPS), short-form mcgill pain questionnaire (SF-MPQ), verbal descriptive scale (VDS), visual analog scale (VAS), and west haven-yale multidisciplinary pain inventory (WHYMPI). *Arthritis Care Res*, 2003, 49: S96–S104.
20. Lysholm J, Gillquist J. Evaluation of knee ligament surgery results with special emphasis on use of a scoring scale. *Am J Sports Med*, 1982, 10: 150–154.
21. Tegner Y, Lysholm J. Rating systems in the evaluation of knee ligament injuries. *Clin Orthop Relat Res*, 1985, 198: 43–49.
22. Hughston JC, Norwood JL. The posterolateral drawer test and external rotational recurvatum test for posterolateral rotatory instability of the knee. *Clin Orthop Relat Res*, 1980, 147: 82–87.
23. Tyler TF, McHugh MP, Gleim GW, Nicholas SJ. Association of KT-1000 measurements with clinical tests of knee stability 1 year following anterior cruciate ligament reconstruction. *J Orthop Sports Phys Ther*, 1999, 29: 540–545.
24. Konan S, Haddad FS. The unpredictable material properties of bioabsorbable PLC interference screws and their adverse effects in ACL reconstruction surgery. *Knee Surg Sports Traumatol Arthrosc*, 2009, 17: 293–297.
25. Sekiya JK, West RV, Ong BC, Irgang JJ, Fu FH, Harner CD. Clinical outcomes after isolated arthroscopic single-bundle posterior cruciate ligament reconstruction. *Arthroscopy*, 2005, 21: 1042–1050.
26. Fanelli GC, Giannotti BF, Edson CJ. Arthroscopically assisted combined posterior cruciate ligament/posterior lateral complex reconstruction. *Arthroscopy*, 1996, 12: 521–530.
27. Jaber FM, Abbasi H, Saki N, et al. A modification of tibial inlay fixation in posterior cruciate ligament reconstruction by interference screw: a biomedical study on calf tibial bone model. *Arch Orthop Trauma Surg*, 2010, 130: 1065–1069.
28. Ahn JH, Lee YS, Choi S-H, Chang MJ, Lee DK. Single-bundle transtibial posterior cruciate ligament reconstruction using a bioabsorbable cross-pin tibial back side fixation. *Knee Surg Sports Traumatol Arthrosc*, 2013, 21: 1023–1028.
29. Iorio R, Di SV, Vadalà A, et al. ACL reconstruction with hamstrings: how different technique and fixation devices influence bone tunnel enlargement. *Eur Rev Med Pharmacol Sci*, 2013, 17: 2956.
30. Johnson DH, Fanelli GC, Miller MD. PCL 2002: indications, double-bundle versus inlay technique and revision surgery. *Arthroscopy*, 2002, 18: 40–52.
31. Zorzi C, Alam M, Iacono V, Madonna V, Rosa D, Maffulli N. Combined PCL and PLC reconstruction in chronic posterolateral instability. *Knee Surg Sports Traumatol Arthrosc*, 2013, 21: 1036–1042.
32. Ettinger M, Wehrhahn T, Petri M, et al. The fixation strength of tibial PCL press-fit reconstructions. *Knee Surg Sports Traumatol Arthrosc*, 2012, 20: 308–314.
33. Paessler HH, Mastrokalos DS. Anterior cruciate ligament reconstruction using semitendinosus and gracilis tendons, bone patellar tendon, or quadriceps tendon-graft with press-fit fixation without hardware. A new and innovative procedure. *Orthop Clin North Am*, 2003, 34: 49–64.
34. Xu X, Huang T, Liu Z, et al. Hamstring tendon autograft versus LARS artificial ligament for arthroscopic posterior cruciate ligament reconstruction in a long-term follow-up. *Arch Orthop Trauma Surg*, 2014, 134: 1753–1759.
35. Chan Y-S, Yang S-C, Chang C-H, et al. Arthroscopic reconstruction of the posterior cruciate ligament with use of a quadruple hamstring tendon graft with 3-to 5-year follow-up. *Arthroscopy*, 2006, 22: 762–770.
36. Li B, J-s W, He M, G-b W, Shen P, Bai L-h. Comparison of hamstring tendon autograft and tibialis anterior allograft in arthroscopic transtibial single-bundle posterior cruciate ligament reconstruction. *Knee Surg Sports Traumatol Arthrosc*, 2015, 23: 3077–3084.
37. Weiler A, Hoffmann RF, Bail HJ, Rehm O, Südkamp NP. Tendon healing in a bone tunnel. Part II: histologic analysis after biodegradable interference fit fixation in a model of anterior cruciate ligament reconstruction in sheep. *Arthroscopy*, 2002, 18: 124–135.
38. Daifeng Lu MX, Lian Y, Zhou Y, Liu X. Comparison of the operation of arthroscopic tibial inlay and traditional tibial inlay for posterior cruciate ligament reconstruction. *Int J Clin Exp Med*, 2014, 7: 3193.