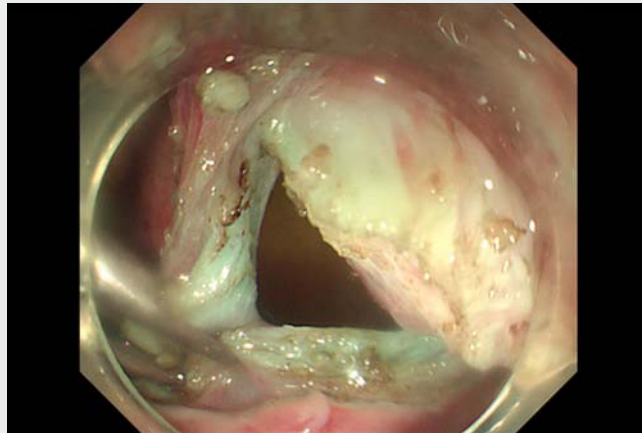
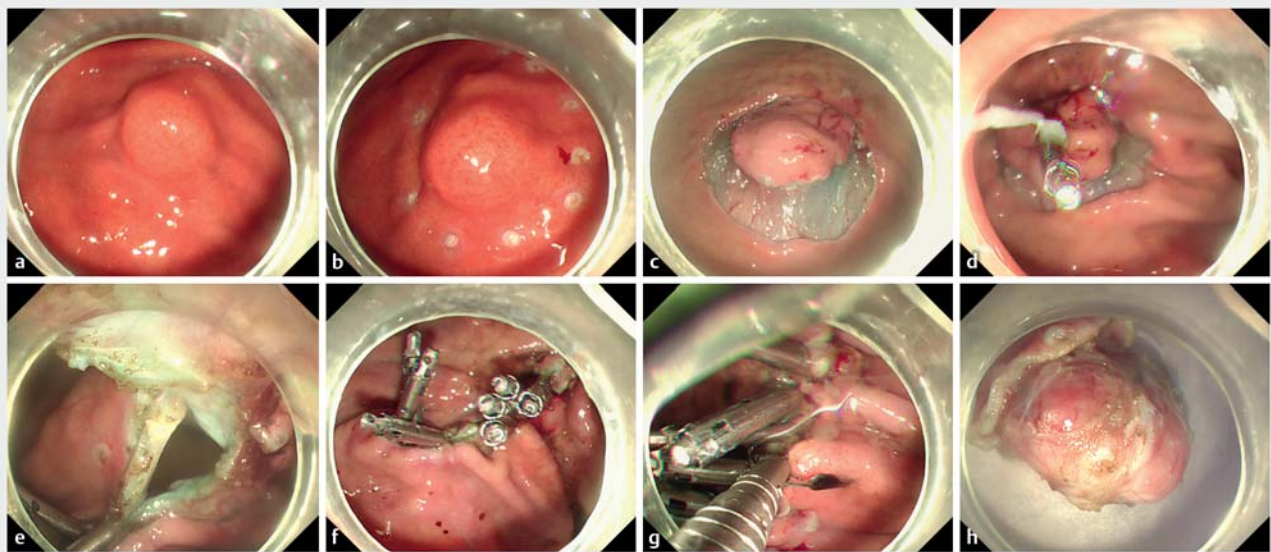


A modified endoscopic full-thickness resection for gastrointestinal stromal tumors: A new closure technique based on the instruction of super minimally invasive surgery

Endoscopic resection, including endoscopic submucosal excavation (ESE) and endoscopic full-thickness resection (EFTR), is an effective and safe method for gastrointestinal stromal tumors (GISTs). While during traditional EFTR, closure of the defect using a loop-and-clip closure technique or just clips always follows the full-thickness resection, this usually results in the occurrence of gas-related complications, such as pneumoperitoneum [1,2]. What is more, it is time-consuming and not easy to perform for some lesions larger than 2.0 cm. In this study, we performed a modified EFTR, whereby a full-thickness resection and closure of the defect were performed simultaneously until the lesion was completely removed (► **Video 1**). Conse-



► **Video 1** A modified endoscopic full-thickness resection for gastrointestinal stromal tumors.



► **Fig. 1** The procedure of modified endoscopic full-thickness resection for gastrointestinal stromal tumor (GIST). **a** The feature of the GIST was revealed under white light endoscopy. **b** The margin of the GIST was marked by argon plasma coagulation. **c** A circumferential submucosal incision was performed to adequately expose the lesion. **d** A clip was fixed to the surface of the lesion. **e** Full-thickness resection was performed to resect the lesion. **f** Clips were used to close the submucosal layer of the defect at the same time until the lesion was completely removed. **g** The GIST was completely resected and the submucosal layer of the defect was sutured. **h** Other clips were used to close the mucosal layer. **h** The morphology of the GIST was shown under white light.

quently, both operating time and gas flowing into intraperitoneal cavity were reduced. In addition, the demix suture method was another innovation closure method based on the instruction of super minimally invasive surgery, which means the suture of the first layer during lesion resection was the closure of the submucosal layer. After removal of the lesion, other clips were used to close the mucosal layer for preserving the integrity of the gastric anatomy and full closure of the defect (► **Fig. 1**)

First the margin of the lesion was marked by argon plasma coagulation (APC) (► **Fig. 1 b**). Then sufficient submucosal injection was conducted to separate the mucosal and submucosal layer. Next, a circumferential submucosal incision was performed to adequately expose the lesion (► **Fig. 1 c**). A clip was then fixed to the surface of the lesion, attaining full traction of the lesion (► **Fig. 1 d**). Full-thickness resection was performed to resect the lesion, and clips were used to close the defect at the same time until the lesion was completely removed (► **Fig. 1 e, f**). Finally, the defect was sutured for a second time with clips (► **Fig. 1 g**).

This study first proposes a modified EFTR that is time-saving and decreases gas-related complications. On the whole, it is worthy of clinical promotion, and prospective studies are needed to obtain much more reliable evidence.

Endoscopy_UCTN_Code_TTT_1AO_2AC

Competing interests

The authors declare that they have no conflict of interest.

The authors

Xiao Li^{*}, Wengang Zhang^{*}, Fei Gao, Hao Dong, Jiafeng Wang, Ningli Chai, Enqiang Linghu

Department of Gastroenterology, The First Medical Center of Chinese PLA General Hospital, Beijing, China

Corresponding author

Enqiang Linghu, MD

Department of Gastroenterology, The First Medical Center of Chinese PLA General Hospital, 28 Fuxing Road, Haidian District, Beijing, 100853, China
linghuenqiang@vip.sina.com

References

- [1] Li B, Chen T, Qi ZP et al. Efficacy and safety of endoscopic resection for small submucosal tumors originating from the muscularis propria layer in the gastric fundus. *Surg Endosc* 2019; 33: 2553–2561
- [2] Aslanian HR, Sethi A, Bhutani MS et al. ASGE guideline for endoscopic full-thickness resection and submucosal tunnel endoscopic resection. *VideoGIE* 2019; 4: 343–350

Bibliography

Endoscopy 2023; 55: E561–E562

DOI 10.1055/a-2040-3927

ISSN 0013-726X

© 2023. The Author(s).

This is an open access article published by Thieme under the terms of the Creative Commons Attribution-NonDerivative-NonCommercial License, permitting copying and reproduction so long as the original work is given appropriate credit. Contents may not be used for commercial purposes, or adapted, remixed, transformed or built upon. (<https://creativecommons.org/licenses/by-nc-nd/4.0/>)

Georg Thieme Verlag KG, Rüdigerstraße 14, 70469 Stuttgart, Germany



ENDOSCOPY E-VIDEOS

<https://eref.thieme.de/e-videos>



Endoscopy E-Videos is an open access online section, reporting on interesting cases and new techniques in gastroenterological endoscopy. All papers include a high quality video and all contributions are freely accessible online. Processing charges apply, discounts and waivers acc. to HINARI are available.

This section has its own submission website at
<https://mc.manuscriptcentral.com/e-videos>

* Co-first authors.