

[CASE REPORT]

Tamoxifen-induced Lung Injury

Satoshi Etori¹, Ryoji Nakano¹, Hideki Kamada², Keisuke Hosokawa¹, Shinichi Takeda¹,
Masanori Fukuhara¹, Yoshiyuki Kenmotsu¹, Atsushi Ishimine¹ and Kumiko Sato¹

Abstract:

Cases of drug-induced lung injury caused by tamoxifen are rare. A 74-year-old man underwent surgery for the treatment of right breast cancer; tamoxifen was administered as an adjuvant therapy after surgery. The patient developed cough and dyspnea and chest computed tomography showed ground glass opacification in the lower lobe of the right lung. He was diagnosed with tamoxifen-induced lung injury. The diagnosis was made based on the exclusion of other causes and recurrence with the re-administration of tamoxifen. Physicians should therefore be aware of the potential for the development of tamoxifen-induced lung injury.

Key words: tamoxifen, breast cancer, drug-induced lung injury

(Intern Med 56: 2903-2906, 2017)

(DOI: 10.2169/internalmedicine.8649-16)

Introduction

Tamoxifen is an antiestrogen agent with proven efficacy in the treatment of breast cancer. The major side effects of tamoxifen are menopausal symptoms. Rare but serious toxicities include an increased risk of endometrial cancer and thromboembolism (1, 2). The development of drug-induced lung injury is a very rare side effect of tamoxifen (3). We herein report a case of drug-induced lung injury caused by tamoxifen.

Case Report

A 74-year-old Japanese man underwent surgery for the treatment of right breast cancer in early December 2015. The tumor was diagnosed as stage IIA papillotubular carcinoma (T1N1M0). The tumor was positive for both estrogen receptor (ER) and progesterone receptor (PgR).

After surgery, he was started on tamoxifen (20 mg/daily) as an adjuvant therapy. Three months later, he visited our hospital with a mild cough. Chest computed tomography (CT) revealed mild ground glass opacification in the lower lobe of the right lung (Fig. 1A). We suspected that the patient had infectious pneumonia or drug-induced lung injury. Because his symptoms were minor, and the imaging findings were mild, we decided to stop tamoxifen and observe his

progress without medication. After stopping tamoxifen, the chest CT findings showed improvement (Fig. 1B). Because tamoxifen could not be confirmed as the source of the findings, the administration of tamoxifen was resumed.

Two months later, the patient visited our hospital complaining of cough and dyspnea on exertion. He was hospitalized to undergo a detailed examination. His initial vital signs on admission were as follows: temperature, 36.2°C; respiratory rate, 16 breaths/minute; and oxygen saturation on room air, 93%. A physical examination revealed fine crackles in the right lower lung fields. His laboratory test results were as follows: white blood cell (WBC) count, 5,380/ μ L; neutrophil count, 3,570/ μ L; serum lactate dehydrogenase (LDH) level, 180 U/L (normal: 115 to 245 U/L); serum C-reactive protein (CRP) level, 0.06 mg/dl (normal: >0.3 mg/dL); Krebs von den Lungen-6 (KL-6) level, 4,790 IU/L (normal: >500 IU/L); surfactant protein-D (SP-D) level, 167 ng/mL (normal: >110 ng/mL). The patient's blood cultures were negative, and urinary antigens of *Streptococcus pneumoniae* and *Legionella pneumoniae* were not detected. The patient was negative for antinuclear antibodies and rheumatoid factor and his β -D-glucan levels were normal. A chest X-ray showed reticular shadows at the right lower zone (Fig. 1D). Chest CT showed ground glass opacification and mosaic perfusion in the lower lobe of the right lung, without consolidation, traction bronchiectasis, or architectural distortion (Fig. 1C). We performed bronchoalveolar lavage and a

¹Department of Respiratory Medicine, Kin-i-Kyo Chuo Hospital, Japan and ²Department of Surgery, Kin-i-Kyo Chuo Hospital, Japan
Received: December 6, 2016; Accepted: March 13, 2017; Advance Publication by J-STAGE: September 25, 2017
Correspondence to Dr. Satoshi Etori, etori.satoshi@gmail.com

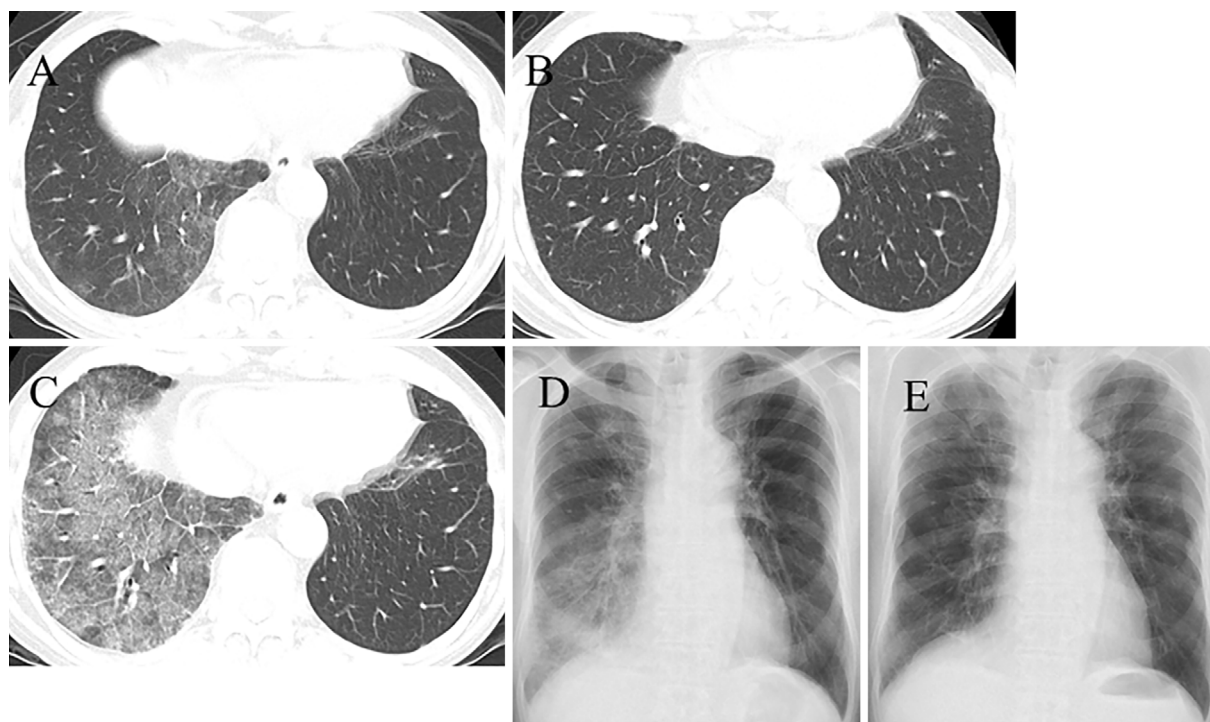


Figure 1. The radiological findings. (A) Chest CT performed after three months of medication showed mild ground-glass opacification in the lower lobe of the right lung. (B) Chest CT performed 14 days after stopping the drug showed the improvement of the ground-glass opacity. (C) Chest CT performed on admission showed ground-glass opacification and mosaic perfusion in the lower lobe of the right lung. (D) Chest X-ray performed on admission showed reticular shadows in the right lower zone. (E) Chest X-ray performed 11 days after the initiation of steroid therapy showed improvements in the reticular shadows.

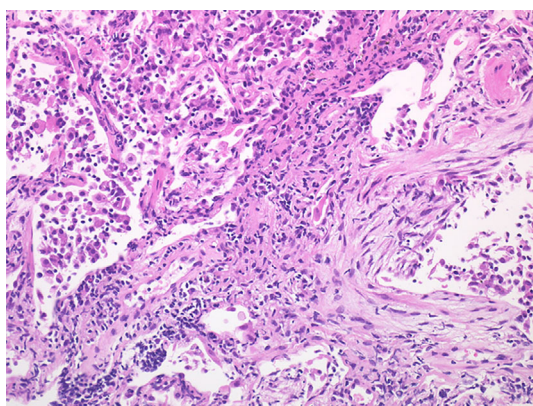


Figure 2. Transbronchial lung biopsy specimens showed interstitial fibrosis associated with lymphocytic infiltration, and the proliferation of fibroblasts. Hematoxylin and Eosin staining ($\times 200$).

transbronchial lung biopsy from the right B⁸. The total cell count and lymphocytes in his bronchoalveolar lavage fluid (BALF) were elevated ($4.4 \times 10^5/\text{mL}$ and 89%, respectively). The patient's BALF culture was negative. The BALF cytology was class I. Transbronchial lung biopsy specimens showed interstitial fibrosis associated with lymphocytic infiltration, and the proliferation of fibroblasts (Fig. 2). A drug lymphocyte stimulation test (DLST) of the peripheral blood

was positive for tamoxifen (stimulation index: 258%).

Based on the above findings, the patient was diagnosed with tamoxifen-induced lung injury.

We stopped tamoxifen and observed the patient's progress; however, the dyspnea on exertion worsened, the chest radiography findings did not improve, and the oxygen saturation on room air declined. We therefore determined that steroids were needed. The oral administration of prednisolone (25 mg) was initiated. Thereafter, his chest radiography findings showed a dramatic improvement (Fig. 1E). The patient's clinical course is shown in Fig. 3.

Discussion

We reported a case of tamoxifen-induced lung injury in a patient who had undergone surgery for the treatment of breast cancer. In this case, the diagnosis of drug-induced lung injury was made based on the exclusion of all other possible cause and the recurrence of symptoms with the re-institution tamoxifen. Recurrence with rechallenge is central to the diagnosis of drug-induced lung injury; however, this carries an intrinsic risk of severe pulmonary toxicity (4). After obtaining his informed consent, the patient was rechallenged for two reasons: stopping tamoxifen increases the risk of breast cancer recurrence; and no alternative endocrine therapy has been established for male breast cancer pa-

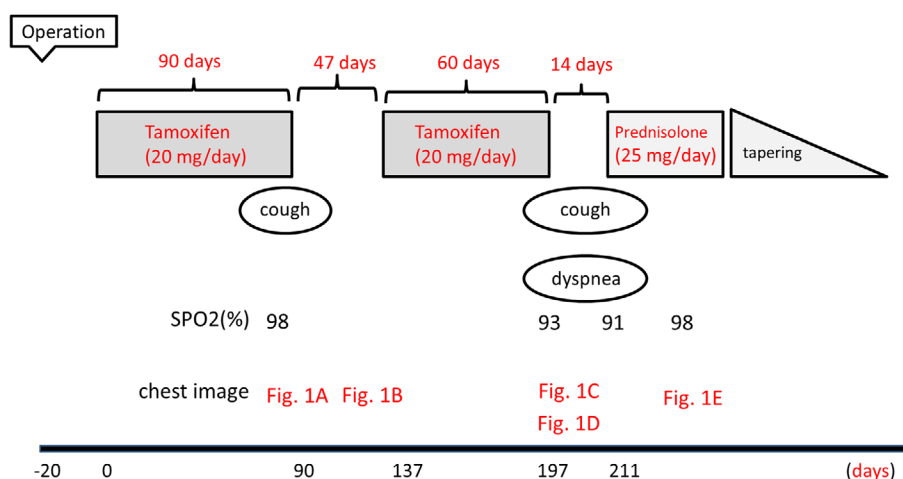


Figure 3. The clinical course of the present case.

tients. In addition, the lung injury was mild, and tamoxifen could not be confirmed as the source of the findings.

Bentzen et al. identified tamoxifen as a risk factor for radiotherapy-related lung fibrosis (5). Katayama et al. found that concurrent endocrine therapy can promote the development of radiation-induced bronchiolitis obliterans organizing pneumonia after breast-conserving therapy (6). A case of tamoxifen-induced lung injury was reported in Japan in a patient who had received radiation therapy (7). However, reports of tamoxifen-induced lung injury without radiation therapy are rare. Indeed, to the best of our knowledge, the only other published case report is a report by Ahmed et al. (8).

Our case shows that tamoxifen can cause drug-induced lung injury without radiation therapy.

The imaging findings of drug-induced lung injury are typically bilateral; thus, the presence of unilateral imaging findings prompted us to consider the possibility of infectious pneumonia (9, 10). In this case, the BALF culture was negative, and the patient recovered without receiving antimicrobial drugs. Thus, infectious pneumonia was not likely to have caused the patient's condition. Although the mechanism is unknown, our case showed that tamoxifen-induced lung injury can present unilaterally. The imaging patterns of drug-induced lung injury are classified according to the pattern of idiopathic interstitial pneumonias or well-known lung diseases (9, 11). The CT findings of our case showed ground glass opacity and mosaic perfusion but no consolidation, traction bronchiectasis, or architectural distortion. This pattern seemed to be similar to that of hypersensitivity pneumonitis (12, 13).

Based on the imaging pattern, an allergic reaction may have caused the drug-induced lung injury in the present case. Further reports should be accumulated to clarify the characteristic imaging findings and the mechanism that underlies the development of tamoxifen-induced lung injury.

Physicians should therefore be aware of the potential for the development of drug-induced lung injury after treatment with tamoxifen.

The authors state that they have no Conflict of Interest (COI).

References

- Osborne CK. Tamoxifen in the treatment of breast cancer. *N Engl J Med* **339**: 1609-1618, 1998.
- Pemmaraju N, Munsell MF, Hortobagyi GN, Giordano SH. Retrospective review of male breast cancer patients: analysis of tamoxifen-related side-effects. *Ann Oncol* **23**: 1471-1474, 2012.
- Pneumotox[®] [internet]. [cited 2016 Aug. 1]. Available from: www.pneumotox.com
- Camus P, Fanton A, Bonniaud P, Camus C, Foucher P. Interstitial lung disease induced by drugs and radiation. *Respiration* **71**: 301-326, 2004.
- Bentzen SM, Skoczylas JZ, Overgaard M, Overgaard J. Radiotherapy-related lung fibrosis enhanced by tamoxifen. *J Natl Cancer Inst* **88**: 918-922, 1996.
- Katayama N, Sato S, Katsui K, et al. Analysis of factors associated with radiation-induced bronchiolitis obliterans organizing pneumonia syndrome after breast-conserving therapy. *Int J Radiat Oncol Biol Phys* **73**: 1049-1054, 2009.
- Shiiki S. A case of drug-induced pneumonia due to tamoxifen. *Nihon Rinsho Geka Gakkai Zasshi (J Jpn Surg Assoc)* **64**: 3040-3043, 2003 (in Japanese, Abstract in English).
- Ahmed S, Shahid RK. Acute interstitial pneumonitis following adjuvant tamoxifen therapy. *J Clin Oncol* **27**: 2009 (suppl; abstr e11637).
- Rossi SE, Erasmus JJ, McAdams HP, et al. Pulmonary drug toxicity: radiologic and pathologic manifestations. *Radiographics* **20**: 1245-1259, 2000.
- Franks TJ, Galvin JR. Hypersensitivity Pneumonitis: Essential Radiologic and Pathologic Findings. *Surg Pathol Clin* **3**: 187-198, 2010.
- Kubo K, Azuma A, Kanazawa M, et al. Diagnostic procedure and differential diagnosis for drug-induced lung injury. In: Consensus Statement for the Diagnosis and Treatment of Drug-induced Lung Injuries. 1st ed. The Japanese Respiratory Society Committee for formulation of Consensus statement for the diagnosis and treatment of drug-induced lung injuries, Ed. The Japanese Respiratory Society, Tokyo, 2012: 12-35 (in Japanese).
- Hansell DM, Wells AU, Padley SP, et al. Hypersensitivity pneumonitis: correlation of individual CT patterns with functional abnormalities. *Radiology* **199**: 123-128, 1996.
- Small JH, Flower CD, Traill ZC, et al. Air-trapping in extrinsic allergic alveolitis on computed tomography. *Clin Radiol* **51**: 684-

688, 1996.

The Internal Medicine is an Open Access article distributed under the Creative

Commons Attribution-NonCommercial-NoDerivatives 4.0 International License. To view the details of this license, please visit (<https://creativecommons.org/licenses/by-nc-nd/4.0/>).

© 2017 The Japanese Society of Internal Medicine
Intern Med 56: 2903-2906, 2017