

CORRECTION

Open Access



Correction to: Early postoperative complications of bone filling in curettage defects

Clark J. Chen^{1*} and Earl W. Brien²

Correction to: J Orthop Surg Res (2019) 14: 261
<https://doi.org/10.1186/s13018-019-1297-4>

In the original publication of this article [1], there was a mistake in Fig. 2. Figure 2a and c should be swapped. The revised Fig. 2 is shown below.

The authors sincerely apologize for the inconvenience caused to the readers.

Author details

¹Miller School of Medicine, University of Miami, Miami, FL 33136, USA.

²Department of Orthopaedic Surgery, Cedars Sinai Medical Center, Los Angeles, CA 90048, USA.

Published online: 28 October 2019

Reference

1. Chen CJ, Brien EW. Early postoperative complications of bone filling in curettage defects. *J Orthop Surg Res.* 2019;14:261. <https://doi.org/10.1186/s13018-019-1297-4>.

* Correspondence: cjc217@med.miami.edu

The original article can be found online at <https://doi.org/10.1186/s13018-019-1297-4>

¹Miller School of Medicine, University of Miami, Miami, FL 33136, USA

Full list of author information is available at the end of the article



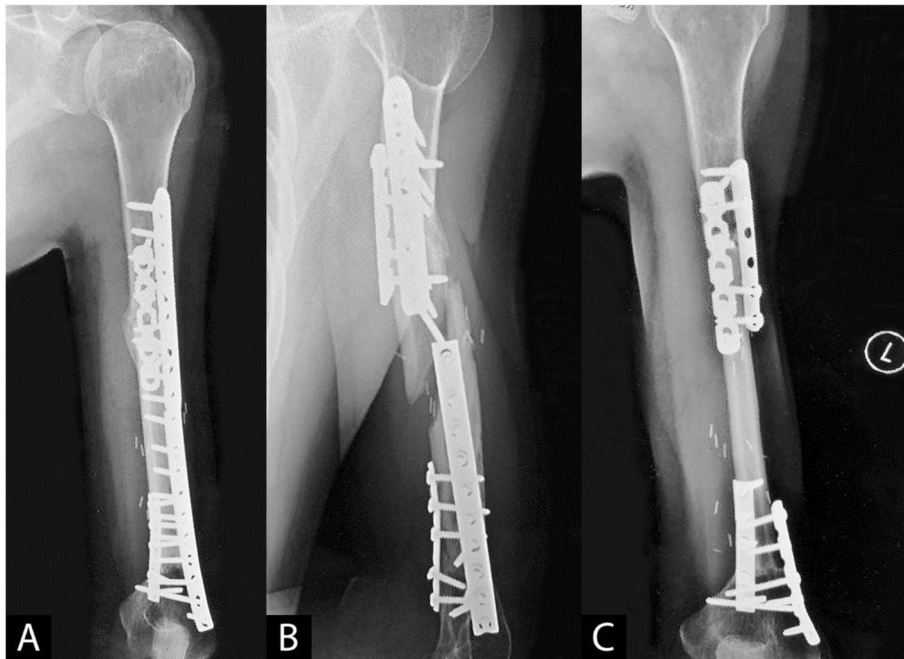


Fig. 2 a-c Ewing's sarcoma of the left humerus treated with chemotherapy, radiation, and resection. **a** Bulk allograft reconstruction showing ventral healing. **b** Fifteen years later, the patient suffered a fracture in his allograft from a twisting maneuver. **c** Because of the avascular central portion of the allograft, vascularized fibular autograft reconstruction was chosen, which healed well