

CASE REPORT



## Atypical manifestations of sarcoidosis in a Hispanic male

Bao Ho<sup>a,b</sup>, Kristal S. Choi<sup>b,c,d</sup>, William Ochoa<sup>a,b</sup>, Karina D. Torralba<sup>a,b,c,d</sup>, Vaneet K. Sandhu<sup>a,b,c,d</sup> and Zahra Pakbaz<sup>a,b,d,e</sup>

<sup>a</sup>Department of Internal Medicine, University of California, Riverside, School of Medicine, Riverside, CA, USA; <sup>b</sup>Department of Internal Medicine, Riverside University Health System Medical Center, Moreno Valley, CA, USA; <sup>c</sup>Division of Rheumatology, Loma Linda University, School of Medicine, Loma Linda, CA, USA; <sup>d</sup>Department of Medicine, Loma Linda University, School of Medicine, Loma Linda, CA, USA; <sup>e</sup>Hematology, Riverside University Health System Medical Center, Moreno Valley, CA, USA

### ABSTRACT

Sarcoidosis is a multisystem granulomatous disease of unknown etiology that can present with nonspecific features, often resulting in delayed diagnosis. The diagnosis requires the demonstration of non-caseating granulomas on biopsy. While the prevalence of sarcoidosis in the USA is rare, the disease is rarer yet in Hispanics. It is for this reason that we report herein the case of a Hispanic gentleman with a unique clinical manifestations of sarcoidosis. With what began as a two-month history of joint pain and skin rash, this 55-year-old man was hospitalized with multiple joint pain, weight loss, fatigue and a pruritic rash with leonine facies in the setting of anemia, leukopenia, hypercalcemia, elevated serum creatinine, and urine Bence-Jones proteinuria. CT imaging of the chest was nonspecific, but skin biopsy revealed non-caseating granulomatous disease. After completing an infectious and malignancy evaluation, the patient was diagnosed with sarcoidosis, which was treated successfully with low-dose steroid therapy.

### ARTICLE HISTORY

Received 8 October 2018  
Accepted 9 April 2019

### KEYWORDS

Sarcoidosis; hypercalcemia; non-caseating granulomas; leonine facies; nephrocalcinosis

## 1. Introduction

Sarcoidosis is a multisystem granulomatous disease of unknown etiology that can present with nonspecific features, often resulting in delayed diagnosis [1]. The diagnosis requires the presence of non-caseating granulomas on biopsy. While sarcoidosis occurs worldwide and affects all ages and races, the incidence and prevalence in the USA is rare in Hispanics (4.3 and 21.7 per 100,000, respectively) as compared to African-Americans (17.8 and 141.4 per 100,000, respectively) and Caucasians (8.1 and 49.8 per 100,000, respectively) [2].

We report herein the unique presentation of sarcoidosis in a Hispanic gentleman with no prior medical problems.



## 2. Case

A 55-year-old Hispanic male presented to the hospital at the request of his primary care provider due to a two-month history of joint pain in the shoulders, elbows, wrists, and knees, decreased appetite and 20-pound weight loss in the setting of hypercalcemia, anemia, elevated serum creatinine, and positive urine Bence-Jones protein. He also endorsed a severely pruritic rash, chills, and fatigue that began three weeks prior to admission, but denied fever, headache, alopecia, chest pain, cough, diaphoresis, dyspnea,

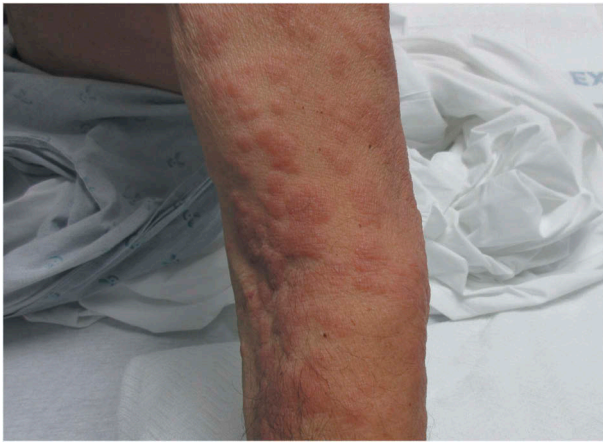abdominal pain, nausea, vomiting, or diarrhea. Travel history was significant for a trip to Mexico 3 months prior to admission. His occupation is in landscaping.

Physical exam was significant for diffuse joint tenderness without swelling or warmth, and multiple raised, blanchable, erythematous papules and plaques distributed on the back, arms, legs, and face, as well as leonine facies (Figures 1 and 2). Labs were significant for a serum white blood cell count (WBC) of 3,700/microL (normal 4,500–11,000/microL), absolute lymphocytes 400/microL (1,000–4,000/microL), hemoglobin of 8.6 g/dL (normal 14.0–17.5 g/dL), corrected calcium of 14.4 mg/dL (normal 8.6–10.3 mg/dL), 1,25-dihydroxyvitamin D of 154 pg/mL (normal 18–72 pg/mL), 25-hydroxyvitamin D of 20 ng/mL (normal 30–100 ng/mL), PTH of 1 pg/mL (normal 14–64 pg/mL), PTH-related protein of 24 pg/mL (normal 14–27 pg/mL), creatinine of 3.23 mg/dL (unknown baseline, normal 1.13 and 0.93 mg/dL), and 24-h urine protein of 700 mg (normal < 100 mg).

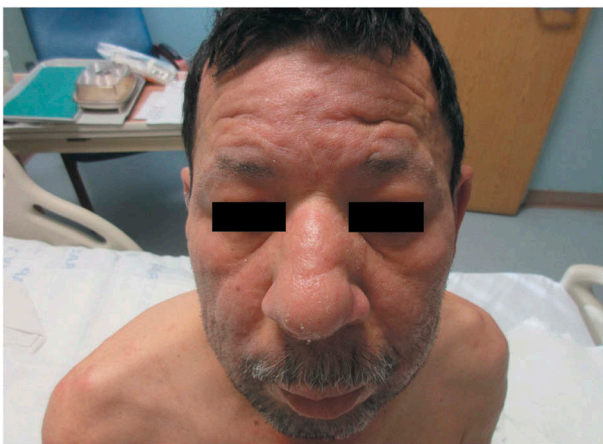Due to positive Bence-Jones protein on urinalysis from an outside laboratory, the diagnosis of gammopathy was entertained. However, an in-house evaluation for monoclonal gammopathy, including serum and urine protein electrophoresis and immunofixation, skeletal survey, and bone marrow biopsy, was negative for gammopathy as well as infection and malignancy. Interestingly, skin punch biopsy revealed

**CONTACT** Zahra Pakbaz  [z.pakbaz@ruhealth.org](mailto:z.pakbaz@ruhealth.org)  Department of Internal Medicine, University of California, Riverside, School of Medicine, 26520 Cactus Avenue, Moreno Valley, CA 92555, USA

© 2019 The Author(s). Published by Informa UK Limited, trading as Taylor & Francis Group on behalf of Greater Baltimore Medical Center. This is an Open Access article distributed under the terms of the Creative Commons Attribution-NonCommercial License (<http://creativecommons.org/licenses/by-nc/4.0/>), which permits unrestricted non-commercial use, distribution, and reproduction in any medium, provided the original work is properly cited.

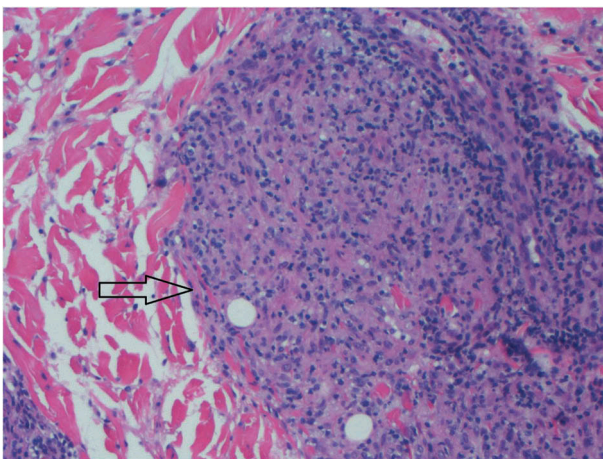


**Figure 1.** Left arm, antecubital area, discrete, multiple well-demarcated, edematous, erythematous papules and plaques.



**Figure 2.** Face, frontal view. Leonine facies: Diffuse skin infiltration, multiple nodular lesions.

non-caseating granulomatous dermatitis, with negative stains for atypical mycobacteria, tuberculosis and fungal organisms (Figure 3). CT chest showed non-specific calcified granulomas at the hilum and left lung without hilar adenopathy or infiltrates. Renal



**Figure 3.** Histopathology, skin biopsy, taken from left arm. H&E staining 200 x magnification showing non-caseating granulomatous dermatitis.

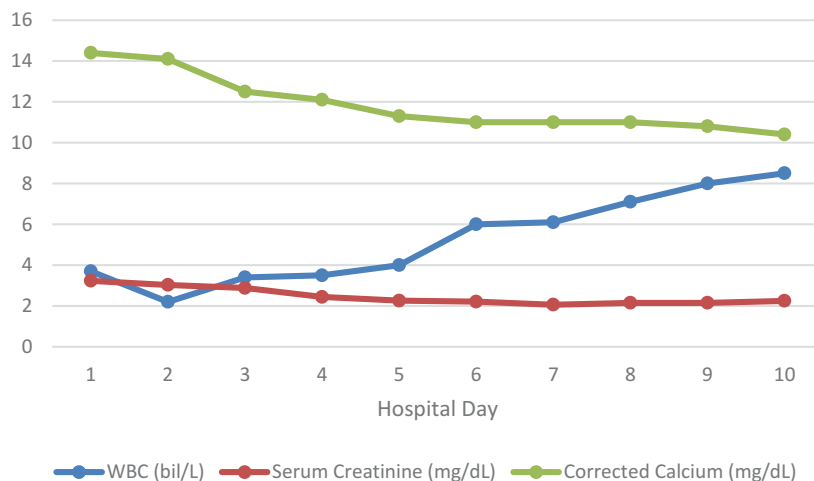
biopsy demonstrated mild arterial nephrocalcinosis and segmental thickening of the glomerular basement membrane. Tissue cultures, serum Quantiferon TB gold, coccidioides antibodies, histoplasma antibodies, and blastomyces antibodies were all negative. Serum Angiotensin Converting Enzyme (ACE) level was normal. Screening electrocardiogram and transthoracic echocardiogram did not demonstrate any evidence of cardiac involvement. By exclusion of alternative diagnoses, the patient was treated for sarcoidosis with prednisone 20 mg daily, yielding substantial improvements in the rash, and arthralgia. The hypercalcemia resolved with steroids, fluid resuscitation, calcitonin, and pamidronate which also led to the improvement of renal function (Figure 4). Two weeks after discharge, he was started on azathioprine 50 mg daily with subsequent prednisone taper. As an outpatient, the patient was doing well with resolution of his rash, and azathioprine was up-titrated to 100 mg daily. The patient was subsequently lost to follow-up.

### 3. Discussion

Sarcoidosis is relatively rare in Hispanics, with a reported prevalence of 21.7 per 100,000, when compared to other ethnic groups [2]. Skin involvement occurs in 25% to 35% of patients with sarcoidosis, and can present at any stage of illness [3]. While sarcoidosis is typically asymptomatic and rarely associated with pruritus and pain, this patient presented with a pruritic rash and leonine faces, reported only in a few cases worldwide [4,5]. The skin biopsy clutched the diagnosis of a granulomatous disease, which may be related to tubercular (though granulomas would be caseating), fungal, parasitic, or viral infections, malignancy or autoimmune diseases like sarcoidosis, granulomatosis with polyangiitis, Crohn's disease, or even common variable immune deficiency (CVID). However, a comprehensive evaluation for these alternative diagnoses was deemed negative despite recent travel and an occupation that exposes him to infectious risk. Testing for plasma cell dyscrasias, protein electrophoresis, light chain testing, and bone marrow biopsy were all unrevealing. Serologies, blood cultures, and pathology staining were negative for infectious etiologies described above.

The patient lacked symptoms suggestive of inflammatory bowel disease, and abdominal CT imaging was unremarkable. The diagnosis of sarcoidosis was ultimately made after excluding other etiologies and noting concomitant laboratory findings of hypercalcemia, hypervitaminosis D, skin biopsy with non-caseating granulomas, skin rash, joint pain, and constitutional symptoms [6].

An additional unique point to this case is that the majority (70%) of patients with cutaneous involvement also demonstrates pulmonary symptoms [7],



**Figure 4.** Trends in WBC, serum creatinine, and albumin-corrected calcium over 10 hospital days. There is sustained improvement in WBC, creatinine, and calcium levels after administration of oral prednisone, as noted on hospital day 6.

but our patient lacked pulmonary complaints and demonstrated only two calcified granulomas on advanced pulmonary imaging.

Reports implicate the presence of hypercalcemia in 10 to 20% of patients with sarcoidosis [8]. The enzyme, 1- $\alpha$  hydroxylase, converts 25-hydroxyvitamin D to 1,25-dihydroxyvitamin D, the active form of the vitamin, which may result in hypercalcemia, hypercalciuria, and nephrolithiasis. Longstanding hypercalcemia and hypercalciuria can cause nephrocalcinosis and renal failure [9,10], as seen in our case. The patient had a suppressed PTH level suggesting that hypercalcemia was not parathyroid hormone dependent. Successful treatment of the hypercalcemia with steroids and other therapies often improves, but usually does not completely resolve the renal dysfunction, as also seen in our patient.

Sarcoidosis may be associated with a reduction in any blood cell line. The most common hematologic problem is lymphopenia, which is a reflection of the sequestration of lymphocytes into the areas of inflammation [11]. Anemia, in this case, could be multifactorial, including anemia of inflammation, renal insufficiency, and lack of nutrients (decreased appetite, weight loss).

The majority of sarcoidosis-related manifestations resolve within 2–5 years. Certain risk factors at presentation may be associated with worse prognosis, such as fibrosis on chest imaging, presence of lupus pernio, bone cysts, nephrolithiasis, and cardiac disease [11].

While a large number of patients with sarcoidosis, typically pulmonary sarcoidosis, never needs medications, symptomatic sarcoidosis is treated with corticosteroids as the first line of treatment [12]. The decision to add steroid-sparing agents is dependent on the tolerability, duration, and dosage of corticosteroids. Specifically, if one is unable to safely taper off steroid treatment without a recurrence of sarcoidosis symptoms, steroid-sparing therapy is indicated. Such

treatments may include hydroxychloroquine, methotrexate, azathioprine, mycophenolate, leflunomide [13], cyclophosphamide, infliximab [14,15], adalimumab, and newer agents like rituximab [16]. In the 1950s, corticotropin (Acthar gel, subcutaneous) demonstrated efficacy in treating pulmonary sarcoidosis and was approved by the FDA to do so on the basis of case reports [17]. Shortly thereafter, hydrocortisone and prednisone were FDA approved for the treatment of symptomatic sarcoidosis, proving to be more cost-effective and convenient than Acthar injections [18]. Our patient demonstrated a good response to a low-dose steroid therapy by improving skin lesions, arthralgia, leukopenia, hypercalcemia, and serum creatinine; however, his prognosis may not be favorable due to concern for a component of his renal dysfunction related to hypercalcemia.

## Disclosure statement

No potential conflict of interest was reported by the authors.

## References

- [1] Judson MA, Thompson BW, Rabin DL, et al. The diagnostic pathway to sarcoidosis. *Chest*. 2003 Feb;123(2):406–412.
- [2] Baughman RP, Field S, Costabel U, et al. Sarcoidosis in America. Analysis based on health care use. *Ann Am Thorac Soc*. 2016 Aug;13(8):1244–1252.
- [3] Fernandez-Faith E, McDonnell J. Cutaneous sarcoidosis: differential diagnosis. *Clin Dermatol*. 2007 May-Jun;25(3):276–287.
- [4] Marchell RM, Thiers B, Judson MA. Chapter 152. Sarcoidosis. In: Goldsmith LA, Katz SI, Gilchrist BA, et al., editors. *Fitzpatrick's dermatology in general medicine*. New York, NY: McGraw-Hill; 2012. p. 8e.
- [5] Kendrick CG, Brown RA, Reina R, et al. Cutaneous sarcoidosis presenting as leonine facies. *Cutis*. 2004 Jan;73(1):57–62.

- [6] Hunninghake GW, Costabel U, Ando M, et al. ATS/ERS/WASOG statement on sarcoidosis. American thoracic society/European respiratory society/World association of sarcoidosis and other granulomatous disorders. *Sarcoidosis Vasc Diffuse Lung Dis.* 1999 Sep;16(2):149–173.
- [7] Yanardag H, Tetikkurt C, Bilir M, et al. Diagnosis of cutaneous sarcoidosis; clinical and the prognostic significance of skin lesions. *Multidiscip Respir Med.* 2013 Mar 22;8(1):26.
- [8] Singer FR, Adams JS. Abnormal calcium homeostasis in sarcoidosis. *N Engl J Med.* 1986 Sep 18;315(12):755–757.
- [9] Sharma N, Tariq H, Uday K, et al. Hypercalcemia, anemia, and acute kidney injury: a rare presentation of sarcoidosis. *Case Rep Med.* 2015;2015:1–6.
- [10] Berliner AR, Haas M, Choi MJ. Sarcoidosis: the nephrologist's perspective. *Am J Kidney Dis.* 2006 Nov;48(5):856–870.
- [11] Baughman RP, Lower EE. Sarcoidosis. In: Jameson J, Fauci AS, Kasper DL, et al., editors. *Harrison's principles of internal medicine.* New York, NY: McGraw-Hill; 2018; p. 20e.
- [12] Baughman RP, Nunes H, Sweiss NJ, et al. Established and experimental medical therapy of pulmonary sarcoidosis. *Eur Respir J.* 2013;41:1424–1438.
- [13] Sahoo DH, Bandyopadhyay D, Xu M, et al. Effectiveness and safety of leflunomide for pulmonary and extrapulmonary sarcoidosis. *Eur Respir J.* 2011;38:1145–1150.
- [14] Sodhi M, Pearson K, White ES, et al. Infliximab therapy rescues cyclophosphamide failure in severe central nervous system sarcoidosis. *Respir Med.* 2009;103:268–273.
- [15] Moravan M, Segal BM. Treatment of CNS sarcoidosis with infliximab and mycophenolate mofetil. *Neurology.* 2009;72:337–340.
- [16] Sweiss NJ, Lower EE, Mirsaeidi M, et al. Rituximab in the treatment of refractory pulmonary sarcoidosis. *Eur Respir J.* 2014;43:1525–1528.
- [17] Miller MA, Bass HE. Effect of Acthar-c (ACTH) in sarcoidosis. *Ann Intern Med.* 1952; 37: 776–784.
- [18] Salomon A, Appel B, Collins SF et al. Sarcoidosis: pulmonary and skin studies before and after ACTH and cortisone therapy. *Dis Chest.* 1956; 29: 277–291.