

Available online at www.sciencedirect.com

ScienceDirect

journal homepage: www.elsevier.com/locate/ihj

Original Article

An experience with off pump technique for repair of anomalous left coronary artery from pulmonary artery (ALCAPA)[☆]



Suresh V. Joshi, Abhijeet V. Naik^{*}, Parag S. Bhargat, Bhushan Chavan, Prasanna Salvi

Department of Pediatric and Congenital Heart Centre, New Age Wockhardt Hospital, Mumbai, India

ARTICLE INFO

Article history:

Received 30 November 2015

Accepted 2 February 2016

Available online 19 February 2016

Keywords:

ALCAPA

Off pump

Subclavian bypass

ABSTRACT

Background: Anomalous origin of left coronary artery from pulmonary artery is a very rare disease with incidence of one every 300,000 live births. It has a high mortality of 80% in the first year of life.

This observational study summarized our experience using the technique of subclavian arterial bypass without the use of cardiopulmonary bypass (CPB) for treatment of this coronary anomaly in pediatric population. The study aims to revive an earlier technique, with modifications, as an alternative to the existing coronary translocation.

Methods: From 2009 till 2015, six consecutive infants were operated by a single surgeon using subclavian artery to left coronary artery bypass done off pump, to establish a two coronary circulation.

Results: Five patients had an improvement in their LV ejection fractions at the time of the last follow-up. Angiography done in two cases after 2 and 6 years after surgery revealed good flow in the left coronary artery and good growth in the length of subclavian artery. There was one surgical mortality in this series.

Conclusions: The technique of off pump subclavian arterial bypass for anomalous origin of the left coronary artery from the pulmonary artery is a viable alternative to the existing standard technique of coronary translocation. It essentially eliminates extracorporeal circulatory support or a left heart bypass that may be needed after coronary translocation. Also, the advantage of avoiding CPB, both in economic terms and also the adverse effects related to use of bypass in this very sick hearts, cannot be disregarded.

© 2016 Cardiological Society of India. Published by Elsevier B.V. This is an open access article under the CC BY-NC-ND license (<http://creativecommons.org/licenses/by-nc-nd/4.0/>).

[☆] This manuscript was presented as an oral presentation in the Annual Conference of the Pediatric Cardiac Society of India 2015 at Hyderabad for I.M. Rao Surgical Award session on 16th October 2015. The statement has been read by all the mentioned authors and we believe that this work represents honest and original work.

^{*} Corresponding author.

E-mail address: abhijeet_avian@yahoo.co.in (A. V. Naik).

<http://dx.doi.org/10.1016/j.ihj.2016.02.002>

0019-4832/© 2016 Cardiological Society of India. Published by Elsevier B.V. This is an open access article under the CC BY-NC-ND license (<http://creativecommons.org/licenses/by-nc-nd/4.0/>).

1. Introduction

Anomalous origin of the left coronary artery from the pulmonary artery (ALCAPA) is the current term for what was previously known as Bland-White-Garland syndrome. ALCAPA is a rare but serious congenital anomaly of the coronary anatomy that affects 1 in 300,000 births.¹ The overall mortality in the first year of life for untreated cases is 90%.² In untreated kids, who survive infancy, there is 80–90% incidence of sudden death.³

The surgical treatment has evolved from simple ligation of the origin of the left coronary artery⁴ to various forms of bypass grafts from the aorta,^{5,6} subclavian to left coronary artery anastomosis,⁷ transpulmonary baffling or Takeuchi procedure,⁸ and direct re-implantation of the coronary artery into the aorta.⁹

Successful surgical repair basically depends upon the reestablishment of a two-coronary system.¹⁰ The authors have attempted to revive an earlier technique of using subclavian artery bypass to the left coronary artery, with modifications (without the aid of cardiopulmonary bypass (CPB)), to correct this complex anomaly.

2. Methods

2.1. Patients

Between January 2009 and August 2015, 6 consecutive patients (M:F ratio 2:1) underwent surgical repair for ALCAPA. Their age ranged from 7 weeks to 8 months of age (mean age 4 months). Their weight ranged from 3.6 kg to 5.3 kg (mean weight 4.5 kg). All patients were diagnosed using echocardiography and the preoperative LVEF and FS along with the degree of mitral regurgitation and the extent of endomyocardial fibroelastosis were documented. The basic clinical data are presented in Table 1.

All these patients underwent repair for ALCAPA using a modification of the Meyer's technique, i.e. left subclavian artery to the left coronary artery bypass, but without the use of CPB. We have followed a policy to not address the MR at the time of initial surgery as recommended by certain groups.^{11,12} Some authors recommend routine mitral valve repair at the time of initial repair.¹³ Postoperative mitral incompetence has been identified as a risk factor for reintervention, but not for death.

2.2. Surgical technique

After standard median sternotomy, pericardium was opened and hitched. Anatomy was confirmed. Left subclavian artery was dissected free as distally as possible and all the branches were ligated and transected. The principles and technique of beating heart bypass were followed but since there are no pediatric cardiac stabilizers, stay sutures were taken to stabilize LAD as close to the origin. The origin of the left coronary artery was dissected and a long arteriotomy was performed on the LAD and an intracoronary shunt of appropriate size was inserted into LAD. Left subclavian to LAD anastomosis was done with 7.0 polypropylene suture in a continuous manner and the shunt was extracted before completion of the anastomosis. LMCA was transfixated at the origin using 5.0 polypropylene suture near the MPA. Epicardial pacing wires were placed and the pericardium was approximated and chest closed in a standard manner over drainage catheters.

3. Results

All patients were started on inotropic supports of milrinone and adrenaline electively and dopamine was added as per hemodynamic requirement. None of our patients required delayed sternal closure or had any need of left heart bypass support (LVAD), or any need of ECMO.

The median duration of ventilation was 28 h and the median ICU stay was 5 days. The average hospital stay was 10.6 days.

There was no significant morbidity except for one patient (patient 5) having features of low cardiac output syndrome and needing peritoneal dialysis.

Patient 3 had a sudden and intractable ventricular fibrillation after shifting to the ICU and resuscitation proved to be unsuccessful. After retrospective analysis of the case, it was hypothesized that the left circumflex artery could have been compromised during the ligation of the left main artery as this patient had a very short stump of left main segment. We modified the technique, so as to transfix the origin of the left main segment close to the MPA wall, instead of ligation, that we followed earlier.

The postoperative details are summarized in Table 2.

3.1. Follow-up assessment

All patients were followed up at intervals of 1 month, 3 months, and subsequently at 6 monthly intervals. The follow-

Table 1 – Preoperative data.

Sr No.	Age (months)	Weight (kg)	Sex	FS	LVEF	Preoperative MR	Endomyocardial fibroelastosis	Sinus of origin from MPA
1	5	4.2	F	16%	35%	Mild	Yes	Posterior facing sinus
2	2	3.6	M	17%	35%	Mild	Yes	Facing sinus
3	3	4.4	M	13%	25%	Moderate	Yes	Nonfacing sinus
4	6	4.6	F	15%	30%	Moderate	Mild	Posterior facing sinus
5	8	5.3	M	14%	27%	Moderate	Yes	Non Facing Sinus
6	3	4.9	M	15%	30%	Moderate	Yes	Facing sinus

LVEF, left ventricular ejection fraction; FS, fractional shortening; MR, mitral regurgitation.

Table 2 – Postoperative parameters.

Sr No.	Duration of ventilation (hours)	Inotrope score	ICU stay (days)	Need for peritoneal dialysis	Morbidity	Rhythm disorders	Mortality	Hospital stay (days)
1	36	15	5	No	No	No	No	12
2	28	15	4	No	No	No	No	13
3	–	20	–	No	–	Ventricular fibrillation	Yes	–
4	6	10	3	No	No	No	No	6
5	78	20	7	Yes	LCOS	No	No	13
6	28	15	5	No	No	No	No	9

LCOS, low cardiac output syndrome.

up included electrocardiograms and a detailed echocardiographic assessment (LVEF, FS, MR). Detailed echocardiographic and Doppler assessment of flows in the left anterior descending artery was done.

Two older patients underwent treadmill test. In two cases, a conventional angiography was done to assess the grafts and the length and growth of the left subclavian artery (Figs. 1 and 2). At every interval follow-up, the clinical status of the child and symptoms were determined and an anthropometric evaluation of the left upper limb was done. Also, the left upper extremity was evaluated for power and capillary refill. In select cases (case number 2), a cardiac perfusion scan was done, as there was suspicion of a kink or an angulation at the anastomotic site on angiography (Fig. 2). The scan revealed no perfusion defect or inducible ischemia.

In the two patients who underwent angiography, the length of the subclavian artery was measured and the origin was studied. The growth of the subclavian artery was satisfactory and the left coronary arterial system showed excellent filling.

Patient 6 underwent a cardiac magnetic resonance study for assessing the early postoperative parameters like immediate postoperative LVEF and MR and coronary flow.

The details of the follow-up are summarized in Table 3.

4. Discussion

Anomalous origin of the coronary artery from the pulmonary artery is a rare congenital cardiac malformation. The orifice of anomalous main coronary or branch coronary artery may be located almost anywhere on the MPA or branch PA. It mostly arises from the left sinus of the pulmonary artery, rarely from the right sinus and, exceptionally, from the anterior wall of the PA.¹⁴

When the anomalous coronary artery originates from the pulmonary artery, the myocardial perfusion is mainly dependent on the extent of collateral circulation, and on the changing morphological-functional alterations of pulmonary

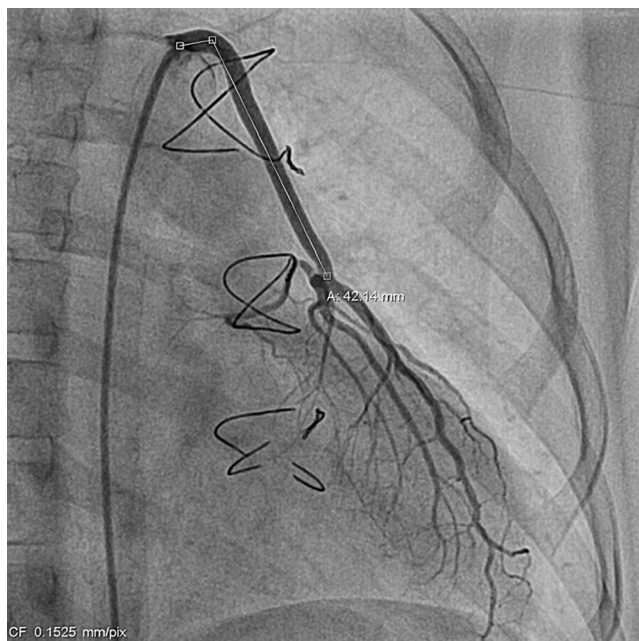


Fig. 1 – Angiographic appearance of the subclavian to LAD anastomosis in patient 1. The subclavian artery has grown well in length and size.

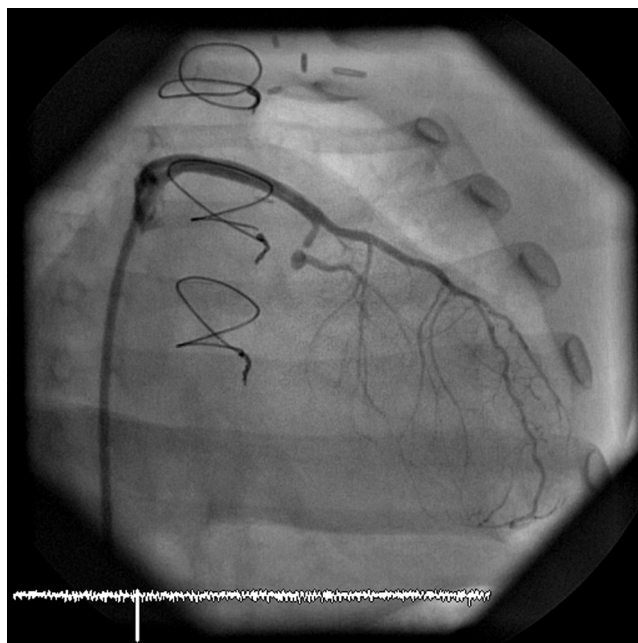

Fig. 2 – The angiographic appearance of the subclavian to LAD anastomoses in patient 2. There is a suspicion of angulation and kink at the level of the anastomosis. The perfusion scan revealed no perfusion defect.

Table 3 – Follow up data.

Sr No.	Months of follow up	FS	LVEF	MR (Grade)	ECG	TMT	Left upper limb	Angiography	Perfusion scan	CMR
1	80	36%	65%	Trivial	Normal	Normal	Normal	Done, good flow and patency	No	No
2	60	29%	60%	No	Normal	ST-T changes seen	Normal	Done, suspicious angulation at the anastomoses	Yes, No inducible ischemia, Normal EF	No
3	-	-	-	-	-	-	-	-	-	-
4	18	35%	64%	No	Normal	-	Normal	No	No	No
5	17	29%	55%	Mild	Normal	-	Normal	No	No	No
6	3	24%	50%	Mild	Normal	-	Normal	No	No	Done

LVEF, left ventricular ejection fraction; FS, fractional shortening; MR, mitral regurgitation; TMT, treadmill test; CMR, cardiac MR.

circulation. As pulmonary vascular resistance decreases after birth, the retrograde flow through the ACA from the collateral circulation floods mostly into the low-pressure PA, resulting in coronary steal and subsequent angina. If the collateral network is not well developed, coronary steal into the PA still persists early into infancy. This decrease in antegrade flow ultimately results in myocardial ischemia, myocardial infarction, papillary muscle dysfunction, congestive heart failure, cardiogenic shock, and even sudden death. So this situation is uniformly fatal with a mortality of 90% by 1 year of age without surgical intervention.

Patients who survive past childhood often have varying symptoms such as angina, impaired LV function, MI, and progressive heart failure, according to the evolvement of the collateral circulation.

Over half a century, several varied operative procedures have been recommended as treatment for ALCAPA. It was soon evident that simple ligation of the anomalous artery at its pulmonary origin, as described by Sabiston et al.,⁴ though often successful, was associated with significant short- and long-term complications. These complications were felt to be due to the fact that, after ligation, the heart was converted to a single vessel coronary system, making it entirely dependent upon right coronary artery to left coronary artery collaterals vessels, which though present, were unpredictable. In 1966, Cooley and colleagues⁵ pioneered the two-vessel coronary system by placing a Dacron interposition graft from the aorta to the left coronary artery, thus restoring direct, antegrade arterial flow to the left coronary artery. Following this, over the course of the next few years, several other bypass procedures using saphenous vein, internal mammary artery, or left subclavian artery were proposed in attempts to restore a two-vessel coronary system and to improve the surgical outcome for these patients. The modern operative correction of ALCAPA, the coronary translocation, is based upon the concept of the arterial switch operation and was proposed by Neches et al.⁹ in 1974. In cases where direct left coronary translocation is not possible due to anatomic constraints, the Takeuchi procedure⁸ can be used. Introduced in 1979, the Takeuchi procedure involves the creation of a tunnel within the pulmonary artery that leads from the aorta to the ostium of the anomalous left coronary artery.

Although coronary translocation has been more or less established as the treatment of choice in ALCAPA surgery, the effects of a cardioplegic arrest and CPB on a sick myocardium cannot be brushed aside. Also, the incidence of need of ECMO

in this cases is around 19%.¹⁵ According to Lange et al.,¹⁶ the left subclavian artery to coronary artery anastomosis and the direct implantation of the left coronary artery were equally effective surgical techniques.

In our institution, we have followed a policy of doing an off pump subclavian bypass to LAD in these sick infants with very poor LVEF and poor contractility in order to avoid the harmful effects and hazards of CPB.

The reason that we refer to our technique as a modification of Meyer's technique is that the original technique involved an end to end anastomosis of the left subclavian artery to button of the left main coronary artery excised from the pulmonary artery. This needed not only CPB, but also cardioplegic arrest. As the newer techniques like Takeuchi method and the coronary translocation developed, this earlier technique of Meyer did not offer any significant advantage and fell by the wayside.

The authors have revived this technique in a manner that the anastomosis is done end to side on the arteriotomy of the left coronary artery, without the aid of CPB. We have offered this technique to all patients of ALCAPA, irrespective of the preoperative LVEF, sinus of origin, or coronary dominance.

The authors have followed a policy of not addressing the mitral regurgitation during the primary surgery. Regarding mitral valve repair, there are multiple references where mitral valve regurgitation improves after ALCAPA repair with improvement in left ventricular function. Also, mitral regurgitation is a risk factor for re-intervention and not for mortality. We believe that if there is clear structural and morphological anomaly in mitral valve apparatus, then repair is indicated. We have not come across such a case in our limited experience. Also, many studies, notably Ben Ali et al.¹¹ have studied the long-term outcomes of mitral valve regurgitation in ALCAPA and have recommended that "mitral valve surgery is probably not indicated at initial surgery, except in cases with low potential of recovery (severe regurgitation with well preserved left ventricular function)".

In our experience, this technique has the advantage of reducing the postoperative morbidity and the inotropic support and the length of ICU stay. Also, none of our patients needed ECMO or LVAD. Regarding the economic advantages of avoidance of CPB, we have to understand that the cost of the consumables of the CPB is significant. We may borrow from the fact that off pump coronary artery bypass grafting is extremely well received in our country primarily because it avoids the inflammatory response of the CPB and also due to

the decreased financial demands. Same principal may be applicable here. In addition, we have not had the need for ECMO in our series which in addition to being an expensive modality, also has significant ill effects (though it is a necessary evil in some cases).

In conclusion, the technique of off pump subclavian arterial bypass for ALCAPA is a viable alternative to the existing standard technique of coronary translocation. The technique essentially eliminates extracorporeal circulatory support or a left heart bypass that may be needed if the child does not come off bypass after coronary translocation. Also, the advantage of avoiding CPB, both in economic terms and also the adverse effects related to use of bypass in this very sick hearts, cannot be disregarded.

4.1. Limitations of the study

The subset of the study is small and also the follow-up duration is limited. In the short term, the technique has definite advantages over the existing established coronary translocation as mentioned above; however, the long-term effects of the technique and durability of the coronary anastomoses need to be studied in detail. The follow-up period of patients is not fixed, since it is an ongoing study.

Conflicts of interest

The authors have none to declare.

REFERENCES

1. Keith JD. The anomalous origin of left coronary artery from pulmonary artery. *Br Heart J*. 1959;21:149-161.
2. Wesselhoeft H, Fawcett JS, Johnson AL. Anomalous origin of left coronary artery from pulmonary artery, its clinical spectrum, pathology and pathophysiology, based on review of 140 cases with seven further cases. *Circulation*. 1968;38:403-425.
3. George JM, Knowlam DM. Anomalous origin of left coronary artery from pulmonary artery in adult. *N Engl J Med*. 1959;261:933.
4. Sabiston Jr DC, Neill CA, Taussig HB. The direction of blood flow in anomalous left coronary artery arising from the pulmonary artery. *Circulation*. 1960;22:591-597.
5. Chaitman BR, Bourassa MG, Lesperance J, Grondin P. Anomalous left coronary artery from pulmonary artery. An eight year angiographic follow-up after saphenous vein bypass graft. *Circulation*. 1975;51:552-555.
6. Cooley DA, Hallman GL, Bloodwell RD. Definitive surgical treatment of anomalous origin of left coronary artery from pulmonary artery: indications and results. *J Thorac Cardiovasc Surg*. 1966;52:798-808.
7. Meyer BW, Stefanik G, Stiles QR, Lindesmith GG, Jones JC. A method of definitive surgical treatment of anomalous origin of left coronary artery. A case report. *J Thorac Cardiovasc Surg*. 1968;56:104-107.
8. Takeuchi S, Imamura H, Katsumoto K, et al. New surgical method for repair of anomalous left coronary artery from pulmonary artery. *J Thorac Cardiovasc Surg*. 1979;78:7-11.
9. Neches WH, Mathews RA, Park SC, et al. Anomalous origin of the left coronary artery from the pulmonary artery. A new method of surgical repair. *Circulation*. 1974;1974:582-587.
10. Bunton R, Jonas RA, Lang P, Rein AJ, Castaneda AR. Anomalous origin of coronary artery from pulmonary artery: ligation versus establishment of a two coronary artery system. *J Thorac Cardiovasc Surg*. 1987;93:103-108.
11. Ben Ali W, Metton O, Roubertie F, et al. Anomalous origin of the left coronary artery from the pulmonary artery: late results with special attention to the mitral valve. *Eur J Cardiothorac Surg*. 2009;244-249.
12. Ojala T, Salminen J, Happonen J-M, Pinkhala J, Jokinen E, Sairanen H. Excellent functional result in children after correction of anomalous origin of left coronary artery from the pulmonary artery – a population based complete follow up study. *Interact Cardiovasc Thorac Surg*. 2010;1:70-75.
13. Isomatsu Y, Imai Y, Shin'oka T, Aoki M, Iwata Y. Surgical intervention for anomalous origin of the left coronary artery: the Tokyo experience. *J Thorac Cardiovasc Surg*. 2001;121:792-797.
14. Smith A, Arnold R, Anderson RH, et al. Anomalous origin of the left coronary artery from the pulmonary trunk. Anatomic findings in relation to pathophysiology and surgical repair. *J Thorac Cardiovasc Surg*. 1989;98:16-24.
15. Imamura M, Dossey AM, Jaquiss RDB. Reoperation and mechanical circulatory support after anomalous origin of the left coronary artery from the pulmonary artery: a twenty year experience. *Ann Thorac Surg*. 2011;92:167-173.
16. Lange R, Vogt M, Horer J, et al. Long term results of repair of anomalous origin of the left coronary artery from the pulmonary artery. *Ann Thorac Surg*. 2007;83:1463-1471.