

Rotator Cuff Tendon Adhesion to the Acromial Undersurface: Identification and Management Techniques



Daniel K. Grahl, M.D., and Larry D. Field, M.D.

Abstract: Identifying and mobilizing rotator cuff tissue during arthroscopic revision rotator cuff repair can be challenging. A particularly complex situation is encountered when rotator cuff tendons become adhered to surrounding bony structures. Tendon adherence to the undersurface of the acromion may occur after rotator cuff repair, especially when concurrent acromioplasty was carried out during the index procedure. This adhered and retracted rotator cuff tissue may be difficult to both recognize and mobilize, once identified, arthroscopically. The authors present a technique that can aid in both identifying and lateralizing this adhered rotator cuff tissue within the subacromial space.

Introduction

Failure of rotator cuff surgery to achieve a successful outcome for a patient is not uncommon. Such repair failure can have several causes, including diagnostic errors, technical errors, surgical complications, or failure to heal. Likewise, many poor outcomes result from a combination of these various causes. Failure of the rotator cuff tissue to heal to its tuberosity insertion has been linked to inadequate strength of the initial repair, biological factors, and improper postoperative rehabilitation.¹

The indications for revision rotator cuff repair after failure to heal are not well defined, and there are many factors to consider before recommending revision surgery. However, there are certainly clinical situations in

which an attempt to re-repair a previously failed rotator cuff repair is appropriate, and maximizing surgeons' ability to recognize the rotator tissue that is present intraoperatively in this revision setting improves the chances that a patient can achieve a successful postoperative outcome. Additional considerations that should be properly weighed before recommending revision rotator cuff surgery include the amount and presumed quality of rotator cuff tissue that remains. Such an assessment of the rotator cuff preoperatively is based on clinical and radiologic evaluation, the specifics of the index surgical intervention such as the original tear size and orientation, and the likelihood that mobilization of the remaining rotator cuff tissue will achieve adequate footprint coverage.^{2,3}

Acromioplasty is commonly carried out in conjunction with rotator cuff repair, especially when preoperative or intraoperative evaluations identify significant evidence of impingement. When revision rotator cuff repair is chosen based on persistent postoperative symptoms and objective testing, effective and secure repair of this rotator cuff tissue can be difficult to achieve. This torn and often retracted rotator cuff tissue may also be challenging to simply identify arthroscopically, as a result of, in part, scar formation and distortion of the rotator cuff tissue.⁴ Specifically, in such a clinical setting when revision rotator cuff repair is carried out, the torn rotator cuff tissue may become adherent to the undersurface of the acromion. When this rotator cuff tissue becomes adhered to the acromial undersurface, it can be remarkably disguised and difficult to fully appreciate. In fact, the surgeon may have

From the Mississippi Sports Medicine and Orthopaedic Center, Jackson, Mississippi, U.S.A. (D.K.G.); and the Upper Extremity Service, Sports Medicine and Arthroscopy Fellowship, Mississippi Sports Medicine and Orthopaedic Center, Jackson, Mississippi, U.S.A. (L.D.F.).

The authors report that they have no conflicts of interest in the authorship and publication of this article and that no funding or financial remuneration was received. Full ICMJE author disclosure forms are available for this article online, as [supplementary material](#).

Received February 13, 2019; accepted June 8, 2019.

Address correspondence to Larry D. Field, M.D., Upper Extremity Service, Sports Medicine and Arthroscopy Fellowship, Mississippi Sports Medicine and Orthopaedic Center, 1325 East Fortification Street, Jackson, MS 39202. E-mail: lfield@msmoc.com

© 2019 by the Arthroscopy Association of North America. Published by Elsevier. This is an open access article under the CC BY-NC-ND license (<http://creativecommons.org/licenses/by-nc-nd/4.0/>).

2212-6287/19189

<https://doi.org/10.1016/j.eats.2019.06.004>

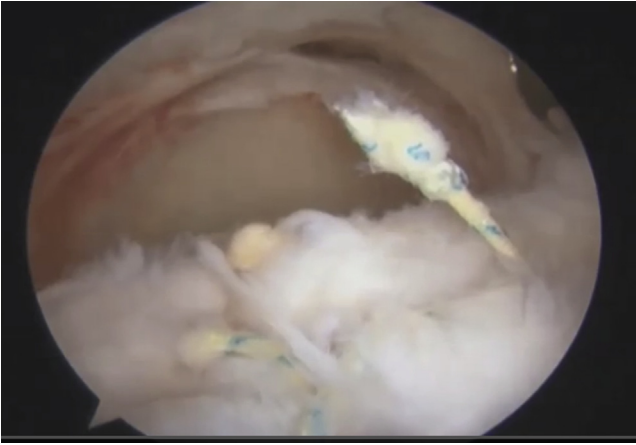


Fig 1. View from a lateral portal looking inside the right shoulder. Anterior is to the right and posterior to the left. In the foreground, a failed rotator cuff repair can be visualized with remaining suture. In the distance, the glenoid and what could appear as loss of rotator cuff tissue with only scar tissue on the under surface of the acromion (top of image).

the false perception that there is a complete absence of supraspinatus and infraspinatus tissue when, in actuality, a significant portion of the detached rotator cuff tissue is intimately scarred to the undersurface of the acromion instead. This perceived absence of rotator cuff tissue may lead the unwary surgeon to falsely conclude that the rotator cuff tear is irreparable. Potentially worse, the adherent rotator cuff tissue may be mistaken for bursal or scar tissue and be inappropriately debrided. Very careful and thorough examination of the glenohumeral joint and subacromial space is required to consistently recognize the rotator cuff tissue that is

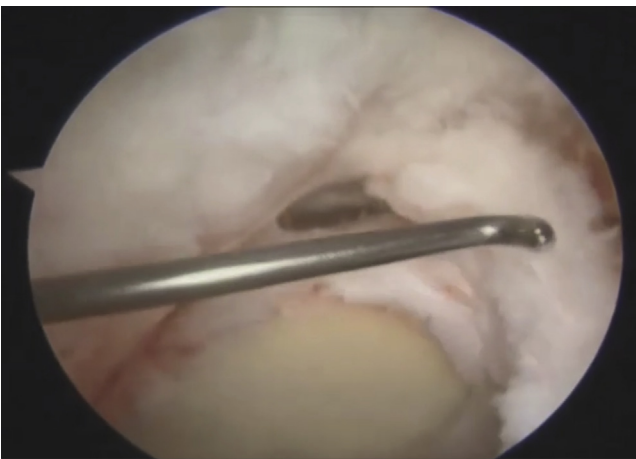


Fig 2. Tissue identification is shown in this arthroscopic image for a right shoulder in beach chair position. A probe has been inserted in the posterior portal and is probing the tissue that is superior to the glenoid and scarred to the undersurface of the acromion (top of image). Identification of tissue in this setting is difficult but must be achieved before debridement can safely begin.

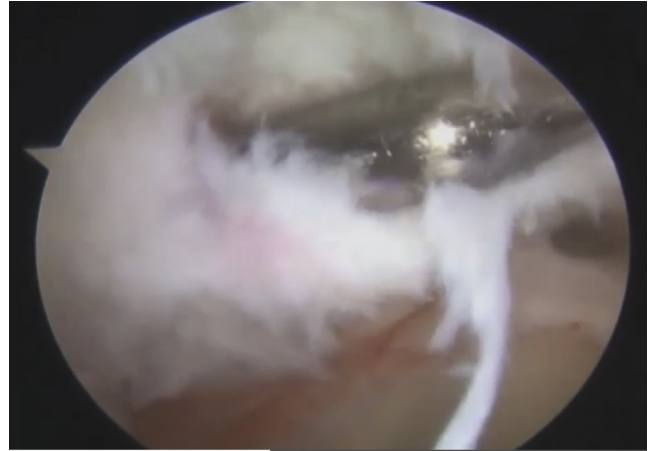


Fig 3. A technique for release of identified adhesions is shown for a right shoulder in beach chair position. A blunt probe can be inserted into the posterior portal, as in this image, and used to free the tissue from the undersurface of the acromion. This probe has developed a plane and can be used to work both medially and laterally, thus releasing the tissue that is scarred to the acromion.

present and available for revision repair. Once accurately identified, this tissue can then be mobilized and reattached to its bony insertion.

Surgical Technique

The patient is placed in either the beach chair or lateral decubitus position for revision arthroscopic rotator cuff repair. The senior author (L.D.F.) uses the beach chair for rotator cuff repair surgery, and the

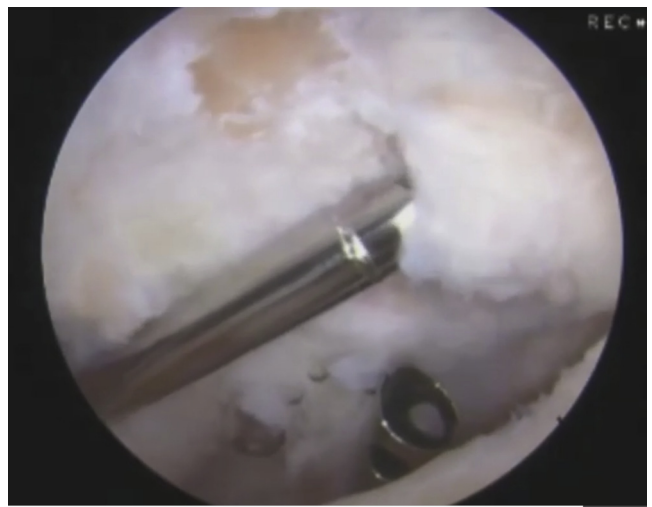


Fig 4. Viewed from a posterior portal with a shaver introduced from the lateral portal, a release of the adhesions of the rotator cuff to the acromion is shown for this left shoulder. The shaver blade is oriented with the teeth toward the acromion, to release the adhered tissue and allow for further mobilization of the supraspinatus and infraspinatus tendons, without unintended soft tissue damage.

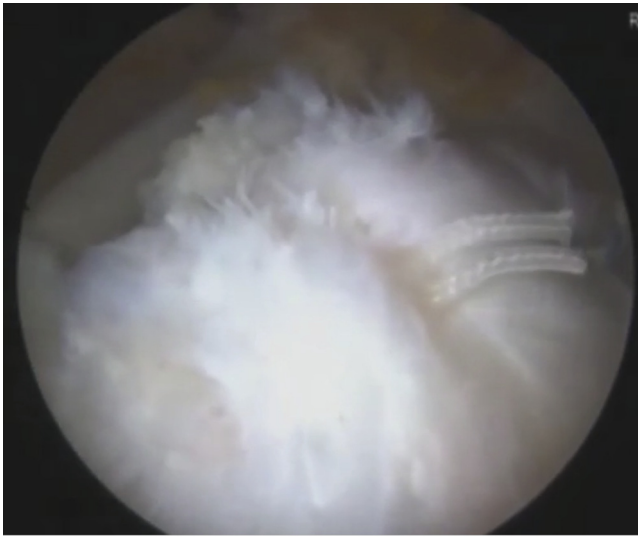


Fig 5. This image of a left shoulder, shown from the lateral viewing portal, demonstrates the repair of the rotator cuff once all tissue has been released and mobilized to the footprint. Repair is done in a rip stop configuration, producing an anatomical repair, from an initial situation lacking sufficient mobilization for adequate footprint coverage.

video procedure referenced here ([Video 1](#)) is carried out with the patient in the beach chair position. After the induction of anesthesia, the operative arm is prepped and draped in standard fashion. Posterior and anterior glenohumeral joint portals are created, and a thorough glenohumeral joint diagnostic examination is carried out. In the clinical scenario that has been described here in which the rotator cuff tissue is adhered to the acromion undersurface, deficient rotator cuff tissue seems to be present. Also, the greater tuberosity footprint is recognized as being devoid of attached rotator cuff tissue when viewed from the glenohumeral joint. After completion of the glenohumeral joint diagnostic assessment and any required glenohumeral joint surgical procedures, the arthroscope is then introduced into a lateral subacromial portal site to provide optimal visualization of the subacromial space and rotator cuff tissue ([Fig 1](#)). Thorough assessment, including probing of subacromial space margins as well as the tissue within this space, is carried out to identify all rotator cuff tissue. Also, care is taken to differentiate rotator cuff tissue from adhesions and scar. With deliberate and thorough evaluation, this

adherent, and often retracted, rotator cuff tissue can be recognized as it attaches to the acromion undersurface. Once identified, this tissue should be thoroughly defined so that it can be separated from the acromion undersurface and thus preserved for subsequent repair ([Fig 2](#)).

Once the adherent tissue is recognized and its margins defined, release of this tissue from the acromion along with rotator cuff mobilization can be accomplished. Either a blunt trocar ([Fig 3](#)) or an arthroscopic soft tissue shaver (Dynoics Powermax; Smith & Nephew, London, UK) ([Fig 4](#)), or both, can be used to separate the rotator cuff from the undersurface of the acromion. Once an appropriate tissue plane is established between the rotator cuff and the acromion, further mobilization of the rotator cuff can be carried out as necessary. The authors' experience with such rotator cuff adhesions to the acromion undersurface has consistently demonstrated that the rotator cuff tissue, even after separation from the undersurface of the acromion, is difficult to further lateralize. However, once a distinct plane between the rotator cuff and the acromion has been established, blunt soft tissue elevators and arthroscopic soft tissue shavers are usually helpful, to some extent, in allowing for additional tissue mobilization. In addition, when using the shaver to separate the rotator cuff tissue from the acromion, it is advised that the surgeon face the hooded portion of the shaver blade in the direction of the rotator cuff tissue to minimize the risk of inadvertent, overly extensive debridement of the adhered rotator cuff. An arthroscopic grasper can be introduced and used as well to provide gentle traction to this tissue to protect it and to aid in facilitating progressive tissue releases.

Repair of this newly separated and mobilized rotator cuff tissue can be accomplished in standard fashion ([Fig 5](#)). The rotator cuff is evaluated for its ability to be lateralized to the greater tuberosity footprint. The authors' experience with such tissue that has had to be freed from the acromion undersurface has generally been that not only is it difficult to mobilize but also this tissue is often relatively poor in quality, making revision rotator cuff repair even more challenging and potentially less predictable. If the rotator cuff tissue, after mobilization, is unable to be reapproximated to the anatomic greater tuberosity in a relatively low-tension state, then medialization of the greater tuberosity

Table 1. Technique Advantages and Disadvantages

Advantages	Disadvantages and Limitations
The demonstrated technique can yield a more substantial repair and better functional outcomes.	Prolonged physical therapy may be required postoperatively compared with the use of alternative treatments.
Improved anatomic function, via this technique, can increase the likelihood of satisfactory or very satisfactory patient results.	Available tissue quality may be a limiting factor in the utilization of the demonstrated technique.
The technique may reduce the need for a more invasive procedure.	Surgeon experience with cuff mobilization and arthroscopic repair still weight significantly into overall outcome.

Table 2. Technique Pearls and Pitfalls

When using a shaver for tissue release, caution must be taken not to debride but rather to protect as much tissue as possible by facing the aggressive end of the shaver away from the rotator cuff tissue.
If the tissue does have some pliability and enough substance to be localized to the footprint, it is well worth an attempt at repair.
Use the lateral viewing portal for visualization during mobilization as well as repair.
Work in an anterior-to-posterior direction on tissue with adhesion to the acromion.
Identify tissue before debridement in the subacromial space begins.

footprint, achieved by carefully removing 5 to 10 mm of superior humeral head articular cartilage, provides a more robust bony footprint area for tendon reattachment. Likewise, the dimensions of the mobilized rotator cuff tear will usually dictate the number and orientation of suture anchors used (5.5-mm Healicoil anchor, Smith & Nephew).

Discussion

Retraction and extensive adhesions of rotator cuff tissue after the failure of an index rotator cuff repair procedure are commonly seen in the revision surgical setting. However, dense scarring of this tissue to the undersurface of the acromion after index surgical acromioplasty is much less common, in the authors' experience. Maintaining a high index of suspicion regarding the potential for scarring of the detached rotator cuff tissue to the undersurface of the acromion is especially important because of its relatively uncommon occurrence and because such adhesions can be well disguised. Failure to identify repairable rotator cuff tissue such as that seen in the clinical scenario described here could significantly reduce the potential for achieving successful outcomes in such patients undergoing revision rotator cuff repair. Care should be taken in all cases of revision rotator cuff repair to palpate and visualize the undersurface of the acromion, especially in those instances in which significant rotator cuff tissue loss appears to be present. If this adhered tissue is present and recognized, care should then be taken to thoroughly and carefully release the rotator cuff from the acromion to improve the chances for a successful postoperative outcome. Certainly, restoring the rotator cuff anatomically to its greater tuberosity footprint insertion site increases the potential for improved functional outcomes and patient satisfaction in revision rotator cuff repair.¹

Alternatives to revision rotator cuff repair, such as superior capsular reconstruction (SCR) and even reverse shoulder arthroplasty, have been used in clinical situations for which the rotator cuff tear is deemed irreparable.⁵ Although these procedures offer patients the potential for good and even excellent clinical outcomes when used in appropriate clinical situations, they should be reserved for those patients in whom the

rotator cuff tear cannot be adequately reconstructed. One key to achieving a functional repair of the rotator cuff, and thus avoiding these more invasive, salvage-type procedures such as SCR and reverse shoulder arthroplasty, is accurately identifying all repairable rotator cuff tissue. Because these dense adhesions of the rotator cuff to the acromion may be difficult to recognize in a revision repair setting, the undersurface of the acromion should be specifically visualized and probed, especially when large rotator cuff defects appear to be present. Last, the amount of retraction and lower quality of the rotator cuff tissue that may be available in a revision setting can present additional challenges for the surgeon intraoperatively. Likewise, the necessity for more prolonged rehabilitation and recovery timetables in some of these patients creates postoperative challenges as well (Table 1).

The advantages of this technique are that the patient's own tissue is being used and the rotator cuff is restored to the footprint. This allows for the surgeon to forego use of an autograft or allograft for an SCR, delaying the need for a reverse total shoulder arthroplasty. Release and mobilization of the native rotator cuff tissue and even partial repair have provided for excellent results.⁶ Risks involved with use of this procedure are that during the release the tissue quality deteriorates or is resected, requiring the surgeon to proceed with one of the previously mentioned procedures.

Conclusions

This technique requires attention to tissue planes for preservation of the cuff tissue that remains. Overall, this technique gives the surgeon another tool in his or her toolbox to provide an arthroscopic solution to a problem that may commonly be solved with a more invasive open procedure (Table 2).

References

1. Ladermann A, Denard P, Burkart S. Management of failed rotator cuff repair: A systematic review. *J ISAKOS* 2016. <https://doi.org/10.1136/jisakos-2015-000027>.
2. Desmoineaux P. Failed rotator cuff repair. *Orthop Traumatol Surg Res* 2018 [Epub ahead of print].
3. Bedeir YH, Jimenez AE, Grawe BM. Recurrent tears of the rotator cuff: Effect of repair technique and management options. *Orthop Rev (Pavia)* 2018;10:7593.
4. Montgomery S, Petrigliano F, Gamradt S. Failed rotator cuff surgery, evaluation and decision making. *Clin Sports Med* 2012;693-712.
5. Strauss E, McCormak R, Onyekwelu I, Rokito A. Management of failed arthroscopic rotator cuff repair. *J Am Acad Orthop Surg* 2012;20.
6. Iagulli ND, Field LD, Hobgood ER, Ramsey JR, Savoie FH. Comparison of partial versus complete arthroscopic repair of massive rotator cuff tears. *Am J Sports Med* 2012;40:1022-1026.