

Challenging Airway Management in a Patient with Retrosternal Goiter Presenting in Respiratory Distress

Babatunde B. Osinaike¹, Alaba O. Ogunsiji², Olufunke C. Joseph²

¹Department of Anaesthesia, University of Ibadan/ University College Hospital, Ibadan, Nigeria, ²Department of Anaesthesia, University College Hospital, Ibadan, Nigeria

Submitted: 06-Nov-2019
Revised : 24-Jan-2020
Accepted : 26-Mar-2020
Published : 09-Mar-2021

ABSTRACT

A number of options exist for patients with anticipated difficult intubation on account of a retrosternal goiter compressing on the trachea. The chosen technique(s) to secure the airway in this delicate situation often depends on the location and degree of airway obstruction, available resources/facilities, and an anesthetist's experience and preferences. We report the case of a 68-year-old woman with severe airway obstruction from a retrosternal goiter coming for total thyroidectomy. Airway management started with an awake fiber-optic intubation, proceeded to a tracheostomy and finally to use of a rigid bronchoscope following failure of the earlier techniques to achieve adequate ventilation.

KEYWORDS: *Difficult airway, retrosternal goiter, rigid bronchoscope*

INTRODUCTION

Goiter is known to be endemic in some developing nations, particularly in regions where iodine deficiency is likely. The prevalence of endemic goiter in Nigeria is put at 1%–23%.^[1] Late presentation in resource-poor settings means there is an increased likelihood of having to deal with a large goiter which may be compressing on the airway. Majority of these cases do not present significant difficulty during tracheal intubation. The incidence of difficult intubation in patients with goiter has been reported to range from 2% to 12.7%, whereas failed intubation occurs in 0.3%–0.5% of cases.^[2] In Northern Nigeria, Olusomi *et al.*^[3] reported incidences of difficult intubation and failed intubation of 13.6% and 1.6%, respectively.

For patients having tracheal compression from their goiter, commonly utilized airway management techniques include routine laryngoscopy and intubation, awake fiber-optic intubation (AFOI), and tracheostomy when feasible.^[4-6] Although usually included in the airway management plan, rigid bronchoscopy is rarely needed.

CASE REPORT

A 68-year-old woman with body mass index of 34.88 kg/m² (102 kg, 171 cm) presented to our hospital with a 5-year history of anterior neck swelling and a progressively worsening breathlessness of 2-year

duration. She had presented 8 months earlier but defaulted before she could be scheduled for surgery.

Breathlessness was worse on lying down, and she occasionally had acute exacerbations in breathlessness. She was not previously known to be asthmatic, and such exacerbations were poorly responsive to nebulization with salbutamol. Breathlessness became distressing a week before the presentation. There was an associated history of dysphonia but no history suggestive of thyrotoxicosis. The patient is a known hypertensive of 25 years' duration regular on medications. She had no history of surgery or exposure to anesthesia.

On examination, we found an elderly woman in semi-recumbent position, dyspneic at rest, and on oxygen (O₂) supplementation by nasal prongs at 4 L/min. The patient was not pale and not cyanosed. A firm lower anterior neck mass measuring 6 cm by 4 cm was noted. It was possible to get above but not below the mass. Her respiratory rate was 34 cycles/min, with trachea deviated to the left. There was adequate mouth opening, Mallampati score was 2, and thyromental distance was 8 cm. There was globally reduced air entry with

Address for correspondence: Dr. Alaba O. Ogunsiji, Department of Anaesthesia, University College Hospital, Ibadan, Nigeria.
E-mail: ogunsijialaba@gmail.com

This is an open access journal, and articles are distributed under the terms of the Creative Commons Attribution-NonCommercial-ShareAlike 4.0 License, which allows others to remix, tweak, and build upon the work non-commercially, as long as appropriate credit is given and the new creations are licensed under the identical terms.

For reprints contact: WKHLRPMedknow_reprints@wolterskluwer.com

How to cite this article: Osinaike BB, Ogunsiji AO, Joseph OC. Challenging airway management in a patient with retrosternal goiter presenting in respiratory distress. *Niger J Surg* 2021;27:66-70.

Access this article online	
Quick Response Code: 	Website: www.nigerianjsurg.com
	DOI: 10.4103/njs.NJS_58_19

generalized inspiratory and expiratory rhonchi. Oxygen saturation was 96% (84% before commencement of O₂). Her heart rate was 106 beats/min and blood pressure of 140/80 mmHg.

Blood counts were normal, but electrolyte check revealed a potassium level of 3.3 mmol/L (normal 3.5–5.0 mmol/L, corrected to 4.0 mmol/L preoperatively) and HCO₃⁻ of 30 mmol/L (22–26 mmol/L). Arterial blood gas was not available. Thyroid function test showed T4 of 16.7 pmol/L (12–22 pmol/L), T3 of 3.0 pmol/L (3.1–6.8 pmol/L), and Thyroid Stimulating Hormone (TSH) of 1.43 mU/L (0.27–4.2 mU/L). Electrocardiogram (ECG) and echocardiography were essentially normal. Spirometry showed a forced expiratory volume in 1 s (FEV1) of 0.93 L, forced vital capacity (FVC) of 4.04 L, and FEV1/FVC of 23%, an indication of severe airway obstruction.

Chest radiograph showed a huge mediastinal mass with a leftward deviation of the trachea and downward displacement of the heart [Figure 1a]. There were bilateral lower lobe patchy opacities with prominent hilar markings. Computed tomography of the neck and chest revealed a huge soft-tissue mass extending from the root of the neck into the posterior mediastinal region at the level of the tracheal bifurcation. The mass is seen displacing the trachea to the left and compressing on it [Figure 2].

The patient was counseled for AFOI and possible tracheostomy as a backup plan should the initial attempts at securing her airway fail. Consent was obtained accordingly, and she was fasted for 8 h. An appropriately sized double-lumen tube was not available, so nonkinkable endotracheal tubes (ETT) of different sizes were gotten instead.

The patient was taken to the theater for surgery 3 days after the presentation. Two large bore cannulae were inserted, and intravenous glycopyrrolate 0.2 mg,

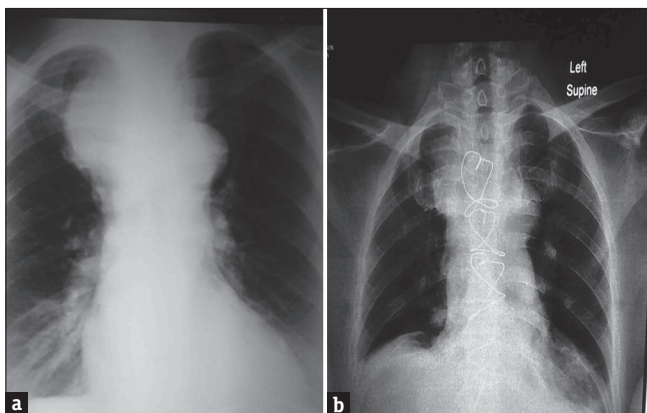


Figure 1: (a) Preoperative chest radiograph showing mediastinal mass with tracheal deviation to the left. (b) Postoperative radiograph showing centralized trachea. Sternotomy wire *in situ*

dexamethasone 8 mg, and ranitidine 50 mg were given as premedication. Routine monitors (ECG, Non-invasive blood pressure (NIBP), pulse oximeter, and temperature probe) were attached and baseline values obtained. Oxygen supplementation was continued with the patient in sitting position with SpO₂ ranging between 94% and 97%. An intraarterial line for continuous blood pressure monitoring was also inserted under local anesthesia.

Following spraying of the nasal cavity and nasopharynx with 2% xylocaine, awake fiber-optic nasotracheal intubation was commenced with a size 6.5 mm I.D nonkinkable ETT. Intubation was successful; however, the ETT stopped just above the level of obstruction proximal to the carina. Air entry remained very poor bilaterally with measured tidal volumes ranging between 100 and 150 ml. Oxygen saturation remained stable at about 95% on FiO₂ of 1 until the patient was sedated using sevoflurane at 2%; saturation promptly dropped to <90% necessitating the discontinuation of inhalational agent.

After discussions between the anesthetist; ear nose, and throat (ENT); and cardiothoracic team leaders, it was agreed to do a tracheostomy in hope that inserting an ETT through the tracheal opening will allow for placement distal to the obstruction. A tracheostomy was done by the ENT surgeon under local anesthetic (1% lidocaine + adrenaline 1:200,000) infiltration. Subsequently, the *in situ* nasotracheal tube was withdrawn, and a new ETT inserted through the tracheal stoma. However, all attempts to go beyond the obstruction in the distal trachea proved abortive despite using different sizes of ETT (7.0, 6.5, and 6.0 mm, respectively). Air entry remained very poor, without improvement in oxygen saturation.

As a last resort, it was decided to utilize a rigid bronchoscope. Anesthesia was deepened using sevoflurane 5% and IV fentanyl 50 µg. A size 8-mm rigid bronchoscope was carefully inserted under direct vision by the cardiothoracic surgeon. It went through the narrowed portion of the trachea and was advanced further until placed just above the carina. The breathing circuit was then connected to the side port of the bronchoscope and the patient ventilated through the bronchoscope [Figure 3]. There was noticeable bilateral chest expansion with improved air entry on auscultation. Measured tidal volume was in the range of 300–350 ml, and oxygen saturation promptly improved to 100% on FiO₂ of 1. A throat pack was put in place to minimize air leakage, and the patient's teeth protected with gauze around the bronchoscope.

With ventilation now adequate, an initial dose of 50 mg suxamethonium was administered to assess the effect of

muscle relaxation on the patient's respiratory dynamics. Satisfied that respiration remained optimal despite muscle relaxation, a long-acting muscle relaxant, pancuronium 5 mg, was then given. Adequate analgesia was ensured with intravenous morphine 5 mg, and maintenance of anesthesia was with isoflurane as tolerated.

Surgery commenced with the ENT team dissecting the anterior neck mass. The whole mass could not be removed from a cervical approach, so the cardiothoracic team performed a sternotomy to mobilize the mediastinal part of the goiter. The resected thyroid mass, the larger part of which was retrosternal, weighed 300 g [Figure 4]. The tracheostomy stoma was closed primarily. Oxygen saturation remained satisfactory (98%–100%) throughout the course of surgery.

At the end of the surgery, the throat pack was removed. While the patient was still under anesthesia and muscle paralysis, the rigid bronchoscope was gradually withdrawn ensuring that ventilation remained feasible at every point in time. Satisfied that there was no airway collapse with the withdrawal of the bronchoscope beyond the previously obstructed portions, the bronchoscope was removed and the patient was intubated with a size 7.0-mm ETT. Saturation remained satisfactory with good air entry bilaterally. Isoflurane was discontinued, and neuromuscular blockade reversed with the administration of neostigmine 2.5 mg and glycopyrrolate 0.4 mg.

Following adequate reversal of neuromuscular blockade and awakening from anesthesia, the patient was transferred on O₂ supplementation to the intensive care unit (ICU) for postoperative observation. She was said to have self-extubated about 4 h after the surgery and was placed on O₂ by nonrebreathing facemask. Saturation remained stable ranging between 98% and 100%. By the next day, the facemask was replaced with nasal prongs which was well tolerated. However, further attempts to completely wean off O₂ failed as the patient persistently desaturated off O₂. She was commenced on physiotherapy and incentive spirometry.

Postoperative chest radiograph showed a centralized trachea, widened mediastinum, and homogenous opacity in the lower lobe of the right lung [Figure 1b]. Four days after the surgery, the patient was discharged from the ICU to the ward on O₂ by nasal prongs. She was completely weaned off O₂ by 8 days postoperative and discharged home on the 12th day after the surgery.

DISCUSSION

Majority of goiters, including those with retrosternal extension, present no difficulty during endotracheal intubation and ventilation. In a retrospective review

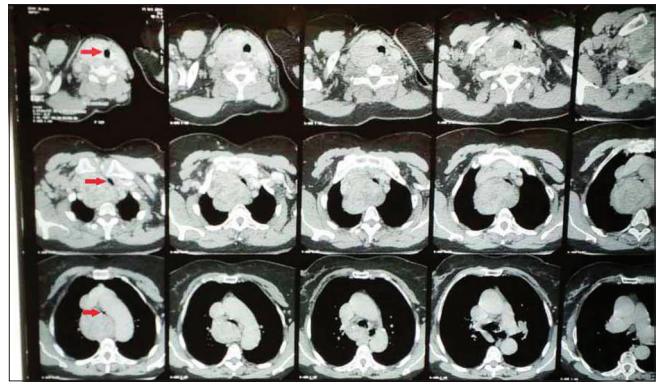


Figure 2: Neck and chest computed tomography scan showing progressively narrowed trachea with the area of minimum trachea diameter close to the carina

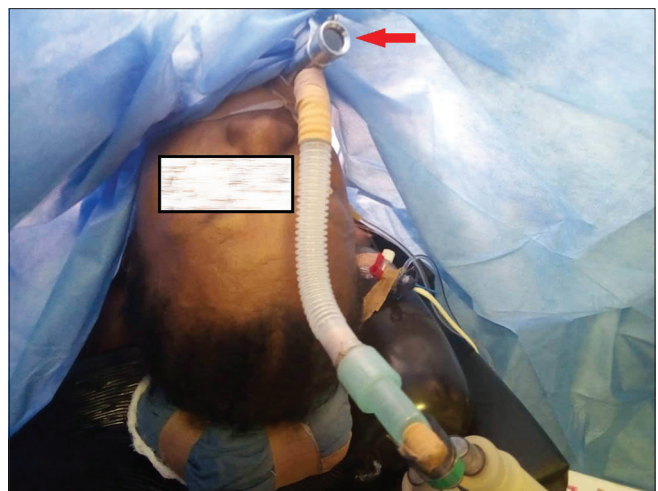


Figure 3: Rigid bronchoscope *in situ*, connected to a breathing circuit

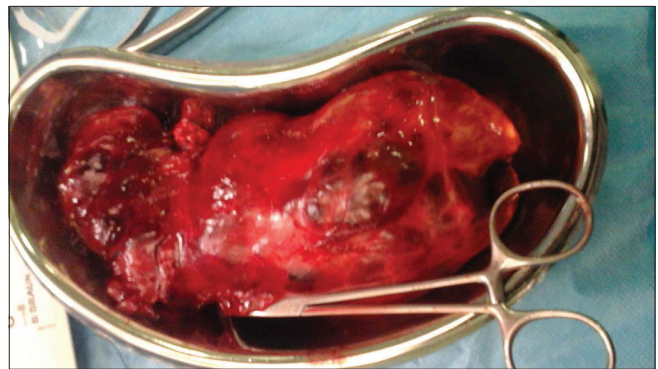


Figure 4: Excised 300 g retrosternal goiter

by Dempsey *et al.*,^[4] of 19 patients with massive retrosternal goiters (three of whom had evident stridor) for surgery, 18 had successful direct laryngoscopy and intubation. Only one required an AFOI as a second technique. All 19 patients were easily ventilated following intubation. Nonetheless, airway management in the setting of a massive retrosternal goiter could be challenging with the potential for cardiorespiratory

collapse. The reduction in or loss of muscle tone that follows the administration of anesthetic agents or muscle relaxants could convert a partial airway obstruction into a complete obstruction that presents with inability to ventilate by face mask.^[7,8] Reduction in thoracic volume as well as cephalad displacement of the diaphragm following induction of anesthesia also brings about changes in airway pressures that impact negatively on ventilation in a patient with airway compression.^[8] The resulting hypoxemia, if not promptly managed, may have catastrophic outcomes.

Routine clinical airway assessment techniques such as Mallampati score, thyromental distance, and lower lip bite test, may prove useful in identifying patients that would otherwise have a difficult laryngoscopy and intubation. However, they provide no clue on the likelihood of an ETT bypassing the compression caused by a huge goiter. Radiologic investigations such as computed tomography scan help identify the level and degree of obstruction, offering a guide to the type and size of ETT to use. In the patient under review, the presence of dyspnea at rest, an FEV1/FVC ratio of 23% and radiologic confirmation of severe tracheal compression guided our choice of airway management options. We considered induction of anesthesia and muscle relaxation for direct laryngoscopy and intubation to be quite risky and as such opted for safer alternatives.

The goal of airway management in this setting is to maintain airway patency as much as possible while selecting the airway management technique that would most likely secure the airway at the first attempt. In the presence of significant airway compression, many airway experts opine that the induction of anesthesia and muscle relaxation be delayed until after the airway is secured.^[9] In these group of patients, AFOI has been touted as the safest method to secure the airway and is very often the plan of the first choice.^[9] The risk of aspiration and sudden airway collapse are minimized as the patient remains awake until the airway is secured. Backup plans are, however, necessary in the event of failure to intubate or failure to bypass the obstruction following AFOI.

Awake tracheostomy was feasible in the patient under review as the goiter had a relatively small cervical component. A similar approach was employed by El-Dawlatly *et al.*,^[6] where an awake tracheostomy was done following previously failed AFOI attempts. In the patient under review, passing the ETT through a tracheostomy stoma allowed for adequate ETT length to reach the level of obstruction. Sajid and Rekha^[10] found that patients with goiter having trachea compression still had an easy passage of normal-sized ETT.

Even among four adult patients with critical trachea compression (minimum trachea diameter <5 mm), three were successfully intubated with normal-sized (7 mm) ETTs, whereas the last one required a 6-mm ETT. This was, however, not the case in our patient suggesting that the compression was less readily displaceable. Softening of an ETT by wet heating makes it more pliable, but there is a dearth of literature on its use in the setting of severe airway obstruction. However, softened tubes are generally more prone to kinking and collapse, further worsening ventilation in both instances.

Rigid bronchoscope has always had a place in the management of difficult airways, including difficulty caused by mediastinal masses.^[11] In a compilation of expert opinions on difficult airway management in a patient with retrosternal goiter, seven out of eight airway management experts chose rigid bronchoscopy as a backup plan.^[9] Although rarely required, occasional cases of very challenging airways like ours justify its continued inclusion in the airway management plan.

CONCLUSION

Airway management in patients with massive retrosternal goiter could be challenging, requiring vital input, from planning to execution, from a multidisciplinary team including anesthesiologists, ENT, and cardiothoracic surgeons. Adequate preparation for multiple airway techniques must be made. Rigid bronchoscopy remains a useful alternative technique for managing a difficult airway in retrosternal goiters and should be part of the airway management plan.

Declaration of patient consent

The authors certify that they have obtained all appropriate patient consent forms. In the form the patient(s) has/have given his/her/their consent for his/her/their images and other clinical information to be reported in the journal. The patients understand that their names and initials will not be published and due efforts will be made to conceal their identity, but anonymity cannot be guaranteed.

Financial support and sponsorship

Nil.

Conflict of interest

There are no conflicts of interest.

REFERENCES

1. Ogbera AO, Kuku SF. Epidemiology of thyroid diseases in Africa. *Indian J Endocrinol Metab* 2011;15:S82-8.
2. Kamath SS, Naik SA, Pratiksha NP. Retrosternal goitre-an anaesthetic challenge. *J Clin Diagn Res*. 2019;13:UD01-3.
3. Olusomi BB, Aliyu SZ, Babajide AM, Sulaiman AO, Adegboyega OS, Gbenga HO, *et al.* Goitre-related factors

- for predicting difficult intubation in patients scheduled for thyroidectomy in a resource-challenged health institution in North central Nigeria. *Ethiop J Health Sci* 2018;28:169-76.
4. Dempsey GA, Snell JA, Coathup R, Jones TM. Anaesthesia for massive retrosternal thyroidectomy in a tertiary referral centre. *Br J Anaesth* 2013;111:594-9.
 5. Raval CB, Rahman SA. Difficult airway challenges-intubation and extubation matters in a case of large goiter with retrosternal extension. *Anesth Essays Res* 2015;9:247-50.
 6. El-Dawlatly A, Takroui M, Elbakry A, Ashour M, Kattan K, Hajjar W, *et al.* Perioperative management of huge goiter with compromised airway. *Int J Anesthesiol* 2002;7:1-5.
 7. Bajwa SJ, Sehgal V. Anesthesia and thyroid surgery: The never ending challenges. *Indian J Endocrinol Metab* 2013;17:228-34.
 8. Erdős G, Tzanova I. Perioperative anaesthetic management of mediastinal mass in adults. *Eur J Anaesthesiol* 2009;26:627-32.
 9. Cook TM, Morgan PJ, Hersch PE. Equal and opposite expert opinion. Airway obstruction caused by a retrosternal thyroid mass: Management and prospective international expert opinion. *Anaesthesia* 2011;66:828-36.
 10. Sajid B, Rekha K. Airway management in patients with tracheal compression undergoing thyroidectomy: A retrospective analysis. *Anesth Essays Res* 2017;11:110-6.
 11. Chao YK, Liu YH, Hsieh MJ, Wu YC, Liu HP, Wang CJ, *et al.* Controlling difficult airway by rigid bronchoscope-an old but effective method. *Interact Cardiovasc Thorac Surg* 2005;4:175-9.