

# Delayed Wound Healing After Achilles Tendon Suture: An Arthroscopic Solution



Hong-yu Chen, M.D., Ying-fang Ao, M.D., and Yu-ping Yang, M.D.

**Abstract:** This technical note describes an arthroscopic technique for treating delayed wound healing after Achilles tendon suture. Ankle arthroscopy is used to clean up the inflammatory tissues and foreign bodies that lead to delayed wound healing, with the advantages of simple postoperative care and low infection risk. This method may provide a less traumatic and low-risk option for the treatment of delayed wound healing after Achilles tendon surgery. The purpose of this technical note is to describe surgical procedures and related recommendations.

**A**chilles tendon rupture is a relatively common type of sports injury. Most Achilles tendon ruptures occur during leisure sports, and the incidence is also showing an increasing trend.<sup>1-3</sup> Regarding the treatment of acute Achilles tendon rupture, there is currently no clear evidence indicating what method is best,<sup>4,5</sup> but surgical treatment more effectively reduces the risk of rerupture of the Achilles tendon compared with nonsurgical treatment.<sup>6,7</sup> Patients with higher requirements for Achilles tendon function often choose surgical treatment, but they need to also bear the corresponding postoperative complications, including foreign body reaction, skin laceration, skin necrosis, scar adhesion, and delayed wound healing.<sup>8-10</sup> Among these complications, delayed wound healing after

Achilles tendon suture<sup>11</sup> will hinder the patient's recovery and affect quality of life.

The occurrence of delayed healing is related to the anatomic characteristics of the Achilles tendon and surrounding skin,<sup>12</sup> but some specific conditions are causative, such as local foreign body reactions caused by nonabsorbable sutures,<sup>13,14</sup> skin necrosis, or reinjury after surgery. Delayed wound healing may also be caused by deep infection,<sup>15,16</sup> which requires special attention.

If conservative treatment cannot be adopted, the conventional treatment is to keep the wound open and perform daily irrigation and routine flushing,<sup>17,18</sup> but this approach leaves a larger wound that takes longer to heal and increases the difficulty of postoperative care. We pioneered the use of arthroscopy to treat delayed wound healing after Achilles tendon suture, and our results have been satisfactory.

The purpose of this Technical Note is to introduce the surgical procedure and analyze its clinical significance and advantages over conventional open surgery, to provide an alternative idea for the treatment of patients with delayed healing.

## Surgical Technique

### Preoperative Evaluation

It is necessary to understand the patient's medical history before surgery and evaluate the patient's wound for delayed healing and current condition (Fig. 1). Magnetic resonance imaging is helpful to find inflammatory changes in the surrounding tissues of the Achilles tendon, which can determine the surgical site and the weakened area of the Achilles tendon. Patients

From the Peking University Health Science Center, Beijing, P.R. China (H.C.); and the Department of Sports Medicine, Peking University Third Hospital, Beijing Key Laboratory of Sports Injuries, Beijing, P.R. China (Y.A., Y.Y.).

The study was supported by Integrated application of technology and comprehensive demonstration Project of Scientific and Technological Winter Olympics of Zhangjiakou in 2020 (20110004D) and 2021 (21110006D).

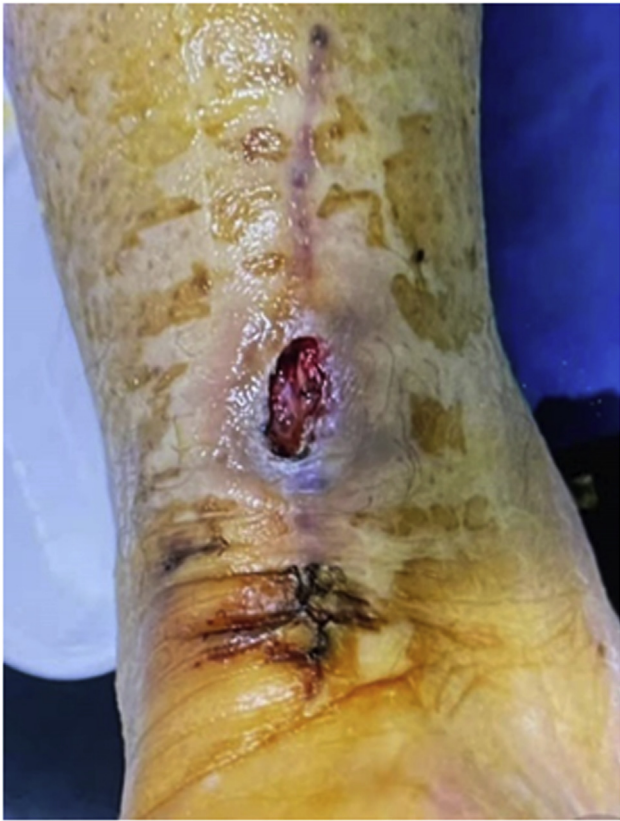The authors report that they have no conflicts of interest in the authorship and publication of this article. Full ICMJE author disclosure forms are available for this article online, as [supplementary material](#).

Received October 11, 2021; accepted November 9, 2021.

Addresses correspondence to Yu-ping Yang, M.D., 49 North Garden Rd., Haidian District, Beijing, P.R. China; Ying-fang Ao, M.D., 49 North Garden Rd., Haidian District, Beijing, P.R. China. E-mail: [yypwxh@126.com](mailto:yypwxh@126.com) or [yingfang.ao@vip.sina.com](mailto:yingfang.ao@vip.sina.com)

© 2021 THE AUTHORS. Published by Elsevier Inc. on behalf of the Arthroscopy Association of North America. This is an open access article under the CC BY-NC-ND license (<http://creativecommons.org/licenses/by-nc-nd/4.0/>). 2212-6287/211458

<https://doi.org/10.1016/j.eats.2021.11.007>



**Figure 1.** The dehisced wound after the Achilles tendon suture.

are evaluated before surgery to see if they meet the indications and contraindications for surgery (Table 1).

### Arthroscopy Technique and Postoperative Management

The patient is placed in a prone position, and the foot is placed at the end of the operating table (Fig. 2). A pneumatic tourniquet is applied to the affected lower extremity. The unhealed part of the original incision (original defect) is selected as the portal to insert the shaver, and the other portal (new portal) for inserting the camera is usually selected at the top of the original incision (Fig. 3). This method ensures that the 2 ports are as far away from each other as possible, covers all

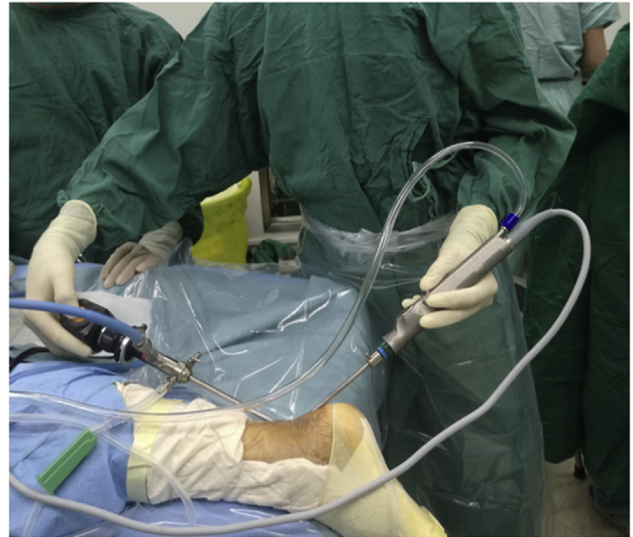**Table 1.** Indications and Contraindications

#### Indications

- (1) The diagnostic criteria for delayed wound healing after Achilles tendon suture are met, namely the presence of skin necrosis, wound nonunion, or delayed wound healing.
- (2) The expected healing time of a regular wound is >2 weeks with regular dressing changes.

#### Contraindications

- (1) Abnormal body temperature (underarm temperature >37.5°C)
- (2) Abnormal coagulation function (platelets  $\leq 50 \times 10/L$ )
- (3) Presence of other diseases; inability to tolerate surgery
- (4) If the expected healing time of wounds with regular dressing changes is <2 weeks



**Figure 2.** Prone position and foot placement.

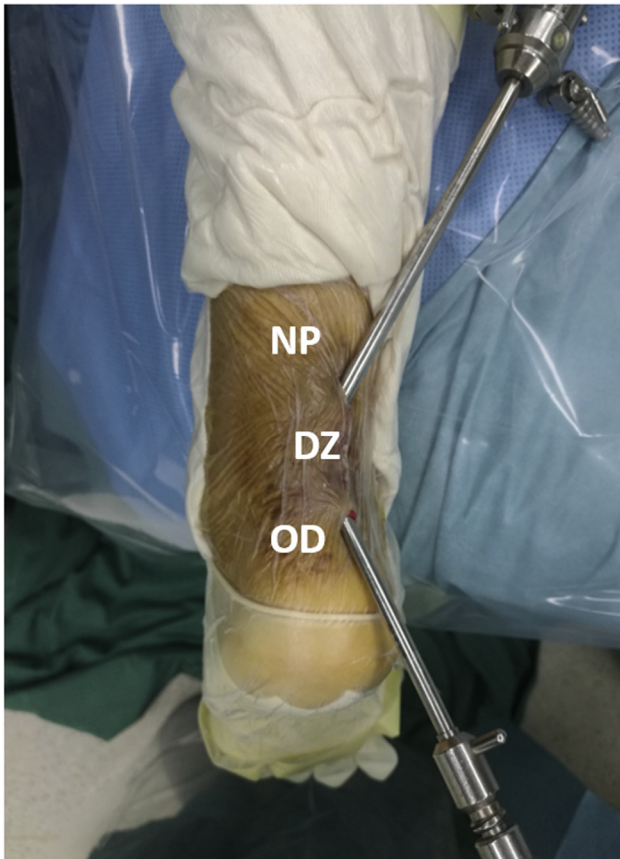
the suture areas of the Achilles tendon from the first operation, and allows full exploration of the surgical area (Video 1).

First, the Achilles tendon and surrounding tissues are explored to identify lesions, which includes inflammatory tissues, infected tissues under the skin or around the Achilles tendon, and necrotic tendons. The shaver is then used to remove these lesions. In this process, it is necessary to avoid excessive damage to the surrounding soft tissues, blood vessels, and nerves. The point of this is to carefully identify whether the tissue has completely lost its biological activity and needs to be removed.

Next, all the weak areas of the Achilles tendon need to be identified. In our experience, most of the weak areas will have healed, but some cavities may still exist. These cavities of Achilles tendon wounds need to be cleaned by shaver. If foreign bodies (nonabsorbable sutures) are found, they should be removed with nucleus pulposus forceps, which can be inserted from the original defect (Fig. 4). If necessary, another portal can be established at the distal end of the scar, so that the distal area of the Achilles tendon can also be accessed by surgery. The operation process is the same as described above (Table 2).

Finally, the subcutaneous tissue is processed. The planer is used to remove the inflamed tissue and scar tissue. Skin tissue that has lost bioactivity around the wound also needs to be cut off, and the skin edge of the wound should be trimmed neatly.

Primary suturing of the wounds is performed (Fig. 5). Roll gauze pads are placed on both sides of the Achilles tendon incision, and a pressure bandage is applied to the surgical area (Fig. 6). The purpose of the pads is to avoid fluid accumulation on the left and right sides of the Achilles tendon. For patients who are in good



**Figure 3.** Endoscopic surgery technique for delayed wound healing after Achilles tendon suture. The shaver and camera were inserted into the existing skin defect and the new portal (NP), respectively, which is generally located at the top of the other side of the original defect (OD). DZ, delayed wound healing zone.

condition and have no wound infection, there is no need to use antibiotics or plaster fixation after surgery, which is also conducive to allowing exercise of the

patient's motor functions. If the blood circulation around the wound is poor and slow to heal, or infection is prone to occur, short-term preventive antibiotics can be used after the operation, and a short leg plaster can be used to fix the foot in natural plantarflexion for 2 weeks. Sutures can be removed 2 to 3 weeks after surgery. The rehabilitation plan can refer to the treatment of acute Achilles tendon rupture.

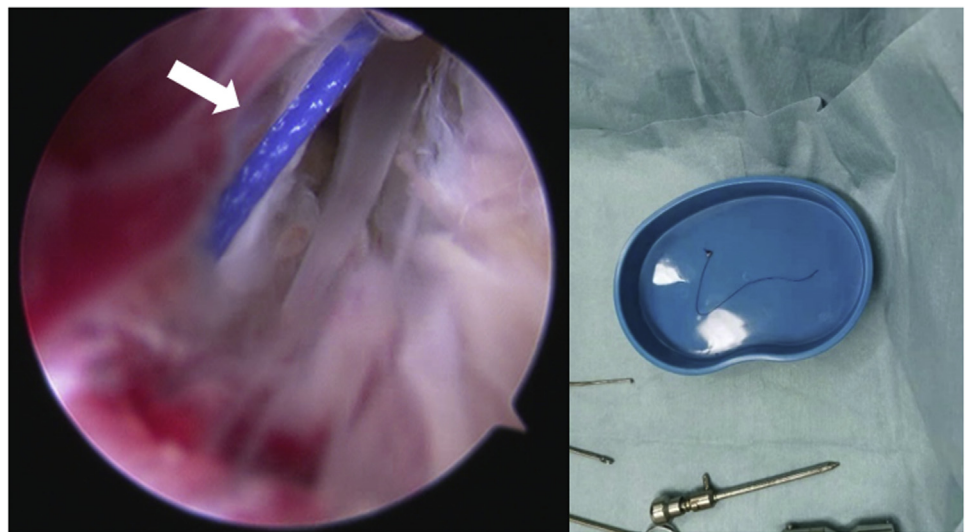
### Discussion

Achilles tendon rupture occurs mainly in young and middle-aged men.<sup>19</sup> If delayed wound healing and infection occur after surgical treatment, the patient will subjectively feel pain around the wound and worry that the wound will not heal. The function of the lower limb will also be greatly affected. The natural properties of trauma and surgical repair have already affected the healing of the wound,<sup>15</sup> and the patient's own condition and surgery-related treatment are also factors that lead to postoperative complications.<sup>20</sup>

Nonabsorbable sutures are widely used after Achilles tendon ruptures because they are considered to provide sufficient fixation strength during the critical healing period.<sup>21,22</sup> However, they can also cause a certain degree of inflammation of the soft tissues<sup>23</sup> or may cause infections, which will affect the healing of the wound. Influence. Itoga et al.<sup>24</sup> reported a case of foreign body granuloma caused by nonabsorbable sutures, which had poor therapeutic effect with antibiotics alone. Surgical treatment was required, an incision was made on the basis of the original scar, and the granuloma was removed.

If the ruptured wound is not covered, the exposed tendon will become dry and subject to secondary adhesions.<sup>10</sup> Although this process does not necessarily cause infection, the treatment methods are similar. Liles and Adams<sup>15</sup> recommended early surgical intervention

**Figure 4.** Nonabsorbable suture can be seen in the arthroscopy; it was removed.



**Table 2.** Pearls and pitfalls

## Pearls

- (1) A dry environment for the arthroscope should be maintained.
- (2) One of the surgical instruments is inserted into the existing defect, which avoids an additional surgical port.
- (3) The 2 ports should be far enough apart to adequately cover the surgical field.

- (4) Explore carefully to detect foreign objects that need removal.

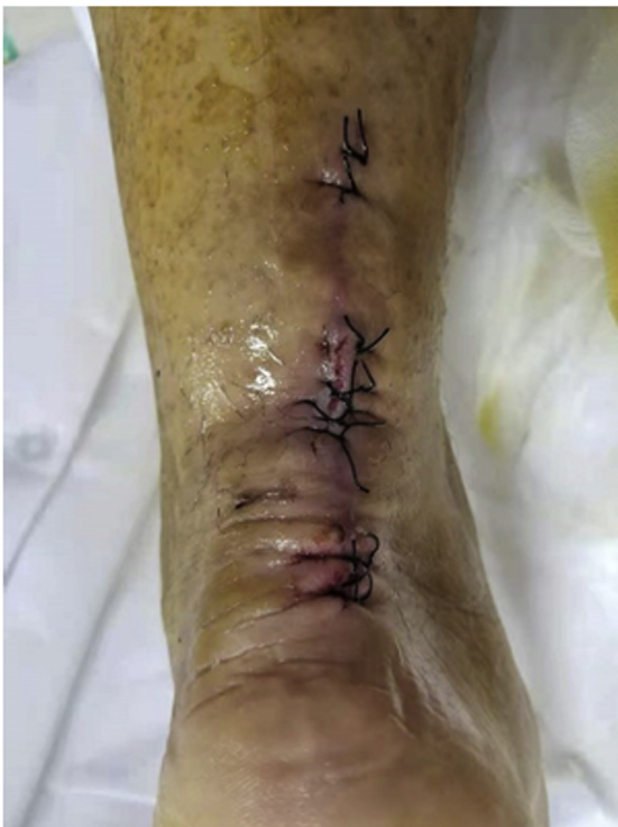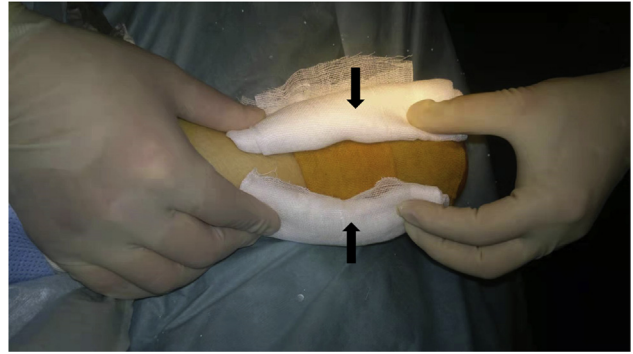
## Pitfalls

- (1) If the cavities of the Achilles tendon have not been obliterated completely, infection or delayed healing may result.
- (2) If there is a foreign body that is removed, such as a nonabsorbable suture, foreign body reaction and pain may result.

(irrigation and debridement) to avoid secondary deep infections.

For patients with infection at the wound site, Bae et al.<sup>25</sup> used open debridement. The wound was kept open after debridement for patients with poor wound condition, and daily irrigation and changing of dressing were performed. The result of a deep infection can be catastrophic. Surgery requires removal of the infected and necrotic tendon. The patient may completely lose the Achilles tendon during treatment.<sup>26</sup>

These days, the use of endoscopic technology in Achilles tendon surgery is normal, and the arthroscopic technique used in Achilles tendon repair was first described by Maquirriain<sup>27</sup> in 1998. This

**Figure 5.** Primary suture of the wounds.**Figure 6.** Roll gauze pads are placed on both sides of the Achilles tendon incision.

technology is not difficult for those who have mastered conventional endoscopy technology, increasing its suitability. Arthroscopy itself has a slighter “second blow” to the wound site, relatively. It has smaller incisions compared with traditional treatment. In addition, after the lesion is cleared, the wound can be primary sutured to avoid the complications that may be caused by an open wound. Depending on the doctor’s evaluation, the application of antibiotics and plaster fixation is not even necessary after the operation, which demonstrates the benefits of this technology (Table 3). Patients can perform early postoperative functional exercises.

During the operation, care to detect whether there is a foreign body left around the Achilles tendon is necessary, because this may cause the patient’s delayed healing. Because of the limited surgical field, and perhaps lack of adequate experience, it may be difficult to find during the operation.

The remaining nonabsorbable sutures may cause relapse, which means that although the wound is completely healed after treatment, inflammation around the Achilles tendon will appear later, which is manifested as redness, swelling, and pain. FiberWire is known to have the risk of causing foreign body reactions,<sup>28</sup> which may require surgery. If it is considered that these symptoms are caused by foreign body reactions, there is no need to perform arthroscopic

**Table 3.** Advantages and limitations

## Advantages

- (1) No requirement for the wound to be open postoperatively for multiple irrigations
- (2) Improved visibility of the surgical field
- (3) Smaller incisions compared with traditional treatment
- (4) Reduced need for postoperative antibiotics
- (5) Rehabilitation exercises may be resumed quickly

## Limitations

- (1) A minor local procedure may be needed at a later stage if a foreign body has not been removed completely.
- (2) The cost of this technique is higher than conventional open surgery.

surgery again. Instead, a small incision can be made directly under local anesthesia, and the sutures can be taken out. Therefore, when using this technology to treat patients, the risk needs to be communicated to patients in advance. In addition, taking into account the difficulty of arthroscopic surgery and supplies, there will be a higher cost compared with conventional open surgery.

## Conclusions

This technical note describes an arthroscopic technique for delayed wound healing after Achilles tendon suture. Compared with conventional open surgery, it has the characteristics of lower risk of intraoperative injury and postoperative infection, easier postoperative care, and faster wound recovery.

## References

- Leppilahti J, Orava S. Total Achilles tendon rupture. A review. *Sports Med* 1998;25:79-100.
- Ganestam A, Kallemose T, Troelsen A, Barfod KW. Increasing incidence of acute Achilles tendon rupture and a noticeable decline in surgical treatment from 1994 to 2013. A nationwide registry study of 33,160 patients. *Knee Surg Sports Traumatol Arthrosc* 2016;24:3730-3737.
- Lantto I, Heikkinen J, Flinkkilä T, Ohtonen P, Leppilahti J. Epidemiology of Achilles tendon ruptures: Increasing incidence over a 33-year period. *Scand J Med Sci Sports* 2015;25:e133-e138.
- Ochen Y, Beks RB, van Heijl M, Hietbrink F, Leenen LPH, van der Velde D, Heng M, van der Meijden O, Groenwold RHH, Houwert RM. Operative treatment versus nonoperative treatment of Achilles tendon ruptures: Systematic review and meta-analysis. *BMJ* 2019;364, k5120.
- Nilsson-Helander K, Silbernagel KG, Thomeé R, Faxén E, Olsson N, Eriksson BI, Karlsson J. Acute achilles tendon rupture: A randomized, controlled study comparing surgical and nonsurgical treatments using validated outcome measures. *Am J Sports Med* 2010;38:2186-2193.
- Zhou K, Song L, Zhang P, Wang C, Wang W. Surgical versus non-surgical methods for acute Achilles tendon rupture: A meta-analysis of randomized controlled trials. *J Foot Ankle Surg* 2018;57:1191-1199.
- Wilkins R, Bisson LJ. Operative versus nonoperative management of acute Achilles tendon ruptures: A quantitative systematic review of randomized controlled trials. *Am J Sports Med* 2012;40:2154-2160.
- Reda Y, Farouk A, Abdelmonem I, El Shazly OA. Surgical versus non-surgical treatment for acute Achilles' tendon rupture. A systematic review of literature and meta-analysis. *Foot Ankle Surg* 2020;26:280-288.
- Deng S, Sun Z, Zhang C, Chen G, Li J. Surgical treatment versus conservative management for acute achilles tendon rupture: A systematic review and metaanalysis of randomized controlled trials. *J Foot Ankle Surg* 2017;56:1236-1243.
- Young JS, Kumta SM, Maffulli N. Achilles tendon rupture and tendinopathy: Management of complications. *Foot Ankle Clin* 2005;10:371-382.
- Schipper O, Cohen B. The acute injury of the Achilles: Surgical options (open treatment, and, minimally invasive surgery). *Foot Ankle Clin* 2017;22:689-714.
- Dayton P. Anatomic, vascular, and mechanical overview of the Achilles tendon. *Clin Podiatr Med Surg* 2017;34:107-113.
- Kara A, Celik H, Seker A, Uysal MA, Uzun M, Malkoc M. Granuloma formation secondary to Achilles tendon repair with nonabsorbable suture. *Int J Surg Case Rep* 2014;5:720-722.
- Ahluwalia R, Zourelidis C, Guo S, Dega R. Chronic sinus formation using non absorbable braided suture following open repair of Achilles tendon. *Foot Ankle Surg* 2013;19:e7-e9.
- Liles J, Adams SB Jr. Management of complications of Achilles tendon surgery. *Foot Ankle Clin* 2019;24:447-457.
- Mosser P, Kelm J, Anagnostakos K. Negative pressure wound therapy in the management of late deep infections after open reconstruction of Achilles tendon rupture. *J Foot Ankle Surg* 2015;54:2-6.
- Fourniols E, Lazennec JY, Rousseau MA. Salvage technique for postoperative infection and necrosis of the Achilles tendon. *Orthop Traumatol Surg Res* 2012;98:915-920.
- Saku I, Kanda S, Saito T, Fukushima T, Akiyama T. Wound management with negative pressure wound therapy in postoperative infection after open reconstruction of chronic Achilles tendon rupture. *Int J Surg Case Rep* 2017;37:106-108.
- Raikin SM, Garras DN, Krapchev PV. Achilles tendon injuries in a United States population. *Foot Ankle Int* 2013;34:475-480.
- Yang YP, Chen HY, Cui GQ, Xiu XL, Liu XP, An H, Ao YF. Endoscopic surgery for delayed wound healing after achilles tendon suture repair: A report of three cases. *Orthop Surg* 2021;13:1126-1131.
- Carmont MR, Kuiper JH, Grävare Silbernagel K, Karlsson J, Nilsson-Helander K. Tendon end separation with loading in an Achilles tendon repair model: Comparison of non-absorbable vs. absorbable sutures. *J Exp Orthop* 2017;4:26.
- Barber FA, Herbert MA, Richards DP. Sutures and suture anchors: Update 2003. *Arthroscopy* 2003;19:985-990.
- Cho J, Kim HJ, Lee JS, Kim J, Won SH, Yi Y, Chun DI. Comparing absorbable and nonabsorbable suture materials for repair of Achilles tendon rupture: A magnetic resonance imaging-based study. *Diagnostics (Basel)* 2020;10:1085.
- Itoga R, Matsuoka M, Onodera T, Shimizu A, Iwasaki K, Matsubara S, Hishimura R, Kondo E, Iwasaki N. Delayed onset of infectious foreign body granuloma for nonabsorbable sutures after open Achilles tendon repair: A case report. *J Foot Ankle Surg* 2021. S1067-251600258-1.
- Bae SH, Lee HS, Seo SG, Kim SW, Gwak HC, Bae SY. Debridement and functional rehabilitation for Achilles tendon infection following tendon repair. *J Bone Joint Surg Am* 2016;98:1161-1167.

26. Pajala A, Kangas J, Ohtonen P, Leppilahti J. Rerupture and deep infection following treatment of total Achilles tendon rupture. *J Bone Joint Surg Am* 2002;84:2016-2021.
27. Maquirriain J. Endoscopic release of Achilles peritenon. *Arthroscopy* 1998;14:182-185.
28. Barp EA, Reese ER, Jones NEH, Blied ZJ. Heel complications. *Clin Podiatr Med Surg* 2021;38:183-191.