



Case report

Delayed Femoral Artery Occlusion After Total Hip Arthroplasty via the Posterior Approach: A Single-Case Report From Thailand

Payap Payapanon, MD, Pakpoom Ruangsomboon, MD, Rapeepat Narkbunnam, MD, Keerati Chareancholvanich, MD, Chaturong Pornrattanamanee Wong, MD *

Department of Orthopaedic Surgery, Faculty of Medicine Siriraj Hospital, Mahidol University, Bangkok, Thailand

ARTICLE INFO

Article history:
Received 2 February 2021
Received in revised form
23 April 2021
Accepted 25 April 2021
Available online xxx

Keywords:
Delayed femoral artery occlusion
Total hip arthroplasty
Posterior approach
Thailand

ABSTRACT

Arterial injury after total hip arthroplasty is rare, but the consequences of this complication are serious and potentially life-threatening. Here, we report a case of delayed-onset common femoral artery occlusion after total hip arthroplasty that was performed via the posterior approach at Siriraj Hospital—Thailand's largest university-based national tertiary referral center. Our case was successfully treated with arterial thromboembolectomy. We postulate that anterior retractor placement caused intimal injury to the vessel. Routine monitoring of postoperative vascular pulse is essential. Early detection and prompt vascular surgeon consultation are the important factors for preventing the potentially catastrophic consequences of this complication.

© 2021 The Authors. Published by Elsevier Inc. on behalf of The American Association of Hip and Knee Surgeons. This is an open access article under the CC BY-NC-ND license (<http://creativecommons.org/licenses/by-nc-nd/4.0/>).

Introduction

Arterial injury after total hip arthroplasty (THA) is a rare, serious, and potentially life-threatening complication [1], and its occurrence can adversely influence the functional outcome and prognosis of the operated limb. A systematic review by Alshameeri et al. revealed rates of incidence of vascular injury of 0.04% in primary THA and of 0.19% in revision surgery [1]. During THA, the common femoral artery was proposed to be the artery most likely to be affected [2]. However, as this vessel is located anterior to the hip joint, THA via a posterior approach is associated with reduced risk of this potentially catastrophic complication. Here, we report a case of delayed-onset intimal injury-induced common femoral artery occlusion after THA via the posterior approach. The patient's clinical presentation, the potential causes of vessel injury, our treatment strategy, and the patient's outcome are hereafter described.

Case history

A 60-year-old Thai female (weight, 53 kg; height, 151 cm; body mass index, 23.2 kg/m²) was admitted to the Department of Orthopedic Surgery of the Faculty of Medicine Siriraj Hospital,

Mahidol University, Bangkok, Thailand, with a diagnosis of developmental dysplastic hip with secondary osteoarthritis of the right hip (Fig. 1). Written informed consent was obtained from the patient to publish her case and images. She had a history of progressive right groin pain for 1 year. The dorsalis pedis and posterior tibial pulses were palpable and symmetric. During the operation, the patient was placed in the left lateral decubitus position after administration of regional anesthesia. A posterolateral approach was used to obtain exposure, and a cementless THA then was performed. The operative time was 70 minutes with an estimated blood loss of 500 ml. To expose the acetabulum, 3 curved Hohmann retractors with blunt tips were used to sequentially retract the anterior, inferior, and posterior tissues. During this process, no pulsatile or massive bleeding was observed.

Immediately after surgery, the dorsalis pedis and posterior tibial pulses of her right foot were both palpable. After postoperative observation, she was returned to the orthopedic ward. Postoperative radiograph of both hips is shown in Figure 2. After 13 hours, she complained of pain and numbness at her right leg. Physical examination by an orthopedic surgery resident revealed decreased sensation in her right leg and weakness of the tibialis anterior and extensor hallucis longus muscles; however, her distal pulses were both still palpable. At 25 hours after surgery, she was experiencing progressive pain and numbness in her right leg. Repeat physical examination revealed that her right leg had become cold and that her dorsalis pedis, posterior tibial, popliteal, and femoral artery pulses were absent. Emergency arterial Doppler

* Corresponding author. 2 Thanon Wang Lang, Siriraj, Bangkok Noi, Bangkok 10700, Thailand. Tel.: +660817553977.

E-mail address: toonchaturong@gmail.com

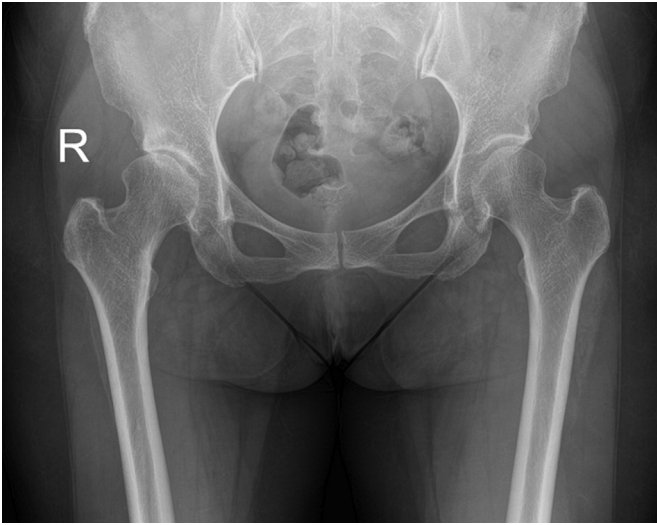


Figure 1. Preoperative radiograph of the patient, both hip AP.

scan showed complete occlusion of the right femoral artery. A vascular surgeon was consulted immediately, and the decision was made to perform emergency right femoral thromboemblectomy and prophylactic fasciotomy of the right leg. The intraoperative findings revealed a tear in the tunica adventitia of the anterior wall of the common femoral artery (Fig. 3). No complete rupture was detected. After the right femoral artery was exposed, intimal tear of the posterior wall was observed. A thrombus that extended to the anterior and posterior tibial arteries was removed (Fig. 4). The femoral artery was examined, and the artery had no atherosclerosis. The vessel was recanalized, and good blood flow was established. Her distal pulses were all palpable postoperatively. The fasciotomy site was closed at 2 weeks after thromboemblectomy. Her leg numbness and weakness gradually improved during the first 3 months after thromboemblectomy surgery. At the 6-month follow-up, our patient had good function of her hip with full recovery of motor power, but she reported continued numbness at the lateral side of her right leg.

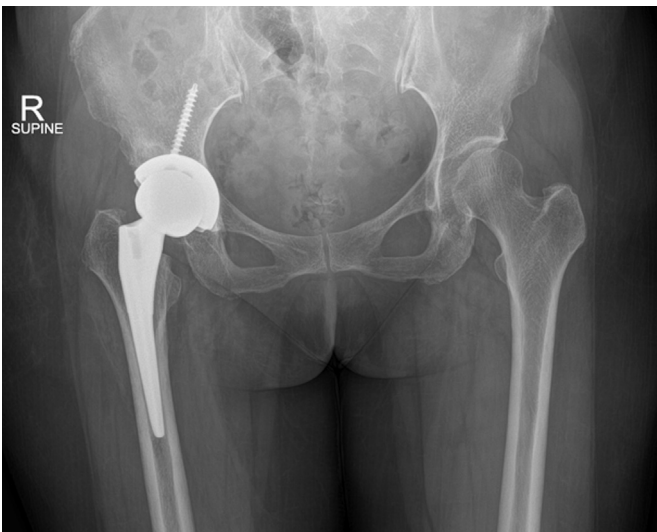

Figure 2. Postoperative radiograph of the patient, both hip AP.

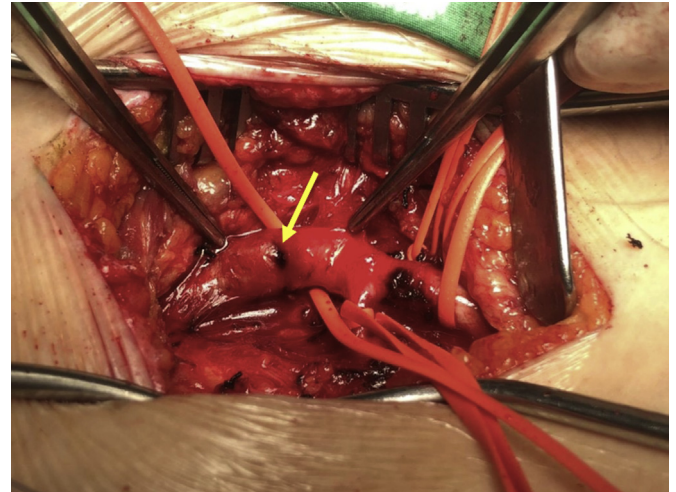

Figure 3. Intraoperative photograph shows the site of tunica adventitia tear of anterior wall of right common femoral artery (arrow).

Discussion

Vascular injury in THA is very rare complication. A systematic review by Alshameeri et al. revealed rates of incidence of vascular injury of 0.04% in primary THA and of 0.19% in revision surgery [1]. Several risk factors have been proposed, and those factors are divided into 2 categories. The first category includes patient factors, such as previous blood vessel abnormality (eg, atherosclerotic artery, artery bypass, atypical size, and altered location), hip anatomy distortion (eg, hip dysplasia and osteoarthritis), muscular atrophy, and skin scarring. The second category includes surgical factors, such as number of operations, surgical approach, Hohmann retractor use, and acetabular screw placement [3–5].

Vascular injury can cause hemorrhagic or ischemic symptoms. Our patient presented with ischemic symptoms, including paresthesia and paralysis of lower extremity. In the early postoperative period, these symptoms can mimic postregional anesthesia or intraoperative sciatic nerve injury. Calligaro et al. [6] reported that 56% of arterial injury was detected on the day of surgery and that 44% of arterial injury was not recognized until the first to fifth postoperative day after joint replacement. Thus, early diagnosis is the most essential factor for preventing catastrophic complication that could lead to compartment syndrome or requirement for limb amputation. Lazarides et al. [2] reported the consequences of



Figure 4. Intraoperative photograph shows removed thrombus that extended from common femoral artery down to anterior and posterior tibial arteries.

severe vascular injury to be death (4%), amputation (7%), and long-term disability (11%).

Preoperative assessment by history taking and physical examination plays an important role in assessing patient risk. Patients with previous coronary artery bypass, carotid endarterectomy, abdominal aortic aneurysm, and/or the symptoms intermittent claudication or ischemic rest pain should be considered to be at higher risk. Physical examination should include inspection of the skin of the lower extremities (skin discoloration, absence of hair, and dystrophic nail), and the peripheral pulses of the leg to be treated should be palpated and compared with those of the contralateral leg. If suspicion of arterial insufficiency is detected, the ankle-brachial index should be determined by Doppler ultrasound. An ankle-brachial index of less than 0.9 should be assessed preoperatively by a vascular surgeon [7].

Nachbur et al. [3] reported the following as being potential causes of common femoral artery injury: 1) bending back of the blood vessels by the use of a sharp-edged retractor; 2) direct damage by osteotome or knife blade; 3) damage by osteophyte during joint manipulation; 4) thermal damage due to bone cement; 5) over-reaming of acetabulum; 6) injury by drill or screw insertion; and 7) intimal tear in an atherosclerotic vessel during limb manipulation. From the intraoperative findings of the vascular repair procedure in our case, we think that the injury to the common femoral artery was caused by the retractor pushing the vessel anteriorly. Specifically, we observed an intimal tear of the posterior wall and a tunica adventitia tear of the anterior wall. The anterior Hohmann retractor is the suspected possible cause. Although an anterior approach was reported to be associated with a higher risk of vascular injury than a posterior approach, the location of the anterior Hohmann retractor is similar, and blood vessels and nerves are located near the anterior column of the acetabulum [8,9].

Concerning the correlation between the course of femoral blood vessels and the extent of acetabular dysplasia, Maeda et al. [10] reported the mean shortest distances between vessels and the anterior pelvic wall in Crowe classification type I-IV to be 7.7, 6.7, 5.4, and 4.2 mm, respectively (The mean shortest distance in a normal hip was 7.5 mm.). Riouallon et al. [5] proposed that defect of the anterior acetabular wall can make acetabular exposure more difficult and that absence of soft tissue between the femoral artery and the anterior acetabular wall can increase the likelihood of vessel injury caused by the anterior Hohmann retractor. At our center, we do not routinely evaluate the hip using preoperative computed tomography or magnetic resonance imaging. The present case was considered to be very low risk because of a diagnosis of Crowe type I without an anterior wall defect. Thus, placement of the retractor on the anterior column bone without any soft-tissue interposition is the important surgical step for preventing this type of vascular injury.

There are several treatment options for managing ischemic thromboembolism, including arterial thromboembolism, interventional thrombolysis, stenting, or revascularization using a graft [11]. The treatment decision in this setting is made by the attending vascular surgeon(s). Regarding blood vessel-related complications, the role of the orthopedic surgeon can be categorized into 3 periods. In the preoperative period, identification of the patient's level of risk is essentially important. If the patient is determined to be at risk, consultation with a vascular surgeon is needed, and further vascular investigation should be considered [12]. In the intraoperative period, appropriate approach, adequate surgical exposure, and Hohmann retractor placement should be carefully considered. In the postoperative period, routine monitoring of the dorsalis pedis pulse is the simplest method for early

detection of limb ischemia. If the dorsalis pedis pulse is not detected, urgent consultation with a vascular surgeon is essential.

Summary

We report a patient with mild hip dysplasia who was diagnosed with delayed-onset intimal injury-induced common femoral artery occlusion after THA performed via the posterior approach, and placement of the anterior Hohmann retractor is proposed as a possible cause. The diagnosis is obtained via close postoperative monitoring of the dorsalis pedis pulse. Our case was successfully treated with arterial thromboembolism. Early detection and prompt vascular surgeon consultation are the essential factors for preventing the potentially catastrophic consequences of this complication.

Conflicts of interest

The authors declare that they have no known competing financial interests or personal relationships that could have appeared to influence the work reported in this article.

Acknowledgment

The authors gratefully acknowledge the patient profiled in this report for granting us permission to report details relating to her case.

Informed patient consent

The author(s) confirm that informed consent has been obtained from the involved patient(s) or if appropriate from the parent, guardian, power of attorney of the involved patient(s); and, they have given approval for this information to be published in this case report (series).

References

- [1] Alshameeri Z, Bajekal R, Varty K, Khanduja V. Iatrogenic vascular injuries during arthroplasty of the hip. *Bone Joint J* 2015;97-B(11):1447.
- [2] Lazarides MK, Arvanitis DP, Dayantas JN. Iatrogenic arterial trauma associated with hip joint surgery: an overview. *Eur J Vasc Surg* 1991;5(5):549.
- [3] Nachbur B, Meyer RP, Verkkala K, Zürcher R. The mechanisms of severe arterial injury in surgery of the hip joint. *Clin Orthop* 1979;(141):122.
- [4] Reiley MA, Bond D, Branick RI, Wilson EH. Vascular complications following total hip arthroplasty. A review of the literature and a report of two cases. *Clin Orthop* 1984;(186):23.
- [5] Riouallon G, Zilber S, Allain J. Common femoral artery intimal injury following total hip replacement. A case report and literature review. *Orthop Traumatol Surg Res* 2009;95(2):154.
- [6] Calligaro KD, Dougherty MJ, Ryan S, Booth RE. Acute arterial complications associated with total hip and knee arthroplasty. *J Vasc Surg* 2003;38(6):1170.
- [7] Smith DE, McGraw RW, Taylor DC, Masri BA. Arterial complications and total knee arthroplasty. *J Am Acad Orthop Surg* 2001;9(4):253.
- [8] Proschek D, Proschek P, Hochmuth K, Balzer JO, Mack MG, Vogl TJ. False aneurysm of the left femoral artery and thrombosis of the left femoral vein after total hip arthroplasty. *Arch Orthop Trauma Surg* 2006;126(7):493.
- [9] Kawasaki Y, Egawa H, Hamada H, Takao S, Nakano S, Yasui N. Location of intrapelvic vessels around the acetabulum assessed by three-dimensional computed tomographic angiography: prevention of vascular-related complications in total hip arthroplasty. *J Orthop Sci* 2012;17(4):397.
- [10] Maeda Y, Nakamura N, Takao M, Hamada H, Sugano N. Risk of injury to the femoral blood vessels based on the extent of acetabular dysplasia in total hip arthroplasty. *J Artif Organs* 2019;22(4):324–9.
- [11] al-Salman M, Taylor DC, Beauchamp CP, Duncan CP. Prevention of vascular injuries in revision total hip replacement. *Can J Surg J Can Chir* 1992;35(3):261.
- [12] Fukunishi S, Okahisa S, Fukui T, et al. Significance of preoperative 3D-CT angiography for localization of the femoral artery in complicated THA. *J Orthop Sci* 2014;19(3):457.