IMAGING DIAGNOSIS—MAGNETIC RESONANCE IMAGING FINDINGS IN A CAT WITH SYSTEMIC REACTIVE ANGIOENDOTHELIOMATOSIS

AMY E. SCHKEEPER, JILL NARAK, RICHARD WEISS

A 10-year-old, castrated male domestic short-haired cat was presented with an acute history of seizures, lethargy, anorexia, vomiting, and dyspnea. Magnetic resonance imaging of the brain showed multifocal areas of gray matter T2-weighted hyperintensity. The lesions did not enhance with intravenous contrast. The cat was diagnosed at necropsy with feline systemic reactive angioendotheliomatosis, a rare vascular proliferative disorder for which a treatment has not yet been identified. This report is the first to describe associated magnetic resonance imaging changes for this disease.

Key words: angioendotheliomatosis, feline, MRI, reactive, systemic.

Signalment, History, and Clinical Findings

A 10-YEAR-OLD, CASTRATED MALE domestic short-haired cat was presented with a 1-day history of lethargy, anorexia, vomiting, dyspnea, and seizures. Physical examination revealed hypothermia, mild bradycardia, labored breathing, pale mucous membranes, and petechial hemorrhages on the pinnae. There were numerous neurologic abnormalities, as well. Neurologic examination revealed nonambulatory tetraparesis with a stuporous mentation, responsive only to noxious stimuli. Spinal reflexes were normal, and cranial nerve exam revealed a negative menace response in both eyes, reduced oculocephalic reflexes in both eyes, and a reduced response to facial and nasal sensation on the right side. Postural reactions were not attempted, and pain was not elicited on palpation of the head or spine. Neuroanatomic localization was multifocal or diffuse intracranial disease, and differential diagnoses included infectious meningoencephalidities, metabolic encephalopathies, and, less likely, a vascular encephalopathy.

A complete blood count revealed a normocytic, normochromic, nonregenerative anemia (18.7%; reference interval 30–45%), thrombocytopenia ($55 \times 10^3/\mu l$; reference interval $200–700 \times 10^3/\mu l$), lymphopenia ($1.3 \times 10^3/\mu l$; reference interval $1.5–1.7 \times 10^3/\mu l$), and neutrophilia ($17 \times 10^3/\mu l$; reference interval $2.5–12.5 \times 10^3/\mu l$) with a left shift ($0.5 \times 10^3$ band neutrophils/μl; reference interval $0–0.3 \times 10^3/\mu l$). Microscopic examination of the blood smear indicated possible infection with a *Mycoplasma* spp, as small round structures suggestive of the organism were seen at the edges of some erythrocytes. A chemistry panel revealed increased creatine kinase (12,369 U/l; reference interval 100–250 U/l), alanine aminotransferase (262 U/l; reference interval 26–77 U/l), and aspartate aminotransferase (217 U/l; reference interval 12–45 U/l) activity, as well as hyperbilirubinemia (0.86 mg/dl; reference interval 0.1–0.2 mg/dl) and hyperphosphatemia (8 mg/dl; reference interval 4.3–5.9 mg/dl). A coagulation panel was normal, other than the previously noted thrombocytopenia.

Imaging, Diagnosis, and Outcome

Orthogonal thoracic radiographs were within normal limits (Summit Innovet Model E7239X, Chicago, IL; GAD OX Canon DDR; kVp 78, mA 300, 1 ms). Abdominal ultrasound findings were within normal limits, other than a mildly thickened jejunal wall (ranging from 2.4 mm to 3.7 mm) with a prominent muscularis layer (ranging from equal to, to nearly double the thickness of the mucosal layer) (Philips ie33, Bothell, WA, microconvex probe 5–8 mHz). Differential diagnoses considered for the appearance of the small bowel included inflammatory bowel disease or less likely small cell lymphoma. As there was no history of gastrointestinal signs, clinical significance of this finding was questionable.

The patient was routinely anesthetized and magnetic resonance (MR) imaging of the brain was performed with a 1.5T scanner and using a human knee coil (Infinion; Philips Medical Systems, Andover, MA). Transverse images were obtained with T2-weighted (T2W) (TR 4000,

From the Department of Clinical Sciences (Schkeeper, Narak) and the Department of Pathobiology (Weiss), Auburn University College of Veterinary Medicine, Auburn, AL 36849.

The authors declare that there were no external sources of funding or support for this clinical report.

Address correspondence and reprint request to Dr. Jill Narak, at the above address. E-mail: narakjc@auburn.edu

Received October 13, 2015; accepted for publication January 22, 2016.
doi: 10.1111/vru.12374

Vet Radiol Ultrasound, Vol. 58, No. 2, 2017, pp E16–E21.

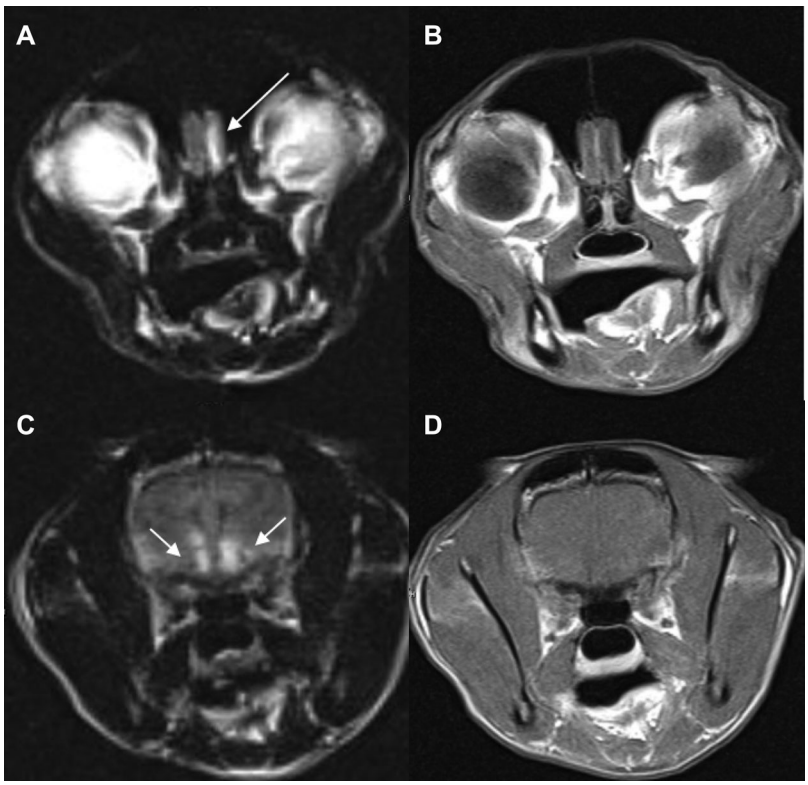

FIG. 1. Transverse images at the level of the olfactory bulbs (A and B) and at the level of the frontal lobes (C and D) including T2-weighted images (A and C, TR = 4000 ms, TE = 142.8 ms, slice thickness 5.0 mm) and T1 postcontrast images (B and D, TR = 600 ms, TE = 11.5 ms, slice thickness 5.0 mm). T2 hyperintensity is seen in the left olfactory bulb (long arrow), though this region is hypointense on T1-weighted images. T2 hyperintensity is seen in the region of the caudate nuclei bilaterally (short arrows), which is hypointense on post contrast T1-weighted images.

TE 142.8, 5.0 mm), proton density (TR 4000, TE 20.4, 5.0 mm), fluid attenuating inversion recovery (FLAIR) (TR 6000, TE 110.4, 5.0 mm), gradient-echo (GE) (TR 1188, TE 23.5, 5.0 mm), and T1-weighted (T1W) (TR 600, TE 11.5, 5.0 mm) sequences preintravenous contrast. T2-weighted sagittal images were also obtained (TR 4000, TE 119.0, 3.0 mm). Postintravenous contrast T1W images were obtained in all three standard planes approximately 5 min postmanual intravenous injection of gadolinium-based contrast (transverse, sagittal, and dorsal: TR 600, TE 11.5, 5.0 mm) (0.12 mmol/kg bodyweight, gadoteridol [ProHance; Bracco Diagnostic, Inc., Township, NJ]). Field of view for all images was 20 cm × 20 cm, except for the T1W postcontrast dorsal sequence that had a field of view of 21 cm × 21 cm. Multifocal ill-defined, small regions of hyperintensity were identified on T2W images, primarily in the gray matter at the following locations: both piriform lobes, the caudate nucleus bilaterally, the region of the caudal aspect of the right hippocampus, the ventromedial aspect of the frontal lobe bilaterally, and ventral to the rostral aspect of the lateral ventricles bilaterally **(**Figs. 1C, 2A**, C)**. These regions were hyperintense on FLAIR and iso- to slightly hypointense on T1W images (Figs. 1D, 2B, D). No abnormal regions of intravenous contrast enhancement were identified. Hyperintensity was noted in the region of the left olfactory bulb on T2W images; this was hyperintense on FLAIR images. This region was hypointense on T1W images pre- and postintravenous contrast (Figs. 1A, B, 3A, B). No regions of signal void were identified on GE images. No abnormalities were identified in the portion of the cervical spine included on the sagittal images. Differentials considered for these findings included a noninfectious or infectious encephalitis, a component of postictal changes, or less likely, neoplasia.

Cisternal cerebrospinal fluid analysis revealed increased protein concentration (60.8 mg/dl; reference interval < 25 mg/dl) and a moderate neutrophilic pleocytosis (14 white blood cells/μl; reference interval < 5/ μl, 75% neutrophils, 20% macrophages, and 5% small lymphocytes). No microorganisms were seen on cytologic examination. Whole blood polymerase chain reaction (PCR) testing for *Mycoplasma turicensis*, *Mycoplasma hemofelis*, *Cytauxazoon felis*, *Anaplasma phagocytophilum*, *Bartonella henselae*, *Bartonella clarridgeiae*, *Bartonella quintana*, *Rickettsia rickettsia*, *Rickettsia felis*, and *Ehrlichia* spp. was negative. There was a positive PCR result for *Mycoplasma heamominutum*. Serology for feline leukemia virus and feline immunodeficiency virus was negative. Serology

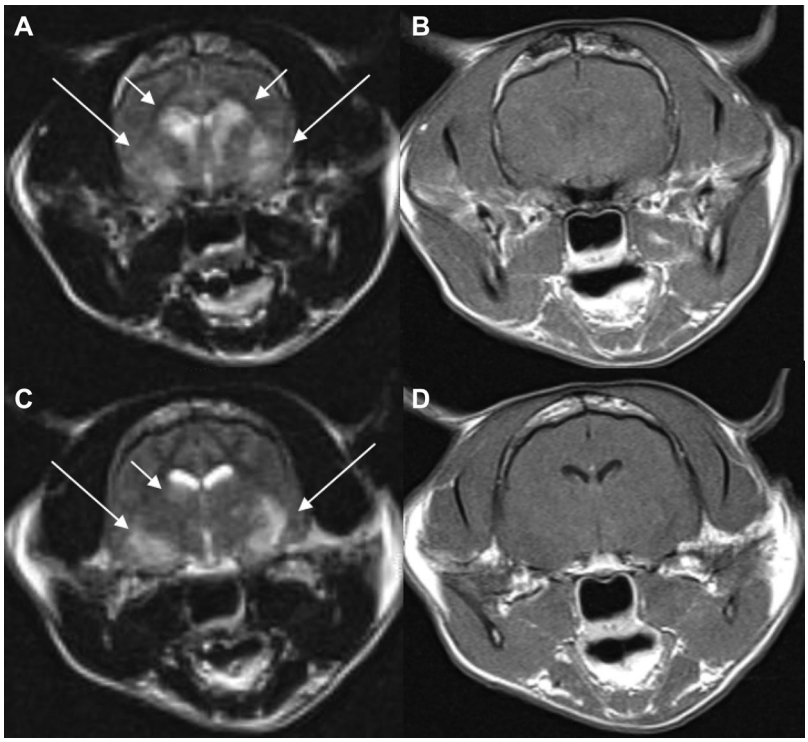

FIG. 2. Transverse images at the level of the caudal aspect of the frontal lobe (A and B) and at the level of the rostral aspect of the thalamus (C and D) including T2-weighted images (A and C, TR = 4000 ms, TE = 142.8 ms, slice thickness 5.0 mm) and T1 postcontrast images (B and D, TR = 600 ms, TE = 11.5 ms, slice thickness 5.0 mm). T2 hyperintensity is seen in the region of the caudate nuclei bilaterally (short arrows) and in the region of the piriform lobes bilaterally (long arrows). These regions are iso to slightly hypointense on postcontrast T1-weighted images.

for feline coronavirus was mildly positive, indicating exposure.

Supportive care was continued, but the cat made little improvements over the 6-day hospitalization period. The owner elected for humane euthanasia due to the grave prognosis.

On gross postmortem examination, the cat had pale, yellow-tinged mucous membranes and subcutaneous and visceral fat. There was a moderate amount of hemorrhagic semiformed feces in the colon and rectum. The ventral surface of the left anterior prosencephalon near the olfactory lobes contained several irregular 0.2–0.5 cm in diameter necrotic dark tan foci. Other significant systemic lesions included multifocal petechial hemorrhages in the small intestines and heart; mild cardiomegaly with right ventricular hypertrophy and left atrial dilatation; pulmonary edema and congestion; and, passive congestion with an increased lobular ("nutmeg") pattern in the liver.

Microscopically, numerous variably sized blood vessels within both gray and white matter, leptomeninges, and Virchow–Robin space throughout the cerebrum, thalamus, cerebellum, and brainstem contained variably sized, often glomeruloid, intraluminal proliferations of bland spindle to slightly polygonal cells variably separated by slit-like spaces containing erythrocytes that partially or almost completely filled the vascular lumen. In several areas, the occluded vessels surrounded or lay adjacent to variably sized circumscribed foci of malacia (infarct), hemorrhage, and white matter degeneration (Fig. 4A). Many vessels also contained fibrin thrombi (Fig. 4B). Proliferating intraluminal cells had plump, irregularly round to oval vesicular nuclei with coarsely clumped or stippled and marginated chromatin and inconspicuous nucleoli and had modest amounts of poorly defined eosinophilic cytoplasm. Nuclear and cellular atypia and mitotic figures were not observed. Immunohistochemically, the cells stained strongly positive multifocally for Factor VIII and/or muscle specific actin (MSA) suggesting an endothelial cell or pericyte histogenesis, respectively (Fig. 4C, D).[1] Vascular lesions similar to those described in the brain were also observed in the heart (severe), spinal cord, spleen, adrenal, pancreas, extraocular muscles, stomach, small intestine, colon, bone marrow, kidney (rarely), and liver (rarely). Additionally, there was moderate erythroid hyperplasia of bone marrow. Sections of brain, heart, and spleen were negative for Bartonella spp by PCR test (Galaxy Diagnostics, Morrisville, NC). The final histopathological diagnosis was vasculopathy, intraluminal and proliferative, multifocal and disseminated, subacute, moderate to marked, with vascular thrombosis and multiple brain infarcts consistent

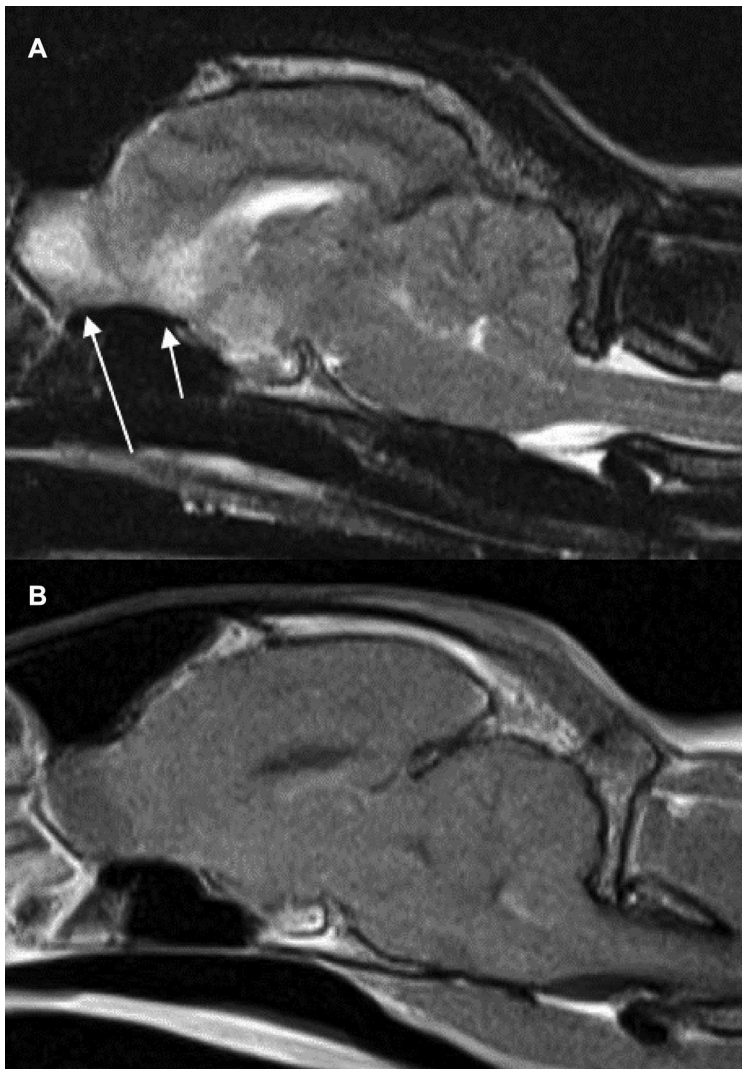

FIG. 3. Sagittal images through the left olfactory bulb including T2-weighted images (A, TR = 4000 ms, TE = 119.0 ms, slice thickness 3.0 mm) and T1 postcontrast images (B, TR = 600 ms, TE = 11.5 ms, slice thickness 5.0 mm). T2 hyperintensity is seen in the region of the left olfactory lobe (long arrow), which is hypointense on postcontrast T1 images. T2 hyperintensity in the region of the caudate nucleus (short arrow) is isointense on postcontrast T1 images.

with feline systemic reactive angioendotheliomatosis (FSRA).

Discussion

Feline systemic reactive angioendotheliomatosis is a rare intravascular proliferative disorder that is multisystemic, fatal, and presumed idiopathic.[1] To the authors' knowledge, only 13 cases of feline intravascular proliferative disorders have been described in the literature.[1,3–6] Feline systemic reactive angioendotheliomatosis can be classified as a variant of reactive angioendotheliomatosis (RAE) or intravascular angiotropic lymphoma, the latter of which has been reported in only one cat, affecting the vessels of the brain and kidney.[6] Reactive angioendotheliomatosis primarily affects juvenile to young adult domestic male cats.[1] It is characterized by intraluminal endothelial and pericyte proliferation, with the heart being the most commonly and severely affected organ.[1] Feline systemic reactive angioendotheliomatosis differs from intravascular lymphoma primarily in that it is endothelial in origin, though is also differentiated cytologically being characterized by obliteration of the lumen of small vessels with glomeruloid whorls of bland spindle cells and microthrombi.[1] Numerous other organs can be affected, including kidneys, spleen, lymph nodes, gastrointestinal tract, brain/meninges, eyes, and pancreas, and less commonly, liver, adrenal glands, thyroid gland, sciatic nerve, subcutis, lung, bone marrow, and urinary bladder.[1] Typically, small arterioles comprise the majority of affected vessels and thrombi within proliferative spindle cell tufts are a common finding.[1] In people, RAE is a rare but self-limiting cutaneous disorder. Although FSRA

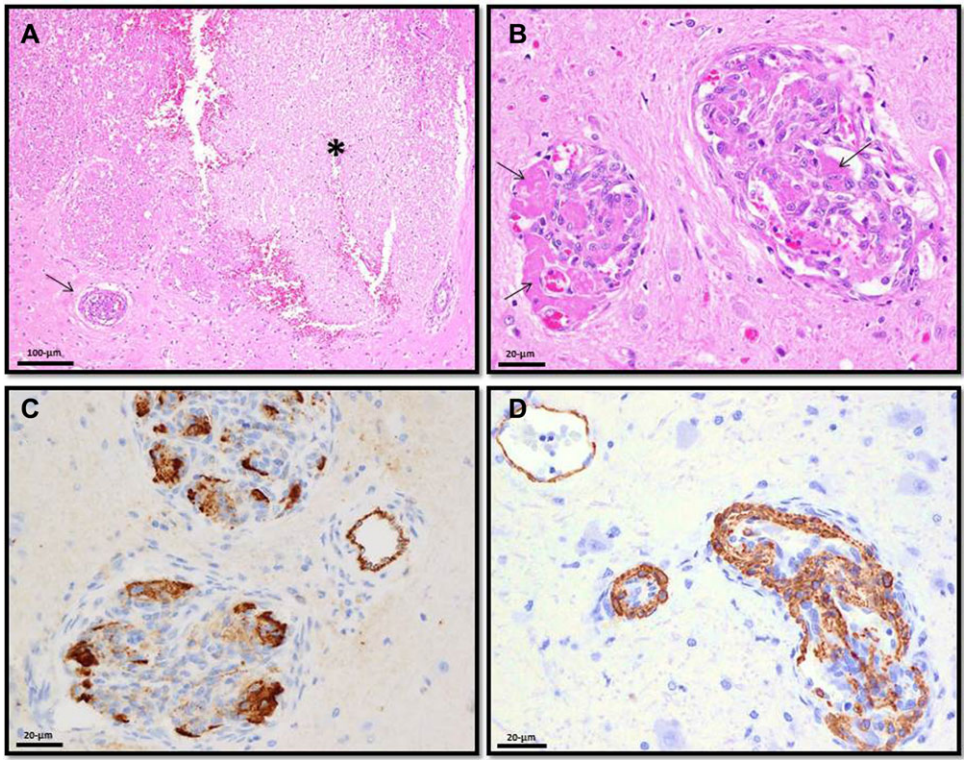

FIG. 4. (A) Hematoxylin and eosin stain (H&E). Section of brain at junction of gray and white matter near the corona radiata. There is a large, locally extensive circumscribed area of malacia and hemorrhage (asterisk) flanked by a prominent blood vessel containing occlusive glomeruloid intravascular accumulations (arrow) (Bar 100 μM). (B) H&E stain. Section of brain containing two blood vessels expanded by intravascular glomeruloid proliferations of spindle cells interspersed with fibrin thrombi (arrows) (Bar 20 μM). (C) Immunohistochemical staining for Factor VIII on section of brain. Positive multifocal Factor VIII staining of a population of intraluminal spindle cells is consistent with an endothelial cell histogenesis. Note concomitant positive Factor VIII immunostaining of endothelial cells lining a normal blood vessel on right. (Bar 20 μM). (D) Immunohistochemical staining MSA (muscle-specific actin) on section of brain. Positive MSA staining of a large population of intraluminal and bridging spindle cells is consistent with a pericyte or smooth myocyte cell origin. Note concomitant positive MSA staining of smooth muscle cells in the walls of two normal blood vessels on left. (Bar 20 μM).

is multisystemic, the lesions are most similar to RAE in people.[1,2]

The clinical signs of FSRA are variable, but commonly include an acute onset of dyspnea, lethargy, and spontaneous death,[1] similar to the patient described in this report. There is an apparent predilection for male cats.[1] As death appears imminent, treatment at this time is unknown.

Magnetic resonance imaging findings of FSRA have not yet been reported. A report of intravascular lymphoma in the brain of a 10-year old Rottweiler–German Shepard cross demonstrated multifocal hyperintensities on T2-weighted images, FLAIR, and precontrast T1-weighted images, being most apparent on FLAIR images.[8] These hyperintensities were located in the thalamus, occipital lobe, cerebellum, and mesencephalic tegmentum. Administration of intravenous contrast yielded mild enhancement of these lesions as well as identification of an additional lesion in the claustrum.[8] Noncontrast enhanced MR images of the 7-year-old Siamese with intravascular lymphoma revealed asymmetry in the cerebral cortices with hyperintensities in the right cerebral cortex on T2 and proton density images, as well as thickened/poorly defined gyri in that location.[6] These intravascular lymphoma patients differ from the patient in this report in that this patient did not have enhancing lesions, did not have cerebral asymmetry, and was ultimately not diagnosed with lymphoma.

The patient in this report had mutifocal regions of T2 hyperintensities in the piriform lobes, caudate nuclei, hippocampus, and frontal lobes with no regions of enhancement. The cause of the T2 hyperintensities may be related to infarction from small vessel occlusion with fibrin thrombosis found on necropsy, and though numerous additional lesions were present on necropsy they were not appreciated on MR images. The cause for the mild dilation of the left rostral horn of the lateral ventricle is unknown, though it may be a normal variant. Thoracic radiographs and abdominal sonographic findings were relatively unremarkable aside from the slightly thickened small bowel with a prominent muscularis layer. Though this can be seen with chronic enteritis, inflammatory bowel disease, or lymphoma among others, in this case, it may have been due to the vasculopathy from FSRA.[7] The cytologic and PCR evidence of a Mycoplasma infection in this patient is thought to be an incidental, unrelated finding.

Feline reactive systemic angioendotheliomatosis is a rare multisystemic intravascular proliferative disorder of cats that typically present with acute onset of dyspnea and lethargy. In a patient with a severe multifocal neuroanatomic localization, systemic signs of illness, and multifocal, nonenhancing T2 hyperintensities on brain MRI, FSRA should be considered a differential diagnosis.

LIST OF AUTHOR CONTRIBUTIONS

Category 1

(a) Conception and Design: Jill Narak, Amy Schkeeper
(b) Acquisition of Data: Amy Schkeeper, Richard Weiss
(c) Analysis and Interpretation of Data: Jill Narak, Amy Schkeeper, Richard Weiss

Category 2

(a) Drafting the Article: Jill Narak, Amy Schkeeper, Richard Weiss
(b) Revising Article for Intellectual Content: Jill Narak, Amy Schkeeper, Richard Weiss

Category 3

(a) Final Approval of the Completed Article: Jill Narak, Amy Schkeeper, Richard Weiss

ACKNOWLEDGMENT

The authors thank Dr. Jey Koehler for sharing her knowledge of feline systemic reactive angioendotheliomatosis.

REFERENCES

1. Fuji RN, Patton KM, Steinbach TJ, et al. Feline systemic reactive angioendotheliomatosis: eight cases and literature review. Vet Pathol 2005;42:608–617.
2. Requena L, Sangueza OP. J Am Acad Dermatol 1998;38:143–175.
3. Dunn KA, Smith KC, Blunden AS. Fatal multisystemic intravascular lesions in a cat. Vet Rec 1997;140:128–129.
4. Rothwell TL, Xu FN, Wills EJ, et al. Unusual multisystemic vascular lesions in a cat. Vet Pathol 1985;22:510–512.
5. Straumann Kunz U, Ossent P, Lott-Stolz G. Generalized intravascular proliferation in two cats: endotheliosis or intravascular pseudoangiosarcoma? J Comp Pathol 1993;109:99–102.
6. Lapointe JM, Higgins RJ, Kortz GD, et al: Intravascular malignant T-cell lymphoma (malignant angioendotheliomatosis) in a cat. Vet Pathol 1997;34: 247–250.
7. Nyland TG, Neelis DA, Mattoon JS. Gastrointestinal tract. In: Mattoon JS, Nyland TG (eds): Small animal diagnostic ultrasound, 3rd ed. St. Louis: Elsevier Saunders, 2015; 2468–2500.
8. Kent M, DeLahunta A, Tidwell AS. MR imaging findings in a dog with intravascular lymphoma in the brain. Vet Rad 2001;42: 504–510.