

# Retroperitoneal hematoma after implantation of double inferior vena cava filters

Yulong Tian<sup>1,2</sup>, Hongshan Zhong<sup>1,2,\*</sup>, Wei Zhang<sup>3</sup>

## Abstract

A 55-year-old man developed deep venous thrombosis and inferior vena cava (IVC) thrombosis 7 years earlier and was treated by placement of a permanent IVC filter. One week ago, he was admitted with bilateral lower limb swelling and pain. Digital subtraction angiography showed a filling defect above the original filter. A retrievable Tulip filter was placed and catheter-directed thrombolysis was performed. Six days later, the patient experienced sudden, persistent upper right abdominal pain, and a computed tomography scan revealed the formation of retroperitoneal hematoma. Symptomatic treatments were administered, and the hematoma gradually resolved during follow-up.

<sup>1</sup>Department of Interventional Radiology, The First Affiliated Hospital of China Medical University, Shenyang, China.

<sup>2</sup>Laboratory of Medical Imaging and Interventional Radiology, The First Affiliated Hospital of China Medical University, Shenyang, China.

<sup>3</sup>Department of Intervention and Department of Shenzhen Medical Intervention Engineering Center, The Second Clinical Medical College, Jinan University, Shenzhen, China.

\* **Correspondence:** Hongshan Zhong, Department of Interventional Radiology, The First Affiliated Hospital of China Medical University, 155 Nanjing North Street, Shenyang 110001, Liaoning, China, Email: hszhong@cmu.edu.cn

**Conflict of interest:** The authors declare that they have no conflict of interest.

**Funding:** This research did not receive a specific grant from any funding agency in the public, commercial, or not-for-profit sectors.

**Ethical approval:** This case report was approved by our Institutional Review Board of the First Affiliated Hospital of China Medical University.

**Informed consent:** Not applicable.

*Journal of Interventional Medicine* 2018, Vol. 1, No. 4, pp. 252–256

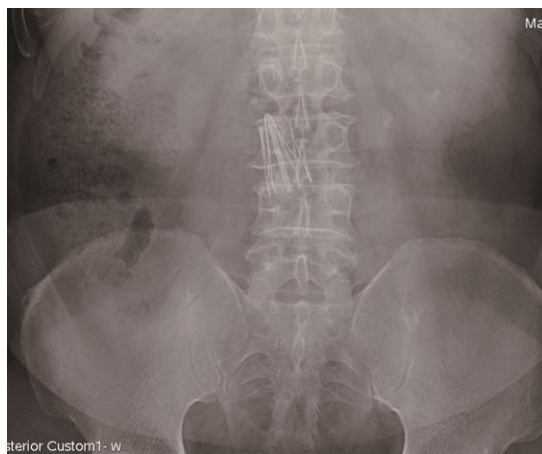## INTRODUCTION

Retroperitoneal hematoma resulting from penetration of an inferior vena cava (IVC) filter is rare but fatal, especially in patients with double filters in the IVC. We describe a case of successful endovascular treatment of thrombosis in the IVC and follow-up of the subsequent retroperitoneal hematoma.

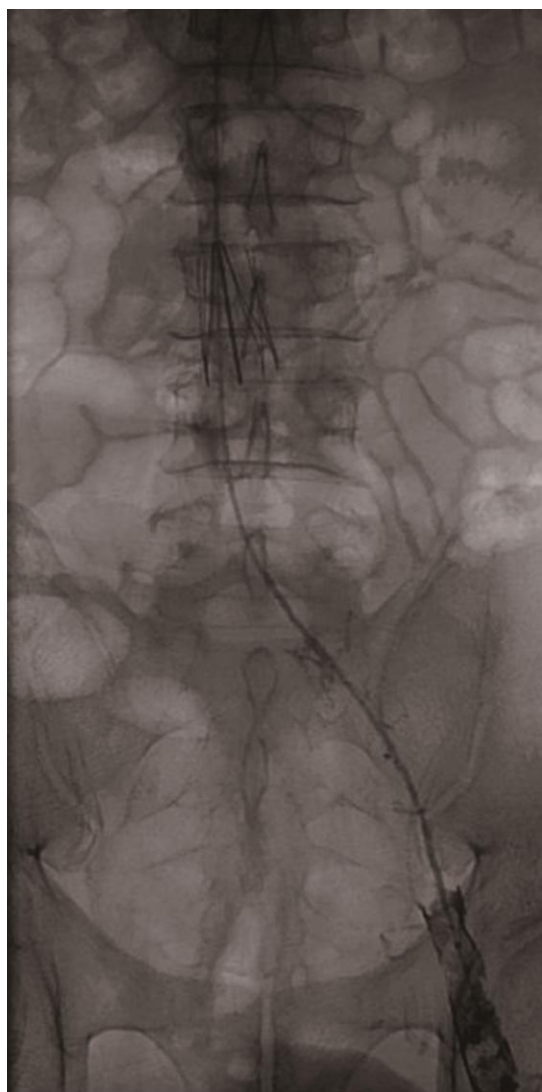
## CASE REPORT

This case report was approved by our Institutional Review Board. A 55-year-old man with right lower extremity deep vein thrombosis (DVT) and inferior vena cava (IVC) thrombosis underwent IVC filter implantation and anticoagulant therapy in February 2003 at another hospital. The Vena Tech LP filter (B. Braun Medical S.A., Boulogne, France) can be seen in the IVC (Figure 1). The patient did not receive regular anticoagulant therapy after the filter implantation. Seven years later (April 2010), the patient was admitted to our hospital with complaints of bilateral lower limb swelling and pain of 1 week's duration. Color Doppler ultrasound imaging indicated DVT in the left lower extremity and thrombosis in the IVC.

Venography showed left lower extremity DVT and a thrombus that had formed in the IVC filter (Figure 2). The original filter had lost the ability to prevent a



**Figure 1.** Abdominal X-ray showing permanent inferior vena cava filter.



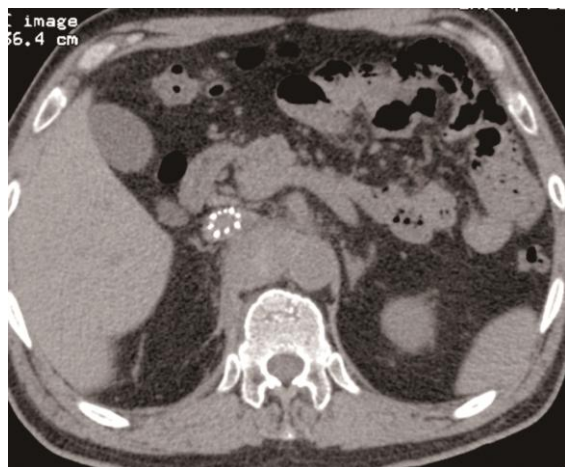**Figure 2.** Venography showing left lower extremity DVT and thrombosis in the IVC.

pulmonary embolism (PE). To reduce the risk of thrombosis and pulmonary embolism and relieve clinical symptoms, a retrievable Günther Tulip filter (William Cook Europe, Bjaeverskov, Denmark) was placed intraoperatively in the appropriate suprarenal position and catheter-directed thrombolysis (CDT) and anticoagulant therapy was performed. Urokinase (500,000 U) was infused via a thrombolysis catheter (Angiodynamics, Uni Fuse, USA) over the course of 2 to 3 h, twice daily. Low-molecular-weight heparin calcium (0.4 mL) was injected subcutaneously twice daily.

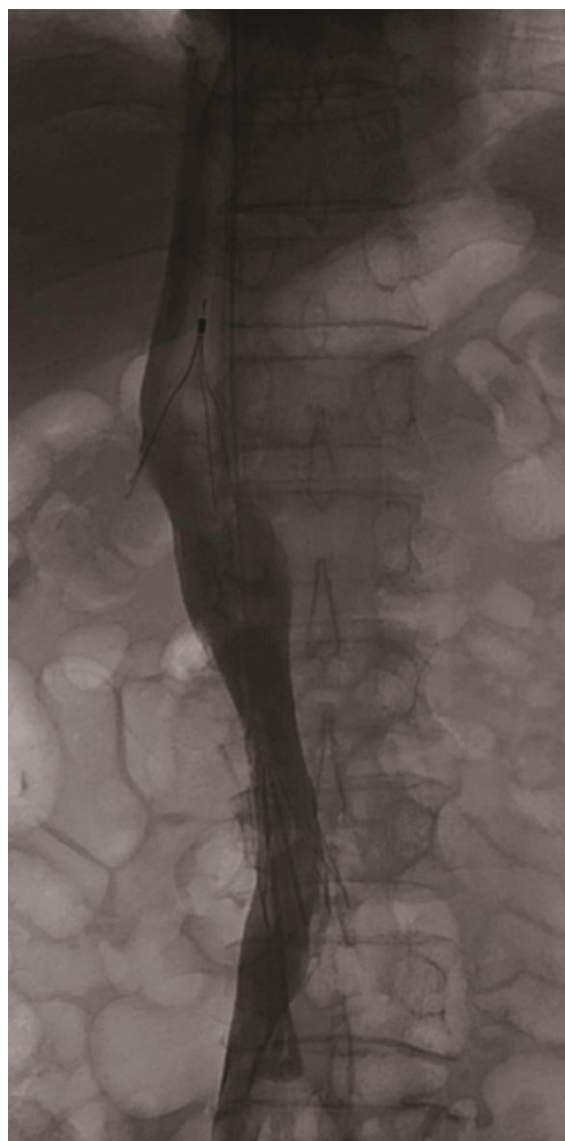
Two days later, vena cava angiography showed that the thrombus in the IVC had partially dissolved. Lower limb swelling was alleviated. Laboratory data showed hemoglobin (HB) 135 g/L. However, due to the remaining thrombosis of the filter, the returned blood of IVC was limited, and further low-dose CDT treatment was required to be given. Six days after filter placement, the patient experienced sudden, persistent pain in the upper right abdomen, accompanied by pale skin and mucosa. The systolic blood pressure decreased to 90 mmHg. Laboratory data revealed HB 91 g/L, platelets  $90 \times 10^9/L$ , international normal ratio (INR) 1.2; abdominal computed tomography (CT) showed a large retroperitoneal hematoma along the lateral side of the IVC filter struts (Figure 3). The retroperitoneal hematoma may have been caused by the IVC as a result of the IVC wall injury by the filter. Removal of the IVC filter was planned to control the retroperitoneal hematoma. Vena cava angiography indicated that the residual intrafilter thrombus had completely dissolved (Figure 4). Lower limb swelling had totally resolved. However, attempted Günther Tulip filter retrieval through the right jugular approach were unsuccessful due to filter tilt. For this reason, thrombolysis was terminated, and symptomatic treatment, blood transfusion, and fluid infusion were administered.

Two days later, the patient's symptoms and hematologic profile had improved (HB 129 g/L, INR 1.2). Thereafter, the clinical course was favorable. Heparin was continued after discharge. Abdominal CT scans at 2, 3, and 6 months showed no evidence of recurrent thrombus, and there was a progressive decrease in size and absorption of the hematoma (Figures 5–8).

## DISCUSSION



**Figure 3.** Retroperitoneal hematoma along with the struts of filter.



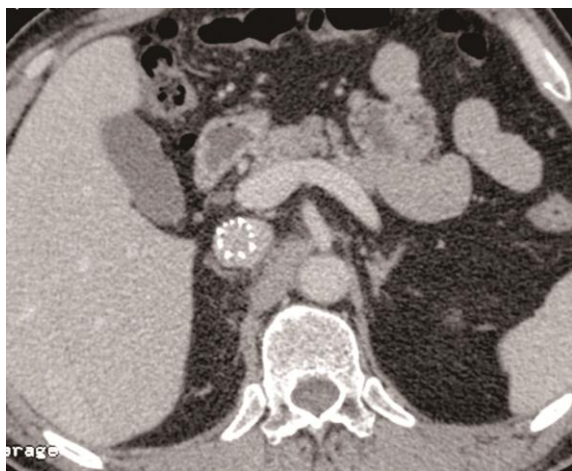**Figure 4.** Unobstructed vena cava.

To our knowledge, this is the first case of double IVC filters being placed in one patient with long-term follow-up results. Placement of an IVC filter is an increasingly common request in patients with proximal lower extremity DVT (1). A number of permanent and retrievable filters are currently available (2). These filters are designed to prevent pulmonary embolism and reduce complications (2). However, there are no therapeutic modalities that can completely prevent all complications.

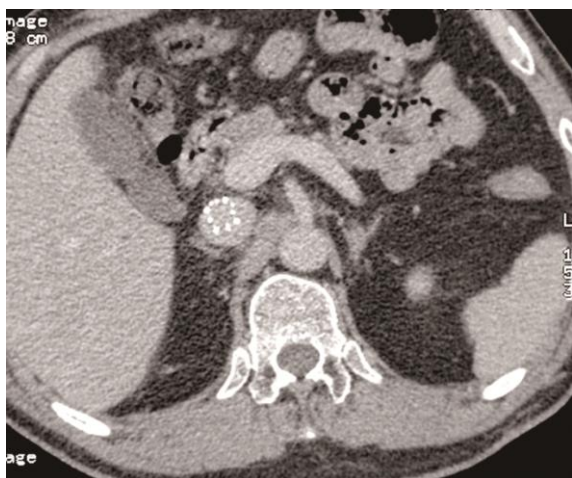Retroperitoneal hematoma should be recognized as a rare but fatal complication after IVC filter placement, especially during anticoagulant and thrombolytic therapy (3). The struts of the vena cava filter may pierce the vessel wall (4). However, most patients are asymptomatic and rarely develop retroperitoneal hematoma (5). However, the occurrence of sudden abdominal pain, severe hypotension, or shock after insertion of a filter, is highly suggestive of a retroperitoneal hematoma (6,7).

Vena cava filters are rarely complicated by retroperitoneal hematoma, especially when the retrievable Günther Tulip filter is used (8,9). The retrievable Günther Tulip filter has small barbed hooks at the caudal ends for fixation. This design of Tulip filters with less area that would come in contact with the vena cava can reduce the rate of vena cava perforation. Only one case of retrievable Günther Tulip filter placement complicated by sepsis and retroperitoneal hemorrhage has been reported, in 2005 (10). This case was a woman with right femoral vein thrombosis. A retrievable Günther Tulip filter was inserted before knee replacement surgery. A large hematoma was formed, and the patient went into shock. The filter was removed and retroperitoneal hemorrhage was successfully controlled.

In the present case, a 55-year-old man with a permanent IVC filter developed thrombosis of the vena cava. The original filter had lost its ability to prevent PE, and on the contrary, it can be a potential risk factor for PE. On this occasion, a retrievable Tulip filter was placed in the appropriate suprarenal position. The benefit of a retrievable filter is that it can be removed when occlusion of the IVC has resolved or the risk of pulmonary embolism is over. A retrievable IVC filter can be left in place as a permanent filter if the risk of PE persists. We have previously used the Tulip filter to treat thrombosis in the IVC (11). Although thrombolytic therapy was effective in the present case, a retroperitoneal hematoma was



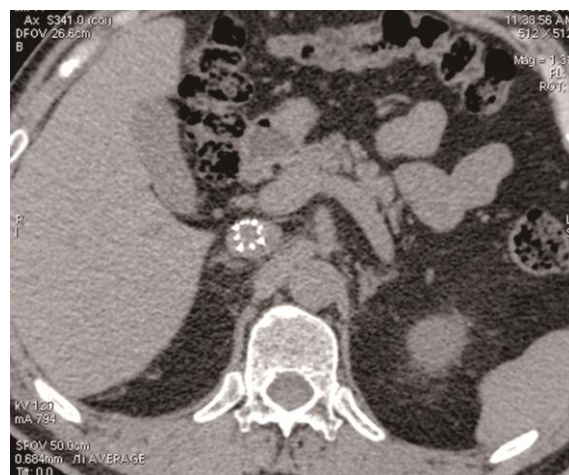**Figure 5.** Retroperitoneal hematoma absorbed gradually 2 months after discharge.



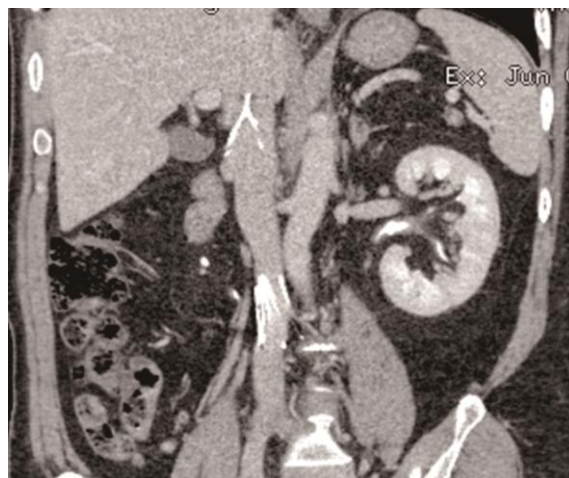**Figure 6.** Further shrinkage of retroperitoneal hematoma 3 months after discharge.

presented on the sixth day after the filter implantation. It has been suggested that placement of a filter in the suprarenal position of the IVC may lead to penetration of the IVC wall as a result of respiratory motion and cardiac and aortic pulsation (10). Others have suggested that the risk of penetration is greater in a smaller IVC (12). Our patient may have had both of these risk factors.

Leonardi et al. reported the treatment of retroperitoneal hematoma by surgery. However, the mortality rate of surgery was high, and there was no long-term follow-up information (13). In this case, we found that the retroperitoneal hematoma was caused by the perforation of IVC filter other than anticoagulant or thrombolysis, because INR was in the normal range during thrombolytic treatment. In this



**Figure 7.** Retroperitoneal hematoma disappear at 6 months.



**Figure 8.** Unobstructed vena cava and no recurrent thrombus.

way, the possibility of retroperitoneal hemorrhage induced by thrombolysis or anticoagulant was excluded. Although the filter retrieval attempts were unsuccessful due to filter tilt, the patient completely recovered by conservative treatment. Post-operation abdominal CT scans at 2, 3, and 6 months showed that there was no evidence of recurrent thrombus, and the hematoma was gradually absorbed.

## REFERENCES

1. Wang SL, Lloyd AJ. Clinical review: inferior vena cava filters in the age of patient-centered outcomes. *Ann Med* 2013; 45:474–481.
2. Sing RF, Fischer PE. Inferior vena cava filters: indications and management. *Curr Opin Cardiol* 2013; 28:625–631.

3. Hanlon D. An evidence-based approach to managing the anticoagulated patient in the emergency department. *Emerg Med Pract* 2011; 13:1–19; quiz 19.
4. Piecuch, Wiewiora, Nowowiejska W, et al. Perforation of inferior vena cava during filter placement. *Vasa* 2011; 40:157–162.
5. Ivascu FA, Janczyk RJ, Bair HA, et al. Spontaneous retroperitoneal hemorrhage. *Am J Surg* 2005; 189:345–347.
6. González C, Penado S, Llata L, et al. The clinical spectrum of retroperitoneal hematoma in anticoagulated patients. *Medicine* 2003; 82:257–262.
7. Wang Y, Chang H, Wang W, et al. Delayed retroperitoneal arterial hemorrhage after inferior vena cava filter deployment. *Medicine* 2018; 97:e9618.
8. Neuerburg JM, Günther RW, Vorwerk D, et al. Results of a multicenter study of the retrievable Tulip vena cava filter: Early clinical experience. *Cardiovasc Intervent Radiol* 1997; 20:10–16.
9. Ray CE, Jr., Kaufman JA. Complications of inferior vena cava filters. *Abdom Imaging* 1996; 21:368–374.
10. Shimizu M, Tatsumi K, Matsukawa R, et al. Retrievable Günther Tulip Filter complicated by sepsis and retroperitoneal hemorrhage: Successful management by filter retrieval. *Intern Med* 2005; 44:593–597.
11. Xiao L, Shen J, Tong J-J, et al. Transcatheter thrombolytic therapy for symptomatic thrombo-occlusion of inferior vena cava filter. *Exp Ther Med* 2012; 5:533–538.
12. Hoekstra A, Elstrodt JM, Nikkels PGJ, et al. Vessel wall reaction after vena cava filter placement. *Cardiovasc Intervent Radiol* 2002; 25:53–56.
13. Leonardi MJ. The rate of bleeding complications after pharmacologic deep venous thrombosis prophylaxis: A systematic review of 33 randomized controlled trials. *Arch Surg* 2006; 141:790–799.