

ORIGINAL ARTICLE

Influence of 2 Veress needles and 4 insertion sites on Veress needle penetration depth: A comparative study in cadaveric dogs

Katharina Leschnik DVM¹ | Barbara Bockstahler DVM, PD, Diplomate ACVSMR¹ |

Nikola Katic DVM, Diplomate ECVS¹ | Johannes P. Schramel DVM² |

Gilles Dupré Prof DVM, Diplomate ECVS¹

¹University Clinic of Small Animal Surgery, Department for Companion Animals and Horses, University of Veterinary Medicine, Vienna, Austria

²Department for Companion Animals and Horses, University of Veterinary Medicine, Vienna, Austria

Correspondence Katharina Leschnik, University Clinic of Small Animal Surgery, Department for Companion Animals and Horses, University of Veterinary Medicine, Veterinärplatz 1, 1210 Vienna, Austria.

Email: katharina.leschnik@vetmeduni.ac.at

Abstract

Objective: To evaluate the penetration depth (VNPd) of 2 disposable Veress needles (VN) at 4 insertion sites in the abdomen.

Study design: Descriptive study.

Sample population: Canine cadavers (n = 22, 6 for confirmation of the test methods and 16 for the comparative study).

Methods: Two disposable VN (VN A and VN B) were inserted at 4 sites (9th intercostal space [ICS] and preumbilical, paraumbilical, and subumbilical sites) in dorsally recumbent dogs by using a hand-cranked jig. The VNPd was measured as the distance traveled by the VN between the subcutaneous tissue and the perforation of the peritoneum on the basis of audible clicks and visible feedback from the VN. The effects of the VN type and insertion site on the VNPd were analyzed by using a linear mixed-effects model.

Results: VNPd varied between insertion sites ($P = .01$) and VN ($P < .01$). The VNPd was less at the 9th ICS than at the preumbilical, paraumbilical, and subumbilical sites. The maximal magnitude of change was 7.4 mm. Veress needle B (with a low spring rate, lower forces, and a back-cut bevel design) penetrated farther than VN A (with a high spring rate, high forces, and a lancet-type bevel) at 3 of 4 insertion sites. The maximal magnitude of change was 6.8 mm.

Conclusion: Veress needle penetration depth varied between VN designs but was the least at the 9th ICS in canine cadavers.

Clinical significance: Insertion of a VN at the 9th ICS is recommended to minimize its penetration into the abdomen. Associations between VNPd and mechanical factors, such as the sharpness and spring rate of VN, warrant additional research.

1 | INTRODUCTION

Laparoscopic surgery begins with the creation of a pneumoperitoneum, usually by insufflation of carbon dioxide into the peritoneal cavity.^{1,2} In small animals, the abdomen can be accessed with an open or closed approach.³ The open-access technique is often described as the *modified Hasson*

technique and is performed as a minilaparotomy. In contrast, the closed technique often uses blind penetration of the abdominal wall with a Veress needle (VN) and CO₂ insufflation to create a pneumoperitoneum.^{1,4–10}

Commercially available VN vary in length (100–160 mm) and consist of a beveled 14 gauge outer cannula with a hollow spring-loaded inner stylet that glides inside the lumen.¹¹ A hole

at the distal end of the stylet enables gas delivery. During passage through the tissue layers, the stylet is pushed into the shaft of the outer cannula, which exposes the sharp tip for cutting. After it is in the peritoneal cavity, the blunt tip of the stylet springs forward by extending the spring and overlaps the tip of the cannula to protect against compliant visceral injury.

The risk of damage to the underlying tissues arising from blind insertion of a VN into the peritoneal cavity is well recognized,^{12–15} and complications associated with VN entry have been reported in both man^{12–15} and dogs.^{5,16–18} These complications include injury to the abdominal or thoracic wall vasculature, injury to intra-abdominal or intrathoracic vessels, penetration of solid organs or hollow viscera, subcutaneous emphysema, and gas embolism.^{19,20} Pneumothorax can occur as a result of incorrect intercostal VN placement,¹⁶ and inadvertent positioning of the VN tip between the abdominal musculature and the peritoneum can lead to preperitoneal gas insufflation.²¹

Another complication reported with VN insertion is peritoneal tenting,¹⁹ which is also known as the *curtain effect*.²⁰ This phenomenon occurs when the peritoneum is displaced under the pressure of the inner stylet before the sharp cannula cuts through it; as a result, the peritoneum is not penetrated by the VN, and the distal extremity of the needle does not communicate with the peritoneal cavity.^{19,20} The ease of penetration and the pressure exerted on the abdominal wall of a given VN depend on the spring rate, the forces required to retract the stylet, the bevel design, and the sharpness. In one study,¹¹ differences in the spring rate and on the forces were found among 13 commercially available VN. Thus, the mechanical characteristics of the VN can contribute to peritoneal tenting.¹¹ In addition, this complication can vary with the site and angle of needle insertion. In man, peritoneal tenting is minimal at the umbilicus compared with other abdominal insertion sites and can be minimized by inserting the VN perpendicular to the abdomen.^{22,23} The impact of the insertion site on the potential development of peritoneal tenting has not been investigated in dogs.

The objective of this study was to compare the depth of penetration (VNPD) of 2 commercially available VN at 4 insertion sites (the 9th ICS and preumbilical, paraumbilical, and subumbilical sites) in the abdomen of canine cadavers.

2 | MATERIALS AND METHODS

2.1 | Canine cadavers

Six canine cadavers were used to develop and validate the test methods, and 16 cadavers were used for the comparative study. All dogs were euthanized unrelated to the study. All animals were client-owned, and written consent was obtained prior to inclusion in the study. The exclusion criteria included any abdominal surgery within 4 weeks prior

to death and any diseases that could have led to distension of the abdominal cavity (eg, gastric dilatation volvulus, hemoabdomen, and abdominal neoplasia). All canine cadavers were cooled to 4 °C immediately after death, and the experimental procedures were performed within 40 hours of death on the cooled cadavers.

2.2 | Veress needles

Two 14 gauge cannula VN that were determined to differ in their spring rates, forces, and bevel designs in a previously published study¹¹ were used for this investigation. VN A (EJ 995 Veress cannula, 120 mm, single use; Aesculap Endoscopic Technology, B. Braun, Tuttlingen, Germany) has a high spring rate, high forces, and a lancet-type bevel. VN B (PN 150 Endopath insufflation needle, 150 mm, single use; Ethicon Endo-Surgery, Cincinnati, Ohio) has a low spring rate, lower forces, and a back-cut bevel design. Both VN are equipped with built-in red-colored markers.

2.3 | Insertion sites

All dogs were positioned in dorsal recumbency. An orthogonal Cartesian light beam coordinate system with x-axis and y-axis was used (laparoscopy mapping system [LAPMAP]) to ensure comparable positions for every VN insertion site regardless of the dogs' weights or body conformation indices.²⁴ This device allowed standardization of the preumbilical, paraumbilical, and subumbilical VN positions (Figure 1). The center of the projection was the umbilicus, which was defined with the coordinates 0/0. The y-axis connected the umbilicus to the xiphoid, and the x-axis was set perpendicular to the y-axis at the level of the umbilicus. The basic unit was defined as 1/4 of the distance between the umbilicus and the xiphoid. The insertion point was denoted with either a “+” (to the right and up from 0/0) or a “–” (to the left and down from 0/0).

With the LAPMAP coordinate system, the VN insertion sites were defined as follows (Figure 1):

- Two paraumbilical: 1 basic unit lateral left and right of the umbilicus (LAPMAP coordinates: –1/0 and 1/0)
- Two subumbilical: 1 basic unit lateral and 1.5 basic units caudal of the umbilicus (LAPMAP coordinates: –1/–1.5 and 1/–1.5)
- Two preumbilical: 1 basic unit lateral and 1.5 basic units cranial of the umbilicus (LAPMAP coordinates: –1/1.5 and 1/1.5)
- Two 9th ICS: 2–3 cm lateral of the medial border of the costal arch

2.4 | Measurements

The dogs were clipped from the 6th rib to the caudal aspect of the abdomen. To avoid resistance during skin penetration, a standardized 5-mm skin incision was made prior to inserting the needle using a No. 10 scalpel blade. For the




FIGURE 1 Dog in dorsal recumbency with the light beam coordinate system projected on the ventral abdomen. The dog's head is at the top. L1, left 9th ICS; L2, left preumbilical; L3, left paraumbilical; L4, left subumbilical; R1, right 9th ICS; R2, right preumbilical; R3, right paraumbilical; R4, right subumbilical; U, umbilicus (center); X, xiphoid

preumbilical, paraumbilical, and subumbilical insertion sites, the dogs were positioned in dorsal recumbency with the thoracic limbs extended cranially and the hind limbs extended caudally. For the 9th ICS insertion site, the dogs were tilted 45° to the contralateral side of the needle insertion site. The VN was inserted perpendicular to the long axis of the body at all insertion sites.

The VNPD was defined as the distance the VN had to travel between entry into the subcutaneous tissue and perforation of the peritoneum. For this study, perforation of the peritoneum was determined indirectly on the basis of positive double-click and spring-back tests. The double click refers to 2 clicks that can be heard during VN insertion. The first click corresponds to perforation of the muscle fascia when the stylet retracts, and the second click is heard when the stylet springs forward after the peritoneum is perforated.^{16,25} Spring back refers to the exposure and then disappearance of the red marker in the stylet as the stylet retracts and then springs forward in the proximal and distal positions, respectively. The VNPD was measured with a homemade device (Figure 2). The jig of the device consisted of a vertically adjustable VN holder that could be moved slowly toward the abdominal surface by turning a hand wheel. The VN was fixed in the device so that the VN tip could be brought into contact with the subcutaneous tissue. The adjustable stop was fixed at this point, which was represented as 0. Then, the examiner turned the hand wheel

slowly until positive results were obtained for both the double-click and spring-back tests. The distance (mm) between these 2 positions (ie, the adjustable stop and the needle holder) was measured within a resolution of 0.02 mm by using a 150-mm digital caliper (Meister, Wuppertal, Germany) and recorded. All measurements were performed by a single investigator (KL).

To assess the accuracy of the double-click and spring-back tests for the detection of peritoneal membrane perforation in cooled cadaveric dogs, VN were placed in 6 cadavers with 1 new VN of each type per site. After positive results were obtained for both tests, 0.2 mL of India ink was injected through the VN prior to removal. After completion of the placements, a midline celiotomy was performed to determine the location of the injected India ink. Thereafter, VNPD measurements were collected from 16 additional cadavers by using a standardized placement order (Table 1), with 1 new VN A and 1 new VN B used for each side of the body.

2.5 | Statistical analysis

All statistical analyses were performed in SPSS v22 (IBM, Armonk, New York). The normality of the data distribution was assessed with the Kolmogorov-Smirnov test. The effects of factors on the VNPD were analyzed by using a linear




FIGURE 2 Test jig for measuring the Veress needle penetration depth (VNPD). The VN (4) was fixed in the vertically adjustable VN holder (2). After the VN tip was brought into contact with the subcutaneous tissue, the adjustable stop (1) was fixed at this point, which is represented as 0. Then, the hand wheel (3) was turned until the peritoneal membrane was perforated, as indicated by the 2 surrogate markers. The distance between the adjustable stop (1) and the needle holder (2) was measured and defined as the VNPD

TABLE 1 Order of VN insertions

Cadaver	VN A				VN B			
	1st	2nd	3rd	4th	1st	2nd	3rd	4th
1	L1	L2	L3	L4	R1	R2	R3	R4
2	R1	R2	R3	R4	L1	L2	L3	L4
3	L2	L3	L4	L1	R2	R3	R4	R1
4	R2	R3	R4	R1	L2	L3	L4	L1
5	L3	L4	L1	L2	R3	R4	R1	R2
6	R3	R4	R1	R2	L3	L4	L1	L2
7	L4	L1	L2	L3	R4	R1	R2	R3
8	R4	R1	R2	R3	L4	L1	L2	L3
9	R1	R2	R3	R4	L1	L2	L3	L4
10	L1	L2	L3	L4	R1	R2	R3	R4
11	R2	R3	R4	R1	L2	L3	L4	L1
12	L2	L3	L4	L1	R2	R3	R4	R1
13	R3	R4	R1	R2	L3	L4	L1	L2
14	L3	L4	L1	L2	R3	R4	R1	R2
15	R4	R1	R2	R3	L4	L1	L2	L3
16	L4	L1	L2	L3	R4	R1	R2	R3

L1, left 9th ICS; L2, left preumbilical; L3, left paraumbilical; L4, left subumbilical; R1, right 9th ICS; R2, right preumbilical; R3, right paraumbilical; R4, right subumbilical; VN, Veress needle.

mixed-effects model that included the VN type and insertion site as fixed factors and the number of VN uses and body side as covariates. The cadaver was treated as a random factor. A post hoc analysis was performed to assess difference between the insertion site and the number of VN uses with the Sidak α correction procedure. $P < .05$ was considered significant.

3 | RESULTS

3.1 | Canine cadavers

The cadavers used for this study were from the following breeds: Dalmatian ($n = 1$), Doberman ($n = 1$), German shepherd ($n = 2$), golden retriever ($n = 1$), Labrador retriever ($n = 3$), Pinscher ($n = 1$), Rottweiler ($n = 2$), Staffordshire ($n = 3$), mixed breed ($n = 6$), spaniel ($n = 1$), and Munsterlander ($n = 1$). The reproductive status and sex composition of the cadavers were spayed females ($n = 13$), intact females ($n = 4$), neutered males ($n = 3$), and intact males ($n = 2$). The ranges for the age and weight values were 1.5-14.0 years (8.8 ± 3.8) and 15-30 kg (24.9 ± 5.1), respectively.

3.2 | Validation of the VNPd measurement technique

Positive double-click and spring-back test results were obtained for both needles at each site in all 6 cadavers. India ink was confirmed to be intraperitoneal for all placements.

3.3 | Differences between VN models

Compared with VN A, VN B had less VNPd at the preumbilical ($P = .013$), paraumbilical ($P = .018$), and

subumbilical ($P = .047$) insertion sites. The maximal magnitude of change was 6.8 mm, 6.8 mm, and 6.1 mm, respectively. No difference in the VNPd was observed between the needles for placements at the 9th ICS insertion site (Figure 3).

3.4 | Differences between insertion sites

The VNPd was less at the 9th ICS than at the preumbilical ($P = .041$) and subumbilical ($P = .012$) sites when the results for both needles were combined. This result was due to differences in VNPd among insertion sites for VN A alone, with less VNPd at the 9th ICS than at the preumbilical ($P = .021$; maximal difference was 6.8 mm) and subumbilical ($P = .013$; maximal difference was 7.4 mm) sites (Figure 3).

3.5 | Body side and number of VN applications

The body side did not influence the VNPd. No differences were found between the 1st and 4th VN applications across uses of the same VN. Table 2 summarizes the mixed model analysis.

4 | DISCUSSION

In this study, the depth of penetration of Veress needles varied among insertion sites and between the tested VN. The use of VN B was associated with less VNPd compared with VN A for all 3 umbilical sites (preumbilical, paraumbilical, and subumbilical) but not for the 9th ICS. When both needles were evaluated together, the VNPd was lower at the

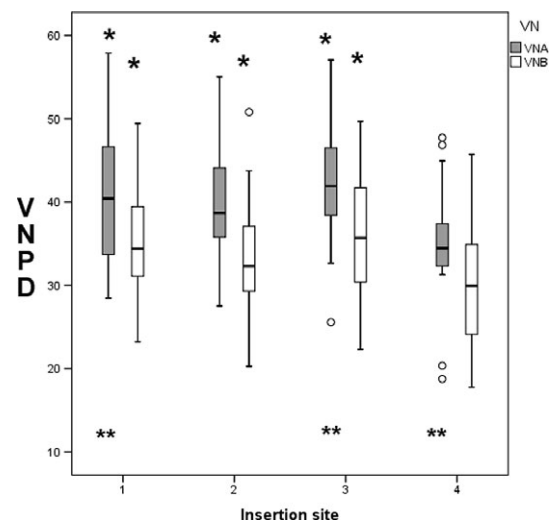


FIGURE 3 Box plot diagram of the VNPd for VN A and VN B at 4 insertion sites in 16 cadaveric dogs. Insertion site: 1, preumbilical; 2, paraumbilical; 3, subumbilical; 4, 9th ICS. *VN B less VNPd compared with VN A at the preumbilical, paraumbilical, and subumbilical insertion site. **VNPd less at the 9th ICS compared with preumbilical and subumbilical insertion site for VN A. VNPd, Veress needle penetration depth

TABLE 2 Primary effects and interactions resulting from the linear mixed-effects model^a

Effect/interaction	F value	P value
VN	17.9	< .001
Insertion site	4.2	.010
Number of VN applications	<1	.714
Body side	<1	.868
VN × insertion site	<1	.919
VN × No. of VN applications	<1	.627

VN, Veress needle.

^a Significant differences in the VNPD were observed between the VN types (VN A or VN B) and among the insertion sites (preumbilical, paraumbilical, and subumbilical, and 9th ICS).

9th ICS than at the preumbilical and subumbilical insertion sites but not at the paraumbilical site. This discrepancy was due to difference in the VNPD for VN A and a lack of difference in the VNPD among the insertion sites for VN B.

4.1 | Assessment of VN penetration

Several studies have described tests and techniques that can be used to determine correct VN placement in man and pigs,^{2,26,27} including the double-click sound test, aspiration test, hanging drop-of-saline test, “hiss” sound test, and initial intra-abdominal gas pressure test. In the present study, intraperitoneal positioning of the VN in cooled canine cadavers was assessed by using both the double-click sound test and the spring-back test with a red-colored built-in marker. One human study evaluating the reliability of 4 commonly used tests found that the gas pressure test was most reliable for detection of preperitoneal placement of the VN, which is the most common entry-related complication and occurs in 5% of cases.²⁷ Although it is not life threatening, this complication frequently leads to abandonment of the blind-entry procedure.²⁸ In our study, gas pressure tests were not performed because verifying intraperitoneal placement of the VN with this test would have influenced the results of subsequent insertions due to dilation of the abdomen. The same rationale applies to laparoscopic observation of the VN position.

Some authors have reported that the click sound associated with the springing forward of the blunt stylet's entrance into the peritoneal cavity is subjective and may be influenced by external factors, such as ambient noise.² We are not aware of any studies in the veterinary literature that have evaluated correct VN placement in anesthetized patients. In a dog cadaver study, the interpretations of tissue impedance measurements resulted in a 90% accuracy and 100% specificity for identification of incorrect VN placement.²⁹ In another veterinary study that evaluated intercostal insertions of VN, the authors confirmed that correct intraperitoneal placement was achieved after a clear double click was heard.¹⁶ In the present study, a 100% rate of correct intraperitoneal placement was found when the double-click test and the spring-back test with the red-colored built-in marker

were used for VN placement in cooled canine cadavers. Extrapolation of these results to live animals should be performed with extreme caution because of the differences in technique and patient characteristics. Specifically, the VN are placed freehand in clinical cases instead of using a hand-cranked jig, which may preclude the detection of the double click, particularly when this is combined with the increased ambient noise in the operating room due to anesthetic monitoring equipment. In addition, tissue compliance and intestinal gas distension can be anticipated to differ greatly among living dogs and cadavers stored at 4 °C.

4.2 | Peritoneal tenting and VNPD

Although some authors have mentioned that peritoneal tenting is unlikely in animals with a tightly adherent peritoneum, such as dogs and goats,¹⁹ we are unaware of any study that has validated this conjecture. For this study, the distance that the VN travelled between the subcutaneous tissue and the peritoneal perforation, which was based on 2 surrogate markers of perforation, was defined as the VNPD. The depth of penetration of the VN may correspond to the body wall thickness as well as the displacement of the inner abdominal wall. Because differences occurred between the 2 VN at the same site in paired evaluations, these differences were most likely due to the mechanical characteristics of the VN. Nevertheless, neither the body wall thickness nor its influence on the VN performance and actual VNPD were evaluated.

4.3 | VN insertion sites and patient positions

Intercostal insertion of the VN is recommended as a safer approach to abdominal access in man.^{30–32} In a canine cadaver study conducted by Doerner et al,³³ the free abdominal wall was evaluated in the subxyphoidian and perixyphoidian regions, and the right 9th ICS entry point was found to be associated with the lowest frequency of intra-abdominal structure penetrations among the intercostal insertion sites. In an in vivo study, Fiorbianco et al¹⁶ demonstrated that VN insertion in the last palpable right ICS with the dog in dorsal recumbency (presumably at the 9th or 10th ICS) resulted in the fewest injuries. Our results similarly provide evidence that VN insertion at the 9th ICS results in a reduced VNPD compared with insertion at umbilical or periumbilical sites. Our study also provides evidence that the advantages of inserting the VN in the ICS come not only from the free abdominal space but also from the resistance offered by the rib cage.³³ Because the intercostal tissues are stretched between 2 ribs, displacement of the tissue layers is less likely to occur at this site than at periumbilical sites. Nevertheless, insertions of VN in the 9th ICS must be performed with caution because iatrogenic bleeding from intercostal vessels can occur,³ and transdiaphragmatic insertion can result in pneumothorax.¹⁶

Because most VN insertions described in reports of small animal laparoscopy are performed with patients in dorsal recumbency and the VN inserted periumbilically,^{1,6-8,10,34-37} most reported complications are expected to be related to periumbilical entry.^{7,8,17} Few studies in the veterinary literature have reported no complications due to VN insertion with live patients in lateral recumbency.³⁷⁻⁴¹ Because lateral recumbency is infrequently used in laparoscopic practice, lateral insertion sites were not evaluated in the current report. The current study used a noncontact coordinate system (ie, the LAPMAP system) that had been previously demonstrated to be a reliable reproduction of the insertion sites of trocars in laparoscopic surgery.²⁴ The system was successfully adopted in this study to match different periumbilical insertion sites with respect to variable cadaver sizes. A jig machine was used to facilitate the reproducible and controlled insertion of the VN, and the same operator manipulated the hand wheel throughout the study. The VN was inserted perpendicular to the long axis of the body at each of the insertion sites. For the 9th ICS, the cadavers were tilted 45° to the contralateral side of the VN insertion site to mimic natural insertion at the 9th ICS as described by Doerner et al.³³ In man, the angle of VN insertion in the periumbilical region varies according to the body mass, from 45° in nonobese patients to 90° in very obese patients.²⁸ In addition, in both species, the rib cage or the abdominal wall should be elevated before inserting the VN to provide counter pressure against the advancing VN.^{16,42} Influences attributable to wall lifting and the insertion angle on the VNPd were not addressed in the present study.

In this study, disposable needles were used, and each needle was inserted 4 times. The repeated use of disposable VN in this study may have been associated with an unobservable loss of sharpness, resulting in a greater VNPd. We sought to prevent the possible influence of needle abrasion resulting from repeated insertions by applying a defined insertion procedure, which was characterized by changing the site of the first VN insertion for every cadaver. Furthermore, we did not find any significant difference in the VNPd between the 1st and the 4th applications of the same VN.

The ease of penetration and the pressure exerted on the abdomen depend on the spring rate, the forces required to retract the stylet, the bevel design, and the sharpness of the VN used. Although cannulas with lancet bevel designs required less penetration force than back-bevel design cannulas in a previous study,⁴³ the opposite trend was found in our evaluation. In addition, the 2 VN selected for this study differed in spring rates and forces. Sharpness, which affects the force that must be exerted on the abdominal wall to achieve penetration, was not determined but presumably differed between the 2 VN. Therefore, we could not determine which mechanical property had the greatest effect on the VNPd. However, our results suggest that differences among

commercially available VN can influence the VNPd and, thus, possibly the likelihood of secondary injuries.

Our study has several limitations. First, all measurements were conducted by 1 investigator (KL) who was not blinded to the hypothesis or to the characteristics of the VN; thus, the hypothesis was 1-sided, and the outcomes were based on surrogates. Furthermore, only 2 VN types were evaluated; therefore, the results of the present study cannot be extrapolated to other VN types. Finally, for the purpose of this study, we used canine cadavers, and extrapolations of our results to living animals should be made with caution. Whittemore et al.²⁹ demonstrated that tissue integrity was stable for up to 40 hours after death, so we chose to use cadavers of dogs that had been dead for less than 40 hours. However, other factors associated with live animals, such as breathing and intestinal movements as well as the individual variability in intra-abdominal topography or adhesions, could influence the VNPd. In addition, performance of VN placement in cooled cadavers could have affected the VN performance by altering body wall compliance and intestinal gaseous distension, as previously discussed.

In conclusion, VNPd differed among insertion sites and between VN models. Our study also provides evidence that inserting the VN into the 9th ICS results in a reduced VNPd compared with other periumbilical insertion sites. Therefore, we suggest the use of this site as long as the risk of iatrogenic pneumothorax is taken into account. Furthermore, our study provides evidence that peritoneal membrane perforation secondary to VN introduction by using a hand-cranked jig in cooled cadavers can be assessed by using audible and visual feedback. Additional evaluation using freehand placement of the VN in live animals should be performed before extrapolating these results to clinical practice. Additional investigations are warranted to determine which specific factors of needle design and manufacture have the greatest influence on VNPd.

ACKNOWLEDGMENT

The authors thank Alexander Tichy for his statistical support.

CONFLICT OF INTEREST

The authors declare no conflicts of interest related to this report.

REFERENCES

1. Monnet E, Twedt DC. Laparoscopy. *Vet Clin North Am Small Anim Pract.* 2003;33:1147-1163.
2. Toro A, Mannino M, Cappello G, Di Stefano A, Di Carlo I. Comparison of two entry methods for laparoscopic port entry: technical point of view. *Diagn Ther Endosc.* 2012;2012:305428.
3. Mayhew PD. Complications of minimally invasive surgery in companion animals. *Vet Clin North Am Small Anim Pract.* 2011;41:1007-1021.

4. Dujowich M, Keller ME, Reimer SB. Evaluation of short- and long-term complications after endoscopically assisted gastropexy in dogs. *J Am Vet Med Assoc.* 2010;236:177-182.
5. Dupre G, Fiorbianco V, Skalicky M, Gultiken N, Ay SS, Findik M. Laparoscopic ovariectomy in dogs: comparison between single portal and two-portal access. *Vet Surg.* 2009;38:818-824.
6. Devitt CM, Cox RE, Hailey JJ. Duration, complications, stress, and pain of open ovariohysterectomy versus a simple method of laparoscopic-assisted ovariohysterectomy in dogs. *J Am Vet Med Assoc.* 2005;227:921-927.
7. Wenkel R, Ziemann U, Thielebein J, Prange H. Laparoskopische kastration der hündin—darstellung neuer verfahren zur minimal invasiven ovariohysterektomie. *Tierarztl Prax.* 2005;33:177-188.
8. Davidson EB, Moll HD, Payton ME. Comparison of laparoscopic ovariohysterectomy and ovariohysterectomy in dogs. *Vet Surg.* 2004;33:62-69.
9. Spinella G, Romagnoli N, Valentini S, Spadari A. Application of the “extraction bag” in laparoscopic treatment of unilateral and bilateral abdominal cryptorchidism in dogs. *Vet Res Commun.* 2003;27 Suppl 1:445-447.
10. Kolata RJ, Freeman LJ. Access, port placement, and basic endosurgical skills. In: Freeman LJ, ed. *Veterinary Endosurgery.* St Louis, MO: Elsevier; 1999:44-60.
11. Schramel JP, Kindslehner A, Bockstahler BA, Dupre GP. Comparison of design features and mechanical properties of commercially available veress needles. *Vet Surg.* 2017;46:994-1001.
12. Azevedo JL, Azevedo OC, Miyahira SA, et al. Injuries caused by Veress needle insertion for creation of pneumoperitoneum: a systematic literature review. *Surg Endosc.* 2009;23:1428-1432.
13. Schafer M, Lauper M, Krahenbuhl L. Trocar and Veress needle injuries during laparoscopy. *Surg Endosc.* 2001;15:275-280.
14. Reich H, Ribeiro SC, Rasmussen C, Rosenberg J, Vidali A. High-pressure trocar insertion technique. *JSLs.* 1999;3:45-48.
15. Hashizume M, Sugimachi K. Needle and trocar injury during laparoscopic surgery in Japan. *Surg Endosc.* 1997;11:1198-1201.
16. Fiorbianco V, Skalicky M, Doerner J, Findik M, Dupré G. Right intercostal insertion of a veress needle for laparoscopy in dogs. *Vet Surg.* 2012;41:367-373.
17. Hardie RJ, Flanders JA, Schmidt P, Credille KM, Pedrick TP, Short CE. Biomechanical and histological evaluation of a laparoscopic stapled gastropexy technique in dogs. *Vet Surg.* 1996;25:127-133.
18. Gilroy BA, Anson LW. Fatal air embolism during anesthesia for laparoscopy in a dog. *J Am Vet Med Assoc.* 1987;190:552-554.
19. Freeman LJ. Complications. In: Freeman LJ, ed. *Veterinary Endosurgery.* St Louis, MO: Elsevier; 1999:92-102.
20. Dupré G, Fiorbianco V. Laparoscopy. In: Griffon D, Hamaide A, eds. *Complications in Small Animal Surgery.* 1st ed. Oxford, United Kingdom: Wiley; 2016:362-369.
21. Rawlings CA. Laparoscopy. In: Tams TR, Rawlings CA, eds. *Small Animal Endoscopy.* 3rd ed. St Louis, MO: Elsevier; 2011:397-417.
22. Ternarmian A. Laparoscopic abdominal entry by the ternarmian threaded visual system. In: Tinelli A, ed. *Laparoscopic Entry.* 1st ed. London, United Kingdom: Springer; 2012:33-60.
23. Ternarmian A. Port dynamics during laparoscopic accessing. *Obstet Gynecol.* 2000;95:S35.
24. Katic N, Fromme V, Bockstahler B, Dupré G. Mapping system for portal placement in laparoscopic procedures of small animals. *BMC Vet Res.* 2015; 11:212.
25. Gould JC, Philip A. Principles and techniques of abdominal access and physiology of pneumoperitoneum. *Sci Am Surg.* 2011. doi: 10.2310/7800.2203. Accessed August 17, 2018.
26. Azevedo JL, Guindalini RS, Sorbello AA, et al. Evaluation of the positioning of the tip of the Veress needle during creation of closed pneumoperitoneum in pigs. *Acta Cir Bras.* 2006;21:26-30.
27. Teoh B, Sen R, Abbott J. An evaluation of four tests used to ascertain veress needle placement at closed laparoscopy. *J Minim Invasive Gynecol.* 2005; 12:153-158.
28. Vilos G, Ternarmian A, Dempster J, Laberge P. Society of Obstetricians and Gynaecologists of Canada. Laparoscopic entry: a review of techniques, technologies, and complications. *J Obstet Gynaecol Can.* 2007;29: 433-465.
29. Whittemore JC, Mitchell A, Hyink S, Reed A. Diagnostic accuracy of tissue impedance measurement interpretation for correct veress needle placement in canine cadavers. *Vet Surg.* 2013;42:613-622.
30. Kumar S. Veress needle insertion through left lower intercostal space for creating pneumoperitoneum: experience with 75 cases. *J Minim Access Surg.* 2012;8:85-89.
31. Agarwala N, Liu CY. Safe entry techniques during laparoscopy: left upper quadrant entry using the ninth intercostal space—a review of 918 procedures. *J Minim Invasive Gynecol.* 2005;12:55-61.
32. Reich H, Levie M, McGlynn F, Sekel L. Establishment of pneumoperitoneum through the left ninth intercostal space. *Gynecol Endosc.* 1995;4:141-143.
33. Doerner J, Fiorbianco V, Dupre G. Intercostal insertion of veress needle for canine laparoscopic procedures: a cadaver study. *Vet Surg.* 2012;41:362-366.
34. Duerr FM, Twedt DC, Monnet E. Changes in pH of peritoneal fluid associated with carbon dioxide insufflation during laparoscopic surgery in dogs. *Am J Vet Res.* 2008;69:298-301.
35. Barnes RF, Greenfield CL, Schaeffer DJ, Landolfi J, Andrews J. Comparison of biopsy samples obtained using standard endoscopic instruments and the harmonic scalpel during laparoscopic and laparoscopic-assisted surgery in normal dogs. *Vet Surg.* 2006;35:243-251.
36. Miller NA, Van Lue SJ, Rawlings CA. Use of laparoscopic-assisted cryptorchidectomy in dogs and cats. *J Am Vet Med Assoc.* 2004;224: 875-878, 865.
37. Hewitt SA, Brisson BA, Sinclair MD, Foster RA, Swayne SL. Evaluation of laparoscopic-assisted placement of jejunostomy feeding tubes in dogs. *J Am Vet Med Assoc.* 2004;225:65-71.
38. Pelaez MJ, Bouvy BM, Dupre GP. Laparoscopic adrenalectomy for treatment of unilateral adrenocortical carcinomas: technique, complications, and results in seven dogs. *Vet Surg.* 2008;37:444-453.
39. Webb CB, Trott C. Laparoscopic diagnosis of pancreatic disease in dogs and cats. *J Vet Intern Med.* 2008;22:1263-1266.
40. Harmoinen J, Saari S, Rinkinen M, Westermarck E. Evaluation of pancreatic forceps biopsy by laparoscopy in healthy beagles. *Vet Ther.* 2002;3:31-36.
41. Grauer GF, Twedt DC, Mero KN. Evaluation of laparoscopy for obtaining renal biopsy specimens from dogs and cats. *J Am Vet Med Assoc.* 1983;183: 677-679.
42. Ternarmian A. Laparoscopic entry safety. <http://www.comtecmed.com/cogilcogi5/abstracts/Ternarmian.doc>. Accessed August 17, 2018.
43. Meyer CH, Kaymak H, Liu Z, Saxena S, Rodrigues EB. Geometry, penetration force, and cutting profile of different 23-gauge trocars systems for pars plana vitrectomy. *Retina.* 2014;34:2290-2299.

How to cite this article: Leschnik K, Bockstahler B, Katic N, Schramel JP, Dupré G. Influence of 2 Veress needles and 4 insertion sites on Veress needle penetration depth: A comparative study in cadaveric dogs. *Veterinary Surgery.* 2018;47:1094–1100. <https://doi.org/10.1111/vsu.12956>