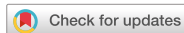



Review Article



Coronary Artery Disease Reporting and Data System: A Comprehensive Review

Parveen Kumar , MD, EDiR, DCBCCT, DICRI¹, and
Mona Bhatia , MD, FRCR, FSCCT^{1,2,3}

¹Department of Radiodiagnosis & Imaging, Fortis Escort Heart Institute, New Delhi, India

²Cardiac Imaging, Cardiological Society of India, Kolkata, India

³International Regional Committee, India Chapter, Society of Cardiovascular Computed Tomography, Arlington, VA, USA



Received: Oct 23, 2020

Revised: Feb 2, 2021

Accepted: Feb 7, 2021

Published online: Mar 23, 2021

Address for Correspondence:

Parveen Kumar, MD, EDiR, DCBCCT, DICRI

Department of Radiodiagnosis & Imaging,
Fortis Escort Heart Institute, Okhla road,
Sukhdev Vihar Metro Station, New Delhi, Delhi,
110025, India.

Email: drparveenbatra@gmail.com


Copyright © 2022 Korean Society of
Echocardiography

This is an Open Access article distributed
under the terms of the Creative Commons
Attribution Non-Commercial License (<https://creativecommons.org/licenses/by-nc/4.0/>)
which permits unrestricted non-commercial
use, distribution, and reproduction in any
medium, provided the original work is properly
cited.

ORCID iDs

Parveen Kumar 

<https://orcid.org/0000-0003-0361-4801>

Mona Bhatia 

<https://orcid.org/0000-0001-8988-4997>

Conflict of Interest

The authors have no financial conflicts of
interest.

Author Contributions

Conceptualization: Kumar P; Formal analysis:
Kumar P; Software: Kumar P; Supervision:
Kumar P; Writing - original draft: Kumar P;
Writing - review & editing: Bhatia M.

ABSTRACT

The Coronary Artery Disease Reporting and Data System (CAD-RADS) is a standardized reporting method for coronary computed tomography angiography (CCTA). It summarizes the findings of CCTA in 6 categories ranging from CAD-RADS 0 (complete absence of coronary artery disease) to CAD-RADS 5 (total occlusion of at least one vessel). It is applied on per patient basis for the highest grade of the stenotic lesion. The CAD-RADS also provides category-specific treatment recommendations, helping patient management. The main objectives of the CAD-RADS are to improve the consistency in reporting, facilitate the communication between interpreting and referring clinicians, recommend the best course of patient management, and produce consistent data for quality improvement, research and education. However, CAD-RADS has many limitations, resulting into the misclassification of the observed findings, misinterpretation of the final category, and misguidance for the treatment based upon the single score. In this review, the authors discuss the CAD-RADS categories and modifiers, along with the strengths and limitations of this new classification system.

Keywords: Coronary artery disease; Stenosis; Coronary artery

INTRODUCTION

Coronary computed tomography angiography (CCTA) has emerged as a powerful non-invasive diagnostic tool for evaluating coronary arteries in patients with low to intermediate risk of obstructive coronary artery disease. With advancements in the technology, there has been vast expansion in the clinical applications of CCTA, and various radiological societies have issued guidelines, appropriateness criteria and expert consensus on CCTA.¹⁻⁵⁾ Many clinical trials (CT-STAT, ACRIN-PA, ROMICAT II, and CT-COMPARE) have demonstrated the improved diagnostic performance of CCTA compared with standard evaluation strategies in both acute and stable chest pain.⁵⁻⁹⁾ After the establishment of the Society of Cardiovascular Computed Tomography (SCCT) guidelines for the interpretation and reporting of CCTA, the prime focus of CCTA was to rule out coronary atherosclerotic disease (CAD) and to categorize luminal stenosis if present. However, the lack of standardization has led to great variability in reporting among practitioners. Other fields in medical imaging have already introduced standardized reporting formats like Breast Imaging Reporting and Data System, Liver

Imaging Reporting and Data System, Prostate Imaging Reporting and Data System, and Lung Imaging Reporting and Data System, which have allowed clinicians to interpret the clinical relevance of structured and standardized reported findings and take appropriate action.

In 2016, multiple radiological and cardiological societies introduced the Coronary Artery Disease Reporting and Data System (CAD-RADS) as a collaborative effort. The initiative was sponsored by the SCCT, the American College of Cardiology, the American College of Radiology, and the North American Society for Cardiovascular Imaging.¹⁰⁾ The main goals of CAD-RADS are to ensure consistency in reporting, enhance the communication between interpreting and referring clinicians, determine the best course of patient care, and generate consistent data for quality improvement, research, and education. The purpose of this review is to discuss the CAD-RADS categories and modifiers, along with illustrative examples. The strengths and limitations of CAD-RADS are also discussed.

CAD-RADS REPORTING SYSTEM

CAD-RADS is applied on per-patient basis for the highest grade of coronary artery stenosis. It is applicable only for vessels greater than 1.5 mm in diameter. The scan indications, imaging protocol, training standards, and scan interpretation are based on SCCT guidelines.¹¹⁾¹²⁾ The final CAD-RADS category is decided on based on the severity of coronary artery stenosis, plaque morphology, evaluation of stent, and analysis of coronary artery bypass grafts (CABGs). It should be kept in mind that CAD-RADS classification does not replace the report and is only complementary to the conclusion section of the report. The detailed analysis of each coronary segment should be mentioned in the descriptive report.

CAD-RADS CATEGORIES

There are 6 CAD-RADS categories, ranging from CAD-RADS 0 (no plaque) to CAD-RADS 5 (at least one total occlusion). The category is assigned based on the highest grade of stenosis present. CAD-RADS 0 represent no atherosclerotic disease in any coronary artery (**Figure 1**). A single maximum stenosis of 1%–24% is classified as CAD-RADS 1 (**Figure 2**); 25%–49% is classified as CAD-RADS 2 (**Figure 3**); 50%–69% is classified as CAD-RADS 3 (**Figure 4**); and 70%–99% is classified as CAD-RADS 4. CAD-RADS 4 is divided into 2 subcategories: 4A, which corresponds to a single or two vessel stenosis of 70%–99% (**Figure 5**), and 4B, which corresponds to three vessel stenosis of 70%–99% or a single 50%–99% stenosis in the left main artery (**Figure 6**). CAD-RADS 5 represents total occlusion of at least one vessel (**Figure 7**) which can be acute or chronic. Features such as calcification and collateralization represent chronic etiology. Differentiating acute from chronic occlusive plaque has clinical relevance in deciding the management plan. CAD-RADS N is a special category which is assigned if some segments of coronary arteries are non-interpretable and the interpretable segments show stenosis <50% (**Figure 8**). These patients require repeat CCTA or alternate diagnostic tests to rule out obstructive CAD.

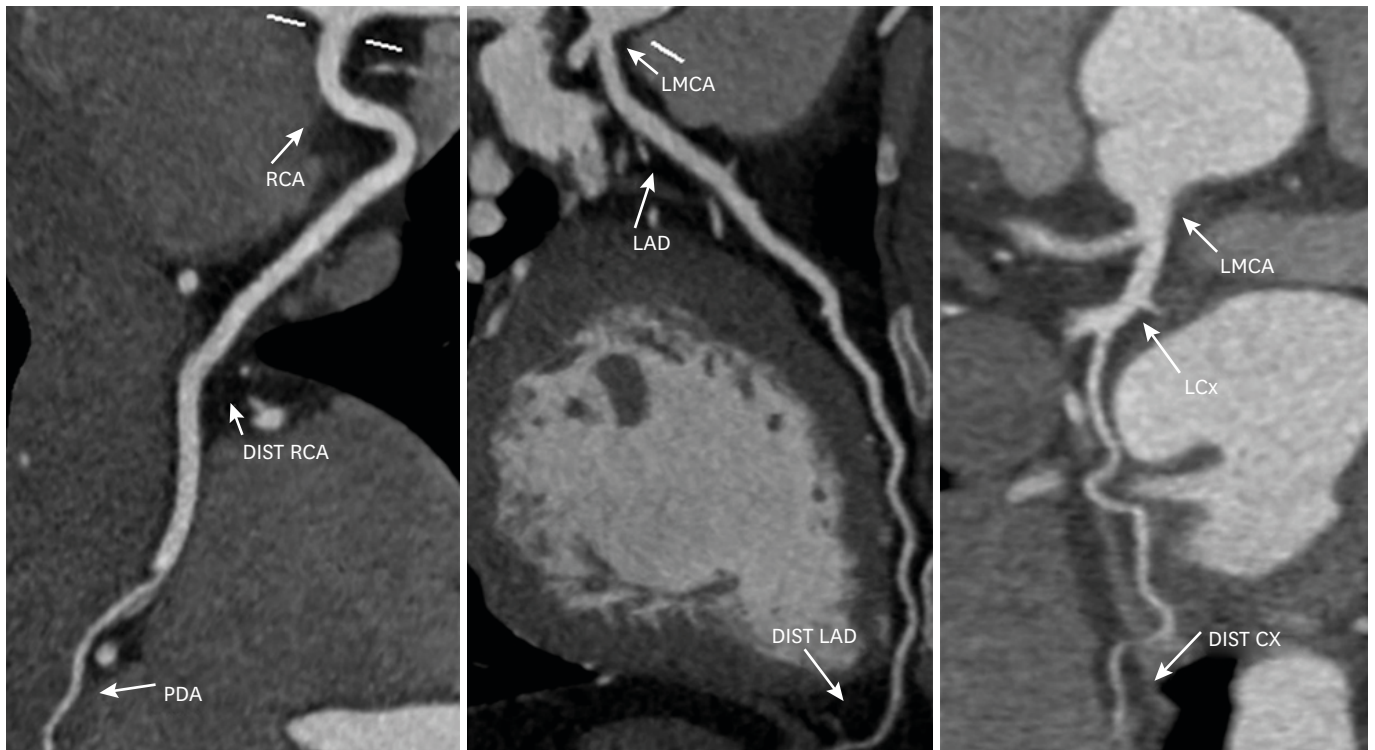


Figure 1. Coronary Artery Disease Reporting and Data System 0 in a 45-year-old man with a history of chronic chest pain. Curved multiplanar reformatted computed tomography angiographic image of the RCA, LAD artery, and LCx artery reveal normal coronary arteries with no atherosclerotic disease or stenosis. No further imaging was recommended. CX: circumflex artery, DIST: distal, LAD: left anterior descending, LCx: left circumflex, LMCA: left main coronary artery, PDA: posterior descending artery, RCA: right coronary artery.

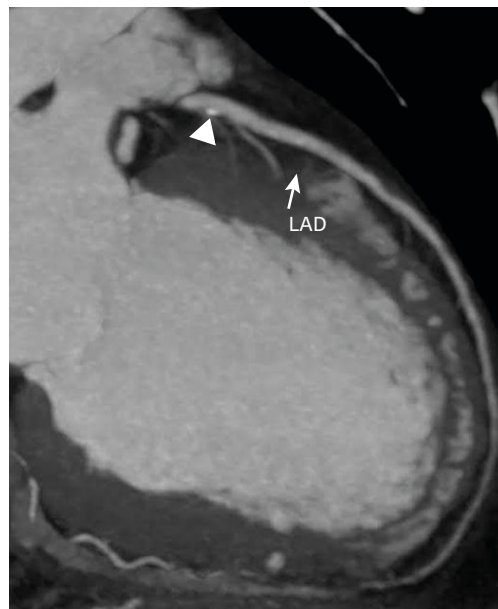


Figure 2. Coronary Artery Disease Reporting and Data System 1 in a 38-year-old man with atypical chest pain. Curved multiplanar reformatted computed tomography angiographic image show a discrete partially calcified plaque in the proximal LAD (white arrowhead) causing minimal stenosis (<25%). No further imaging was recommended. LAD: left anterior descending.

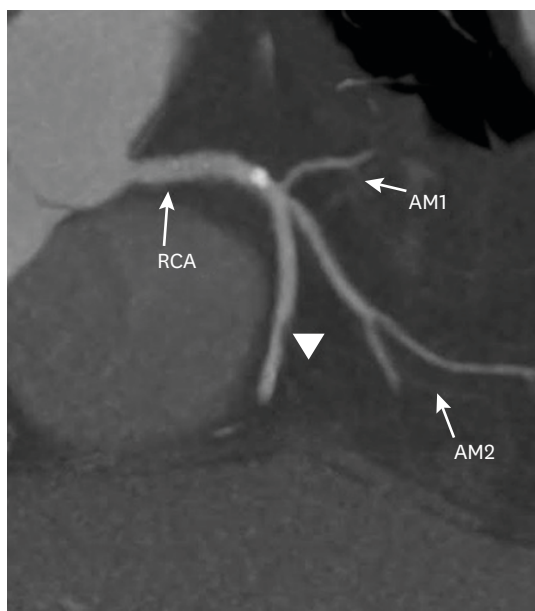


Figure 3. Coronary Artery Disease Reporting and Data System 2 in a 56-year-old man with chronic chest pain. Curved multiplanar reformatted computed tomography image of the RCA reveals a noncalcified plaque (white arrowhead) causing mild stenosis (25%–49%). No further imaging was recommended. AM1: first acute marginal, AM2: second acute marginal, RCA: right coronary artery.

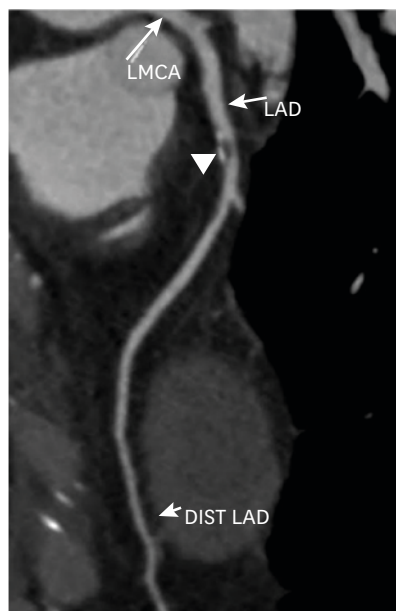


Figure 4. Coronary Artery Disease Reporting and Data System 3 in a 72-year-old woman with atypical chest pain. Curved multiplanar reformatted computed tomography angiographic image of LAD shows a partially calcified plaque (white arrowhead) in the proximal part causing moderate stenosis (50%–69%). Functional assessment was recommended. Myocardial perfusion scintigraphy (not shown) showed a stress perfusion defect in the mid anterior and anteroseptal segments, which is consistent with ischemia. DIST: distal, LAD: left anterior descending, LMCA: left main coronary artery.

MODIFIERS

CAD-RADS classification is supplemented by four modifiers that provide additional information on non-diagnostic image quality (N), stents (S), bypass grafts (G) and lesion vulnerability (V).

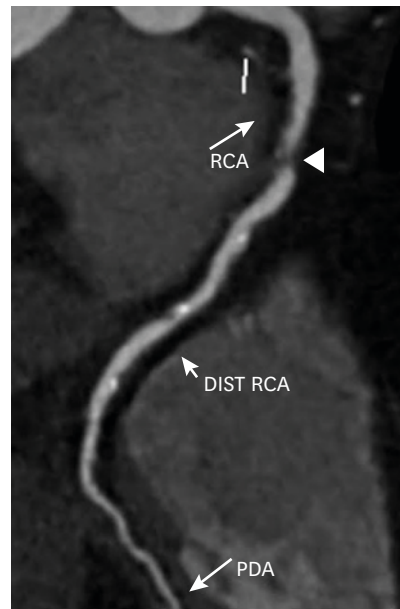


Figure 5. Coronary Artery Disease Reporting and Data System 4A in a 56-year-old woman who presented with chest pain on exertion and abnormal electrocardiogram results. Curved multiplanar reformatted computed tomography angiographic image shows a predominantly noncalcified plaque (white arrowhead) in the mid RCA causing severe luminal stenosis (70%–99%). No other significant coronary artery disease was detected. ICA was recommended. ICA results (not shown) showed severe stenosis in the RCA artery, which was treated with balloon angioplasty and stent placement.

DIST: distal, ICA: invasive coronary angiography, PDA: posterior descending artery, RCA: right coronary artery.

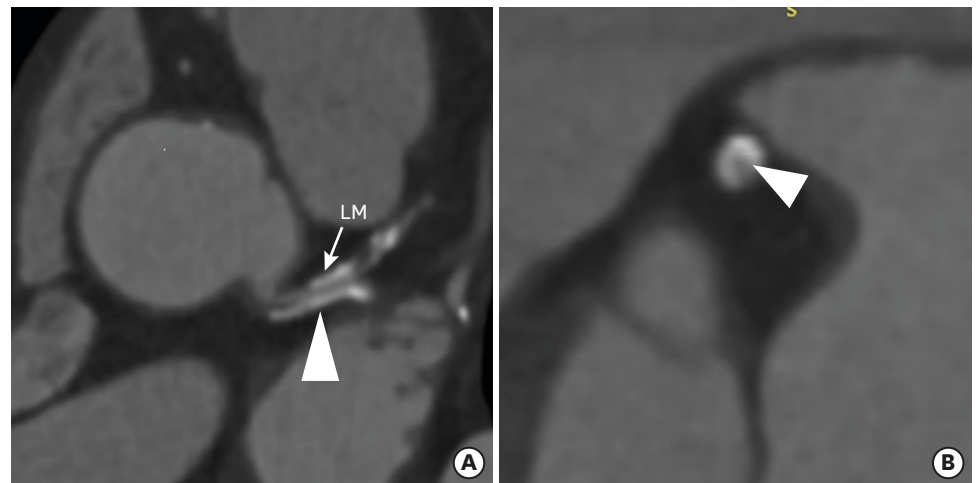


Figure 6. Coronary Artery Disease Reporting and Data System 4B in a 65-year-old man who presented with shortness of breath and chest pain. (A) Curved multiplanar reformatted computed tomography angiographic image and (B) the corresponding axial reformatted image of the LM artery shows circumferential calcified plaque (white arrowheads) causing >50% stenosis. Moderate stenosis was seen in right coronary artery and mild stenosis was seen in the left anterior descending and left circumflex (not shown). Invasive coronary angiography was recommended which revealed triple vessel disease. The patient was considered for coronary artery bypass grafting.

LM: left main coronary artery.

Modifier N

When there is a nonevaluable segment in the study with >50% stenosis in another interpretable segment, the CAD-RADS category is assigned based on the highest grade of stenosis along with the modifier N. Modifier N indicates the presence of a nonevaluable segment. For example, a patient with a non-interpretable segment in the mid right coronary

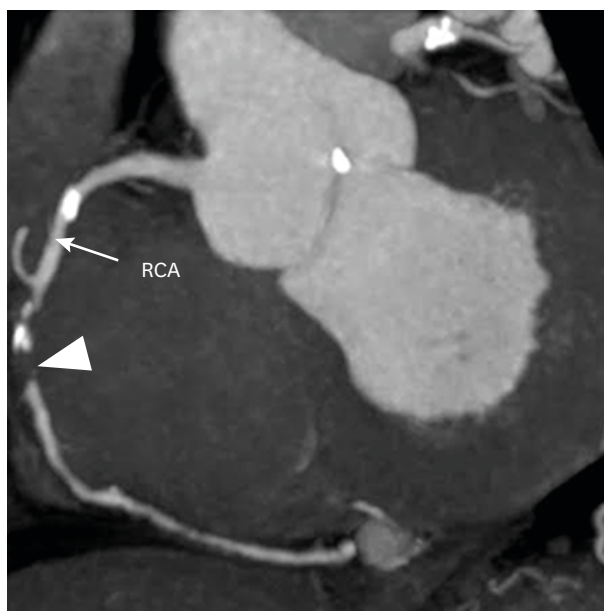


Figure 7. Coronary Artery Disease Reporting and Data System 5 in a 59-year-old man who presented with acute chest pain. Maximum intensity projection computed tomography angiographic image of the RCA shows total occlusion in the mid part (white arrowhead). Invasive coronary angiography findings (not shown) confirmed occlusion of the RCA artery.
RCA: right coronary artery.

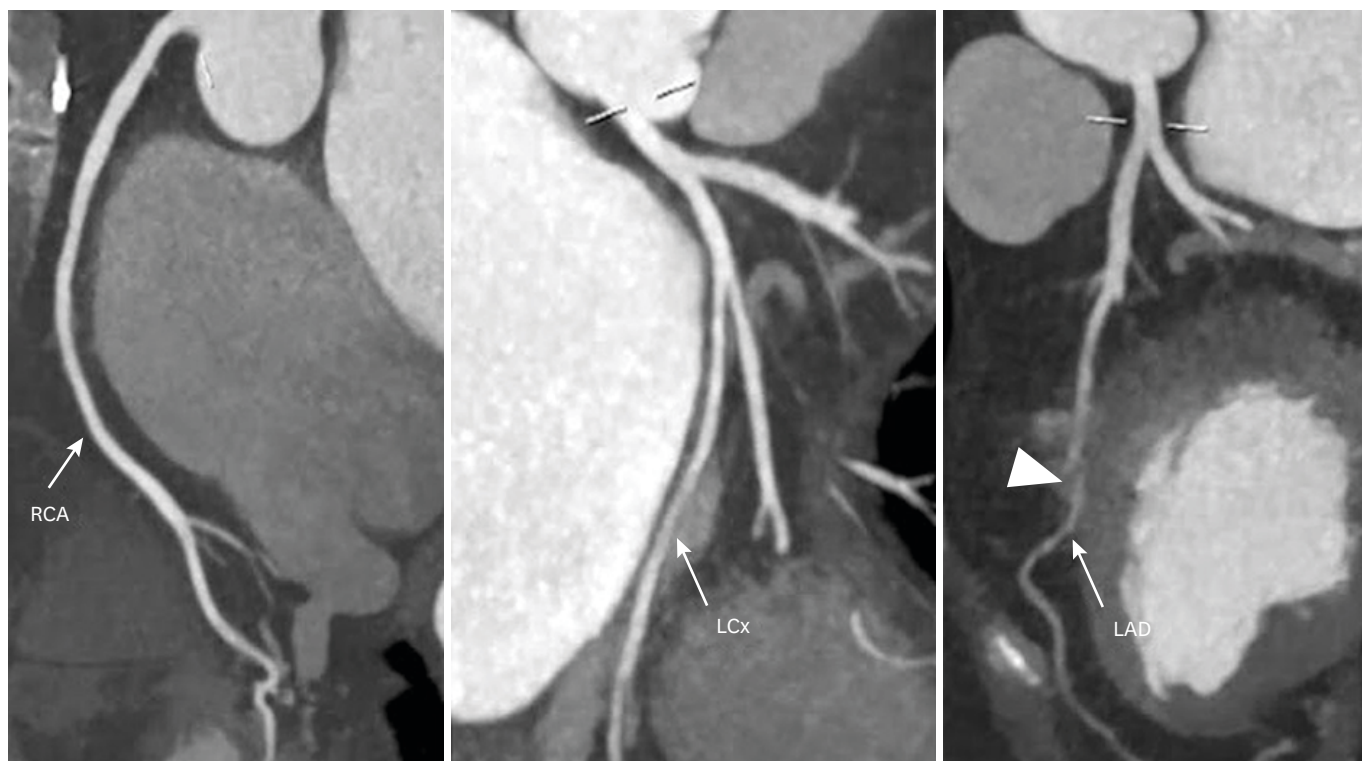


Figure 8. Coronary Artery Disease Reporting and Data System N in a 40-year-old woman who presented with chronic chest pain. Curved maximum intensity projection computed tomography angiographic image of coronary arteries shows no atherosclerotic disease in the RCA, LCx, and proximal LAD. The mid LAD could not be evaluated because of a motion artifact (white arrowhead). Additional or alternative evaluation was recommended.
LAD: left anterior descending, LCx: left circumflex, RCA: right coronary artery.

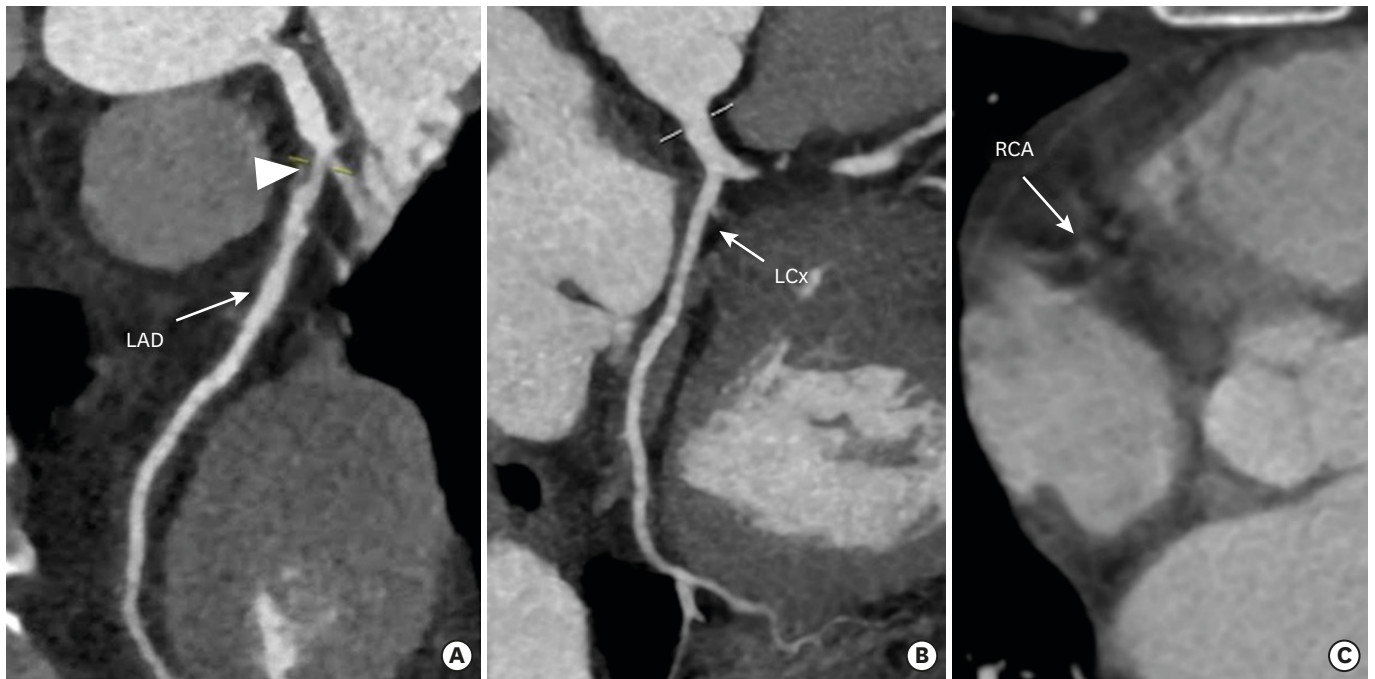


Figure 9. Modifier N in a 56-year-old man with chest pain. (A) Curved MPR CT angiographic image of the LAD shows a non-calcified plaque (white arrowhead) causing moderate stenosis (50%–69%) in the proximal part. (B) Curved MPR CT angiographic image of LCx shows no atherosclerotic disease. (C) Axial reformatted CT angiographic image of RCA shows a non-evaluable segment in the mid part because of motion artifacts. The patient was assigned Coronary Artery Disease Reporting and Data System 3/N category. ICA was recommended. The patient underwent ICA (not shown), which confirmed moderate stenosis (70%) in the mid RCA.

CT: computed tomography, ICA: invasive coronary angiography, LAD: left anterior descending, LCx: left circumflex, MPR: multiplanar reformatted, RCA: right coronary artery.

artery (RCA) and moderate stenosis in the left anterior descending (LAD) artery will be assigned CAD-RADS category 3 with a modifier N (CAD-RADS 3/N) (**Figure 9**). This is different from CAD-RADS N because the patient already has >50% stenosis, and further workup is needed to treat it. The nonevaluable segment does not change the need for invasive angiography. Hence, the modifier N is used instead of the category N.

Modifier S

Modifier S indicates the presence of a stent in any of the coronary arteries. Stents greater than 3 mm are evaluable in CAD-RADS. The grading of in-stent restenosis is done in a manner similar to the coronary arteries. For example, if there is moderate in-stent restenosis with minimal disease in rest of the coronary arteries, the case would be classified as CAD-RADS3/S (**Figure 10**). Similarly, if the patient has a patent stent in the LAD with no in-stent restenosis and a severe obstructive lesion in the RCA, the case would be classified as CAD-RADS 4A/S (**Figure 11**). Likewise, if a patent stent is seen in the LAD with normal left circumflex (LCx) and a non-evaluable segment in the RCA, the case would be classified as CAD-RADS N/S (**Figure 12**).

Modifier G

Modifier G indicates the presence of a CABG (**Figure 13**). The grading of a graft stenosis is similar to that of coronary arteries. A stenotic segment bypassed by graft is not taken into consideration. For example, if a patient has patent left internal mammary artery (LIMA) to LAD graft with total occlusion of proximal LAD and minimal disease in another graft, the case would be classified as CAD-RADS 1/G and not CAD-RADS 5/G (**Figure 14**). Similarly, if

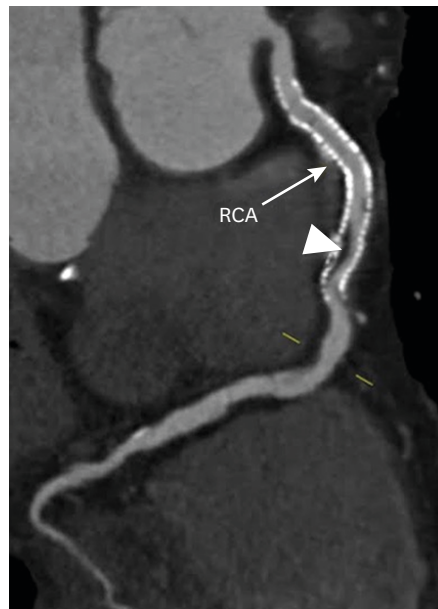


Figure 10. Modifier S (stent) in a 59-year-old woman with new-onset chest pain who had a history of inferior myocardial infarction and stent placement in the RCA. Curved multiplanar reformatted computed tomography angiographic image of the RCA shows a long stent in situ with moderate in-stent restenosis (50%–69%) (white arrowhead). Minimal disease was seen in the left anterior descending and left circumflex arteries (not shown). The patient was assigned Coronary Artery Disease Reporting and Data System 3/S category. Functional assessment was recommended. RCA: right coronary artery.

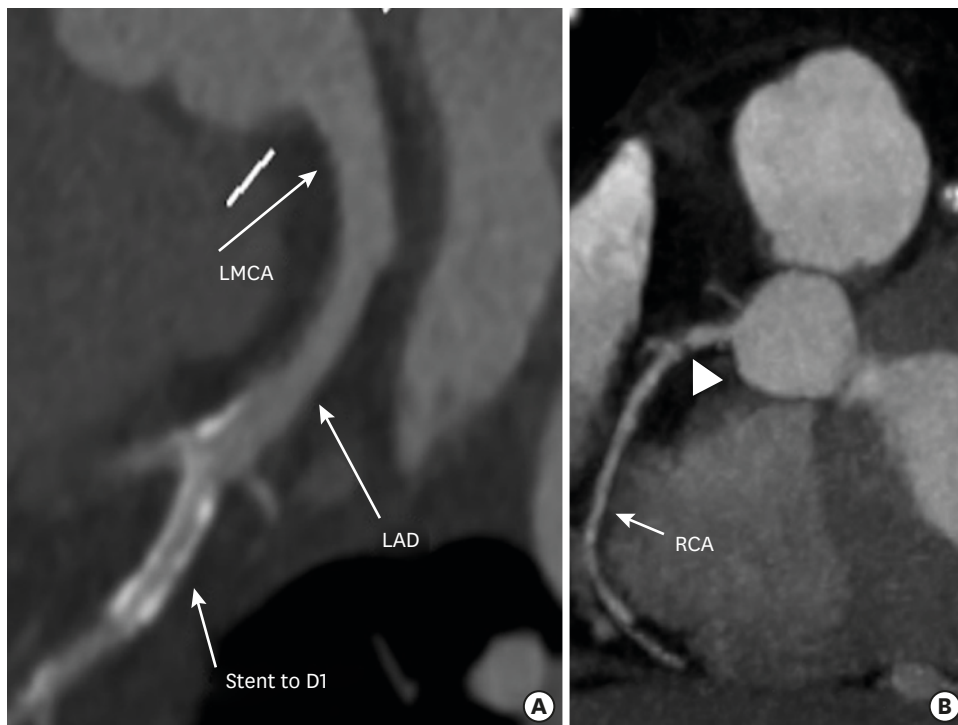


Figure 11. Coronary Artery Disease Reporting and Data System 4A/S in a 75-year-old man with new onset chest pain and a history of myocardial infarction and stent placement in D1 branch. (A) Curved MPR CT angiographic image of the LAD shows a patent stent in D1. No evidence of in-stent restenosis was seen. (B) Curved MPR CT angiographic image of the RCA shows a non-calcified plaque causing severe stenosis (70%–99%) in the proximal part (white arrowhead). ICA was recommended. ICA results (not shown) showed severe stenosis in the RCA artery, which was treated with balloon angioplasty and stent placement. CT: computed tomography, D1: 1st diagonal, ICA: invasive coronary angiography, LAD: left anterior descending, LMCA: left main coronary artery, MPR: multiplanar reformatted, RCA: right coronary artery.

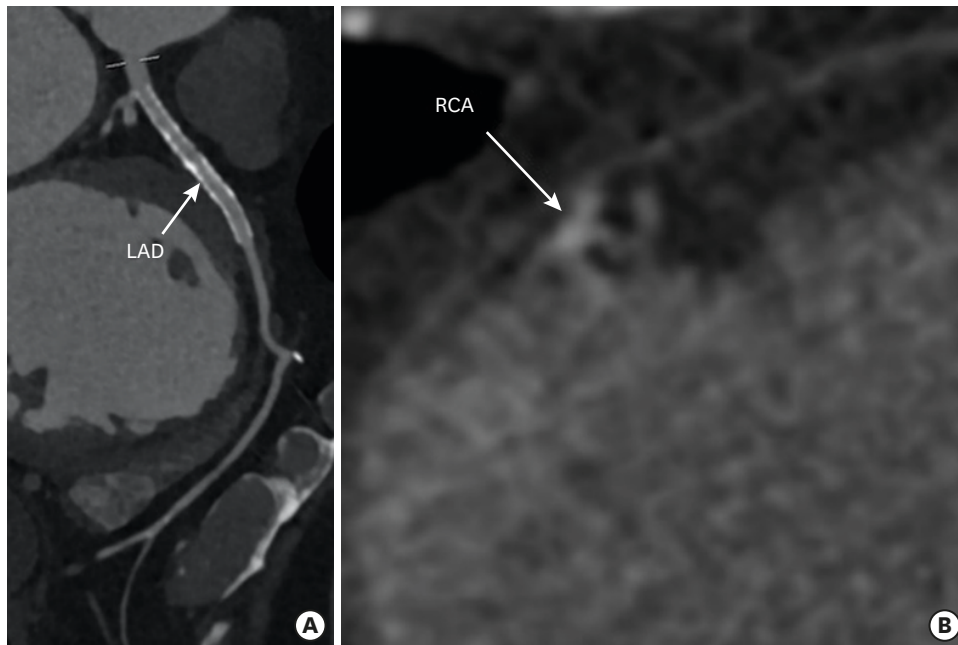


Figure 12. Coronary Artery Disease Reporting and Data System N/S in a 69-year-old woman with new onset chest pain and a history of myocardial infarction and stent placement in the LAD (A) Curved multiplanar reformatted CT angiographic image of the LAD shows a long patent stent in situ. No evidence of in stent stenosis seen. (B) Axial reformatted CT angiographic image of the RCA shows a non-evaluable segment in the mid part because of motion artifacts (white arrow). Left circumflex was normal. Invasive coronary angiography was recommended and revealed mild stenosis in the mid RCA (not shown). CT: computed tomography, LAD: left anterior descending, RCA: right coronary artery.

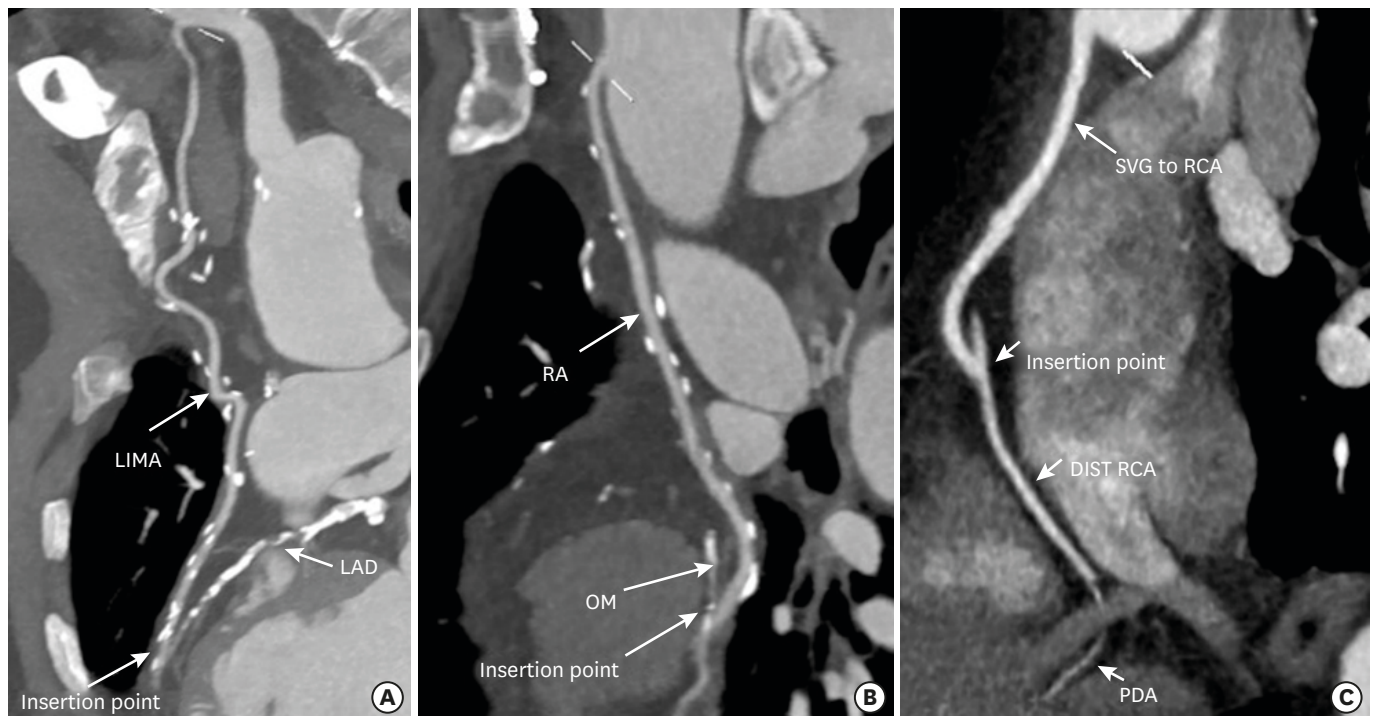


Figure 13. Modifier G in an 82-year-old woman with a history of three-vessel coronary bypass graft surgery who underwent coronary CT angiography to evaluate the patency of the grafts. Curved multiplanar reformatted CT angiographic images shows patent LIMA graft to the LAD (A), patent RA graft from the ascending aorta to OM artery (B), and patent right SVG from the ascending aorta to distal RCA (C). All of the bypass grafts are patent. The patient was assigned CAD-RADS O/G category. CT: computed tomography, DIST: distal, LAD: left anterior descending, LIMA: left internal mammary, OM: obtuse marginal, PDA: posterior descending artery, RA: radial artery, RCA: right coronary artery, SVG: saphenous vein graft.

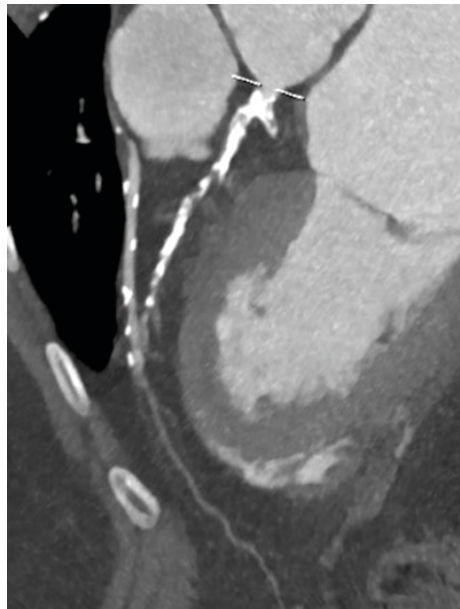


Figure 14. Modifier G in a 78-year-old man with a history of three-vessel coronary bypass graft surgery who underwent coronary CT angiography to evaluate the patency of the grafts. Curved multiplanar reformatted CT angiographic images shows patent left internal mammary to the LAD. Extensive calcifications with severe luminal stenosis is seen in the LAD proximal to the site of graft insertion. The rest of the 2 grafts (not shown) were also patent with minimum disease in one of them. The patient was assigned CAD-RADS 1/G category. The stenotic segment bypassed by graft is not taken into consideration for CAD-RADS classification. CAD-RADS: Coronary Artery Disease Reporting and Data System, CT: computed tomography, LAD: left anterior descending.

there is total occlusion of saphenous venous graft to the RCA with patent LIMA to LAD graft, and minimal to mild disease in rest of the coronaries, the case would be classified as CAD-RADS 5/G (**Figure 15**).

Modifier V

Modifier V indicates the presence of high-risk plaque features or a vulnerable plaque. Various studies have described four important vulnerable plaque features, which include positive remodeling, low-attenuation centre (<30 Hounsfield unit), spotty calcification and napkin-ring sign¹³⁾¹⁴⁾ (**Figure 16**). If any plaque shows 2 or more high-risk features, it should be labelled as a vulnerable plaque and a modifier V should be added to the final CAD-RADS category (**Figures 17 and 18**). For example, if the LAD shows mild disease with features of vulnerable plaque, along with minimal disease in RCA, the case should be classified as CAD-RADS 2/V.

If there are more than one modifier, the modifiers should be arranged in the following order: N, S, G, and V. For example, if there are patent stent and grafts with a non-diagnostic segment in one coronary artery, the case should be classified as CAD-RADS N/S/G. Similarly, if there is patent stent in RCA, patent LIMA to LAD graft and mild disease in LCx, the case should be categorised as CAD-RADS 2/S/G.

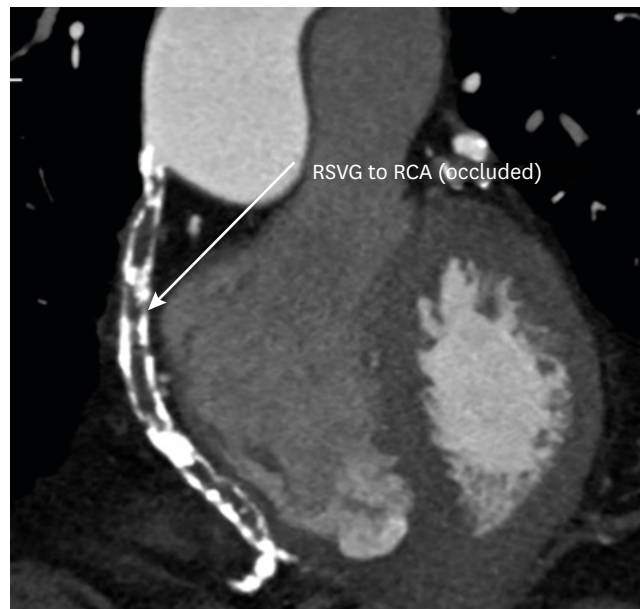

Figure 15. CAD-RADS 5/G in a 86-year-old man with a history of three-vessel coronary bypass graft surgery who underwent coronary CT angiography to evaluate the patency of the grafts. Curved multiplanar reformatted CT angiographic image shows a RSVG from the ascending aorta to distal RCA. There is dense wall calcification with total luminal occlusion of the graft. All other bypass grafts were patent (not shown). The patient was assigned CAD-RADS 5/G category. Invasive coronary angiography was recommended. CAD-RADS: Coronary Artery Disease Reporting and Data System, CT: computed tomography, RCA: right coronary artery, RSVG: reversed saphenous vein graft.

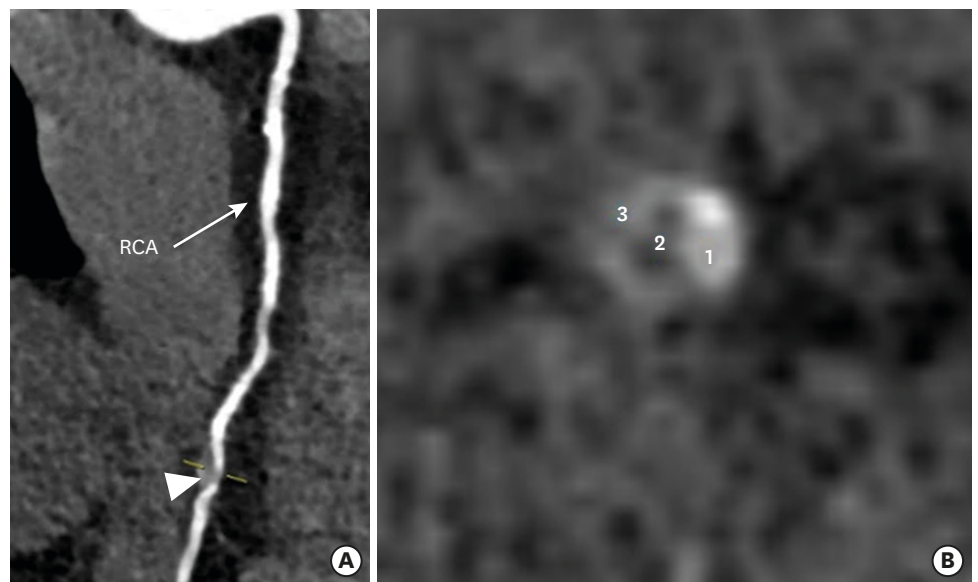


Figure 16. Modifier V in a 61-year-old man with chest pain. (A) Curved multiplanar reformatted CT angiographic image of RCA shows a noncalcified plaque (white arrowhead) in the distal part. The plaque shows positive remodeling and is causing moderate stenosis (50%–69%). (B) Corresponding axial reformatted CT angiographic image perpendicular to the vessel lumen (1, CT number = 380 HU) shows central low-attenuation core (2, CT number = 24 HU) and outer circumferential high-attenuation area (3, CT number = 98 HU) representing napkin-ring sign. The patient was assigned CAD-RADS: Coronary Artery Disease Reporting and Data System 3/V category. CT: computed tomography, HU: hounsfield unit, RCA: right coronary artery.

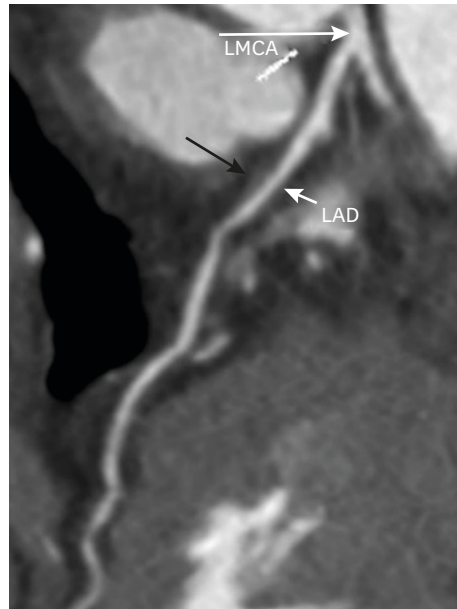


Figure 17. CAD-RADS 2 in a 48-year-old man with chest pain. Curved multiplanar reformatted computed tomography angiographic image shows noncalcified plaque (black arrow) in the proximal-LAD. It shows positive remodelling and is causing mild stenosis (25%-49%). Right coronary artery and left circumflex were normal. The patient was assigned CAD-RADS 2 category. Only one high-risk feature was present, so modifier V was not included. No further imaging was recommended.

CAD-RADS: Coronary Artery Disease Reporting and Data System, LAD: left anterior descending, LMCA: left internal mammary.

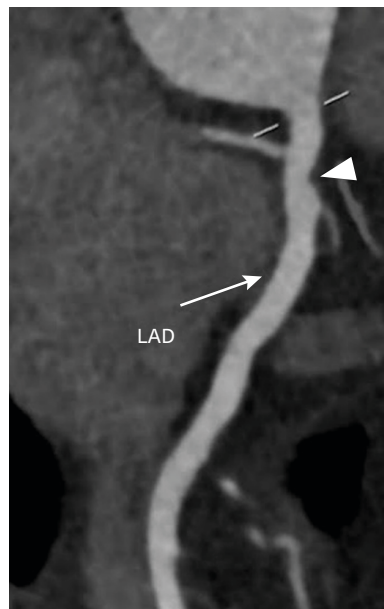


Figure 18. CAD-RADS 1 in a 45-year-old man with chest pain. Curved multiplanar reformatted computed tomography angiographic image shows noncalcified plaque (white arrowhead) causing minimal stenosis (<25%) in the proximal-LAD. The average attenuation of lesion was 7 Hounsfield unit. Right coronary artery and left circumflex were normal. The patient was assigned CAD-RADS 1 category. Only one high-risk feature was present, so modifier V was not included. No further imaging was recommended.

CAD-RADS: Coronary Artery Disease Reporting and Data System, LAD: left anterior descending.

TREATMENT RECOMMENDATIONS

CAD-RADS categories provide patient-specific treatment recommendations for both stable and acute chest pain. Patients with stable chest pain and CAD-RADS categories 0, 1, and 2 do not need additional imaging, and alternate nonatherosclerotic causes of chest pain should be considered. Preventive therapy and risk factor modification are recommended for CAD-RADS categories 1–5. Anti-ischemic therapy is suggested for CAD-RADS categories 3–5. Revascularization is advocated for CAD-RADS categories 4 and 5.

In patients with acute chest pain and CAD-RADS categories 0, 1, and 2, other non-coronary causes of chest pain should be considered. Hospital admission may be considered for CAD-RADS 2 category if the clinical suspicion is very high. Patients with CAD-RADS categories 3–5 need hospital admission. Revascularization is considered appropriate for CAD-RADS category 4A and 4B and should be expedited for CAD-RADS category 5. Unlike the guidelines for stable chest pain, lifestyle modifications and preventive therapy are not recommended in CAD-RADS guidelines for acute chest pain. A detailed classification summary of the categories, modifiers, interpretation and management suggestions is given in **Table 1**.¹⁰⁾

STRENGTHS

CAD-RADS allows uniform and consistent evaluation of stenosis, effective communication, management recommendations, and risk prognostication. The standardized reporting system is also a valuable tool for extensive data collection, paving the path for better education and research. The various strengths of this new system are summarized below.

Uniformity and consistency

There is high variability in the reporting of CCTA among radiologists, cardiologists, trainees and fellows. CAD-RADS provides a uniform and structured reporting pattern with assignment of a single, per-patient severity score. The use of commonly accepted terminologies and CAD-RADS categories are helpful in establishing consistency in the reports. A study by Abdel Razek et al.¹⁵⁾ showed good inter-observer agreement of CAD-RADS in categorising the degree of stenosis and identification of modifiers. The percent agreement between 2 reviewers was found to be 100% for CAD-RADS 0, 97.9%, for CAD RADS 1, 93.8% for CAD-RADS 2, 94.8% for CAD-RADS 3, 94.8% for CAD-RADS 4, and 95.8%. for CAD-RADS 5. A good inter-observer agreement was also seen among various modifiers.¹⁵⁾ Another study done by Maroules et al.¹⁶⁾ also showed excellent inter-observer agreement for CAD-RADS assessment categories among expert readers and early career readers. There was an excellent inter-observer agreement for modifiers S and G (both $\kappa=1.0$) and fair agreement ($\kappa=0.40$) for modifier V (high-risk plaque).¹⁶⁾ The results of both of these studies suggest that CAD-RADS is feasible for clinical implementation and can provide uniform and consistent reports.

Communication

CAD-RADS allows better communication between referring and reporting physicians. The assignment of a particular CAD-RAD category provides more clarification than lengthy and non-conclusive reports. The concise report is helpful in streamlining referrals for non-specialists. For a specialist, the rapid conveying of significant finding using a CAD-RADS category is a time saver and helps in making quick management decisions.

CAD-RADS

Table 1. CAD-RADS classification of patients presenting with acute and stable chest pain

Maximum stenosis	CAD-RADS	Stable chest pain			Acute chest pain		
		Interpretation	Workup	Management	Interpretation	Workup	Management
0	0	No CAD	None	-Reassurance -Consider other etiologies	None	ACS highly unlikely	-No further evaluation of ACS is required. -Consider other etiologies
1%-24%	1	Minimal	None	-Consider other etiologies -Consider preventive therapy and risk factor modification	None	ACS highly unlikely	-If troponin and ECG are normal then evaluate for non-ACS etiology -Consider referral for outpatient follow up for risk factor modification and preventive therapy
25%-49%	2	Mild	None	-Consider non-atherosclerotic causes of chest pain -Consider preventive therapy and risk factor modification, particularly for patients with nonobstructive plaque in multiple segments	None	ACS unlikely	-If troponin and ECG are normal then evaluate for non-ACS etiology -Consider referral for outpatient follow up for risk factor modification and preventive therapy -Consider hospital admission with cardiology consultation if there are high-risk plaque features
50%-69%	3	Moderate	Consider functional assessment	-Consider symptom-guided anti-ischemic and preventive pharmacotherapy -Risk factor modification and treatment as per guideline-directed care	Consider functional assessment	ACS possible	-Consider hospital admission with cardiology consultation, functional testing and/or ICA for evaluation and management -Recommendation for anti-ischemic and preventive management should be considered as well as risk factor modification
A. 70%-99% B. LM >50% or 3 vessel disease (70%-99%)	4	Severe	A. Consider ICA or functional assessment. B. ICA is recommended	-Consider symptom-guided anti-ischemic and preventive pharmacotherapy -Risk factor modification and other treatments (including options of revascularization) per guideline-directed care	A. Consider ICA or functional assessment. B. ICA is recommended	ACS likely	-Consider hospital admission with cardiology consultation -Further evaluation with ICA and revascularization as appropriate -Recommendation for anti-ischemic and preventive management should be considered as well as risk factor modification
100%	5	Total occlusion	Consider ICA or viability assessment	-Consider symptom-guided anti-ischemic and preventive pharmacotherapy -Risk factors modification and other treatments (including options of revascularization) as per guideline-directed care	Consider ICA or viability assessment	ACS very likely	-Consider expedited ICA on a timely basis and revascularization if appropriate if acute occlusion -Recommendation for anti-ischemic and preventive management should be considered as well as risk factor modifications
Non-diagnostic	N	CAD can't be excluded	Additional investigation may be needed	-Additional or alternative evaluation	Additional investigation may be needed	ACS can't be excluded	-Additional or alternative evaluation for ACS is needed

CAD-RADS classification is presented as 4 modifiers: 1st, non-diagnostic (modifier N)—the modifier “N” used if the study is not fully diagnostic (i.e., not all segments >1.5 mm diameter can be interpreted with confidence) and >50% stenosis is present in a diagnostic segment; 2nd, stent (modifier S)—the modifier “S” indicates the presence of coronary artery stent. The grading of in stent restenosis is done similar to native coronary arteries; 3rd: graft (modifier G)—The modifier “G” indicates the presence of at least one coronary artery bypass graft. A stenosis of native artery bypassed by graft is not considered for the CAD-RADS categorisation; 4th: vulnerability (modifier V)—the modifier “V” is used if any plaque shows 2 or more high-risk features (positive remodeling, low-attenuation plaque, spotty calcification, and the napkin-ring sign).

ACS: acute coronary syndrome, CAD: coronary artery disease, CAD-RADS: Coronary Artery Disease Reporting and Data System, ICA: invasive coronary angiography, LM: left main.

Clinical decision and treatment recommendation

CAD-RADS provides category-specific treatment recommendations for both acute and chronic chest pain. The treatment recommendations are helpful in making quick management decisions, especially in acute settings. The incorporation of CAD-RADS can reduce the number of unnecessary invasive coronary angiographies (ICAs), reducing the cost and length of hospital stay. Basha et al conducted a prospective study to estimate the diagnostic validity, reproducibility and applicability of CAD-RADS for predicting high-risk patients and to assess the value of CAD-RADS for decision-making in clinical settings. The overall results were encouraging and CAD-RADS showed excellent performance for categorization of CAD and predicting significant CAD. In terms of diagnostic validity, the CAD-RADS showed a very high sensitivity, specificity, and accuracy (100%, 96.8%–98.7%, and 98.3%–99.3%, respectively) using ICA as the gold standard.¹⁷⁾ The integration of CAD-RADS guided recommendations encourage further appropriate follow-up care for patients. This is particularly important in stable patients with intermediate lesions (CAD-RADS 3) in which early ICA is commonly performed before adequate trials of medical therapy.

Risk prognostication

Coronary artery calcium (CAC) scoring is currently used as a tool for cardiovascular risk assessment in asymptomatic subjects who are at intermediate risk according to clinical risk scores. A CAC score of 0 guarantees a very good long-term prognosis. The major limitation of the CAC score is the lack of data for the downstream testing, management, and screening strategy for patients with a CAC score of more than 1. CCTA has the ability to detect the coronary plaque location, severity and plaque characterization. Several studies have demonstrated the prognostic power of CCTA in high-risk patients.¹⁸⁻²⁰⁾ The use of CAD-RADS further adds value to CCTA by standardizing the classification of CAD severity and incorporating management recommendations. A recent study examined the long-term prognostic value of CAD-RADS scores to predict the death or myocardial infarctions in patients from the COronary CT Angiography EvaluationN For Clinical Outcomes: An InteRnational Multicenter registry. The authors compared the predictive power of CAD-RADS to the Duke index and traditional method of characterizing CAD extent/severity. The predictive value of CAD-RADS was found to be similar to both the Duke and traditional methods, suggesting that CAD-RADS can be used as prognosis predictor in a high-risk asymptomatic CAD population.²¹⁾ Another study done by Nam et al investigated the prognostic value and additional risk stratification benefits of CAD-RADS compared with CACS and CAD extent classifications in ischemic stroke patients without cardiac symptoms. The study showed that CAD-RADS provides prognostic value for future major adverse cardiovascular events and better risk discrimination compared with CAC score alone.²²⁾ Another recent report by Bittner et al.²³⁾ in 3,840 eligible patients included in the PROMISE trial demonstrated that the CAD-RADS has significantly higher discriminatory value than traditional stenosis-based assessment for predicting cardiac events in 2 years. In addition, a stepwise increase in the event rate was seen with stepwise increment in the CAD-RADS category.²³⁾ These findings indicate that the additive prognostic value of CAD-RADS scoring system is above and beyond the traditional methods.

Education and research

CAD-RADS makes the process of data collection very easy. The consistency in the CCTA reporting allows the creation of a large data pool from different institutions. The structured and uniform results allow effective communication of data to digital systems, which ultimately helps in developing advanced artificial intelligence algorithms. Muscogiuri et

al.²⁴) developed a deep convolutional neural network (CNN) to classify the CCTA findings in the correct CAD-RADS categories. The authors analysed the diagnostic accuracy of the 3 models: model A (CAD-RADS 0 vs. CAD-RADS 1–2 vs. CAD-RADS 3–5), model 1 (CAD-RADS 0 vs. CAD-RADS >0), and model 2 (CAD-RADS 0–2 vs. CAD-RADS 3–5). Deep CNN yielded accurate automated classification of patients in different CAD-RADS categories. Moreover, the time of analysis was significantly lower using CNN compared with on-site reading.²⁴ Besides paving the path for artificial intelligence, the availability of meaningful data is also helpful in the training of residents and fellows. Hence, CAD-RADS is an invaluable tool in providing opportunities for education and research also.

LIMITATIONS

The assignment of the appropriate CAD-RADS category depends upon the accurate quantification of luminal stenosis on CCTA. Although CCTA is a robust modality for the evaluation of coronary arteries, it frequently falls short in assessing the precise degree of coronary artery stenosis. One such example is the presence of densely calcified plaque. The blooming artifact of densely calcified plaques often results in overestimation of luminal stenosis and hence assignment of a higher category. Likewise, the spatial resolution of CCTA does not allow differentiation between near total (near 99%) and total occlusion (100%) of coronary arteries. In addition to these technique-dependent limitations, CAD-RADS has several missing components. It does not provide information about stent-related complications, plaque burden, coronary anomalies, hemodynamic significance of stenosis, non-atherosclerotic causes of CAD, and important incidentally detected extracardiac findings. These limitations of this new system are discussed below.

Stent-related complications

Stent-related complications like stent fracture and overlapping occurs in 0.8%–8% of patients and are frequently detected on CCTA rather than ICA.²⁵ Similarly, endoleak may occur from the stent implanted in coronary artery aneurysm. Computed tomography (CT) angiography can accurately identify these entities, but the stent evaluation in CAD-RADS is limited to in stent restenosis only (**Figures 19** and **20**). The final CAD-RADS score therefore may miss important information.

Plaque burden and plaque characterization

The CAD-RADS category is assigned based on the highest grade of stenosis. The estimation of plaque volume and plaque characterization are not taken into consideration. For example, a partially calcified plaque with moderate stenosis in the proximal LAD and diffuse calcific disease with moderate stenosis in the LAD are assigned the same CAD-RADS category. Similarly, the diffuse mild disease in two coronaries with moderate disease in one coronary, and no disease in two coronaries with moderate disease in one coronary will fall in the same CAD-RADS category. In both of these examples, despite the different plaque burdens (higher in one and lower in another), the subjects will be assigned the same CAD-RADS category. Previous studies showed that the total plaque volume is a predictor of acute coronary syndrome.²⁶ Therefore, by assigning the same category to both the cases, CAD-RADS fails to segregate the low- and high-risk patients. Another important component of atherosclerosis is the plaque characterization. Studies have shown that non-calcific plaque burden is more commonly associated with perfusion defects. However, the current scheme of CAD-RADS classification will assign a similar category to the same degree of stenosis caused by calcified or non-calcified plaques.²⁷

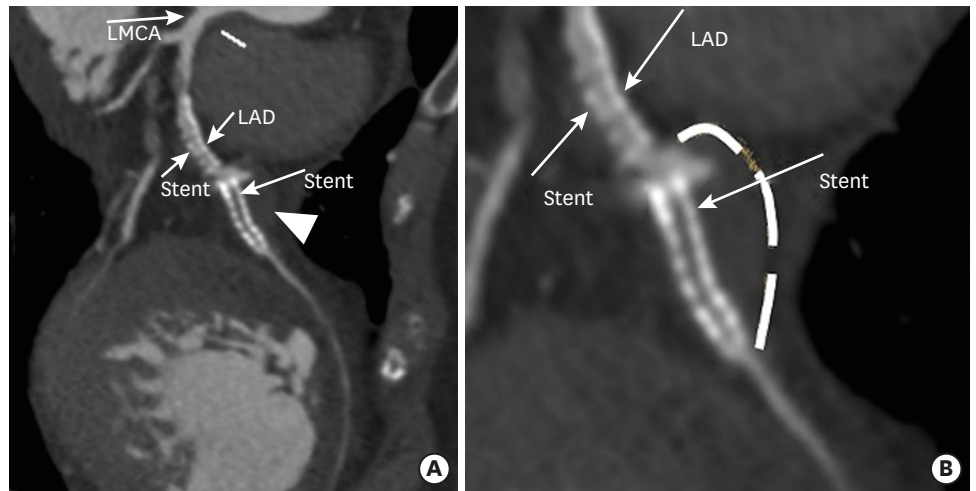


Figure 19. CAD-RADS 5/S in a 54-year-old woman. (A) Curved multiplanar reformatted computed tomography angiographic image of the LAD and (B) corresponding magnified image show a coronary artery stent in the proximal LAD with a complete gap and angulation of the stent due to fracture. The distal part of stent shows total luminal occlusion. A persistent hematoma is formed around the site of fracture (white arrowhead and dashed white line). The CAD-RADS 5/S suggests total luminal occlusion but conveys information about stent fracture. CAD-RADS: Coronary Artery Disease Reporting and Data System, LAD: left anterior descending, LMCA: left internal mammary.

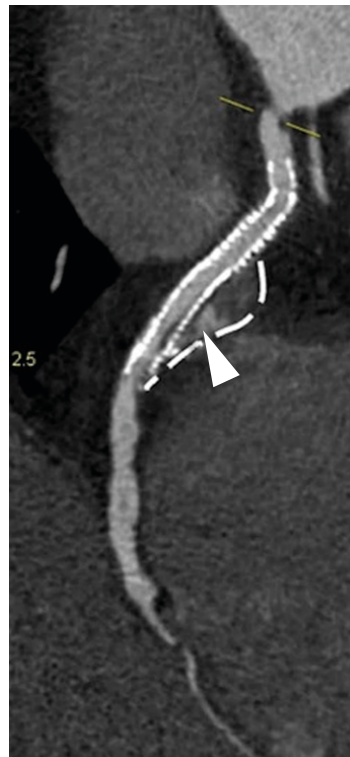


Figure 20. CAD-RADS 2/S in a 54-year-old man with a history of stent implantation in RCA aneurysm. Curved multiplanar reformatted computed tomography angiographic image of the RCA shows a long stent in the proximal and mid part. Mild stenosis is seen at the ostium of RCA and minimal stenosis is seen in distal part of the stent. There is evidence of endoleak (white arrowhead) into the aneurysmal sac (dashed white line). The CAD-RADS 2/S suggests mild luminal occlusion but conveys information about stent endoleak. CAD-RADS: Coronary Artery Disease Reporting and Data System, RCA: right coronary artery.

Hemodynamic significance of stenosis

The significant stenosis on CCTA does not necessarily mean the culprit lesion for myocardial ischemia. Various factors, including location and severity of stenosis, microvascular status and viability of myocardial bed, will determine future events, like myocardial infarction. Therefore, it is important to determine the hemodynamic significance of the lesion to guide patient treatment. Various modalities are available including exercise electrocardiography, stress echocardiography, stress scintigraphy, stress magnetic resonance imaging, and invasive fractional flow reserve (FFR).²⁸⁾ CT is also useful for this purpose, and various CT techniques like CT perfusion, CT-derived FFR, and transluminal attenuation gradient imaging can analyse the hemodynamic significance of stenosis.²⁹⁾³⁰⁾ The CAD-RADS classification does not address this key component and hemodynamic significance of stenosis is not taken into account in assigning the specific category (**Figure 21**). This may misguide the treating physician, especially non-specialists or general physicians.

Congenital coronary anomalies

The prevalence of congenital coronary anomalies varies from 1%–1.7%.³¹⁾ The clinical presentation of coronary artery anomalies may vary from asymptomatic to sudden cardiac death.³²⁾ CCTA is an excellent modality to demonstrate the origin, course, termination and relationships of coronary arteries to surrounding structures.³³⁾ Few anomalous patterns like malignant and intramural course put the individual at high-risk of myocardial infarction (**Figure 22**). There is no special modifier or category for coronary anomalies in the present CAD-RADS classification.

Non-atherosclerotic causes of CAD

Atherosclerosis is the leading cause of chest pain but some patients present with myocardial ischemia without any atherosclerotic disease. The common non-atherosclerotic causes of coronary artery narrowing include extrinsic compression (interarterial course, mass and

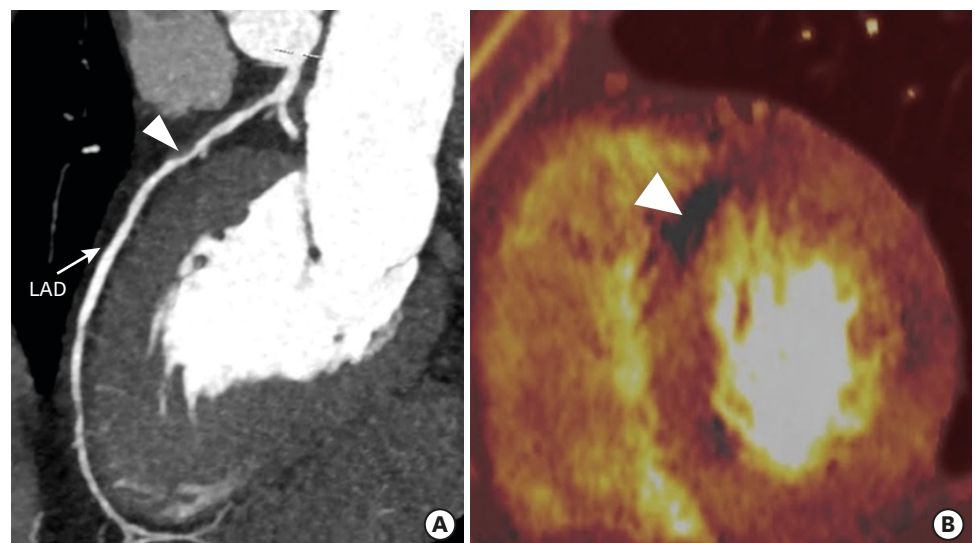


Figure 21. Coronary Artery Disease Reporting and Data System 3 in a 54-year-old man with a history of chest pain. (A) Curved multiplanar reformatted computed tomography angiographic image of the LAD shows a non-calcific plaque (white arrowhead) with external remodelling in the proximal part causing moderate stenosis. (B) Iodine map (rest) shows perfusion defects (white arrowhead) in the mid ventricular anteroseptal segment, suggesting hemodynamically significant stenosis. LAD: left anterior descending.

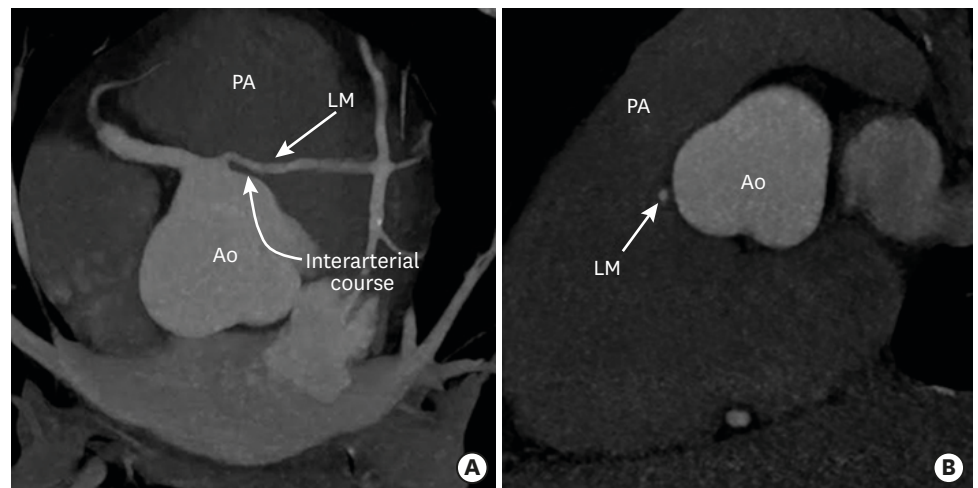


Figure 22. Coronary artery anomaly in a 47-year-old man with chest pain. (A) Axial and (B) sagittal oblique maximum intensity projection coronary computed tomography angiographic image in a 47-year-old man shows an anomalous origin of the LM from right coronary sinus. The proximal LM has an interarterial course between the ascending aorta and pulmonary trunk. No atherosclerotic disease was seen in coronary arteries. CAD-RADS does not apply to these findings, so the patient was assigned CAD-RADS category of 0.

Ao: aorta, CAD-RADS: Coronary Artery Disease Reporting and Data System, LM: left main, PA: pulmonary artery.

myocardial bridging), intrinsic disease (vasculitis, coronary artery dissection) and flow reduction (anomalous origin of left coronary artery from pulmonary artery, vasospasm and fistula) (Figure 23).³⁴⁾ CT angiography is an excellent modality to demonstrate the non-atherosclerotic causes of luminal narrowing. The CAD-RADS assessment is, however, limited to only atherosclerotic diseases of coronary arteries. Hence, critical and clinically important

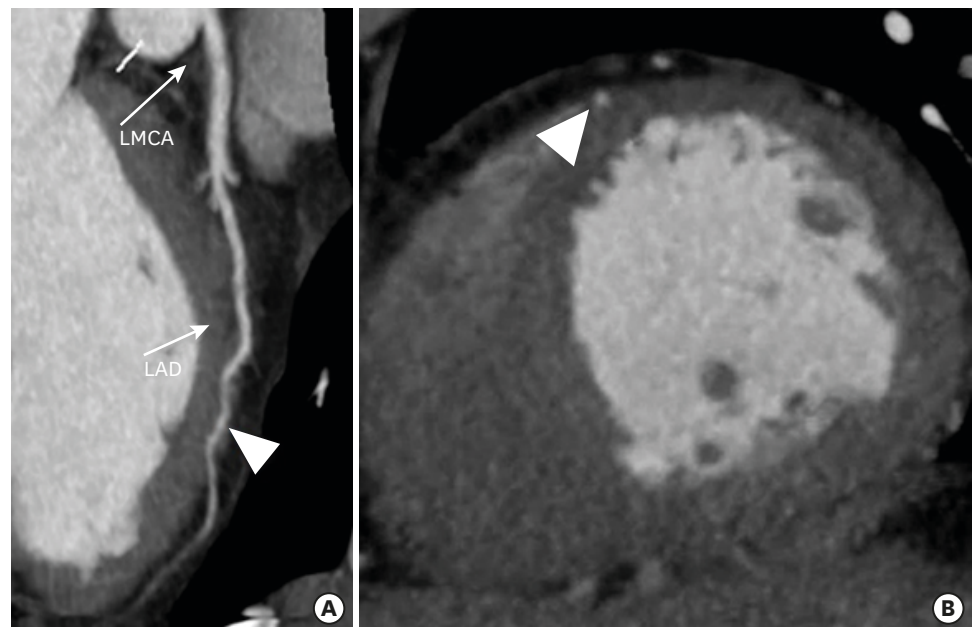


Figure 23. Coronary artery anomaly in a 49-year-old man with chest pain. (A) Sagittal and (B) short axis reformatted axial intensity projection coronary computed tomography angiographic image shows myocardial bridging of the distal LAD (white arrowheads). No atherosclerotic disease was seen in coronaries. CAD-RADS does not apply to these findings, so the patient was assigned CAD-RADS category of 0.

CAD-RADS: Coronary Artery Disease Reporting and Data System, LAD: left anterior descending, LMCA: left internal mammary.

findings like coronary artery dissection, coronary vasculitis and coronary artery fistula will be assigned to CAD-RADS 0 category, although such patients needs serious clinical attention.

Coronary artery and graft ectasia or aneurysm

Both coronary artery aneurysm and ectasia are defined as the dilatation of coronary arteries more than 1.5 times the normal diameter. While coronary artery aneurysm represents focal enlargement (<50% of vessel length), coronary ectasia represents the diffuse enlargement of the coronary artery (>50% of vessel length) (**Figure 24**).³⁵⁾³⁶⁾ The common causes of coronary artery aneurysm include atherosclerosis followed by congenital infections and Kawasaki disease. Atherosclerosis is also a risk factor for graft aneurysm (**Figure 25**). Similar to the above-mentioned limitations, the CAD-RADS classification does not consider coronary and graft vessel ectasia or aneurysm.

Incidental findings

A number of incidental findings are seen during CCTA, a few of which may have clinical significance and need urgent treatment. One study has shown that approximately 44% patients may have at least one incidental finding.³⁷⁾ Although these findings are mostly benign and are of little significance, like lung nodules, mediastinal lymph nodes and emphysema; sometimes clinically significant findings requiring urgent treatment like aortic dissection and pulmonary embolism may also be present. There is no place for incidentally detected cardiac and extracardiac findings in CAD-RADS classification.

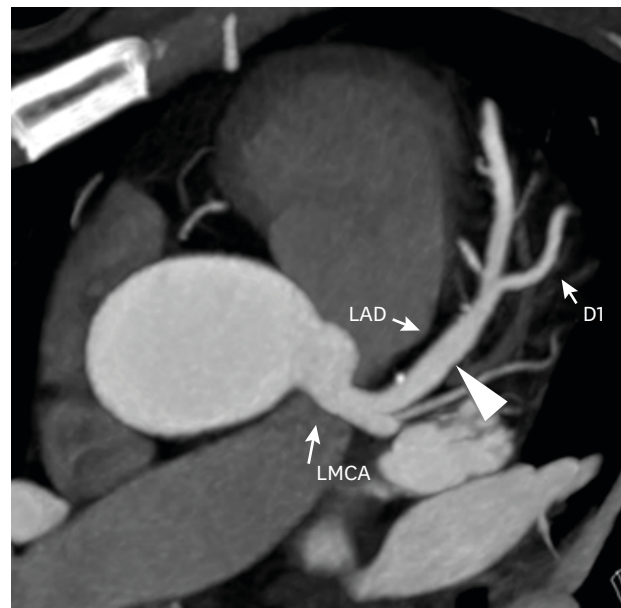


Figure 24. Coronary artery aneurysm in a 58-year-old man with chest pain. Curved multiplanar reformatted angiographic image of the LAD shows fusiform aneurysm (white arrowhead) of the proximal part with eccentric calcific plaques causing minimal stenosis. The patient was assigned Coronary Artery Disease Reporting and Data System 1. No further imaging was recommended.

D1: 1st diagonal, LAD: left anterior descending, LMCA: left internal mammary.

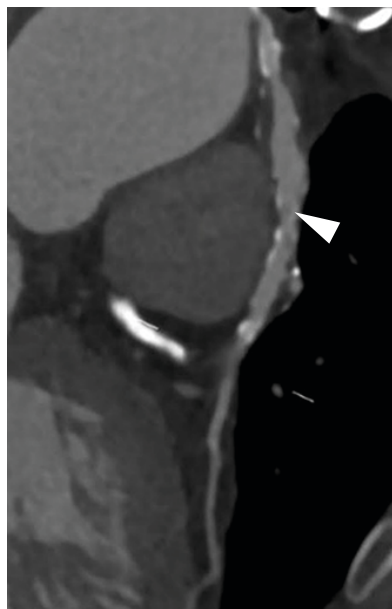

Figure 25. Graft aneurysm in a 78-year-old man with new onset chest pain and history of bypass grafting. Curved multiplanar reformatted angiographic image of the saphenous venous graft to obtuse marginal shows mild diffuse disease and graft aneurysm (white arrowhead). Right saphenous vein graft to right coronary artery and left internal mammary to left anterior descending were patent. The patient was assigned Coronary Artery Disease Reporting and Data System 2/G, and no further imaging was recommended.

CONCLUSION

CAD-RADS is a CTA-based classification system of coronary artery disease. It provides a standardized reporting format for consistent and uniform reporting. CAD-RADS aims to improve the communication with referring physicians and includes treatment suggestions. The standardized framework also provides improved communication between humans and computer-based system, paving a pathway for the development of artificial intelligence algorithms. Nevertheless, CAD-RADS still has many limitations, which may lead to misinterpretation, misclassification and misguidance for treatment and management. We believe that there is an opportunity for further improvement with the integration of functional assessment and addressing the limitations and shortcomings discussed.

REFERENCES

1. Leipsic J, Abbara S, Achenbach S, et al. SCCT guidelines for the interpretation and reporting of coronary CT angiography: a report of the Society of Cardiovascular Computed Tomography guidelines committee. *J Cardiovasc Comput Tomogr* 2014;8:342-58.
[PUBMED](#) | [CROSSREF](#)
2. Abbara S, Arbab-Zadeh A, Callister TQ, et al. SCCT guidelines for performance of coronary computed tomographic angiography: a report of the Society of Cardiovascular Computed Tomography guidelines committee. *J Cardiovasc Comput Tomogr* 2009;3:190-204.
[PUBMED](#) | [CROSSREF](#)
3. Halliburton SS, Abbara S, Chen MY, et al. SCCT guidelines on radiation dose and dose-optimization strategies in cardiovascular CT. *J Cardiovasc Comput Tomogr* 2011;5:198-224.
[PUBMED](#) | [CROSSREF](#)

4. Achenbach S, Delgado V, Hausleiter J, Schoenhagen P, Min JK, Leipsic JA. SCCT expert consensus document on computed tomography imaging before transcatheter aortic valve implantation (TAVI)/ transcatheter aortic valve replacement (TAVR). *J Cardiovasc Comput Tomogr* 2012;6:366-80.
[PUBMED](#) | [CROSSREF](#)
5. Taylor AJ, Cerqueira M, Hodgson JM, et al. ACCF/SCCT/ACR/AHA/ASE/ASNC/ NASCI/SCAI/SCMR 2010 appropriate use criteria for cardiac computed tomography. A report of the American College of Cardiology Foundation appropriate use criteria task force, the Society of Cardiovascular Computed Tomography, the American College of Radiology, the American Heart Association, the American Society of Echocardiography, the American Society of Nuclear Cardiology, the North American Society for Cardiovascular Imaging, the Society for Cardiovascular Angiography and Interventions, and the Society for Cardiovascular Magnetic Resonance. *J Cardiovasc Comput Tomogr* 2010;4:407.e1-407.e33.
[PUBMED](#) | [CROSSREF](#)
6. Goldstein JA, Chinnaiyan KM, Abidov A, et al. The CT-STAT (coronary computed tomographic angiography for systematic triage of acute chest pain patients to treatment) trial. *J Am Coll Cardiol* 2011;58:1414-22.
[PUBMED](#) | [CROSSREF](#)
7. Litt HI, Gatsonis C, Snyder B, et al. CT angiography for safe discharge of patients with possible acute coronary syndromes. *N Engl J Med* 2012;366:1393-1403.
[PUBMED](#) | [CROSSREF](#)
8. Hoffmann U, Truong QA, Schoenfeld DA, et al. Coronary CT angiography versus standard evaluation in acute chest pain. *N Engl J Med* 2012;367:299-308.
[PUBMED](#) | [CROSSREF](#)
9. Hamilton-Craig C, Fifoot A, Hansen M, et al. Diagnostic performance and cost of CT angiography versus stress ECG--a randomized prospective study of suspected acute coronary syndrome chest pain in the emergency department (CT-COMPARE). *Int J Cardiol* 2014;177:867-73.
[PUBMED](#) | [CROSSREF](#)
10. Cury RC, Abbara S, Achenbach S, et al. CAD-RADS(TM) Coronary Artery Disease - Reporting and Data System. An expert consensus document of the Society of Cardiovascular Computed Tomography (SCCT), the American College of Radiology (ACR) and the North American Society for Cardiovascular Imaging (NASCI). *J Cardiovasc Comput Tomogr* 2016;10:269-81.
[PUBMED](#) | [CROSSREF](#)
11. Abbara S, Blanke P, Maroules CD, et al. SCCT guidelines for the performance and acquisition of coronary computed tomographic angiography: a report of the Society of Cardiovascular Computed Tomography Guidelines Committee: Endorsed by the North American Society for Cardiovascular Imaging (NASCI). *J Cardiovasc Comput Tomogr* 2016;10:435-49.
[PUBMED](#) | [CROSSREF](#)
12. Raff GL, Abidov A, Achenbach S, et al. SCCT guidelines for the interpretation and reporting of coronary computed tomographic angiography. *J Cardiovasc Comput Tomogr* 2009;3:122-36.
[PUBMED](#) | [CROSSREF](#)
13. Motoyama S, Sarai M, Harigaya H, et al. Computed tomographic angiography characteristics of atherosclerotic plaques subsequently resulting in acute coronary syndrome. *J Am Coll Cardiol* 2009;54:49-57.
[PUBMED](#) | [CROSSREF](#)
14. Puchner SB, Liu T, Mayrhofer T, et al. High-risk plaque detected on coronary CT angiography predicts acute coronary syndromes independent of significant stenosis in acute chest pain: results from the ROMICAT-II trial. *J Am Coll Cardiol* 2014;64:684-92.
[PUBMED](#) | [CROSSREF](#)
15. Abdel Razek AAK, Elrakhawy MM, Yossof MM, Nageb HM. Inter-observer agreement of the Coronary Artery Disease Reporting and Data System (CAD-RADS™) in patients with stable chest pain. *Pol J Radiol* 2018;83:e151-9.
[PUBMED](#) | [CROSSREF](#)
16. Maroules CD, Hamilton-Craig C, Branch K, et al. Coronary artery disease reporting and data system (CAD-RADS™): Inter-observer agreement for assessment categories and modifiers. *J Cardiovasc Comput Tomogr* 2018;12:125-30.
[PUBMED](#) | [CROSSREF](#)
17. Basha MAA, Aly SA, Ismail AAA, Bahaaeldin HA, Shehata SM. The validity and applicability of CAD-RADS in the management of patients with coronary artery disease. *Insights Imaging* 2019;10:117.
[PUBMED](#) | [CROSSREF](#)
18. Min JK, Labounty TM, Gomez MJ, et al. Incremental prognostic value of coronary computed tomographic angiography over coronary artery calcium score for risk prediction of major adverse cardiac events in asymptomatic diabetic individuals. *Atherosclerosis* 2014;232:298-304.
[PUBMED](#) | [CROSSREF](#)

19. Aldrovandi A, Maffei E, Seitun S, et al. Major adverse cardiac events and the severity of coronary atherosclerosis assessed by computed tomography coronary angiography in an outpatient population with suspected or known coronary artery disease. *J Thorac Imaging* 2012;27:23-8.
[PUBMED](#) | [CROSSREF](#)
20. Kang SH, Park GM, Lee SW, et al. Long-term prognostic value of coronary CT angiography in asymptomatic type 2 diabetes mellitus. *JACC Cardiovasc Imaging* 2016;9:1292-300.
[PUBMED](#) | [CROSSREF](#)
21. Xie JX, Cury RC, Leipsic J, et al. The coronary artery disease-reporting and data system (CAD-RADS): prognostic and clinical implications associated with standardized coronary computed tomography angiography reporting. *JACC Cardiovasc Imaging* 2018;11:78-89.
[PUBMED](#) | [CROSSREF](#)
22. Nam K, Hur J, Han K, et al. Prognostic value of coronary artery disease-reporting and data system (CAD-RADS) score for cardiovascular events in ischemic stroke. *Atherosclerosis* 2019;287:1-7.
[PUBMED](#) | [CROSSREF](#)
23. Bittner DO, Mayrhofer T, Budoff M, et al. Prognostic value of coronary CTA in stable chest pain: CAD-RADS, CAC, and cardiovascular events in PROMISE. *JACC Cardiovasc Imaging* 2020;13:1534-45.
[PUBMED](#) | [CROSSREF](#)
24. Muscogiuri G, Chiesa M, Trotta M, et al. Performance of a deep learning algorithm for the evaluation of CAD-RADS classification with CCTA. *Atherosclerosis* 2020;294:25-32.
[PUBMED](#) | [CROSSREF](#)
25. Williams PD. Stent fracture with contemporary coronary stent platforms. *EuroIntervention* 2014;10:651-2.
[PUBMED](#) | [CROSSREF](#)
26. Pflederer T, Marwan M, Schepis T, et al. Characterization of culprit lesions in acute coronary syndromes using coronary dual-source CT angiography. *Atherosclerosis* 2010;211:437-44.
[PUBMED](#) | [CROSSREF](#)
27. Bauer RW, Thilo C, Chiamida SA, Vogl TJ, Costello P, Schoepf UJ. Noncalcified atherosclerotic plaque burden at coronary CT angiography: a better predictor of ischemia at stress myocardial perfusion imaging than calcium score and stenosis severity. *AJR Am J Roentgenol* 2009;193:410-8.
[PUBMED](#) | [CROSSREF](#)
28. Mangiacapra F, Bressi E, Sticchi A, Morisco C, Barbato E. Fractional flow reserve (FFR) as a guide to treat coronary artery disease. *Expert Rev Cardiovasc Ther* 2018;16:465-77.
[PUBMED](#) | [CROSSREF](#)
29. Hamon M, Geindreau D, Guittet L, Bauters C, Hamon M. Additional diagnostic value of new CT imaging techniques for the functional assessment of coronary artery disease: a meta-analysis. *Eur Radiol* 2019;29:3044-61.
[PUBMED](#) | [CROSSREF](#)
30. Cademartiri F, Seitun S, Clemente A, et al. Myocardial blood flow quantification for evaluation of coronary artery disease by computed tomography. *Cardiovasc Diagn Ther* 2017;7:129-50.
[PUBMED](#) | [CROSSREF](#)
31. Cheezum MK, Ghoshhajra B, Bittencourt MS, et al. Anomalous origin of the coronary artery arising from the opposite sinus: prevalence and outcomes in patients undergoing coronary CTA. *Eur Heart J Cardiovasc Imaging* 2017;18:224-35.
[PUBMED](#) | [CROSSREF](#)
32. Warnes CA, Williams RG, Bashore TM, et al. ACC/AHA 2008 guidelines for the management of adults with congenital heart disease: a report of the American College of Cardiology/American Heart Association task force on practice guidelines (writing committee to develop guidelines on the management of adults with congenital heart disease). Developed in collaboration with the American Society of Echocardiography, Heart Rhythm Society, International Society for Adult Congenital Heart Disease, Society for Cardiovascular Angiography and Interventions, and Society of Thoracic Surgeons. *J Am Coll Cardiol* 2008;52:e143-263.
[PUBMED](#) | [CROSSREF](#)
33. Dodd JD, Ferencik M, Liberthson RR, et al. Congenital anomalies of coronary artery origin in adults: 64-MDCT appearance. *AJR Am J Roentgenol* 2007;188:W138-46.
[PUBMED](#) | [CROSSREF](#)
34. Canan A, Ranganath P, Goerne H, Abbara S, Landeras L, Rajiah P. CAD-RADS: pushing the limits. *Radiographics* 2020;40:629-52.
[PUBMED](#) | [CROSSREF](#)
35. Díaz-Zamudio M, Bacilio-Pérez U, Herrera-Zarza MC, et al. Coronary artery aneurysms and ectasia: role of coronary CT angiography. *Radiographics* 2009;29:1939-54.
[PUBMED](#) | [CROSSREF](#)

36. Pahlavan PS, Niroomand F. Coronary artery aneurysm: a review. *Clin Cardiol* 2006;29:439-43.
[PUBMED](#) | [CROSSREF](#)
37. Flor N, Di Leo G, Squarza SA, et al. Malignant incidental extracardiac findings on cardiac CT: systematic review and meta-analysis. *AJR Am J Roentgenol* 2013;201:555-64.
[PUBMED](#) | [CROSSREF](#)