

Received: 2019.11.17
Accepted: 2020.01.23
Available online: 2020.03.24
Published: 2020.05.14

The Comparative Analysis of Antegrade Versus Retrograde Approach for a Failed Porous Tantalum Rod Removal During Conversion to Total Hip Arthroplasty

Authors' Contribution:
Study Design A
Data Collection B
Statistical Analysis C
Data Interpretation D
Manuscript Preparation E
Literature Search F
Funds Collection G

AB 1 Fengchao Zhao
D 2 Li Zheng
E 3 Qi Cheng
C 2 Weifan Hu
DFG 4 Bailiang Wang

1 Orthopedic Department, The First Affiliated Hospital, Zhejiang University, Hangzhou, Zhejiang, P.R. China
2 Orthopedic Department, The Affiliated Hospital of Xuzhou Medical University, Xuzhou, Jiangsu, P.R. China
3 Orthopedic Department, Xuzhou Cancer Hospital, Xuzhou, Jiangsu, P.R. China
4 Orthopedic Department, China Japan Friendship Hospital, Beijing, P.R. China

Corresponding Author: Fengchao Zhao, e-mail: zhjianzh@vip.sina.com
Source of support: Departmental sources

Background: The failure of porous tantalum rods applied to patients with osteonecrosis of the femoral head (ONFH) has been increasingly reported during the last few years. Very few studies have reported methods for implant removal. This study aimed at comparing 2 procedures used for the removal of a failed tantalum rod during conversion to total hip arthroplasty (THA).





Material/Methods: A total of 65 patients (65 hips), who underwent THA after failed implantation of a tantalum rod between June 2007 and December 2016, were retrospectively evaluated. These patients were classified into 2 groups depending on whether the antegrade approach (removal of the tantalum rod from the tip to the butt at the lateral femoral cortex, n=27) or retrograde approach (removal of the tantalum rod from the butt at the lateral femoral cortex to the proximal tip, n=38) was used for rod extraction. These 2 groups were compared for incision length, operation time, blood loss, fracture, tantalum debris, Harris hip scores, and the presence of osteolysis and/or radiolucency.

Results: These 2 groups did not present any significant differences in terms of Harris hip score and incision length. However, the operation time ($P=0.000$), blood loss ($P=0.000$), amount of tantalum debris ($P=0.000$), and presence of radiolucency ($P=0.046$) were greater for the retrograde approach than for the antegrade approach.

Conclusions: The risk of conversion to THA following failed tantalum rod implantation is high. In such cases, the antegrade procedure was found to be a simple and efficient method for removing the trabecular metal rod with the use of a trephine.

MeSH Keywords: **Arthroplasty, Replacement, Hip • Hip • Tantalum**

Full-text PDF: <https://www.medscimonit.com/abstract/index/idArt/921459>

 2323  2  2  26



Background

The porous tantalum implant, which was designed and manufactured by Zimmer Biomet, has been widely applied to patients with osteonecrosis of the femoral head (ONFH). The advantages offered by this metal trabecular implant are as follows: high porosity (75–80%), completely interconnected pores, good osteoconductivity, and an elastic modulus similar to that of bones [1–3]. The tantalum implant provides mechanical support, prevents sclerosis and promotes bone growth into the necrotic area. The use of the porous tantalum implantation for ONFH also precludes donor-site morbidity, and is associated with autogenous bone harvesting, as well as disease transmission, which is a risk associated with the use of allografts. Furthermore, the process of using this implant is relatively simple [4–7]. The preliminary results for the porous tantalum rod implantation have been encouraging, with studies indicating the successful retention of implants by nearly 80% of the femoral head necrosis at the end of the 2-year follow-up [4–7]. However, failure of the porous tantalum rod in the treatment of ONFH has been increasingly reported during the last few years, with these failure rates ranged within 2–56% [8–11]. Such cases are mainly managed with revision to total hip arthroplasty (THA). However, in practice, it is difficult to quickly and safely remove the tantalum rod.

Very few studies have reported the methods used for implant removal. Some of these studies reported simple techniques that merely require 5 to 10 minutes, without the risk of complications [8,11], while other studies have revealed that THA is associated with increased blood loss, prolonged operation time, excessive implant debris, and high risk of squeaking and femoral fracture [12–16]. However, most of these studies were comprised of sample sizes of less than 10 cases. To our knowledge, no study has investigated the most effective method for the removal of a failed tantalum implant.

Considering the discrepancies in the results and small sample sizes of the available studies, we sought to conduct a multi-center study in a larger population group, in order to compare the most common methods. The aim of the present study was to compare the antegrade and retrograde approaches for the removal of the porous tantalum rod in cases of ONFH that require conversion to THA after failure of the rod implant.

Material and Methods

We retrospectively investigated 65 patients (65 hips) who underwent THA after failure of the porous tantalum implant for the treatment of ONFH between June 2007 and December 2016. The study protocol was approved by the Ethics Committee of our institution.

The inclusion criteria were as follows: 1) availability of the data for at least 2 years of follow-up, and 2) THA performed only on one side during the operation. Sixty-five hips of 65 patients were included in the present study. Among the included patients, 46 patients were male and 19 patients were female, and the average age of these patients was 42.3 ± 8.0 years old (range, 24 to 64 years old). 3) Patients with possible fracture or infection were ruled out [17]. The Association Research Circulation Osseous (ARCO) classification [18] was used to classify the stage of the hips: 49 hips were at stage III, while 16 hips were at stage IV. According to the method used for the removal of the tantalum rod, patients were classified into 2 groups [16]: antegrade group ($n=27$), in which the antegrade approach was used; and retrograde group ($n=38$), in which the retrograde method was used (Table 1).

Surgical procedure

The surgical procedure was performed with patients in the lateral decubitus position and used the standard posterolateral approach. Once the femoral head was dislocated, the femoral neck cortex was circumferentially excised at the desired level using a reciprocating saw. The tantalum rod was preserved and not transected. Then, the osteotomy was performed to remove the femoral head in a piecemeal fashion using an electric saw or osteotome. Then, the distal end of the rod was extracted using a 15-mm trephine. For the antegrade approach, rod trephination was performed from the level of the head to the lateral cortex of the femur. For the retrograde approach, rod trephination was performed from the lateral cortex of the femur to the level of the neck incision. In both methods, electric saw and trephine are used so as not to contact the tantalum rod as much as possible in order to reduce the generation of debris.

Once the rod was removed, the THA was performed according to routine procedures. The post-operative rehabilitation care administered was the same for all patients.

Clinical evaluation

The pre- and post-operative clinical data of the study patients were collected from the patients' medical files, surgical records and radiographs. In particular, the data collected included the incision length, operative time, blood loss, and perioperative complications such as fracture and infection. The follow-up data for all patients were available for 3- and 6-months post-operative, and annually. Harris Hip Score (HHS) evaluation was performed to evaluate the hip function before and after surgery.

Table 1. Demographic characteristics of the 2 groups.

	Antegrade group	Retrograde group	P
Patients (hips)	27	38	
Gender (Male/Female)	19/8	27/11	0.952
Age (year), mean (range)	41.6±7.9 (24–61)	42.8±8.2 (33–64)	0.785 (–0.273)
Side (R/L)	16/11	21/17	0.749
Body mass index	24.9±4.6 (17.8–35.4)	24.6±3.6 (15.9–37.6)	0.899 (–0.126)
Etiology			0.945
Idiopathic	7	8	
Corticosteroid	7	11	
Alcohol	11	15	
Trauma	2	4	
ARCO stage (III/IV)	20/7	29/9	0.836 (0.043)
HHS (pre-operative)	59.9±9.3 (34.2–71.7)	53.3±17.0 (24.8–73.5)	0.286 (–1.067)

HHS – Harris Hip Score.

Radiological evaluation

Anteroposterior and frog-leg pelvic radiographs were acquired at each follow-up. The anteroposterior-view image was used to determine the inclination and anteversion of the acetabular cup. An inclination of $40\pm 10^\circ$ and anteversion of $15\pm 10^\circ$ for the cup orientation was defined as good [19]. The presence or absence of osteolysis or radiolucency was also recorded and assessed using Gruen's classification for the femoral side [20], and Delee and Charnley's classification for the acetabular side [21]. The distribution of tantalum debris was recorded as proximal, middle, or distal, based on the previously reported system of the authors [16].

Statistical analysis

All statistical analyses in the present study were performed using the SPSS software package, version 19.0 (SPSS, Inc., Chicago, IL, USA). The Mann-Whitney *U* test was used for intergroup comparisons of the age, body mass index, operating time, perioperative blood loss, incision length, and the pre- and post-operative HHS. In order to compare these 2 groups in terms of gender distribution, side affected, etiology, position of the prosthesis, complications, and the presence or absence of osteolysis, Pearson's chi-squared test or Fisher's exact test were used. A *P*-value of <0.05 was considered statistically significant.

Results

For the baseline demographic and clinical characteristics, the 2 groups did not have any significant differences in gender distribution, body mass index, etiology, follow-up period, or pre- and post-operative HHS. However, a significant improvement in HHS was noted in both groups, indicating functional improvement. The HHS increased from 59.9 to 92.2 in the antegrade group, and from 53.3 to 91.6 in the retrograde group (Table 2).

The mean operation time in the retrograde group was 69.7 ± 11.4 minutes, which was greater than that in the antegrade group (58.6 ± 6.0 minutes) ($P=0.000$). The mean blood loss in the retrograde group was greater than that in the antegrade group (562.4 ± 118.1 mL (range 355–1020 mL) versus 459.1 ± 94.9 mL (range: 335–770 mL) ($P=0.000$). The distribution of the tantalum debris was more extensive in the retrograde group than in the antegrade group ($P=0.000$). This finding may also explain the greater frequency of osteolysis and radiolucency in the retrograde group, when compared to the antegrade group ($P=0.046$). However, no differences were noted between these 2 groups in terms of incision length and the position of the prosthesis ($P=0.286$ and 0.368 , respectively).

The average follow-up duration was 6.4 years, and there was no instance of revision or loosening of the prosthesis in either of the groups. Furthermore, there were no differences between these 2 groups in terms of incidence of complications. The incidence of femoral fracture was 10.5% (4 out of 38) in the retrograde group.

Table 2. Results of the 2 groups.

	Antegrade group	Retrograde group	P
HHS (pre-op)	59.9±9.3 (34.2–71.7)	53.3±17.0 (24.8–73.5)	0.286 (–1.067)
HHS (post-op)	92.2±3.5 (86.6–100)	91.6±3.4 (84.3–97)	0.592 (–0.536)
P	0.000	0.000	
Incision length (cm)	13.2±1.7 (11–17)	13.5±1.2 (11–16)	0.238 (–1.179)
Operation time (min)	58.6±6.0 (49–70)	69.7±11.4 (50–91)	0.000 (–3.951)
Blood loss (mL)	459.1±94.9 (335–770)	562.4±118.1 (355–1020)	0.000 (–3.909)
Position of prosthesis (good/not good)	25/2	33/5	0.368
Tantalum debris	26/1/0	14/10/14	0.000
Follow-up (years)	6.5±2.4 (2.3–11.2)	6.3±2.0 (2.8–10.6)	0.729 (–0.347)
Complications	3	8	0.224
Fracture	0	4	
Dislocation	1	0	
Wound problem	0	1	
Squeaking	2	3	
Osteolysis or radiolucency (Y/N)	1/26	8/30	0.046

HHS – Harris Hip Score.

Discussion

Over the last decade, the porous tantalum biomaterial has been widely used for the treatment of osteonecrosis of the femoral head [4–11]. The tantalum rod offers the advantages of having a modulus similar to that of the bone, high volume porosity, which facilitates secure and rapid bone ingrowth, and the elimination of morbidity associated with autogenous bone harvesting and risk of disease transmission accompanied by the use of allografts. However, 2–56% of patients who underwent tantalum implantation reported discomfort and required further treatment. If the tantalum rod implant fails to provide relief to the patient, THA is the most important alternative mode of treatment. In such cases, the tantalum rod needs to be extracted. Several studies have been published on different methods for the extraction of failed tantalum rods [12–16,22–24]. However, no study has compared the effective method for the removal of tantalum rods in cases that require conversion to THA, and the procedure continues to remain a technical challenge for surgeons [12–16].

In 2009, Varitimidis et al. [8] reported 6 cases, in which THA was performed after failure of a tantalum rod implantation. In their study, circumferential excision of the cortex of the femoral neck was performed at the desired level, and this was continued until the rod was reached. The femoral head was fragmented in a piecemeal fashion, while the tantalum rod was preserved. Thereafter, multiple holes were drilled along the circumference of the rod, and the implant was extracted with

back-and-forth movements. All 6 tantalum rods were removed without any complications, and the time required for removing the implant was 5–10 minutes. However, this method is slightly complex, and no other details are available.

In 2012, another method for the removal of the tantalum rod was proposed by Owens et al. [13]. According to their method, the femoral head was first dislocated and exposed, after which the femoral head and tantalum rod were cut using a power saw at the desired level of the femoral neck. The remaining parts of the implant were removed by metal-cutting trephination from the femoral neck to the lateral aspect of the femur in an antegrade fashion. Subsequently, Lee et al. [15] reported 8 similar cases, in which an oscillating saw was used to cut the femoral head, and the tantalum rod was cut at the required level of the femoral neck, followed by retrograde trephination from the lateral femoral cortex to the femoral neck, in order to extract the remaining portion of the implant. However, their study revealed that the transection of the tantalum rod in this method resulted in excessive tantalum debris, as well as increased operative time and blood loss. Among the 8 hips, 1 hip developed a femoral fracture, while another hip developed squeaking. In another study of 5 cases of THA following failed tantalum implantation, 2 patients developed an intraoperative fracture, while 1 patient had extensive spread of tantalum debris [12]. Olsen et al. [14] introduced a new method, in which the standard cortical femoral neck was excised in such a manner that the tantalum rod was preserved, without transecting it after the dislocation and exposure of the

femoral head. Their method involved the trephination of the of the rod from the lateral cortex of the femur to the level of the neck cut, which is similar to the technique applied in the retrograde approach examined in the present study. The distribution of tantalum debris in their study was similar to that in the present study.

Blood loss, operation time, bone loss, risk of femoral fracture, and risk of linear wear due to tantalum residue were lower

in cases of ONFH where THA was opted as the primary treatment option, when compared to cases where THA was performed after failure of the tantalum implant [15]. A 5- to 10-year study revealed that the clinical outcomes in cases where THA was the primary treatment were similar to those in cases where THA conversion was required after failure of tantalum rod implantation. However, the spread of the tantalum debris was associated with femoral osteolysis or radiolucent lines [16].

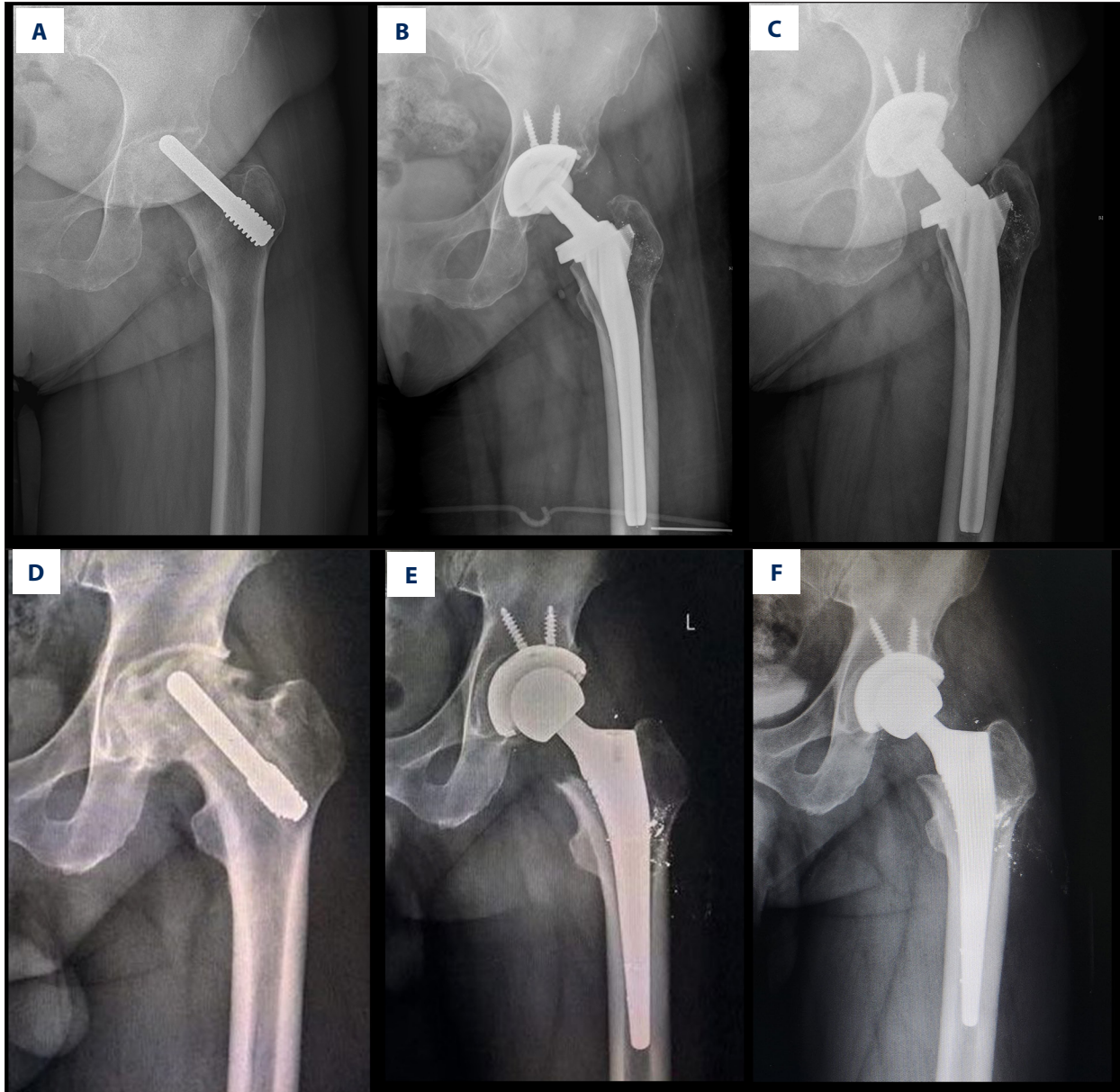


Figure 1. Tantalum debris after total hip arthroplasty (THA) between the 2 methods. (A) Pre-operative x-ray image; (B) x-ray image acquired 1 year after operation; (C) x-ray image obtained 5 years after operation on 67-year-old female using the antegrade procedure. (D) Pre-operative x-ray image; (E) x-ray image acquired 1 year after operation; (F) x-ray image obtained 5 years after operation on 46-year-old male using the retrograde procedure. There was more tantalum debris in retrograde procedure.

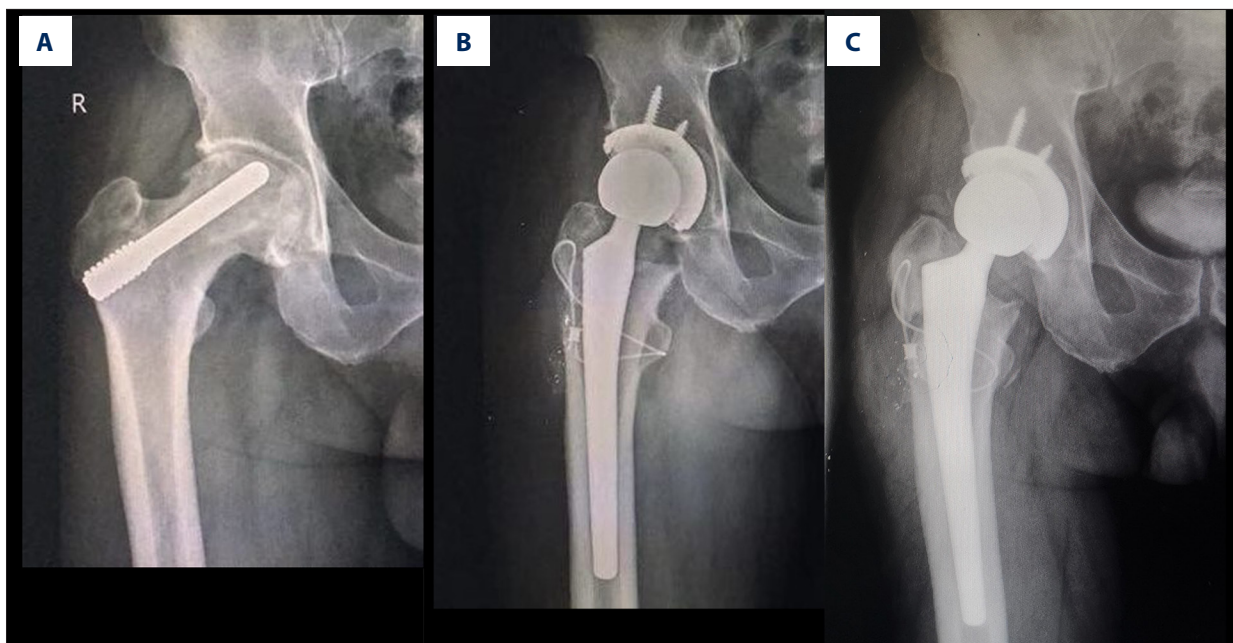


Figure 2. A 50-year-old male patient sustained a trochanteric fracture during conversion to total hip arthroplasty (THA) using the retrograde procedure. (A) Pre-operative x-ray image; (B) Post-operative x-ray image (at 1 month after THA) shows the trochanteric fracture and tantalum debris; (C) Nonunion of the trochanteric fracture 2 years later.

Since the transection of the tantalum rod at the femoral neck results in excessive tantalum residue, which in turn can lead to metal toxicity or foreign-body wear [25,26], the authors chose to only first defragment the cortex of the femoral neck, and proceed with the piecemeal disintegration of the femoral head. Among the 2 approaches used for the removal of the tantalum rod, the retrograde approach resulted in greater blood loss and tantalum debris, and required more time to complete, when compared to the antegrade approach. One of the reasons for the greater operation time in the retrograde approach may be the need for exposure of the insertion point of the rod, which would be overlaid by bone growth. Therefore, during the process of exposing the butt of the tantalum rod, there was substantial bone loss. Furthermore, it is difficult to maintain the trajectory of the tantalum rod from the lateral end to the tip during its removal. The contact of trephine and tantalum rod was hard to avoid, and excessive tantalum debris was present (Figure 1). The high incidence of trochanteric fracture could be attributed to the increased bone loss during tantalum removing (Figure 2).

In the antegrade method, the proximal end of the tantalum rod might serve as a guide for trephination once the femoral head is broken. It was found that this technique is technically simple, requires a short amount of time, and involves minimal bone loss and tantalum debris. Therefore, in order to reduce the associated morbidity, the use of the antegrade approach is recommended for cases of ONFH requiring conversion to THA after failure of the tantalum rod.

One of the limitations of the present study is that the surgery for THA was performed by different surgeons at different hospitals. Hence, various types of prostheses were used. These differences may have influenced the present results. Other limitations of the study include its retrospective design and the small number of cases. In order to further validate these present results, prospective studies with larger sample sizes are warranted.

Conclusions

For cases of ONFH, the antegrade approach appears to be safer and more effective than the retrograde approach for the removal of the porous tantalum rod during conversion to THA due to failure of implantation.

References:

1. Falzarano G, Piscopo A, Rollo G et al: Tantalum in type IV and V Paprosky periprosthetic acetabular fractures surgery in Paprosky type IV and V periprosthetic acetabular fractures surgery. *Musculoskelet Surg*, 2018; 102(1): 87–92
2. Bobyn JD, Poggie RA, Krygier JJ et al: Clinical validation of a structural porous tantalum biomaterial for adult reconstruction. *J Bone Joint Surg Am*, 2004; 86 (Suppl. 2): 123–29
3. Tsao AK, Roberson JR, Christie MJ et al: Biomechanical and clinical evaluations of a porous tantalum implant for the treatment of early-stage osteonecrosis. *J Bone Joint Surg Am*, 2005; 87(Suppl. 2) 22–27
4. Veillette CJ, Mehdian H, Schemitsch EH, Mckee MD: Survivorship analysis and radiographic outcome following tantalum rod insertion for osteonecrosis of the femoral head. *J Bone Joint Surg Am*, 2006; 88(Suppl. 3): 48–55
5. Shuler MS, Rooks MD, Roberson JR: Porous tantalum implant in early osteonecrosis of the hip: Preliminary report on operative, survival, and outcomes results. *J Arthroplasty*, 2007; 22(1): 26–31
6. Zhao D, Zhang Y, Wang W et al: Tantalum rod implantation and vascularized iliac grafting for osteonecrosis of the femoral head. *Orthopedics*, 2013; 36(6): 789–95
7. Zhang Y, Li L, Shi ZJ et al: Porous tantalum rod implant is an effective and safe choice for early-stage femoral head necrosis: A meta-analysis of clinical trials. *Eur J Orthop Surg Traumatol*, 2013; 23(2): 211–17
8. Varitimidis SE, Dimitroulias AP, Karachalios TS et al: Outcome after tantalum rod implantation for treatment of femoral head osteonecrosis: 26 hips followed for an average of 3 years. *Acta Orthop*, 2009; 80(1): 20–25
9. Zhang X, Wang J, Xiao J, Shi Z: Early failures of porous tantalum osteonecrosis implants: A case series with retrieval analysis. *Int Orthop*, 2016; 40(9): 1827–34
10. Liu ZH, Guo WS, Li ZR et al: Porous tantalum rods for treating osteonecrosis of the femoral head. *Genet Mol Res*, 2014; 13(4): 8342–52
11. Floerkemeier T, Thorey F, Daentzer D et al: Clinical and radiological outcome of the treatment of osteonecrosis of the femoral head using the osteonecrosis intervention implant. *Int Orthop*, 2011; 35(4): 489–95
12. Papapietro N, Di Martino A, Niccoli G et al: Trabecular metal screw implanted for avascular necrosis of the femoral head may complicate subsequent arthroplasty surgery. *Eur J Orthop Surg Traumatol*, 2014; 24(6): 931–38
13. Owens JB, Ely EE, Guillian NM et al: Removal of trabecular metal osteonecrosis intervention implant and conversion to primary total hip arthroplasty. *J Arthroplasty*, 2012; 27(6): 1251–53
14. Olsen M, Lewis PM, Morrison Z et al: Total hip arthroplasty following failure of core decompression and tantalum rod implantation. *Bone Joint J*, 2016; 98-B(9): 1175–79
15. Lee GW, Park KS, Kim DY et al: Results of total hip arthroplasty after core decompression with tantalum rod for osteonecrosis of the femoral head. *Clin Orthop Surg*, 2016; 8(1): 38–44
16. Cheng Q, Tang JL, Gu JJ et al: Total hip arthroplasty following failure of tantalum rod implantation for osteonecrosis of the femoral head with 5- to 10-year follow-up. *BMC Musculoskelet Disord*, 2018; 19(1): 289–97
17. Falzarano G, Piscopo A, Grubor P et al: Use of common inflammatory markers in the long-term screening of total hip arthroprosthesis infections: Our experience. *Adv Orthop*, 2017; 2017: 9679470
18. ARCO (Association Research Circulation Osseous). Committee on Terminology and Classification. *ARCO News*, 1992; 4: 41–46
19. Lewinnek GE, Lewis JL, Tarr R et al: Dislocations after total hip-replacement arthroplasties. *J Bone Joint Surg Am*, 1978; 60(2): 217–20
20. Gruen TA, Mcneice GM, Amstutz HC: "Modes of failure" of cemented stem type femoral components: A radiographic analysis of loosening. *Clin Orthop Relat Res*, 1979; 141: 17–27
21. DeLee JG, Charnley J: Radiological demarcation of cemented sockets in total hip replacement. *Clin Orthop Relat Res*, 1976; (121): 20–32
22. Tanzer M, Bobyn JD, Krygier JJ, Karabasz D: Histopathologic retrieval analysis of clinically failed porous tantalum osteonecrosis implants. *J Bone Joint Surg Am*, 2008; 90: 1282–89
23. Aurégan JC, Villain B, Bégue T: What is the rate of patients undergoing a total hip arthroplasty after core decompression and insertion of a tantalum rod in osteonecrosis of the femoral head: A systematic review. *Int Orthop*, 2018; 42(7): 1631–38
24. Fernández-Fairen M, Murcia A, Iglesias R et al: Analysis of tantalum implants used for avascular necrosis of the femoral head: A review of five retrieved specimens. *J Appl Biomater Funct Mater*, 2012; 10(1): 29–36
25. Schoon J, Geißler S, Traeger J et al: Multi-elemental nanoparticle exposure after tantalum component failure in hip arthroplasty: In-depth analysis of a single case. *Nanomedicine*, 2017; 13(8): 2415–23
26. Lombardi AV Jr, Berasi CC, Berend KR: Evolution of tibial fixation in total knee arthroplasty. *J Arthroplasty*, 2007; 22(4 Suppl. 1): 25–29