


# Outbreaks And Epidemics Of Superficial Dermatophytosis Due To *Trichophyton mentagrophytes* Complex And *Microsporum canis*: Global And Indian Scenario

This article was published in the following Dove Press journal:  
*Clinical, Cosmetic and Investigational Dermatology*

Rameshwari Thakur 

Avneet Singh Kalsi 

Department of Dermatology and Microbiology, Muzaffarnagar Medical College and Hospital, Chaudhary Charan Singh University, Meerut, India

→ Video abstract



Point your Smartphone at the code above. If you have a QR code reader the video abstract will appear. Or use: <https://youtu.be/jcdo07zry50>

**Abstract:** Until recently, superficial dermatophytosis, also known as tinea, was considered as a minor skin infection, which was easy to treat. There used to be rare outbreaks and epidemics of superficial dermatophytosis. Lately, there is a sweeping change in the clinical presentation due to extensive, atypical and recalcitrant dermatophytosis. Treating such infections poses a great challenge to the clinicians. Dermatophytosis is a superficial fungal infection of keratinized tissue (skin, hairs and nails) by dermatophytes (fungus). It is caused by the three genera of dermatophytes: *Trichophyton*, *Epidermophyton* and *Microsporum*. The conventional methods of laboratory diagnosis have now been substantiated by molecular characterization. Earlier epidemics were usually due to anthropophilic dermatophytes. Now, zoophilic dermatophytes are also responsible for many outbreaks and epidemics. We need to be equipped with the tools to face the current scenario, because this depends upon the competence of the staff working in the state-of-the-art laboratories, which is needed for the study of the epidemiology and appropriate treatment.

**Keywords:** *Trichophyton mentagrophytes* (*T. mentagrophytes*), *Microsporum canis* (*M. canis*), epidemic, outbreak

## Introduction

Dermatophytes are fungi that have the ability to invade keratinized tissue such as skin, hair and nails and thus are the main cause of mycoses of the integument in humans and animals.<sup>1</sup>

Classification of dermatophytes is being updated as the new species are evolving. According to the new classification of dermatophytes by de Hoog et al, dermatophyte species have been grouped into seven genera : *Trichophyton*, *Epidermophyton*, *Arthroderma*, *Nannizzia*, *Microsporum*, *Paraphyton* and *Lophophyton* and this taxonomy of dermatophytes includes 16 species of *Trichophyton*, one species of *Epidermophyton*, 9 species of *Nannizzia*, 3 species of *Microsporum*, one species of *Lophophyton*, 21 species of *Arthroderma* and one species of *Ctenomyces*.<sup>2</sup>

Epidemics and outbreaks due to dermatophytes have been reported in the literature from time to time.<sup>3,4</sup> Large-scale epidemic of inflammatory dermatophytosis due to *Trichophyton mentagrophytes* var. *mentagrophytes* occurred among American troops in Vietnam during 1966–1969. The source of this epidemic was traced to the rats trapped near the army living quarters.<sup>5</sup>

Correspondence: Rameshwari Thakur  
U-18/75, FF, Pink Town House, DLF City,  
Phase-3, Gurgaon, Haryana 122002, India  
Tel +91-9627440337  
Email rameshwari\_thakur@hotmail.com

Among the recent epidemics and outbreaks are: *T. mentagrophytes* genotype VIII in India, which has been reported by Nenoff et al<sup>6</sup> and two articles have mentioned genital infection due to *T. mentagrophytes* genotype VII from Switzerland and Germany.<sup>7,8</sup> Also, an outbreak due to *M. canis* and with human-to-human transmission has been stated in Israel.<sup>9</sup>

As cited by Rippon JW (1985) in one of his papers titled “The changing epidemiology and emerging patterns of dermatophytes species”

The only evidence of active evolution among the dermatophytes is seen in *M. canis* and *T. mentagrophytes*. In both, host-specific strains have emerged and will probably separate as species. This probably has happened already in the case of the variety *interdigitale* of *T. mentagrophytes*.<sup>10</sup>

Now, we see that it holds true and it has actually happened even before we realized. The zoophilic species like *M. canis* and *T. mentagrophytes* can infect virtually every mammal.<sup>11</sup>

## Current Epidemics

The current epidemics over different geographical regions of the world are due to *T. mentagrophytes* complex and *M. canis*. Until recently, it was thought that the anthropophilic species are responsible for most of the epidemics, but sometimes humans infected by zoophiles remain contagious, leading to small, self-limiting outbreaks and epidemics.<sup>4,6</sup> In some of the outbreaks, person-to-person (anthropophilic) transmission has been implicated either through direct contact or through contaminated fomites.<sup>4,12–14</sup>

## Confusion Due To Frequent Changes In The Nomenclature Of *Trichophyton mentagrophytes* Complex

There have been frequent changes in the nomenclature of *T. mentagrophytes* complex. The anthropophilic form was known as *Trichophyton mentagrophytes* var. *interdigitale* and zoophilic form as *T. mentagrophytes* var. *mentagrophytes*.<sup>11</sup> Later, *Trichophyton interdigitale* (anthropophilic strains) and *Trichophyton interdigitale* (zoophilic strains)<sup>15</sup> *Trichophyton mentagrophytes* complex has been divided into *Trichophyton mentagrophytes* containing eight genotypes, which are zoophilic, and two genotypes of *Trichophyton interdigitale* (anthropophilic species)<sup>16,17</sup> (Table 1). Polymerase Chain Reaction (PCR) cannot differentiate the two species, but it is possible with sequencing of the internal transcribed spacer

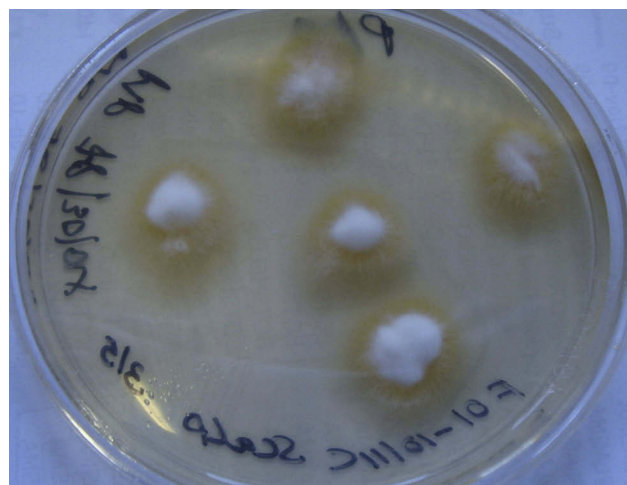**Table 1** *Trichophyton Mentagrophytes* Complex. Nomenclature (Old And current)

Author	Anthropophilic	Zoophilic
Kwon-Chung et al <sup>11</sup> 1992	<i>Trichophyton mentagrophytes</i> var. <i>interdigitale</i>	<i>Trichophyton mentagrophytes</i> var. <i>mentagrophytes</i>
Nenoff et al <sup>15</sup> 2007	<i>Trichophyton interdigitale</i> (anthropophilic strains)	<i>Trichophyton interdigitale</i> (zoophilic strains)
Heidemann et al <sup>16</sup> 2010	Current ITS-based genotypes of <i>Trichophyton mentagrophytes</i> complex	
Ninet et al. <sup>17</sup> 2003	<i>Trichophyton interdigitale</i> (anthropophilic genotypes) genotype I & II	<i>Trichophyton mentagrophytes</i> (zoophilic genotypes) genotypes III–VIII

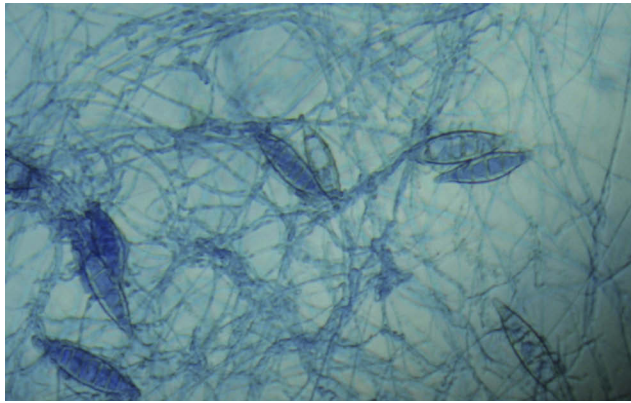
region (ITS) of fungal DNA.<sup>6</sup> Even in many journals, the nomenclature of *T. mentagrophytes* and *T. interdigitale* has been used interchangeably. So, the actual prevalence of these two closely related species is not known. Molecular typing of dermatophytes is available in very few laboratories all over the world.

## *Microsporum canis* Complex

*M. canis* has retained teleomorphs (teleomorph or sexual states) (Figures 1 and 2). It has been found that the distribution of the two compatible mating types is of little importance for propagation and survival in these two species.<sup>11</sup> Most of



**Figure 1** *M. canis*: Whitish fluffy and fur-like surface having yellow pigment at the periphery.



**Figure 2** *M. canis*: LPCB mount showing septate hyphae with thick-walled spindle-shaped macro-conidia and slightly curved tip.

the isolates of *M. canis* throughout the world are known to be the (-) type of *Arthroderma otae*. The positive (+) type was found to be in a ratio of 113 (-) to 1 (+) in Japan, but was not found elsewhere.<sup>18</sup> It is possible that one mating type had selective advantage while the other mating type died out in the process of geophilic to zoophilic evolution.<sup>11</sup>

Person-to-person transmission has been recently reported in Israel.<sup>9</sup>

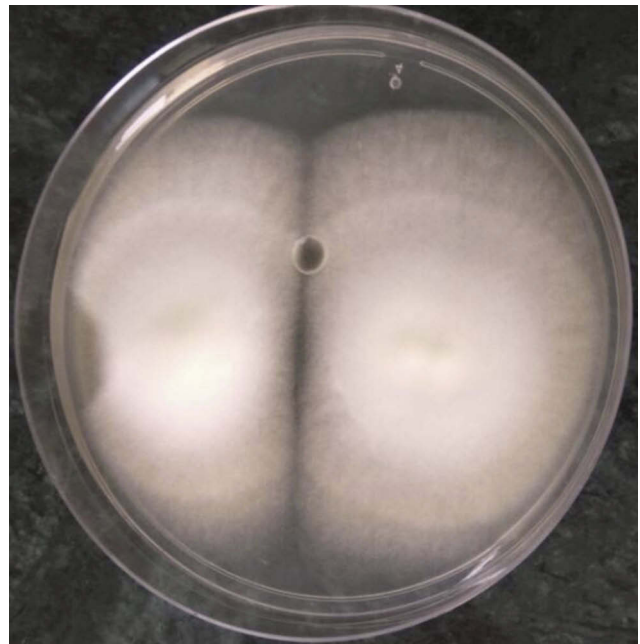## Indian Scenario

India had been facing a challenging scenario of recurrent, extensive and recalcitrant superficial dermatophytosis due to *T. mentagrophytes* genotype VIII.<sup>6</sup>

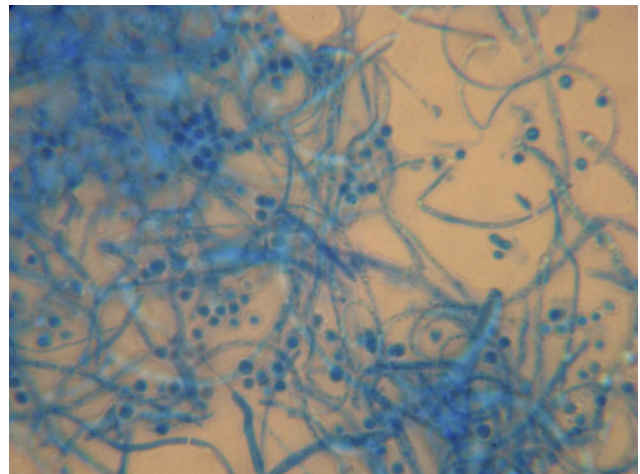
*T. mentagrophytes* complex consists of several anamorphs and three teleomorphs (*Arthroderma vanbreuseghemii*, *A. benhamiae* and *A. simii*) and are usually isolated from pets, such as guinea pigs and rabbits.<sup>19</sup>

India has recently witnessed a change in the epidemiology of dermatophytes. Earlier, *Trichophyton rubrum* was found to be the predominant species.<sup>20</sup> During the past four-five years, *T. mentagrophytes* (Figures 3 and 4) is showing a rising trend in several states of North India (Table 2). In this table, the nomenclature *Trichophyton interdigitale* and *T. mentagrophytes* have been used interchangeably except in Chandigarh<sup>22</sup> and Delhi,<sup>29</sup> where molecular typing was done. Due to reasons unexplored, the prevalence of dermatophytosis due to *M. canis* is less prevalent in India (0.76–4.5%) (Table 2).

In India, very few people keep pets due to various reasons like poor economic status, small houses and rarely cultural issues, though there are many stray dogs of mixed breed. So, the prevalence of *M. canis* could be less in India. There are lots of rodents, stray animals and monkeys, which could be



**Figure 3** Growth of *T. mentagrophytes* on SDA after 7 days of incubation. Powdery to fluffy cottony, cream to white on obverse and beige to brown on reverse.



**Figure 4** *T. mentagrophytes*: LPCB mount showing septate fungal hyphae, with numerous spherical micro-conidia arranged in grape-like clusters, cigar-shaped macro-conidia and spiral hyphae.

possibly associated as a source or the agents for the spread of *T. mentagrophytes* infection. Also, many people dry their clothes and bed linen/bedding outside their houses, and there is every possibility of the clothes and linen getting contaminated either directly or indirectly from the environment.

There could be some genetic factors, because the first author (R. Thakur) had extensive experience in dermatophytosis in Botswana (Africa) and India and has not reported even a single case of dermatophytosis due to *M. canis* from the areas where she worked. *M. canis* is widespread worldwide

**Table 2** Prevalence Of Dermatophytosis In Different States Of India

Authors, Year And Place Of Study	Predominant Species	Second Predominant Species	Other Dermatophytes
Thakur et al 2018, Muzaffarnagar, Uttar Pradesh <sup>21</sup>	<i>T. interdigitale</i> 98% (confirmed to be <i>T. mentagrophytes</i> genotype VIII)	<i>T. rubrum</i> & <i>T. violaceum</i> 1%	
Rudramurthy et al 2018, Chandigarh <sup>22</sup>	<i>T. interdigitale</i> 66.1%	<i>T. rubrum</i> 26.3%	<i>T. tonsurans</i> 3% <i>M. canis</i> 1.5%
Singh et al 2018, Delhi <sup>23</sup>	<i>T. interdigitale</i> 94%	<i>T. rubrum</i> 3%	<i>T. tonsurans</i> 1.5% <i>T. violaceum</i> 1.5%
Narain et al 2018, Allahabad, Uttar Pradesh <sup>24</sup>	<i>T. mentagrophytes</i> 52.47%	<i>T. rubrum</i> 34.98%	<i>T. violaceum</i> 3.80% <i>T. verrucosum</i> 1.52% <i>M. canis</i> 0.76% <i>E. floccosum</i> 0.76%
Vineetha et al 2018, Kerala <sup>25</sup>	<i>T. rubrum</i> 45%	<i>T. mentagrophytes</i> 18%	<i>T. tonsurans</i> 2%
Mahajan et al 2017, Banaras <sup>26</sup>	<i>T. mentagrophytes</i> 75.9%	<i>T. rubrum</i> 21.9%	<i>T. tonsurans</i> 0.7%
Sharma et al 2017, Sikkim <sup>27</sup>	<i>T. mentagrophytes</i> 40%	<i>T. schoenleinii</i> 33.3%	<i>T. tonsurans</i> 16.6% <i>T. rubrum</i> 6.6% <i>E. floccosum</i> 3.33%
Verma et al 2017, Shimla, H.P. <sup>28</sup>	<i>T. mentagrophytes</i> 62.28%	<i>T. rubrum</i> 23.40%	<i>T. violaceum</i> 6.85% <i>T. tonsurans</i> 2.85%
Dabas et al 2017, New Delhi <sup>29</sup>	<i>T. interdigitale</i> 56%	<i>T. rubrum</i> 7.5%	
Kansra et al 2016, Amritsar, Punjab <sup>30</sup>	<i>T. mentagrophytes</i> 46.43%	<i>T. rubrum</i> 24.29%	<i>T. verrucosum</i> 12.14% <i>T. schoenleinii</i> 11.43% <i>T. violaceum</i> 3.57% <i>M. gypseum</i> 2.14%
Pathania et al 2017, Chandigarh <sup>31</sup>	<i>T. mentagrophytes</i> 40%	<i>T. rubrum</i> 32.2%	<i>T. interdigitale</i> 11.1%
Noronha et al 2016, North Karnataka <sup>32</sup>	<i>T. mentagrophytes</i> 48.3%	<i>T. rubrum</i> 38.3%	<i>T. verrucosum</i> 8.3% <i>T. violaceum</i> 5%
Putta et al 2016, Kolhapur, Maharashtra <sup>33</sup>	<i>T. mentagrophytes</i> 37.74%	<i>T. tonsurans</i> 28.30%	<i>T. rubrum</i> 24.53%
Penmetcha et al 2016, Guntur, Andhra Pradesh <sup>34</sup>	<i>T. rubrum</i> 37.64%	<i>T. mentagrophytes</i> 30.58%	<i>T. violaceum</i> 7.05% <i>T. tonsurans</i> 7.05% <i>T. verrucosum</i> 7.05% <i>T. schoenleinii</i> 2.35% <i>E. floccosum</i> 4.75% <i>M. audouinii</i> 3.53%
Choudhary & Kumar 2016, Bihar <sup>35</sup>	<i>T. rubrum</i> 62.3%	<i>T. mentagrophytes</i> 14.1%	<i>E. floccosum</i> 7.05% <i>T. schoenleinii</i> 3.5%
Poluri 2015, Telangana <sup>36</sup>	<i>T. rubrum</i> 58.06%	<i>T. mentagrophytes</i> 22.58%	
Lakshmanan et al 2015, Tamil Nadu <sup>37</sup>	<i>T. rubrum</i> 79%	<i>T. mentagrophytes</i> 14.5%	<i>M. canis</i> 3.2% <i>M. gypseum</i> 3.2%
Naglot et al 2015, Assam (Northeast India) <sup>38</sup>	<i>T. rubrum</i> 50.15%	<i>T. mentagrophytes</i> 29.2%	<i>E. floccosum</i> 9.84%
Najotra et al 2015, Samba, Jammu & Kashmir <sup>39</sup>	<i>T. rubrum</i> 41.8%	<i>T. tonsurans</i> 22.4%	<i>T. mentagrophytes</i> 10.5% <i>T. violaceum</i> 7.5% <i>T. schoenleinii</i> 5.9% <i>M. gypseum</i> 4.5% <i>M. canis</i> 4.5% <i>E. floccosum</i> 2.9%

(particularly in Europe, the eastern Mediterranean and South America) and plays an important zoonotic role.<sup>1</sup> Most of the infections have been reported from the countries with predominance of Caucasians.

## Conclusion

Identification of the dermatophyte is important for the sake of appropriate treatment, prevention and epidemiology. Conventional methods may not be adequate for the differentiation of *T. mentagrophytes*, *T. interdigitale* and *T. benhamiae*, because there are not many characteristics distinguishing microscopic features. Some of these zoophilic dermatophytes, e.g. *T. mentagrophytes* (genotype VIII) and *T. mentagrophytes* (genotype VII) and *M. canis* can also have anthropophilic mode of transmission. Also, unusual infection like tinea genitalis has been reported due to *T. mentagrophytes* (genotype VII) and *M. canis*.<sup>6,7,40</sup> Recently, dermatophytosis due to *T. interdigitale* genotype I and *Trichophyton mentagrophytes* genotypes V and VIII were reported from Iran.<sup>16,17</sup> But, genotype VIII has not acquired the epidemic proportions like India. In another study in North of Iran, molecular characterization of the dermatophytes was done using polymerase chain reaction-restriction fragment length polymorphism (PCR-RFLP) on the ribosomal DNA internal transcribed spacer (ITS) region; *Trichophyton interdigitale* was found to be the predominant species and responsible for most of the cases of tinea pedis and next in frequency to *T. rubrum* for causing tinea unguium. The results of dermatophyte species identification with ITS-RFLP showed 100% concordance with the sequencing results for the ITS of the regions of rDNA.<sup>41</sup>

Many outbreaks of tinea capitis due to anthropophilic dermatophytes, e.g. *Trichophyton tonsurans*, *Trichophyton violaceum* and *Trichophyton audouinii* have been reported earlier.<sup>42–48</sup> In one of the studies, by Allahdadi et al in Arak city, centre of Iran, *T. tonsurans* was the predominant species isolated from asymptomatic carriers. Infection due to *T. tonsurans* at times does not resolve at puberty.<sup>49</sup>

So, a precise identification and delineation of isolates at species and strain level is crucial to settle effective programs for controlling and preventing infection and to establish accurate antifungal therapies.<sup>50</sup> Since dermatophytosis has public health importance, an appropriate diagnosis, source of infection and treatment are very crucial.

## Disclosure

The authors report no conflicts of interest in this work.

## References

- Weitzman I, Summerbell RC. The dermatophytes. *Clin Microbiol Rev.* 1995;8:249–259. doi:10.1128/CMR.8.2.240
- De Hoog GS, Dukik K, Monod M, et al. Towards a novel multilocus phylogenetic taxonomy for the dermatophytes. *Mycopathologia.* 2017;182(1–2):5–31. doi:10.1007/s11046-016-0073-9
- Dolenc-Voljč M, Lunder M. Epidemic of *Microsporum canis* infection in the region of Ljubljana. *Acta Dermatovenereologica A.P.A.* 1998;7:3–4.
- Subelj M, Marinko JS, Učakar V. An outbreak of *Microsporum canis* in two elementary schools in a rural area around the capital city of Slovenia, 2012. *Epidemiol Infect.* 2014;142(12):2262–2266. doi:10.1017/S0950268814000120
- Allen AM, Taplin D. Epidemic *Trichophyton mentagrophytes* infections in servicemen. *JAMA.* 1973;226:864–867. doi:10.1001/jama.1973.03230080014005
- Nenoff P, Verma SB, Vasani R, et al. The current epidemic of superficial dermatophytosis due to *Trichophyton mentagrophytes* – a molecular study. *Mycoses.* 2019;62(4):336–356. doi:10.1111/myc.12878
- Kupsch C, Czaika VA, Deutsch C, Gräser Y. *Trichophyton mentagrophytes* – a new genotype of zoophilic dermatophyte causes sexually transmitted infections. *J Dtsch Dermatol Ges.* 2019;17(5):493–501. doi:10.1111/ddg.13776.
- Luchsinger I, Bosshard PP, Kasper RS, Reinhardt D, Lautenschlager S. Tinea genitalis: a new entity of sexuality transmitted infection? Case series and review of literature. *Sex Transm Infect.* 2015;91(7):493–496. doi:10.1136/sextrans-2015-052036.
- Brosh-Nissimov T, Ben-Ami R, Astman N, Malin A, Brauch Y, Galor I. An outbreak of *Microsporum canis* infection at a military base associated with stray cat exposure and person-to-person transmission. *Mycoses.* 2018;61(7):472–476. doi:10.1111/myc.12771
- Rippon JW. The changing epidemiology and emerging patterns of dermatophyte species. *Curr Top Med Mycol.* 1985;1:208–234. doi:10.1007/978-1-4613-9547-8\_8
- Kwon-Chung KJ, Bennett JE. Dermatophytoses (Ringworm, Tinea, Dermatophytoses). In: *Medical Mycology*. 2nd ed. Philadelphia (PA): Lea and Febige; 1992:109.
- Yu J, Wan Z, Chen W, Wang W, Li R. Molecular typing study of the *Microsporum canis* strain isolated from an outbreak of tinea capitis in a school. *Mycopathologia.* 2004;157(1):37–41. doi:10.1023/b:myco.0000012221.66851.68
- Grills CE, Bryan PL, O'Moore E, Venning VA. *Microsporum canis*: report of a primary school outbreak. *Australas J Dermatol.* 2007;48(2):88–90. doi:10.1111/j.1440-0960.2007.00342.x
- Alteras I, Feuerman EJ. Two outbreaks of *Microsporum canis* ringworm in Israel. *Mycopathologia.* 1979;67(3):169–172. doi:10.1007/bf00470752
- Nenoff P, Herrmann J, Gräser Y. *Trichophyton mentagrophytes* sive interdigitale? A dermatophyte in the course of time. *J Dtsch Dermatol Ges.* 2007;5(3):198–202. doi:10.1111/j.1610-0387.2007.06180.x
- Heidemann S, Monod M, Gräser Y. Signature polymorphism in the internal transcribed spacer region relevant for the differentiation of zoophilic and anthropophilic strains of *Trichophyton interdigitale* and other species of *T. mentagrophytes* sensu lato. *Br J Dermatol.* 2010;162(2):282–295. doi:10.1111/j.1365-2133.2009.09494.x
- Ninet B, Jan I, Bontems O, et al. Identification of dermatophyte species by 28 S ribosomal DNA sequencing with a commercial kit. *J Clin Microbiol.* 2003;41(2):826–830. doi:10.1128/JCM.41.2.826-830.2003
- Hironaga M, Nozaki K, Watanabe S. Ascocarp production by *Nannizzia otae* on keratinous and non-keratinous agar media and mating behaviour of *N. otae* and 123 Japanese isolates of *Microsporum canis*. *Mycopathologia.* 1980;72(3):135–141. doi:10.1077/bf00572655

19. Drouot S, Mignon B, Fratti M, Roosje P, Monod M. Pets as the main source of two zoonotic species of the Trichophyton mentagrophytes complex in Switzerland, *Arthroderma vanbreuseghemii* and *Arthroderma benhamiae*. *Vet Dermatol*. 2009;20(1):13–18. doi:10.1111/j.1365-3164.2008.00691.x
20. Dogra S, Narang T. Emerging atypical and unusual presentations of dermatophytosis in India. *Clin Dermatol Rev*. 2017;1:12–18. doi:10.4103/CDR.CDR\_39\_17
21. Thakur R, Kalsi AS, Kushwaha P, et al. Epidemiology of corticosteroid-modified tinea: study of 100 cases in a rural tertiary care teaching hospital of Western Uttar Pradesh, India. *J Dermat Cosmetol*. 2018;2(5):64–69. doi:10.15406/jdc.2018.02.00087
22. Rudramurthy SM, Shankarnarayan SA, Dogra S, et al. Mutation in the squalene epoxidase gene of trichophyton interdigitale and trichophyton rubrum associated with allylamine resistance. *Antimicrob Agents Chemother*. 2018;62(5):e02522–17. doi:10.1128/AAC.02522-17
23. Singh A, Masih A, Khurana A, et al. High terbinafine resistance in Trichophyton interdigitale isolates in Delhi, India harbouring mutations in the squalene epoxidase gene. *Mycoses*. 2018;61(7):477–484. doi:10.1111/myc.12772
24. Narain U, Bajaj AK, Kant A. Tinea: incidence during Magh Mela. *Int J Adv Med*. 2018;5(4):993–996. doi:10.18203/2349-3933.ijam20183135
25. Vineetha M, Sheeja S, Celine MI, et al. Profile of dermatophytosis in a tertiary care center. *Indian J Dermatol*. 2018;63(6):490–495. doi:10.4103/ijid.IJD\_177\_18
26. Mahajan S, Tilak R, Kaushal SK, Mishra RN, Pandey SS. Clinico-mycological study of dermatophytic infections and their sensitivity to antifungal drugs in a tertiary care center. *Indian J Dermatol Venereol Leprol*. 2017;83(4):436–440. doi:10.4103/ijdv.IJDVL\_519\_16
27. Sharma R, Adhikari L, Sharma RL. Recurrent dermatophytosis: a rising problem in Sikkim, a Himalayan state of India. *Indian J Pathol Microbiol*. 2017;60(4):541–545. doi:10.4103/IJPM.IJPM\_831\_16
28. Verma S, Verma G, Sharma V, Bhagra S, Negi A, Tegta GR. Current spectrum of dermatophytosis in a tertiary care hospital of North India – a six year clinico-mycological study. *J Med Sci Clin Res*. 2017;5(3):19488–19494. doi:10.18535/jmscr/v5i3.184
29. Dabas Y, Xess I, Singh G, Pandey M, Meena S. Molecular identification and antifungal susceptibility patterns of clinical dermatophytes following CLSI and EUCAST guidelines. *J Fungi (Basel)*. 2017;3(2):17. doi:10.3390/jof3020017
30. Kansra S, Devi P, Sidhu S, Malhotra A. Prevalence of Dermatophytoses and their susceptibility in a tertiary care hospital of North India. *Int J Sci Res*. 2016;5(3):450–453. doi:10.36106/ijsr
31. Pathania S, Rudramurthy SM, Narang T, Saikia UN, Dogra S. A prospective study of the epidemiological and clinical patterns of recurrent dermatophytosis at a tertiary care hospital in India. *Indian J Dermatol Venereol Leprol*. 2018;84(6):678–684. doi:10.4103/ijdv.IJDVL\_645\_17
32. Noronha TM, Tophakhane RS, Nadiger S. Clinico-microbiological study of dermatophytosis in a tertiary-care hospital in North Karnataka. *Indian Dermatol Online J*. 2016;7(4):264–271. doi:10.4103/2229-5178.185488
33. Putta SD, Kulkarni VA, Bhadade AA, Kulkarni VN, Walawalkar AS. Prevalence of dermatophytosis and its spectrum in a tertiary care hospital, Kolhapur. *Indian J Basic Appl Med Res*. 2016;5(3):595–600.
34. Penmetcha U, Myneni RB, Yarlagadda P, Simgamsetty S. A study of prevalence of dermatophytosis in and around Guntur District, Andhra Pradesh, South India. *Int J Curr Microbiol App Sci*. 2016;5(9):702–717. doi:10.20546/ijcmas.2016.509.081
35. Chaudhary JK, Kumar A. A clinico-mycological profile of dermatophytosis at a tertiary care hospital in Bihar. *Int J Curr Microbiol App Sci*. 2016;5(2):181–189. doi:10.20546/ijcmas.2016.502.021
36. Poluri LV, Indugula JP, Kondapaneni SL. Clinicomycological study of dermatophytosis in South India. *J Lab Physicians*. 2015;7(2):84–89. doi:10.4103/0974-2727.163135
37. Lakshmanan A, Ganeshkumar P, Mohan SR, Hemamalini M, Madhavan R. Epidemiological and clinical pattern of dermatomycoses in rural India. *Indian J Med Microbiol*. 2015;33(Suppl):134–136. doi:10.4103/0255-0857.150922
38. Naglot A, Shrimali DD, Nath BK, et al. Recent trends of dermatophytosis in Northeast India (Assam) and interpretation of published studies. *Int J Curr Microbiol App Sci*. 2015;4(11):111–120.
39. Najotra DK, Choudhary V, Sahni B, Choudhary A. Clinico-epidemiological profile of dermatophytosis in district Samba: a cross sectional study from the state of Jammu and Kashmir, India. *Med Sci*. 2015;3(1):185–189. doi:10.29387/ms.2015.3.1.183-189
40. Prohić A, Krupalija-Fazlić M, Jovović Sadiković T. Incidence and etiological agents of genital dermatophytosis in males. *Med Glas (Zenica)*. 2015;12(1):52–56.
41. Didehdar M, Shokohi T, Khansarinejad B, et al. Characterization of clinically important dermatophytes in North of Iran using PCR-RFLP on ITS region. *J Mycol Med*. 2016;26(4):345–350. doi:10.1016/j.mycmed.2016.06.006
42. Rosenthal SA, Fisher D, Furnari D. A localized outbreak in New York of tinea capitis due to Trichophyton violaceum: observations with special reference to mixed infections of the scalp. *AMA Arch Derm*. 1958;78(6):689–691. doi:10.1001/archderm.1958.01560120009002
43. Donghi D, Hauser V, Bosshard PP. Microsporum audouinii tinea capitis in a Swiss school: assessment and management of patients and asymptomatic carriers. *Med Mycol*. 2011;49(3):324–328. doi:10.3109/13693786.2010.522602
44. Ilkit M, Ali Saracli M, Kurdak H, et al. Clonal outbreak of Trichophyton tonsurans tinea capitis gladiatorum among wrestlers in Adana, Turkey. *Med Mycol*. 2010;48(3):480–485. doi:10.3109/13693780903278051
45. Bassiri-Jahromi S, Khaksar AA. Outbreak of tinea gladiatorum in wrestlers in Tehran (Iran). *Indian J Dermatol*. 2008;53(3):132–136. doi:10.4103/0019-5154.43219
46. Shroba J, Olson-Burgess C, Preuett B, Abdel-Rahman SM. A large outbreak of Trichophyton tonsurans among health care workers in a pediatric hospital. *Am J Infect Control*. 2009;37(1):43–48. doi:10.1016/j.ajic.2007.11.008
47. Fuller LC, Child FC, Higgins EM. Tinea capitis in south-east London: an outbreak of Trichophyton tonsurans infection. *Br J Dermatol*. 1997;136(1):139. doi:10.1111/j.1365-2133.1997.tb08771.x
48. Babel DE, Baughman SA. Evaluation of the adult carrier state in juvenile tinea capitis caused by Trichophyton tonsurans. *J Am Acad Dermatol*. 1989;21(6):1209–1212. doi:10.1016/s0190-9622(89)70331-5
49. Allahdadi M, Hajihosseini R, Kord M, Rahmati E, Amanloo S, Didehdar M. Molecular characterization and antifungal susceptibility profile of dermatophytes isolated from scalp dermatophyte carriage in primary school children in Arak city, Center of Iran. *J Mycol Med*. 2019;29(1):19–23. doi:10.1016/j.mycmed.2019.01.002
50. Cafarchia C, Iatta R, Latrofa MS, Gräser Y, Otranto D. Molecular epidemiology, phylogeny and evolution of dermatophytes. *Infect Genet Evol*. 2013;20:336–351. doi:10.1016/j.meegid.2013.09.005

### Clinical, Cosmetic and Investigational Dermatology

Dovepress

#### Publish your work in this journal

Clinical, Cosmetic and Investigational Dermatology is an international, peer-reviewed, open access, online journal that focuses on the latest clinical and experimental research in all aspects of skin disease and cosmetic interventions. This journal is indexed on CAS.

The manuscript management system is completely online and includes a very quick and fair peer-review system, which is all easy to use. Visit <http://www.dovepress.com/testimonials.php> to read real quotes from published authors.

Submit your manuscript here: <https://www.dovepress.com/clinical-cosmetic-and-investigational-dermatology-journal>