



A Case of Acute Promyelocytic Leukemia Concomitant with Plasma Cell Myeloma

Jinsook Lim, M.D.¹, Gye Cheol Kwon, M.D.¹, Sun Hoe Koo, M.D.¹, Ik Chan Song, M.D.², and Jimyung Kim, M.D.¹

Departments of Laboratory Medicine¹ and Internal Medicine², Chungnam National University Hospital, Daejeon, Korea

Dear Editor

AML is a myeloid clonal malignancy characterized by the accumulation of abnormal immature myeloid cells in the bone marrow. The occurrence of therapy-related AML as a late complication of cytotoxic therapy is well documented [1], and several regimens for the treatment of plasma cell myeloma (PCM) have been associated with the development of myeloid neoplasms, such as AML, myelodysplastic syndrome, and myeloproliferative neoplasm [2]. The simultaneous occurrence of AML with various plasma cell dyscrasias without prior exposure to chemotherapy or radiotherapy is extremely rare, and most reported cases are of the myelomonocytic or monocytic subtype [3-6].

Herein, we report the first case of simultaneous acute promyelocytic leukemia (APL) and PCM presentation without previous exposure to chemotherapy or radiotherapy. A 60-yr-old man with a history of diabetic nephropathy, hypertension, and acute myocardial infarction with subsequent congestive heart failure presented to the emergency department with a 1-week history of general weakness, poor oral intake, and nausea. Neither hepatomegaly nor splenomegaly was detected on physical examination. The initial complete blood counts were the following: hemoglobin (11.5 g/dL, reference range: 13.5-17.4 g/dL), white blood cell count ($2.7 \times 10^9/L$, reference range: $3.8-10.0 \times 10^9/L$), platelet count ($378 \times 10^9/L$, reference range: $130-400 \times 10^9/L$), and white blood cell differential indicated 1% band neutrophils; 29% neutrophils; 62% lymphocytes; 2% monocytes; 4% eosinophils; and

2% basophils. Initial biochemical tests determined levels of total protein, (7.1 g/dL, reference range: 6.5-8.0 g/dL), albumin (2.9 g/dL, reference range: 4.0-5.0 g/dL), creatinine (5.1 mg/dL, reference range: 0.8-1.2 mg/dL), total calcium (6.6 mg/dL, reference range: 8.7-10.6 mg/dL), phosphorus (4.8 mg/dL, reference range: 2.5-4.7 mg/dL), β_2 microglobulin (9.29 mg/L, reference range: 0-3.0 mg/L), and serum IgG (3,018 mg/dL, reference range: 680-1,620 mg/dL). Capillary electrophoresis (Sebia, Norcross, GA, USA) of serum and urine proteins showed a monoclonal peak (1.41 g/dL, 21.1% in serum; 0.22 g/dL, 8.3% in urine) in the gamma-globulin region, and immunofixation electrophoresis confirmed monoclonal gammopathy of IgG, kappa type. The ratios of serum and urine kappa/lambda light chains were 1.69 (reference range: 0.26-1.65) and 5.33 (reference range: 0.26-1.65), respectively. Radiologically, no osteolytic lesions were detected, but spinal magnetic resonance imaging (MRI) showed abnormal bone marrow signal intensity related to PCM.

A bone marrow aspirate was composed of 10% myeloblasts, 23% abnormal hypergranular promyelocytes containing Auer rods, and 16% plasma cells. Myeloblasts and abnormal promyelocytes stained strongly positive for myeloperoxidase (MPO). The cellularity of biopsy was 70% and diffuse infiltration of two distinct populations consisting of leukemic myeloid cells (myeloblasts and abnormal promyelocytes) and plasma cells was observed. Immunohistochemical staining of the marrow biopsy showed significant positivity for CD138 and kappa light chain (Fig. 1). Flow cytomet-

Received: July 2, 2013

Revision received: July 29, 2013

Accepted: September 2, 2013

Corresponding author: Jimyung Kim

Department of Laboratory Medicine, Chungnam National University Hospital, 33 Munhwa-ro, Joong-gu, Daejeon 301-721, Korea
Tel: +82-42-280-7998, Fax: +82-42-257-5365, E-mail: jmkim@cnuh.co.kr

© The Korean Society for Laboratory Medicine.

This is an Open Access article distributed under the terms of the Creative Commons Attribution Non-Commercial License (<http://creativecommons.org/licenses/by-nc/3.0>) which permits unrestricted non-commercial use, distribution, and reproduction in any medium, provided the original work is properly cited.

ric analysis demonstrated blastic cells expressing CD13, CD33, and cytoplasmic MPO, but not HLA-DR, CD34, or CD15, consistent with the characteristics of APL. Cytogenetic analysis revealed a karyotype of 46,XY,t(15;17)(q22;q21)[4]/46,XY[16], and FISH confirmed nuc ish (PML,RARA)x3(PML con RARAx2)[64/200]. Nested reverse transcriptase-polymerase chain reaction (Seegene, Seoul, Korea) determined rearrangement of the *PML/RARA* gene. On the basis of these findings, we diagnosed the patient with APL concomitant with PCM, and the patient was initially treated with all-trans retinoic acid (ATRA) for 1 week. The patient refused additional chemotherapy because of his deteriorating physical condition after administration of ATRA and was discharged after 4 months of supportive care.

AML and PCM are different disease entities, and most concomitant cases result from leukemia that develops because of chemotherapy for preceding myeloma. Undiagnosed or untreated PCM co-presenting with AML is rare, with only 13 reports in the literature to date [7-9]. To our knowledge, this is the first reported case of APL concomitant with PCM worldwide.

In this case, the diagnosis of APL was evident because of the presence of abnormal promyelocytes, Faggot cells, and the *PML/RARA* gene rearrangement. Before concluding that plasmacytosis is associated with clonal hematologic malignancy or

PCM, reactive plasmacytosis should be ruled out because plasmacytosis can co-occur with AML [10], in which interleukin-6 production by leukemic blasts may stimulate plasma cell growth [11]. The patient's various chronic conditions confounded the assessment of CRAB (hypercalcemia, renal insufficiency, anemia, and bony lesion) to prove end-organ damage by PCM. In this case, anemia could be attributed to the underlying chronic diseases, and the decrease of albumin and elevation of creatinine levels usually accompanied by PCM were masked by diabetic nephropathy. Elevation of total protein levels was not prominent, and hypercalcemia was also not observed because of the patient's nephropathy. As MRI is more sensitive than a skeletal survey, the increased signal intensity detected by MRI determined bony lesions in PCM [12]. The creatinine level in this patient was stable (3 mg/dL), but was aggravated on presentation possibly because of PCM, and urgent hemodialysis was needed. In addition, bone marrow with 16% plasma cells was noted, which is not usually seen in reactive plasmacytosis, where plasma cells typically do not exceed 10% [13]. The presence of >10% plasma cells, monoclonal gammopathy by electrophoresis, kappa restriction by immunohistochemical stain, aggravation of kidney function, and bony lesions in MRI lead to the conclusion of clonal plasmacytosis, and a final diagnosis of APL concomitant with PCM was made.

The proposed reasons for concurrent presentation of 2 different hematologic malignancies are abnormal multipotent stem cells, environmental risk factors, repeated infections that result in the development of a leukemic clone, and decreased immune surveillance, which may result in failure to eliminate leukemic clones [6, 11, 14].

In cases of APL followed by chemotherapy for PCM, a regimen of ATRA or allogeneic stem cell transplantation can be considered treatment options [1, 15], but treatment regimens for concomitant malignancies are not fully established because the co-occurrence of APL and PCM is rare. In this case, treatment with ATRA was begun with the intent to add idarubicine; however, additional chemotherapy was discontinued because the patient developed sepsis with aggravated general weakness. Aside from 1 patient who received stem cell transplantation [9], there have been no reports on survival of patients with concomitant AML and PCM who received chemotherapy, and the time interval from diagnosis to death in most cases was <5 months. The prognosis of this patient was poor because of his deteriorating condition despite appropriate supportive care.

In conclusion, we described the first case of concomitant APL and PCM, suggesting that 2 distinct diseases can present coin-

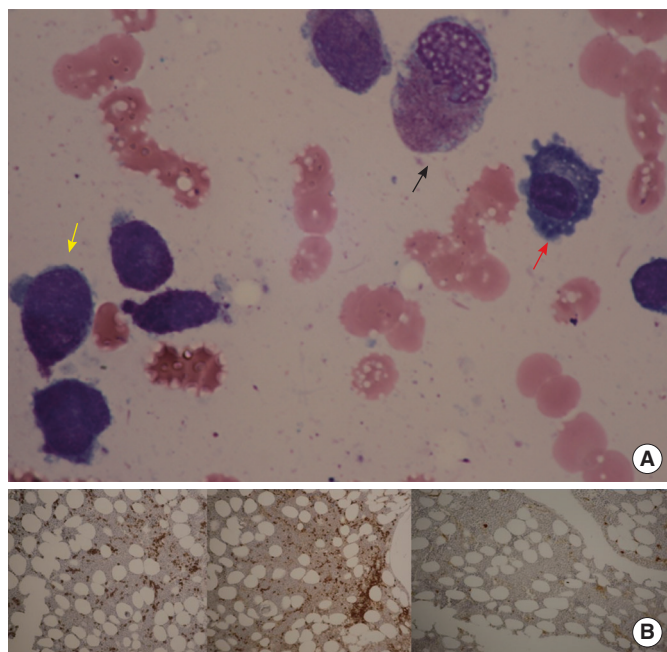


Fig. 1. (A) Bone marrow aspiration showing abnormal promyelocytes (yellow arrow), Faggot cells (black arrow), and plasma cells (red arrow) (Wright stain, $\times 1,000$) and (B) Immunohistochemical stain with CD138, (left, $\times 100$), kappa light chain (middle, $\times 100$), and lambda light chain (right, $\times 100$).

identally without previous chemotherapy. Although rare, plasmacytosis can occur in AML, and clonality should be ruled out because of the simultaneous presentation of these 2 different hematological malignancies.

Authors' Disclosures of Potential Conflicts of Interest

No potential conflicts of interest relevant to this article were reported.

REFERENCES

1. Godley LA and Larson RA. Therapy-related myeloid leukemia. *Semin Oncol* 2008;35:418-29.
2. Reddi DM, Lu CM, Fedoriw G, Liu YC, Wang FF, Ely S, et al. Myeloid neoplasms secondary to plasma cell myeloma: an intrinsic predisposition or therapy-related phenomenon? A clinicopathologic study of 41 cases and correlation of cytogenetic features with treatment regimens. *Am J Clin Pathol* 2012;138:855-66.
3. Murashige N, Tabanda R, Zalusky R. Occurrence of acute myeloid monocytic leukemia in a case of untreated Waldenström's macroglobulinemia. *Am J Hematol* 2002;71:94-7.
4. Parapia L, Abbott CR, Masters GM, Roberts BE. Simultaneous presentation of acute myelomonocytic leukemia and multiple myeloma. *Acta Haematol* 1982;68:153-6.
5. Raz I and Polliack A. Coexistence of myelomonocytic leukemia and monoclonal gammopathy or myeloma. Simultaneous presentation in three patients. *Cancer* 1984;53:83-5.
6. Luca DC and Almanaseer IY. Simultaneous presentation of multiple myeloma and acute monocytic leukemia. *Arch Pathol Lab Med* 2003;127:1506-8.
7. Attili S, Lakshmiah KC, Madhumati M, Saini KS, Anupama G, Saini ML, et al. Simultaneous occurrence of multiple myeloma and acute myeloid leukemia. *Turk J Hematol* 2006;23:209-11.
8. Shukla J, Patne SC, Singh NK; Usah. Simultaneous appearance of dual malignancies of hematopoietic system-multiple myeloma and acute myeloid leukemia. *Indian J Pathol Microbiol* 2008;51:118-20.
9. Kim D, Kwok B, Steinberg A. Simultaneous acute myeloid leukemia and multiple myeloma successfully treated with allogeneic stem cell transplantation. *South Med J* 2010;103:1246-9.
10. Rangan A, Arora B, Rangan P, Dadu T. Florid plasmacytosis in a case of acute myeloid leukemia: a diagnostic dilemma. *Indian J Med Paediatr Oncol* 2010;31:36-8.
11. Wulf GG, Jahns-Streubel G, Hemmerlein B, Bonnekessen K, Wörmann B, Hiddemann W. Plasmacytosis in acute myeloid leukemia: two cases of plasmacytosis and increased IL-6 production in AML blast cells. *Ann Hematol* 1998;76:273-7.
12. Ghanem N, Lohrmann C, Engelhardt M, Pache G, Uhl M, Saueressig U, et al. Whole-body MRI in the detection of bone marrow infiltration in patients with plasma cell neoplasms in comparison to the radiological skeletal survey. *Eur Radiol* 2006;16:1005-14.
13. Naparstek E, Leiserowitz R, Gamliel H, Polliack A. Simultaneous presentation of plasma cell and monocytic leukemia with a subacute clinical course. *Acta Haematol* 1982;68:249-55.
14. Osserman EF. The association between plasmacytic and monocytic dyscrasia in man: clinical and biochemical studies. In: Killander J, ed. *Gamma Globulins: structure and control of biosynthesis*. New York: Interscience Publishers, 1967:573-83.
15. Larson RA. Etiology and management of therapy-related myeloid leukemia. *Hematology Am Soc Hematol Educ Program* 2007:453-9.