

Case Report

Tardive Dyskinesia, Oral Parafunction, and Implant-Supported Rehabilitation

S. Lumetti,¹ G. Ghiacci,¹ G. M. Macaluso,¹ M. Amore,² C. Galli,¹
E. Calciolari,³ and E. Manfredi¹

¹*Centro Universitario di Odontoiatria, SBiBiT, Università degli Studi di Parma, Parma, Italy*

²*Sezione di Psichiatria, Dipartimento di Neuroscienze, Riabilitazione, Oftalmologia, Genetica e Scienze Materno-Infantili, Università degli Studi di Genova, Genova, Italy*

³*Centre for Oral Clinical Research, Queen Mary University of London, London, UK*

Correspondence should be addressed to G. Ghiacci; giulia.ghiacci@gmail.com

Received 12 September 2016; Revised 26 October 2016; Accepted 15 November 2016

Academic Editor: Miguel de Araújo Nobre

Copyright © 2016 S. Lumetti et al. This is an open access article distributed under the Creative Commons Attribution License, which permits unrestricted use, distribution, and reproduction in any medium, provided the original work is properly cited.

Oral movement disorders may lead to prosthesis and implant failure due to excessive loading. We report on an edentulous patient suffering from drug-induced tardive dyskinesia (TD) and oral parafunction (OP) rehabilitated with implant-supported screw-retained prostheses. The frequency and intensity of the movements were high, and no pharmacological intervention was possible. Moreover, the patient refused night-time splint therapy. A series of implant and prosthetic failures were experienced. Implant failures were all in the maxilla and stopped when a rigid titanium structure was placed to connect implants. Ad hoc designed studies are desirable to elucidate the mutual influence between oral movement disorders and implant-supported rehabilitation.

1. Introduction

Tardive dyskinesia (TD) is characterised by involuntary, repetitive, and purposeless movements, which may involve chewing motions, cheek puffing, tongue protrusion, and lip pursing. Movements of other body segments may also occur, and symptoms may appear during sleep and/or wakefulness [1, 2]. Most often TD represents a side effect of antipsychotic medications [3, 4]. Typical and, at a lower rate, atypical antipsychotics may induce TD probably by increasing dopamine sensitivity in the nigrostriatal pathway, especially for D2 dopamine receptor [5–9]. Other drugs, as antiemetic metoclopramide and antidepressants, have been linked to TD, although with much lower frequency [10–13]. It is important to underline the fact that these drugs are capable of inducing diverse movement disorders, as dystonia [14], myoclonus [15], “rabbit syndrome” [16], and sleep bruxism [17]. The latter has been linked particularly to selective serotonin reuptake inhibitors (SSRIs) [18, 19].

The term “tardive” was originally used to indicate the most frequent timing of dyskinesia onset, after at least 3 months of therapy. However, the appearance of dyskinesic

symptoms is not dose-related and may occur either after a short or a long time of drug use, and it is generally accepted that most patients will eventually fall ill with the disorder if they remain on neuroleptics long enough.

Oral parafunctions (OP) include many activities occurring during the awake state, the commonest being prolonged steady mandibular postures and jaw clenching [20]. They can be classified in primary, or idiopathic, and secondary, when they originate from a neurological or psychiatric disease or represent a side effect of a medication or a recreational drug. Alcohol intake and cigarette smoking may also contribute [21]. They have been associated with psychiatric disorders as well as psychosocial factors like stress and anxiety [22–24].

TD may have dental implications, as it causes attritions and abfractions on natural teeth [25, 26]. It also represents a risk factor for the prosthetic management of the patient, worsening the stability of complete dentures and increasing the risk of prostheses breaks. Additionally, TD-provoking drugs can induce changes of salivary flow, which worsen patient’s adaptation to removable prostheses [27–30]. Implant-supported fixed rehabilitation may appear as a valuable

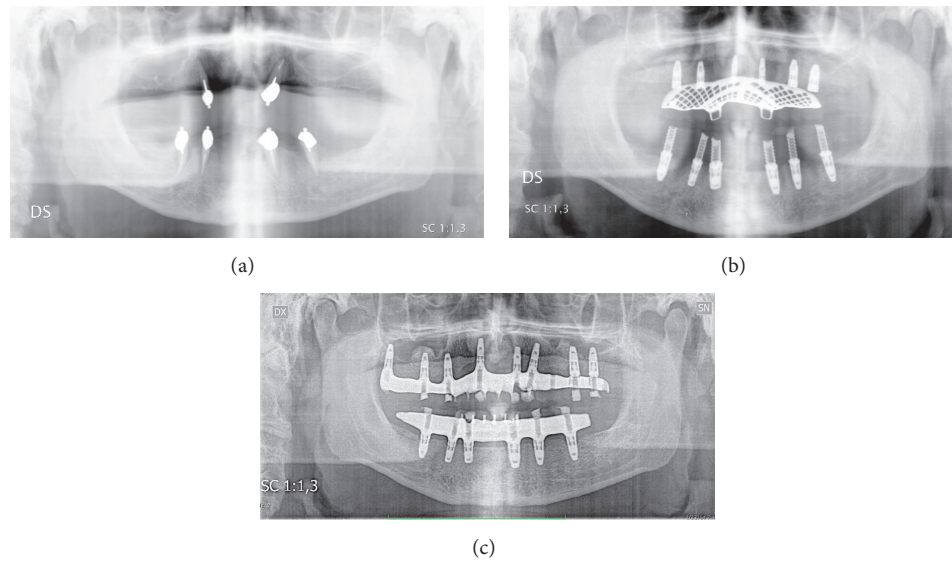


FIGURE 1: Orthopantomography of the patient at first visit (a), 18 weeks (b), and 96 weeks (c).

therapeutic option, as it improves prostheses stability and has positive psychosocial effects [31, 32]. However, oral movement disorders may cause excessive load of the prostheses, which in turn may affect implant outcome [33, 34], and jeopardise simple or complex rehabilitative procedures and tardive dyskinesia represents a particularly critical situation for implant rehabilitation [35, 36].

We here report a case of implant-supported fixed rehabilitation in an edentulous patient with extreme loading conditions due to TD and OP.

2. Case Presentation

A 58-year-old Caucasian man complaining of unsatisfactory removable prostheses was admitted to the dental clinic. Remote anamnesis revealed history of alcohol abuse associated with impulsive behaviour, with the start of medical therapies dating back to 2004. The patient was at that time suffering from major depression and narcissistic personality disorder and was administered a multiple pharmacotherapy. He was treated with Citalopram 40 mg/day, aimed at controlling depression, from 2004 to 2007; an occasional treatment with Paroxetine 30 mg/day was performed in 2004 for 90 days. During the same year, the patient took Promethazine 25 mg/day. Valproic acid 1 g/day and Oxcarbazepine 1.2 g/day were prescribed up to now as anticonvulsants. The patient was also administered benzodiazepines: Lorazepam 2.5 mg/day from 2004 to 2006, Triazolam 0.25 mg/day, and Diazepam 2 mg/day from 2005 to 2006. A temporary treatment with the second-generation antipsychotic Olanzapine 5 mg/day was carried out for 90 days in 2005. The patient also assumed Trazodone 75 mg/day. In 2007, the antidepressant Venlafaxine substituted Citalopram, with doses increasing to the current posology of 150 mg/day. Clonazepam 5 mg/day was administered since 2007, substituting previously used benzodiazepines. In 2008, the patient received Hydroxyzine

25 mg/day. During 2011, Zolpidem 4 mg/day was prescribed to the patient. Olanzapine 5 mg/day was permanently reintroduced into the therapy in April 2012.

The patient has been suffering from TD as a side effect of drugs since 2009. The involuntary movements he presented were repetitive stereotyped chewing motions and lip protruding. The movements were probably present also during sleep, but the patient did not accept further ambulatory sleep study.

OP was also evident, as prolonged steady mandibular postures and habit of teeth clenching; these activities, differently from the repetitive movements of TD, could be voluntarily stopped and were exacerbated in state of psychological anxiety.

The patient had been smoking 20 cigarettes/day since many years.

Clinical examination of the oral cavity revealed the presence of 2 residual teeth in the maxilla (canines) and 4 residual teeth in the mandible (2 canines and 2 premolars), restored with post and ball attachment to, respectively, stabilise maxillary and mandibular overdentures. All teeth were affected by severe reduction of periodontal support and showed class III mobility. Marked gingival inflammation was also evident. Orthopantomography attested horizontal bone loss around the remaining teeth and generalised vertical atrophy of the alveolar processes (Figure 1(a)).

Treatment consisted of extraction of the remaining hopeless teeth (time: T0) and subsequent full mouth rehabilitation with implant-supported fixed prostheses. After thorough discussion, the patient approved this therapeutic option.

Twelve weeks following T0, a CT scan (Siemens Somatom Emotion 6; Siemens, Erlangen, Germany) was performed to plan implant insertion (NobelGuide planning software; Nobel Biocare, Göteborg, Sweden). Two weeks later, the patient underwent bilateral sinus lift with lateral window approach. Autologous bone chips plus deproteinised bovine bone granules (Bio-Oss; Geistlich Pharma AG, Wolhusen,

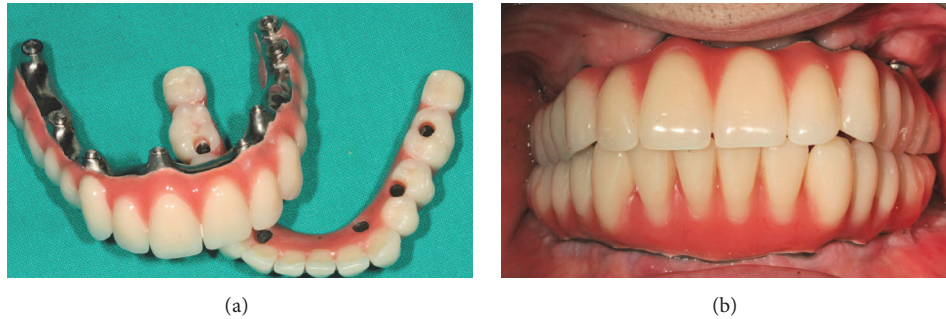


FIGURE 2: Final prostheses delivered to the patient at 96 weeks.

Switzerland) were used as grafting materials. In the course of the same surgical intervention, six dental implants (NobelReplace, Nobel Biocare, Göteborg, Sweden, as all the remaining implants employed) were placed in the maxilla with an insertion torque > 30 N/cm. The patient was provided with a provisional complete denture to wear during the planned 24-week healing period.

The mandible was rehabilitated 18 weeks after T0 by means of 6 dental implants inserted with a torque > 40 N/cm and immediately restored with a provisional screw-retained acrylic bridge. The implants were all 10 mm long and 4.3 diameter, except the 4.6 implant, which had a 5 mm diameter (Figure 1(b)). A group function occlusal scheme was created, with accurate control of contacts in intercuspal position and lateral and protrusive movements. This occlusal scheme was maintained in both provisional and final prostheses.

At 32 weeks, a complete mandibular implant-supported screw-retained prosthesis was finalised with composite teeth and milled titanium framework.

At 36 weeks, the implant in 1.1 position failed. At a routine control visit, the implant was exposed and mobile, with no symptoms. It was therefore removed and substituted with a larger implant. At the same time point, the remaining maxillary implants were loaded with a provisional implant-supported screw-retained acrylic prosthesis.

Four weeks later (at 40-week time point), the implants in 2.2 and 2.6 positions failed, with no apparent sign of infection. The implant in 2.2 site was replaced with a larger one. This was not possible for the 2.6 implant; thus an implant was inserted more distally, in 2.7 position. An additional implant was placed in 1.7. A provisional acrylic bridge was then placed, using all the maxillary implants.

At 44 weeks, the implant in 2.4 site showed severe marginal bone loss on the vestibular side, which was managed by means of a deproteinised bovine bone granular graft (Bio-Oss; Geistlich Pharma AG, Wolhusen, Switzerland). Despite this intervention, the implant failed at 48 weeks and was replaced with a longer implant, inserted apically. Another implant was positioned in the adjacent 2.3 area.

At the following monthly follow-up visits, the provisional maxillary bridge frequently showed cracks, which underwent mostly unnoticed by the patient. All cracks could be repaired.

At 60 weeks, the maxillary acrylic bridge broke into two pieces, and implants 2.4 and 2.7 were removed, due to their

loss of osseointegration in the absence of infection signs. Implants were placed in 2.6 and 2.7 sites. A new acrylic full arch bridge was screwed to all the maxillary implants.

At 72 weeks, the patient was provided with a maxillary screw-retained prosthesis with composite teeth and milled titanium framework (Figures 2(a) and 2(b)). From this moment to the 96-week follow-up visit, no further maxillary implant was lost and the prosthesis performed satisfactorily. A time course of maxillary implant insertions and failures is described in Figure 3.

At 96 weeks, all mandibular implants were successful (Figure 1(c)), as they had good stability and showed no marginal bone loss, no inflammation, nor any symptoms. The mandibular full arch bridge performed adequately during the whole examination period, showing some sign of attrition.

TD appeared as a permanent condition during the observation period. It was not possible to prescribe a pharmacological therapy specifically aimed at controlling TD due to the underlying psychiatric disease of the patient. The patient refused night splint therapy.

Massive efforts to teach self-control of OP were undertaken, but the effect was highly variable in time and, overall, poor.

3. Discussion

Oral parafunctions may alter occlusal loads of natural teeth, prostheses, and dental implants, both in terms of force direction and intensity. Dental attrition, abfraction, and occlusal pits on natural teeth have been documented in patients with self-reported parafunctions. Many authors suggested that oral parafunctions represent a risk factor for marginal bone loss around implants and implant failure [37–40].

TD and other oral movement disorders can similarly generate increased tooth or implant loads. A case of traumatic granulomatous tissue at the implant site of a patient with TD has been reported [41]. Other studies showed successful results of implant-retained overdentures in patients with neurological movement disorders involving oral and perioral areas [35, 36, 42–46].

As a matter of fact, the influence of increased load on implants still represents a matter of debate and no clear-cut conclusion can be drawn from the published literature [47–54]. This is in part due to the inherent difficulty in quantifying

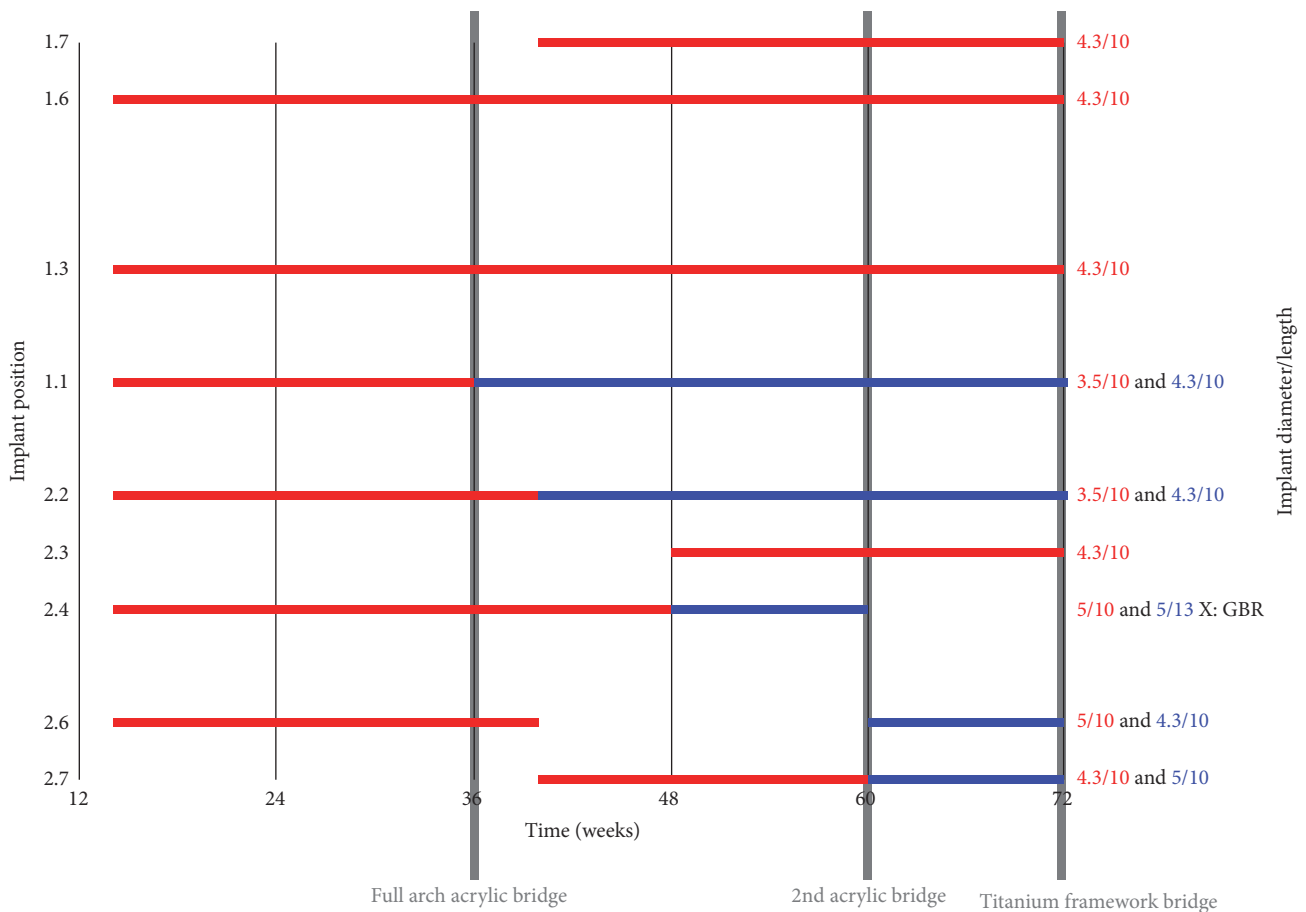


FIGURE 3: Time course of maxillary implant insertions and failures, ordered by position. In red a given implant first positioning and in blue the substituting implant. The initial planning included 6 implants with delayed loading. Five implants failed. The maxilla was finally rehabilitated at 72 weeks with a screwed titanium milled framework with acrylic composite teeth supported by 8 implants. No additional implant failures occurred.

the load transferred to implants in a clinical setting. In the present case, all implant failures occurred in absence of infection. They were likely due to the extreme mechanical loads caused by coexisting severe TD and OP.

The different survival rate of maxillary versus mandibular implants (57% versus 100%) may be related to different factors. The anatomical characteristics of the jaws arguably play a role, the mandible being mainly composed of cortical compact bone. The literature has consistently reported high implant success rates in the mandible, also employing immediate loading protocols. Maxillary bone is generally less favourable, due to its lower density and higher amount of trabecular bone [55, 56], which may hinder the rehabilitation techniques that are applied [57, 58]. Moreover, sinus lift interventions and grafted materials used may play an influence on implant outcome [59, 60]. In our case, implants placed in areas of sinus lifts were successful in 1.6 and 1.7 positions, while they failed on the opposite side in 2.6 and 2.7 positions.

Prosthetic aspects are of the utmost importance in determining the load transfer to implants. Unfortunately, as of today, there is no clear evidence-based concept of “ideal

occlusal scheme” to apply in implant-supported prosthodontics [61, 62]. A review assessed the importance of decreasing cuspal interferences, centralising forces along implant axes and avoiding cantilevers [63]. Klineberg recommended an occlusal design with narrow occlusal table, with central fossa loading in intercuspal contact and low cusp inclination [64, 65]. Occlusal canine guidance instead of group function in patients with OP has also been proposed [66].

Prosthetic breaks represent one of the commonest complications in the rehabilitation of patients suffering from oral parafunctions: it has been reported that ceramic crowns have high risk of fracture, especially when they articulate one with the other [67, 68]. Skalak first hypothesised that resilient prosthetic materials help reducing overloads and so recommended the use of acrylic resin teeth in implant-supported prostheses [69]. Others proposed to use a metal occlusal surface, which combine resiliency and resistance properties [70].

In this case, the patient frequently broke the unreinforced acrylic resin maxillary full arch prosthesis. Such loss of integrity may have represented a further cause of mechanical stress build-up at certain implant areas, together with the

inherent flexibility of this type of prosthesis. We believe that the latter characteristic was of the utmost importance, since implant failure stopped after installing a prosthesis with rigid titanium milled framework. This was probably due to a better load distribution among implants. It is also possible that specific implant surfaces may prove better suitability to withstand abnormal mechanical loads [71], and this aspect should be further explored. This could be consistent with a previous report by Amornvit et al. showing a successful implant rehabilitation with a balanced occlusal scheme, which may have compensated the excessive occlusal loading [36]. The patient's personal history as a heavy smoker should also be considered, as smoke has been shown to be related to risk for and severity of bruxism [72, 73] and may have affected the severity of the symptoms, but may also have impacted on implant survival as smoke has been associated with increased implant failure and complications [74–77].

We conclude that abnormal occlusal loads related to TD and OP played a key role in determining repeated prosthetic breaks and implant failures in the present case. The use of a bridge with a rigid framework stopped implant failures. Longitudinal controlled studies to investigate implant-supported rehabilitation in TD and other extreme load-generating movement disorders are needed.

Competing Interests

The authors have no conflict of interests to disclose.

References

- [1] P. J. Blanchet, P. H. Rompré, G. J. Lavigne, and C. Lamarche, "Oral dyskinesia: a clinical overview," *International Journal of Prosthodontics*, vol. 18, no. 1, pp. 10–19, 2005.
- [2] P. G. Aia, G. J. Revuelta, L. J. Cloud, and S. A. Factor, "Tardive dyskinesia," *Current Treatment Options in Neurology*, vol. 13, no. 3, pp. 231–241, 2011.
- [3] J. Muench and A. M. Hamer, "Adverse effects of antipsychotic medications," *American Family Physician*, vol. 81, no. 5, pp. 617–622, 2010.
- [4] D. Tarsy, C. Lungu, and R. J. Baldessarini, "Epidemiology of tardive dyskinesia before and during the era of modern antipsychotic drugs," *Handbook of Clinical Neurology*, vol. 100, pp. 601–616, 2011.
- [5] W. M. Glazer, "Review of incidence studies of tardive dyskinesia associated with typical antipsychotics," *Journal of Clinical Psychiatry*, vol. 61, no. 4, pp. 15–20, 2000.
- [6] W. M. Glazer, "Expected incidence of tardive dyskinesia associated with atypical antipsychotics," *Journal of Clinical Psychiatry*, vol. 61, supplement 4, pp. 21–26, 2000.
- [7] P. Turrone, G. Remington, and J. N. Nobrega, "The vacuous chewing movement (VCM) model of tardive dyskinesia revisited: is there a relationship to dopamine D₂ receptor occupancy?" *Neuroscience and Biobehavioral Reviews*, vol. 26, no. 3, pp. 361–380, 2002.
- [8] H. Tuppurainen, J. T. Kuikka, H. Viinamki, M. Husso, and J. Tiihonen, "Extrapyramidal side-effects and dopamine D_{2/3} receptor binding in substantia nigra," *Nordic Journal of Psychiatry*, vol. 64, no. 4, pp. 233–238, 2010.
- [9] R. J. Baldessarini and D. M. Gardner, "Incidence of extrapyramidal syndromes and tardive dyskinesia," *Journal of Clinical Psychopharmacology*, vol. 31, no. 3, pp. 382–384, 2011.
- [10] S. D. Botsaris and J. M. Sypek, "Paroxetine and tardive dyskinesia," *Journal of Clinical Psychopharmacology*, vol. 16, no. 3, pp. 258–259, 1996.
- [11] C. U. Correll and E. M. Schenk, "Tardive dyskinesia and new antipsychotics," *Current Opinion in Psychiatry*, vol. 21, no. 2, pp. 151–156, 2008.
- [12] P.-Y. Chen, P.-Y. Lin, S.-C. Tien, Y.-Y. Chang, and Y. Lee, "Duloxetine-related tardive dystonia and tardive dyskinesia: a case report," *General Hospital Psychiatry*, vol. 32, no. 6, pp. 646.e9–646.e11, 2010.
- [13] A. S. Rao and M. Camilleri, "Review article: metoclopramide and tardive dyskinesia," *Alimentary Pharmacology and Therapeutics*, vol. 31, no. 1, pp. 11–19, 2010.
- [14] M. B. Detweiler and G. J. Harpold, "Bupropion-induced acute dystonia," *Annals of Pharmacotherapy*, vol. 36, no. 2, pp. 251–254, 2002.
- [15] D. Kasantikul and B. Kanchanatawan, "Antipsychotic-induced tardive movement disorders: a series of twelve cases," *Journal of the Medical Association of Thailand*, vol. 90, no. 1, pp. 188–194, 2007.
- [16] K. Sansare, D. Singh, V. Khanna, and F. R. Karjodkar, "Risperidone-induced rabbit syndrome: an unusual movement disorder," *The New York State Dental Journal*, vol. 78, no. 5, pp. 44–46, 2012.
- [17] J. M. Ellison and P. Stanziani, "SSRI-associated nocturnal bruxism in four patients," *Journal of Clinical Psychiatry*, vol. 54, no. 11, pp. 432–434, 1993.
- [18] G. J. Lavigne, T. Kato, A. Kolta, and B. J. Sessle, "Neurobiological mechanisms involved in sleep bruxism," *Critical Reviews in Oral Biology and Medicine*, vol. 14, no. 1, pp. 30–46, 2003.
- [19] O. Sabuncuoglu, O. Ekinici, and M. Berkem, "Fluoxetine-induced sleep bruxism in an adolescent treated with buspirone: a case report," *Special Care in Dentistry*, vol. 29, no. 5, pp. 215–217, 2009.
- [20] G. J. Lavigne, S. Khoury, S. Abe, T. Yamaguchi, and K. Raphael, "Bruxism physiology and pathology: an overview for clinicians," *Journal of Oral Rehabilitation*, vol. 35, no. 7, pp. 476–494, 2008.
- [21] G. J. Lavigne, F. Lobbezoo, P. H. Rompré, T. A. Nielsen, and J. Montplaisir, "Cigarette smoking as a risk factor or an exacerbating factor for restless legs syndrome and sleep bruxism," *Sleep*, vol. 20, no. 4, pp. 290–293, 1997.
- [22] J. Ahlberg, M. Rantala, A. Savolainen et al., "Reported bruxism and stress experience," *Community Dentistry and Oral Epidemiology*, vol. 30, no. 6, pp. 405–408, 2002.
- [23] M. K. A. Van Selms, F. Lobbezoo, D. J. Wicks, H. L. Hamburger, and M. Naeije, "Craniomandibular pain, oral parafunctions, and psychological stress in a longitudinal case study," *Journal of Oral Rehabilitation*, vol. 31, no. 8, pp. 738–745, 2004.
- [24] D. Manfredini and F. Lobbezoo, "Role of psychosocial factors in the etiology of bruxism," *Journal of Orofacial Pain*, vol. 23, no. 2, pp. 153–166, 2009.
- [25] F. Lobbezoo and M. Naeije, "Dental implications of some common movement disorders: a concise review," *Archives of Oral Biology*, vol. 52, no. 4, pp. 395–398, 2007.
- [26] N. Tsiggos, D. Tortopidis, A. Hatzikyriakos, and G. Menexes, "Association between self-reported bruxism activity and occurrence of dental attrition, abfraction, and occlusal pits on natural teeth," *Journal of Prosthetic Dentistry*, vol. 100, no. 1, pp. 41–46, 2008.

- [27] U. Brägger, S. Aeschlimann, W. Bürgin, C. H. F. Hämmerle, and N. P. Lang, "Biological and technical complications and failures with fixed partial dentures (FPD) on implants and teeth after four to five years of function," *Clinical Oral Implants Research*, vol. 12, no. 1, pp. 26–34, 2001.
- [28] S. K. Praharaj, A. K. Jana, K. Goswami, P. R. Das, N. Goyal, and V. K. Sinha, "Salivary flow rate in patients with schizophrenia on clozapine," *Clinical Neuropharmacology*, vol. 33, no. 4, pp. 176–178, 2010.
- [29] J. Katsoulis, S. G. Nikitovic, S. Spreng, K. Neuhaus, and R. Mericske-Stern, "Prosthetic rehabilitation and treatment outcome of partially edentulous patients with severe tooth wear: 3-years results," *Journal of Dentistry*, vol. 39, no. 10, pp. 662–671, 2011.
- [30] P. Zoidis and G. Polyzois, "Removable dental prosthesis splint: an occlusal device for nocturnal bruxing partial denture users," *Journal of Prosthodontics*, vol. 22, no. 8, pp. 652–656, 2013.
- [31] M. Packer, V. Nikitin, T. Coward, D. M. Davis, and J. Fiske, "The potential benefits of dental implants on the oral health quality of life of people with Parkinson's disease," *Gerodontology*, vol. 26, no. 1, pp. 11–18, 2009.
- [32] T. D. F. Borges, F. A. Mendes, T. R. de Oliveira, V. L. Gomes, C. J. do Prado, and F. D. das Neves, "Mandibular overdentures with immediate loading: satisfaction and quality of life," *The International Journal of Prosthodontics*, vol. 24, no. 6, pp. 534–539, 2011.
- [33] F. Lobbezoo, J. E. I. G. Brouwers, M. S. Cune, and M. Naeije, "Dental implants in patients with bruxing habits," *Journal of Oral Rehabilitation*, vol. 33, no. 2, pp. 152–159, 2006.
- [34] D. Manfredini, C. E. Poggio, and F. Lobbezoo, "Is bruxism a risk factor for dental implants? A systematic review of the literature," *Clinical Implant Dentistry and Related Research*, vol. 16, no. 3, pp. 460–469, 2014.
- [35] A. G. Payne and L. Carr, "Can edentulous patients with orofacial dyskinesia be treated successfully with implants? A case report," *The Journal of the Dental Association of South Africa*, vol. 51, no. 2, pp. 67–70, 1996.
- [36] P. Amornvit, D. Rokaya, and S. Bajracharya, "Prosthetic management of complete edentulous patient with oromandibular dyskinesia: a case report," *Academic Journal of Oral and Dental Medicine*, vol. 1, pp. 1–4, 2014.
- [37] F. Lobbezoo, J. Van Der Zaag, and M. Naeije, "Bruxism: its multiple causes and its effects on dental implants—an updated review," *Journal of Oral Rehabilitation*, vol. 33, no. 4, pp. 293–300, 2006.
- [38] D. Manfredini, M. B. Bucci, V. B. Sabattini, and F. Lobbezoo, "Bruxism: overview of current knowledge and suggestions for dental implants planning," *Cranio—Journal of Craniomandibular Practice*, vol. 29, no. 4, pp. 304–312, 2011.
- [39] B. R. Chrcanovic, J. Kisch, T. Albrektsson, and A. Wennerberg, "Bruxism and dental implant failures: a multilevel mixed effects parametric survival analysis approach," *Journal of Oral Rehabilitation*, vol. 43, no. 11, pp. 813–823, 2016.
- [40] K. Yadav, A. Nagpal, S. K. Agarwal, and A. Kochhar, "Intricate assessment and evaluation of effect of bruxism on long-term survival and failure of dental implants: a comparative study," *The Journal of Contemporary Dental Practice*, vol. 17, no. 8, pp. 670–674, 2016.
- [41] M. G. Kelleher, B. J. Scott, and S. Djemal, "Case report: complications of rehabilitation using osseointegrated implants—tardive dyskinesia," *The European Journal of Prosthodontics and Restorative Dentistry*, vol. 6, no. 4, pp. 133–136, 1998.
- [42] S. M. Heckmann, J. G. Heckmann, and H.-P. Weber, "Clinical outcomes of three Parkinson's disease patients treated with mandibular implant overdentures," *Clinical Oral Implants Research*, vol. 11, no. 6, pp. 566–571, 2000.
- [43] J. Jackowski, J. Andrich, H. Kappeler, A. Zollner, P. Jöhren, and T. Müller, "Implant-supported denture in a patient with Huntington's disease: interdisciplinary aspects," *Special Care in Dentistry*, vol. 21, no. 1, pp. 15–20, 2001.
- [44] M. Peñarrocha, J. M. Sanchis, J. Rambla, and M. A. Sánchez, "Oral rehabilitation with osseointegrated implants in a patient with oromandibular dystonia with blepharospasm (brueghel's syndrome): a patient history," *International Journal of Oral and Maxillofacial Implants*, vol. 16, no. 1, pp. 115–117, 2001.
- [45] H. Satcher, "Prosthetic dentistry in the treatment of movement disorders: dyskinesias and other neurological abnormalities," *Medical Hypotheses*, vol. 56, no. 3, pp. 318–320, 2001.
- [46] E. Deniz, A. M. Kokat, and A. Noyan, "Implant-supported overdenture in an elderly patient with Huntington's disease," *Gerodontology*, vol. 28, no. 2, pp. 157–160, 2011.
- [47] E. Engel, G. Gomez-Roman, and D. Axmann-Krcmar, "Effect of occlusal wear on bone loss and periosteal value of dental implants," *International Journal of Prosthodontics*, vol. 14, no. 5, pp. 444–450, 2001.
- [48] M. Davarpanah, M. Caraman, B. Jakubowicz-Kohen, M. Kebir-Quelin, and S. Szmukler-Moncler, "Prosthetic success with a maxillary immediate-loading protocol in the multiple-risk patient," *International Journal of Periodontics and Restorative Dentistry*, vol. 27, no. 2, pp. 161–169, 2007.
- [49] S. Nagasawa, K. Hayano, T. Niino et al., "Nonlinear stress analysis of titanium implants by finite element method," *Dental Materials Journal*, vol. 27, no. 4, pp. 633–639, 2008.
- [50] G. E. Salvi and U. Brägger, "Mechanical and technical risks in implant therapy," *International Journal of Oral & Maxillofacial Implants*, vol. 24, supplement, pp. 69–85, 2009.
- [51] N. Alsabeeha, M. Atieh, and A. G. T. Payne, "Loading protocols for mandibular implant overdentures: a systematic review with meta-analysis," *Clinical Implant Dentistry and Related Research*, vol. 12, supplement 1, pp. e28–e38, 2010.
- [52] T. Grandi, G. Garuti, P. Guazzi, L. Tarabini, and A. Forabosco, "Survival and success rates of immediately and early loaded implants: 12-month results from a multicentric randomized clinical study," *Journal of Oral Implantology*, vol. 38, no. 3, pp. 239–249, 2012.
- [53] Y.-T. Hsu, J.-H. Fu, K. Al-Hezaimi, and H.-L. Wang, "Biomechanical implant treatment complications: a systematic review of clinical studies of implants with at least 1 year of functional loading," *The International Journal of Oral & Maxillofacial Implants*, vol. 27, no. 4, pp. 894–904, 2012.
- [54] T.-J. Ji, J. Y. K. Kan, K. Rungcharassaeng, P. Roe, and J. L. Lozada, "Immediate loading of maxillary and mandibular implant-supported fixed complete dentures: A 1- to 10-year retrospective study," *Journal of Oral Implantology*, vol. 38, no. 1, pp. 469–476, 2012.
- [55] R. Glauser, A. Rée, A. Lundgren, J. Gottlow, C. H. Hämmerle, and P. Schärer, "Immediate occlusal loading of Brånemark implants applied in various jawbone regions: a prospective, 1-year clinical study," *Clinical implant dentistry and related research*, vol. 3, no. 4, pp. 204–213, 2001.
- [56] G. M. Raghoebar, B. Friberg, I. Grunert, J. A. Hobkirk, G. Tepper, and I. Wendelhag, "3-Year prospective multicenter study on one-stage implant surgery and early loading in the edentulous

- mandible,” *Clinical Implant Dentistry and Related Research*, vol. 5, no. 1, pp. 39–46, 2003.
- [57] S. Lumetti, U. Consolo, C. Galli et al., “Fresh-frozen bone blocks for horizontal ridge augmentation in the upper maxilla: 6-month outcomes of a randomized controlled trial,” *Clinical Implant Dentistry and Related Research*, vol. 16, no. 1, pp. 116–123, 2014.
- [58] S. Lumetti, C. Galli, E. Manfredi et al., “Correlation between density and resorption of fresh-frozen and autogenous bone grafts,” *BioMed Research International*, vol. 2014, Article ID 508328, 6 pages, 2014.
- [59] W. Att, J. Bernhart, and J. R. Strub, “Fixed rehabilitation of the edentulous maxilla: possibilities and clinical outcome,” *Journal of Oral and Maxillofacial Surgery*, vol. 67, no. 11, pp. 60–73, 2009.
- [60] A. Barone, B. Orlando, P. Tonelli, and U. Covani, “Survival rate for implants placed in the posterior maxilla with and without sinus augmentation: a comparative cohort study,” *Journal of Periodontology*, vol. 82, no. 2, pp. 219–226, 2011.
- [61] B. J. Jackson, “Occlusal principles and clinical applications for endosseous implants,” *Journal of Oral Implantology*, vol. 29, no. 5, pp. 230–234, 2003.
- [62] Y. Kim, T.-J. Oh, C. E. Misch, and H.-L. Wang, “Occlusal considerations in implant therapy: clinical guidelines with biomechanical rationale,” *Clinical Oral Implants Research*, vol. 16, no. 1, pp. 26–35, 2005.
- [63] M. R. Wood and S. G. Vermilyea, “A review of selected dental literature on evidence-based treatment planning for dental implants: report of the Committee on Research in Fixed Prosthodontics of the Academy of Fixed Prosthodontics,” *Journal of Prosthetic Dentistry*, vol. 92, no. 5, pp. 447–462, 2004.
- [64] I. Klineberg, D. Kingston, and G. Murray, “The bases for using a particular occlusal design in tooth and implant-borne reconstructions and complete dentures,” *Clinical Oral Implants Research*, vol. 18, no. S3, pp. 151–167, 2007.
- [65] I. J. Klineberg, M. Trulsson, and G. M. Murray, “Occlusion on implants—is there a problem?” *Journal of Oral Rehabilitation*, vol. 39, no. 7, pp. 522–537, 2012.
- [66] E. Göre and G. Evlioğlu, “Assessment of the effect of two occlusal concepts for implant-supported fixed prostheses by finite element analysis in patients with bruxism,” *The Journal of Oral Implantology*, vol. 40, no. 1, pp. 68–75, 2014.
- [67] R. P. Kinsel and D. Lin, “Retrospective analysis of porcelain failures of metal ceramic crowns and fixed partial dentures supported by 729 implants in 152 patients: patient-specific and implant-specific predictors of ceramic failure,” *Journal of Prosthetic Dentistry*, vol. 101, no. 6, pp. 388–394, 2009.
- [68] O. Komiyama, F. Lobbezoo, A. De Laat et al., “Clinical management of implant prostheses in patients with bruxism,” *International Journal of Biomaterials*, vol. 2012, Article ID 369063, 6 pages, 2012.
- [69] R. Skalak, “Biomechanical considerations in osseointegrated prostheses,” *The Journal of Prosthetic Dentistry*, vol. 49, no. 6, pp. 843–848, 1983.
- [70] W.-S. Lin, C. Ercoli, R. Lowenguth, L. M. Yerke, and D. Morton, “Oral rehabilitation of a patient with bruxism and cluster implant failures in the edentulous maxilla: a clinical report,” *Journal of Prosthetic Dentistry*, vol. 108, no. 1, pp. 1–8, 2012.
- [71] S. Lumetti, E. Manfredi, S. Ferraris et al., “The response of osteoblastic MC3T3-E1 cells to micro- and nano-textured, hydrophilic and bioactive titanium surfaces,” *Journal of Materials Science: Materials in Medicine*, vol. 27, no. 4, article no. 68, 2016.
- [72] D. Feu, F. Catharino, C. C. A. Quintão, and M. A. De Oliveira Almeida, “A systematic review of etiological and risk factors associated with bruxism,” *Journal of Orthodontics*, vol. 40, no. 2, pp. 163–171, 2013.
- [73] E. Bertazzo-Silveira, C. M. Kruger, I. Porto De Toledo et al., “Association between sleep bruxism and alcohol, caffeine, tobacco, and drug abuse,” *The Journal of the American Dental Association*, vol. 147, no. 11, pp. 859.e4–866.e4, 2016.
- [74] D. Nitzan, A. Mamlider, L. Levin, and D. Schwartz-Arad, “Impact of smoking on marginal bone loss,” *International Journal of Oral and Maxillofacial Implants*, vol. 20, no. 4, pp. 605–609, 2005.
- [75] S. DeLuca and G. Zarb, “The effect of smoking on osseointegrated dental implants. Part II: peri-implant bone loss,” *International Journal of Prosthodontics*, vol. 19, no. 6, pp. 560–566, 2006.
- [76] L. Levin, R. Hertzberg, S. Har-Nes, and D. Schwartz-Arad, “Long-term marginal bone loss around single dental implants affected by current and past smoking habits,” *Implant Dentistry*, vol. 17, no. 4, pp. 422–429, 2008.
- [77] S. Vervaeke, B. Collaert, S. Vandeweghe, J. Cosyn, E. Deschepper, and H. De Bruyn, “The effect of smoking on survival and bone loss of implants with a fluoride-modified surface: a 2-year retrospective analysis of 1106 implants placed in daily practice,” *Clinical Oral Implants Research*, vol. 23, no. 6, pp. 758–766, 2012.