



## Relapsing polychondritis causing breathlessness: Two case reports

Song-Yu Zhai, Yu-Hao Zhang, Ru-Yan Guo, Jie-Wen Hao, Shu-Xin Wen

### Specialty type:

Otorhinolaryngology

### Provenance and peer review:

Unsolicited article; Externally peer reviewed.

### Peer-review model:

Single blind

### Peer-review report's scientific quality classification

Grade A (Excellent): 0  
Grade B (Very good): 0  
Grade C (Good): C, C  
Grade D (Fair): 0  
Grade E (Poor): 0

**P-Reviewer:** Raposo A, Spain;  
Wang CR, Taiwan

**Received:** March 16, 2022

**Peer-review started:** March 16, 2022

**First decision:** May 12, 2022

**Revised:** May 24, 2022

**Accepted:** July 11, 2022

**Article in press:** July 11, 2022

**Published online:** August 16, 2022



**Song-Yu Zhai**, Department of Otorhinolaryngology Head and Neck Surgery, Xi'an Fourth Hospital, Xi'an 710004, Shaanxi Province, China

**Yu-Hao Zhang, Shu-Xin Wen**, Department of Otorhinolaryngology Head and Neck Surgery, Shanxi Bethune Hospital, Taiyuan 030000, Shanxi Province, China

**Ru-Yan Guo**, Department of Otorhinolaryngology Head and Neck Surgery, The First People's Hospital of Nanyang, Nanyang 473000, Henan Province, China

**Jie-Wen Hao**, Department of Otorhinolaryngology Head and Neck Surgery, The Third Clinical College of Shanxi Medical University, Taiyuan 030000, Shanxi Province, China

**Corresponding author:** Shu-Xin Wen, MD, Chief Doctor, Department of Otorhinolaryngology Head and Neck Surgery, Shanxi Bethune Hospital, No. 99 Longcheng Street, Taiyuan 030000, Shanxi Province, China. [wensxsx@163.com](mailto:wensxsx@163.com)

### Abstract

#### BACKGROUND

Relapsing polychondritis is a rare multisystem autoimmune disease that mainly involves systemic cartilage and proteoglycan-rich tissues. If the larynx and trachea are involved, the patient's condition deteriorates rapidly. When relapsing polychondritis becomes more advanced, the airways collapse and treatment is difficult, rendering a poor prognosis. Therefore, the diagnosis method, treatment strategy and prognosis of relapsing polychondritis with larynx and trachea involvement need to be elucidated to improve clinicians' awareness of the disease.

#### CASE SUMMARY

A man and a woman were admitted because of breathlessness. Relapsing polychondritis was diagnosed after a series of accessory examinations. They were both treated with glucocorticoids and immunosuppressants, and underwent tracheotomy as their breathing difficulties could not be relieved by the medication.

#### CONCLUSION

The two cases highlight the importance of the timely diagnosis, full evaluation and initiating individualized treatment of relapsing polychondritis with larynx and trachea involvement. Laryngoscopy, bronchoscopy and pathological examination are helpful in diagnosis of this disease.

**Key Words:** Relapsing polychondritis; Larynx; Trachea; Case report

**Core Tip:** Relapsing polychondritis is a rare multisystem autoimmune disease, if the larynx and trachea are involved, the patient's condition deteriorates rapidly. We here report two cases of relapsing polychondritis involving the larynx and trachea. Necessary accessory examinations, timely diagnosis and full evaluation, and initiating individualized treatment are important to reduce the mortality rate and improve patient prognosis.

**Citation:** Zhai SY, Zhang YH, Guo RY, Hao JW, Wen SX. Relapsing polychondritis causing breathlessness: Two case reports. *World J Clin Cases* 2022; 10(23): 8360-8366

**URL:** <https://www.wjgnet.com/2307-8960/full/v10/i23/8360.htm>

**DOI:** <https://dx.doi.org/10.12998/wjcc.v10.i23.8360>

## INTRODUCTION

Relapsing polychondritis is a rare, multisystem autoimmune disease that mainly involves systemic cartilage and proteoglycan-rich tissues such as those of the ears, nose, larynx and trachea, articular cartilage, heart, blood vessels, inner ear, cornea, sclera and kidneys[1]. Relapsing polychondritis usually occurs in middle-aged and young people, and the peak age of onset is 40 years. About 50% of relapsing polychondritis patients have laryngeal and tracheal involvement[2,3]. The etiology and pathogenesis of relapsing polychondritis remain unclear. It is believed that its occurrence and development are related to genetic and environmental factors and immunological changes. In terms of treatment, glucocorticoids and immunosuppressants (such as methotrexate and cyclophosphamide) are mainly used[4]. If the larynx and trachea are involved, breathing difficulties occur, thereby rendering a poor prognosis. Relapsing polychondritis has various clinical manifestations, and thus, can be easily misdiagnosed and missed in clinical practice. Here, we report the clinical diagnosis and treatment of two patients with relapsing polychondritis, mainly with laryngeal and tracheal cartilage involvement. The patients were misdiagnosed in another hospital. We report their specific accessory findings to improve clinicians' awareness of the disease.

## CASE PRESENTATION

### Chief complaints

**Case 1:** A 31-year-old man with a 4-mo history of hoarseness and 3-mo history of dyspnea was admitted on March 23, 2020.

**Case 2:** A 59-year-old woman was admitted on December 7, 2018 because of 5 mo of cough, sputum and hoarseness, in addition to breathing difficulties.

### History of present illness

**Case 1:** Four months before admission, there was no obvious cause for his symptoms. One month later, after a cold, there was exacerbation of his hoarseness. At the same time, the patient developed a cough with a small amount of white sputum. Throat tuberculosis was suggested at another hospital, but antituberculosis treatment, such as rifampin and amroxolol, showed no significant improvement in his condition. The patient's dyspnea symptoms worsened after 5 d, and stridor could be heard during calm breathing, while slight retraction of three fossae was observed.

**Case 2:** Five months before admission to hospital because of fatigue, the patient developed dry cough, which was obvious at night, and exhibited no obvious improvement after anti-inflammatory treatment. Cough with white sticky sputum and breathing difficulties presented 2 mo later, making her unable to lie flat at night. After treatment for bronchitis, pneumonia and asthma in other hospitals, her symptoms exhibited no improvement. The day before admission to our hospital, her breathing difficulty was exacerbated and she experienced a sudden faint.

### History of past illness

**Cases 1 and 2:** The patients reported no notable past illness.

### **Personal and family history**

**Cases 1 and 2:** Personal or family medical history was unremarkable.

### **Physical examination**

**Case 1:** No redness or congestion was found in both eyes. The nose, auricle and limb joints exhibited no swelling deformities or collapse. By indirect laryngoscopy, a well-lifted epiglottis could be identified without redness or swelling, the rima glottidis could not be seen.

**Case 2:** The patient exhibited obvious exhaustion, with the lungs wheezing to auscultation, the nose cartilage had collapsed and she had a saddle nose, no congestion and swelling in the eyes, and normal movement of limbs and joints. Chest CT revealed middle lobe infection in the right lung and mild dilation of the middle lobe and lower lobe of the right lung.

### **Laboratory examinations**

**Case 1:** Erythrocyte sedimentation rate was 65 mm/h and rheumatoid factors were normal.

**Case 2:** Erythrocyte sedimentation rate was 45 mm/h and rheumatoid factors were normal.

### **Imaging examinations**

**Case 1:** After assessing the patient's condition, the initial suspicion was Adam's apple nucleus tuberculosis, so a tuberculin test, cervical and thoracic soft tissue computed tomography (CT) and electronic fiber nasolaryngoscopy were performed. Tuberculin tests were negative. Neck CT revealed stenosis of the cavum larynges with thickening of the ventricular band and vocal cords (**Figure 1A**). No tuberculosis foci were observed. Electronic fiber nasopharyngolaryngoscopy revealed bilateral vocal band mucosa edema and glottal stenosis (**Figure 2A**). So Adam's apple nucleus tuberculosis was excluded. The pathological examination showed that fibrous tissue was visible in the cartilage, and there was chronic inflammatory cell infiltration in the fibrous interstitium (**Figure 3**). Congestion, edema and thickening of the middle and lower tracheal mucosa were observed by bedside bronchoscopy (**Figure 4**).

**Case 2:** On December 27, 2 wk after removing the endotracheal tube, laryngoscopy and bronchoscopy were conducted. The vocal tape mucosa was slightly thicker, the rima glottidis could not be exposed (**Figure 2B**), and the tracheal ring was not obvious. In addition, she had expiratory phase tracheal collapse. Chest CT revealed new atelectasis of the lower left lung (**Figure 1B**).

---

## **FINAL DIAGNOSIS**

### **Case 1**

Relapsing polychondritis was considered based on the patient's symptoms of hoarseness, presence of dyspnea and laryngeal and tracheal mucosa lesion, and the pathological results, and according to the Damiani Standard, article 2.

### **Case 2**

Relapsing polychondritis was considered based on the symptoms of dyspnea and saddle nose, the laryngoscopy and bronchoscopy results, and according to the Rose Standard.

---

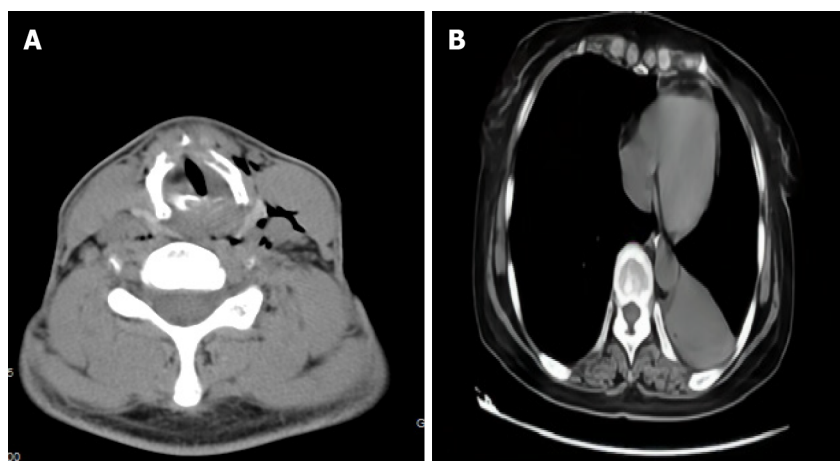
## **TREATMENT**

### **Case 1**

After anti-infection and atomization treatment, the symptoms of dyspnea still exhibited no significant improvement. On March 31, a tracheotomy and biopsy were performed. Due to postoperative dyspnea, the patient had difficulty being weaned off the breathing machine, and was transferred to the intensive care unit (ICU). After diagnosis, 3 d of 0.5 g/d shock therapy was used, and low-dose methylprednisolone and mycophenolate mofetil were administered outside the hospital on a long-term basis.

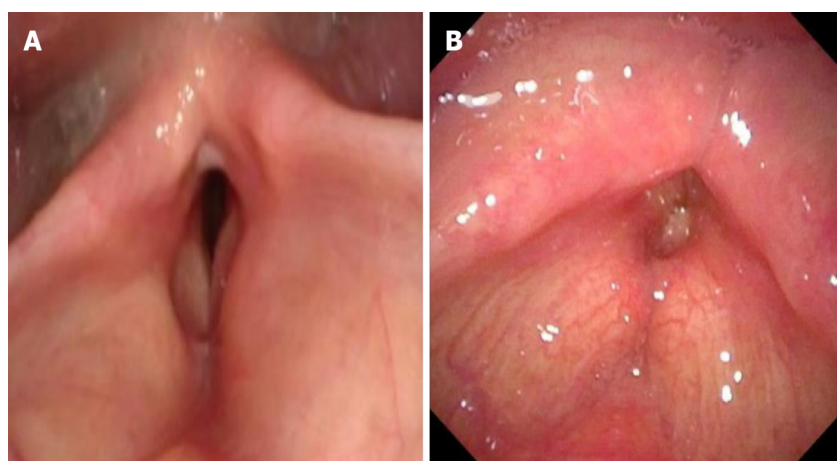
### **Case 2**

After 7 d of treatment, including methylprednisolone (80 mg/d), spasmolysis, anti-infection, and correction of electrolyte disorder, the patient suddenly experienced difficulty in breathing when she inhaled. The patient was transferred to the ICU for tracheal intubation. However, there was obvious tracheal stenosis, which made intubation difficult. Finally, pipe # 5.5 was inserted. The patient was then treated with glucocorticoid combined with methotrexate (10 mg/wk). On January 21, she was discharged from hospital in improved condition. Two weeks after discharge, the patient was admitted



DOI: 10.12998/wjcc.v10.i23.8360 Copyright ©The Author(s) 2022.

**Figure 1 Computed tomography.** A: The neck computed tomography of case 1 showed throat stenosis and thickened ventricular and vocal bands; B: The chest computed tomography of case 2 showed new atelectasis of the lower left lung.



DOI: 10.12998/wjcc.v10.i23.8360 Copyright ©The Author(s) 2022.

**Figure 2 The electronic fiber nasolaryngoscopy.** A: The electronic fiber nasolaryngoscopy of case 1 showed bilateral vocal cord mucosal edema and the appearance of the vocal cords shows as the change of fish abdomen. Narrow glottis, submucosal edema and stenosis were also seen; B: The electronic fiber nasolaryngoscopy of case 2. Two weeks after tracheal extubation, electronic fiber nasolaryngoscopy showed no bilateral ventricular edema, narrow throat cavity, and rima glottidis.

to the hospital again with breathing difficulties. Methylprednisolone plus methotrexate were administered intravenously in combination with auxiliary endotracheal intubation. A tracheotomy was performed due to tube extraction difficulties. Long-term postoperative administration of methylprednisolone and methotrexate was proposed.

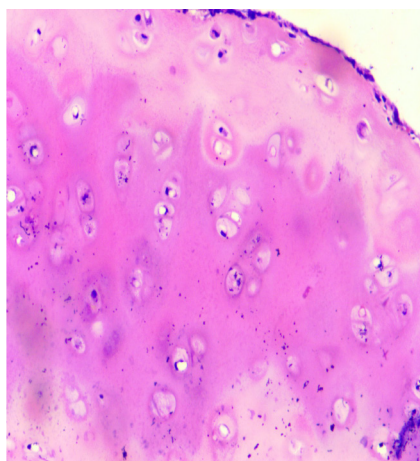
## OUTCOME AND FOLLOW-UP

### Case 1

During 13 mo of follow-up, the patient was hospitalized again with dyspnea and pulmonary inflammation, during which, the patient received large-dose hormone therapy and his condition improved.

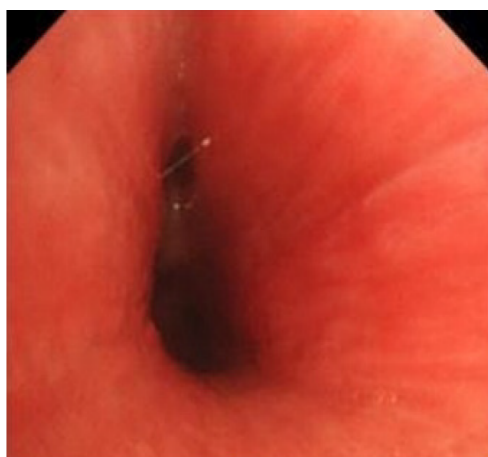### Case 2

During 2 years of follow-up, due to respiratory difficulties and repeated pulmonary inflammation, the patient was hospitalized 6 times in the rheumatism department and the respiratory department.



DOI: 10.12998/wjcc.v10.i23.8360 Copyright ©The Author(s) 2022.

**Figure 3** The pathological examination of case 1 of HE 100× showed fibrotic tissue around chondrocytes, chronic inflammatory cell infiltration among the chondrocytes.



DOI: 10.12998/wjcc.v10.i23.8360 Copyright ©The Author(s) 2022.

**Figure 4** The fiber bronchoscopy of case 2 demonstrated obvious tracheal mucosal congestion and edema, unclear tracheal cartilage ring, and diffuse stenosis of the lumen.

## DISCUSSION

The initial symptoms of relapsing polychondritis vary according to the affected organs. In patients with laryngotracheal involvement, relapsing polychondritis is easily confused with diseases such as Adam's apple tuberculosis, bronchitis, and asthma due to atypical clinical symptoms, and the condition of patients can deteriorate rapidly with the involvement of the larynx and airways. After relapsing polychondritis reaches the advanced stage, the airway collapses and treatment is difficult, rendering a poor prognosis for patients. About 5% of relapsing polychondritis patients are children. Children with laryngeal and tracheal involvement of the disease are more common. It is reported that 91% of children have laryngeal involvement[5,6]. Because children's laryngeal cavity is narrow and submucosal tissue is loose, it is easier to cause laryngeal cavity blockage and suffocation. Han *et al*[7] reported two cases of recurrent polychondritis in children; both of whom underwent tracheotomy due to dyspnea. Some studies have proved that patients with airway involvement are more likely to be admitted to ICU due to airway collapse and lung infection[2]. With the extension of follow-up time, patients with airway involvement have a progressively higher mortality rate[8]. In this study, both patients were admitted to the ICU due to airway collapse. Recurrent polychondritis may involve all parts of the airways. One study reported that about 50% of patients have airway involvement in the course of the disease, with 20% of patients experiencing upper airway collapse, and the potential involvement of upper and lower airway cartilage[9]. In this study, both the atmospheric and upper airways were involved. The existing diagnostic criteria are mainly based on clinical performance, as shown in Table 1[10-13]. The Damiani Standard[11] and Rose Standard[13] were referred to for diagnosis of the two patients in the present study. At present, there is no diagnostic standard sensitive enough to reach 100%[13]. Imaging examin-



Table 1 Existing diagnostic standards for relapsing polychondritis

Ref.	Symptoms	Diagnostic requirements
McAdam <i>et al</i> [10]	Bilateral auricle chondrolitis; eye inflammation; nasal chondrolitis; nonaggressive polyarthritis; larynx and/or tracheochondrolitis; cochlear implant and /or vestibular damage	Patient with $\geq 3$ symptoms
Damiani <i>et al</i> [11]	A: Patients meeting $\geq 3$ standards in the McAdam standard; B: $> 1$ , plus pathological confirmation; C: lesions involving $\geq 2$ anatomical sites, effective with glucocorticoids or dapsone	Patient meeting any one of the criteria
Michet <i>et al</i> [12]	Main manifestations: repeated cartilage inflammation of bilateral auricle; nasal chondrositis; larynx and/or bronchobronchial chondroitis. Secondary manifestations: inflammation of the eye; impaired hearing; impaired vestibular function; serum-negative arthritis	Diagnosed with two main manifestations or one main plus two secondary manifestations
Rose <i>et al</i> [13]	Main manifestations: repeated cartilage inflammation in both auricle; nasal cartilage; eye inflammation; larynx and/or bronchobronchial chondroitis. Secondary manifestations: hearing impairment; impaired vestibular function; serum-negative arthritis	Diagnosed with two main manifestations or one main plus two secondary manifestations

ations, such as CT, positron emission tomography-CT, tracheobronchoscopy, electronic fiber nasolaryngoscopy, and lung function and pathology could be included as auxiliary diagnostic criteria to improve early diagnostic sensitivity[14,15].

When a patient is suffering from relapsing polychondritis mainly with laryngeal and tracheal involvement, the general and systemic treatments are the same for patients with relapsing polychondritis with involvement of other regions. Methylprednisolone is an effective drug for relapsing polychondritis, and the dose should be adjusted according to the condition of the patient. Low doses of glucocorticoid can be administered to patients with mild symptoms, while high doses should be administered, and even methylprednisolone impact treatment (1 mg/kg daily) to patients with severe symptoms. Most patients with laryngotracheal involvement need to use methylprednisolone on a long-term basis[16]. An immunosuppressor can be used when glucocorticoid control is poor. For the short-term rapid relief of patients with dyspnea symptoms, bronchotracheal intubation or tracheotomy is the necessary treatment for upper respiratory collapse, but the scope and extent of tracheal collapse should be fully evaluated before surgery, and various types of tracheal catheter should be prepared. In the present study, tracheotomy was performed for Case 1 because the patient's breathing difficulties could not be relieved. After being diagnosed with relapsing polychondritis, the patient received treatment with large doses of methylprednisolone plus immunosuppressor, which controlled the patient's dyspnea symptoms. Treatment of Case 2 was adjusted after diagnosis, and after addition of immunosuppressive therapy, the patient's condition was controlled. However, due to further breathing difficulties and symptoms that were difficult to relieve, tracheotomy was performed. For patients who require long-term airway management to control dyspnea, tracheobronchial external fixation, laryngeal tracheal reconstruction, tracheal sleeve resection, and balloon dilation with adjustable pressure and security performance can be performed[17]. Some scholars reported different surgical methods on 11 cases of airway stenosis caused by relapsing polychondritis. Nine patients underwent the surgery of sternum tongue muscle flap or costal cartilage to widen laryngeal tracheal reconstruction, one underwent long-term T tube placement; and one underwent routine balloon dilation. All patients had complete recovery of respiratory and swallowing functions after 2–7 years[18]. It has also been suggested that for patients with recurrent polychondritis with bronchial involvement causing diffuse airway stenosis, nasal positive pressure ventilation is useful[19].

## CONCLUSION

Relapsing polychondritis involving the larynx and trachea can be easily misdiagnosed or missed due to the atypical symptoms. However, the patient's condition can deteriorate fast, and the prognosis is poor. To reduce the mortality rate and improve the prognosis of patients, clinicians should improve awareness of relapsing polychondritis, perform laryngoscopy, bronchoscopy and pathological examination as a necessity, make timely diagnosis and full evaluation, and initiate individualized treatment.

## FOOTNOTES

**Author contributions:** Zhai SY designed the study and drafted the manuscript; Zhang YH designed the study and interpreted data; Guo RY participated in the data collection; Wen SX designed the study and supervise the manuscript writing; all authors have read and approved the final manuscript.

**Informed consent statement:** Informed written consent was obtained from the patient for publication of this report and any accompanying images.

**Conflict-of-interest statement:** The authors declare that they have no conflicts of interest.

**CARE Checklist (2016) statement:** The authors have read the CARE Checklist (2016), and the manuscript was prepared and revised according to the CARE Checklist (2016).

**Open-Access:** This article is an open-access article that was selected by an in-house editor and fully peer-reviewed by external reviewers. It is distributed in accordance with the Creative Commons Attribution NonCommercial (CC BY-NC 4.0) license, which permits others to distribute, remix, adapt, build upon this work non-commercially, and license their derivative works on different terms, provided the original work is properly cited and the use is non-commercial. See: <https://creativecommons.org/licenses/by-nc/4.0/>

**Country/Territory of origin:** China

**ORCID number:** Shu-Xin Wen [0000-0002-8377-2481](https://orcid.org/0000-0002-8377-2481).

**S-Editor:** Ma YJ

**L-Editor:** A

**P-Editor:** Ma YJ

## REFERENCES

- Chen N, Wang Z. Progress in the pathology and pathogenesis of Relapsing Polychondritis. *Zhonghua Fengshibing Xue Zazhi* 2019; **3**: 207-211 [DOI: [10.4103/injr.injr\\_6\\_19](https://doi.org/10.4103/injr.injr_6_19)]
- Dion J, Costedoat-Chalumeau N, Sène D, Cohen-Bittan J, Leroux G, Dion C, Francès C, Piette JC. Relapsing Polychondritis Can Be Characterized by Three Different Clinical Phenotypes: Analysis of a Recent Series of 142 Patients. *Arthritis Rheumatol* 2016; **68**: 2992-3001 [PMID: [27331771](https://pubmed.ncbi.nlm.nih.gov/27331771/) DOI: [10.1002/art.39790](https://doi.org/10.1002/art.39790)]
- Taş H, Birkent H, Gerek M. Three Cases of Relapsing Polycondritis with Isolated Laryngotracheal Stenosis. *Türk Arch Otorhinolaryngol* 2017; **55**: 77-82 [PMID: [29392060](https://pubmed.ncbi.nlm.nih.gov/29392060/) DOI: [10.5152/tao.2017.2236](https://doi.org/10.5152/tao.2017.2236)]
- Duan JN, Gao JF, Zhang LY. Progress in diagnosis and treatment of recurrent polychondritis. *Zhonghua Fengshibing Xue Zazhi* 2019; **5**: 356-360 [DOI: [10.1055/s-009-44672](https://doi.org/10.1055/s-009-44672)]
- Wang ZG, Cui L, Gao Y, Chen N. Clinical manifestation of child-onset relapsing polychondritis. *Zhonghua Fengshibing Xue Zazhi* 2014; **10**: 682-685 [DOI: [10.31579/2692-9562/032](https://doi.org/10.31579/2692-9562/032)]
- Fonseca AR, de Oliveira SK, Rodrigues MC, Aymoré IL, Domingues RC, Sztajnbock FR. Relapsing polychondritis in childhood: three case reports, comparison with adulthood disease and literature review. *Rheumatol Int* 2013; **33**: 1873-1878 [PMID: [22210275](https://pubmed.ncbi.nlm.nih.gov/22210275/) DOI: [10.1007/s00296-011-2336-6](https://doi.org/10.1007/s00296-011-2336-6)]
- Han S, Yu D, Gu TT, Liu Y, Wen LJ. [Two cases of relapsing polycondritis in childhood]. *Zhonghua Er Ke Za Zhi* 2019; **57**: 955-956 [PMID: [31795563](https://pubmed.ncbi.nlm.nih.gov/31795563/) DOI: [10.3760/cma.j.issn.0578-1310.2019.12.011](https://doi.org/10.3760/cma.j.issn.0578-1310.2019.12.011)]
- Zhang L, Yun S, Wu T, He Y, Guo J, Han L, Lu J, Liu X, Yang R, Zhang S, Li T, Liu S. Clinical patterns and the evolution of relapsing polychondritis based on organ involvement: a Chinese retrospective cohort study. *Orphanet J Rare Dis* 2021; **16**: 225 [PMID: [34001193](https://pubmed.ncbi.nlm.nih.gov/34001193/) DOI: [10.1186/s13023-021-01861-x](https://doi.org/10.1186/s13023-021-01861-x)]
- Ernst A, Rafeq S, Boisselle P, Sung A, Reddy C, Michaud G, Majid A, Herth FJF, Trentham D. Relapsing polychondritis and airway involvement. *Chest* 2009; **135**: 1024-1030 [PMID: [19017885](https://pubmed.ncbi.nlm.nih.gov/19017885/) DOI: [10.1378/chest.08-1180](https://doi.org/10.1378/chest.08-1180)]
- McAdam LP, O'Hanlan MA, Bluestone R, Pearson CM. Relapsing polychondritis: prospective study of 23 patients and a review of the literature. *Medicine (Baltimore)* 1976; **55**: 193-215 [PMID: [775252](https://pubmed.ncbi.nlm.nih.gov/775252/)]
- Damiani JM, Levine HL. Relapsing polychondritis--report of ten cases. *Laryngoscope* 1979; **89**: 929-946 [PMID: [449538](https://pubmed.ncbi.nlm.nih.gov/449538/)]
- Michet CJ Jr, McKenna CH, Luthra HS, O'Fallon WM. Relapsing polychondritis. Survival and predictive role of early disease manifestations. *Ann Intern Med* 1986; **104**: 74-78 [PMID: [3484422](https://pubmed.ncbi.nlm.nih.gov/3484422/) DOI: [10.7326/0003-4819-104-1-74](https://doi.org/10.7326/0003-4819-104-1-74)]
- Rose T, Schneider U, Bertolo M, Klotzsche J, Casteleyn V, Biesen R, Burmester GR, Hiepe F. Observational study and brief analysis of diagnostic criteria in relapsing polychondritis. *Rheumatol Int* 2018; **38**: 2095-2101 [PMID: [30084004](https://pubmed.ncbi.nlm.nih.gov/30084004/) DOI: [10.1007/s00296-018-4121-2](https://doi.org/10.1007/s00296-018-4121-2)]
- Kamada H, Takanami K, Toyama Y, Saito M, Takase K. 18F-FDG PET/CT Imaging of Vasculitis Complicated With Relapsing Polychondritis. *Clin Nucl Med* 2020; **45**: e327-e328 [PMID: [32433175](https://pubmed.ncbi.nlm.nih.gov/32433175/) DOI: [10.1097/RLU.0000000000003060](https://doi.org/10.1097/RLU.0000000000003060)]
- Vitale A, Sota J, Rigante D, Lopalco G, Molinaro F, Messina M, Iannone F, Cantarini L. Relapsing Polychondritis: an Update on Pathogenesis, Clinical Features, Diagnostic Tools, and Therapeutic Perspectives. *Curr Rheumatol Rep* 2016; **18**: 3 [PMID: [26711694](https://pubmed.ncbi.nlm.nih.gov/26711694/) DOI: [10.1007/s11926-015-0549-5](https://doi.org/10.1007/s11926-015-0549-5)]
- de Montmollin N, Dusser D, Lorut C, Dion J, Costedoat-Chalumeau N, Mouthon L, Chassagnon G, Revel MP, Puéchal X. Tracheobronchial involvement of relapsing polychondritis. *Autoimmun Rev* 2019; **18**: 102353 [PMID: [31323366](https://pubmed.ncbi.nlm.nih.gov/31323366/) DOI: [10.1016/j.autrev.2019.102353](https://doi.org/10.1016/j.autrev.2019.102353)]
- Zhai S, Guo R, Zhang C, Yin H, Wang B, Wen S. Clinical analysis of relapsing polychondritis with airway involvement. *J Laryngol Otol* 2022; **1-16** [PMID: [35105388](https://pubmed.ncbi.nlm.nih.gov/35105388/) DOI: [10.1017/S002221512200038X](https://doi.org/10.1017/S002221512200038X)]
- Oryoji D, Ono N, Himeji D, Yoshihiro K, Kai Y, Matsuda M, Tsukamoto H, Ueda A. Sudden Respiratory Failure due to Tracheobronchomalacia by Relapsing Polychondritis, Successfully Rescued by Multiple Metallic Stenting and Tracheostomy. *Intern Med* 2017; **56**: 3369-3372 [PMID: [29021454](https://pubmed.ncbi.nlm.nih.gov/29021454/) DOI: [10.2169/internalmedicine.8778-16](https://doi.org/10.2169/internalmedicine.8778-16)]
- Yu C, Joosten SA. Relapsing polychondritis with large airway involvement. *Respirol Case Rep* 2020; **8**: e00501 [PMID: [31741739](https://pubmed.ncbi.nlm.nih.gov/31741739/) DOI: [10.1002/rcr2.501](https://doi.org/10.1002/rcr2.501)]



Published by **Baishideng Publishing Group Inc**  
7041 Koll Center Parkway, Suite 160, Pleasanton, CA 94566, USA

**Telephone:** +1-925-3991568

**E-mail:** [bpgoffice@wjgnet.com](mailto:bpgoffice@wjgnet.com)

**Help Desk:** <https://www.f6publishing.com/helpdesk>

<https://www.wjgnet.com>

