


CASE REPORT

Sudden maternal hypoxemia during elective cesarean section in a woman with placenta previa

Takeshi Umazume¹ , Satoshi Hayasaka², Fumi Kato³, Satoshi Ishikawa¹, Mamoru Morikawa¹ & Hisanori Minakami¹

¹Department of Obstetrics, Hokkaido University Graduate School of Medicine, Sapporo, Japan

²Department of Anesthesia, Hokkaido University Hospital, Sapporo, Japan

³Department of Diagnostic and Interventional Radiology, Hokkaido University Hospital, Sapporo, Japan

Correspondence

Takeshi Umazume, Department of Obstetrics, Hokkaido University Graduate School of Medicine, Kita-ku N14 W6, Sapporo 060-8638, Japan. Tel: +81-11-706-5941; Fax: +81-11-706-7711; E-mail: takeuma@med.hokudai.ac.jp

Funding Information

No sources of funding were declared for this study.

Received: 27 May 2017; Revised: 29 June 2017; Accepted: 26 July 2017

Clinical Case Reports 2017; 5(10): 1668–1671

doi: 10.1002/ccr3.1142

Introduction

Amniotic fluid embolism (AFE) remains one of the most devastating conditions in obstetric practice, with an incidence of approximately 1 in 40,000 deliveries and a reported mortality rate ranging from 20% to 60% [1]. The clinical similarities of this condition to other types of acute critical maternal illness and the broad spectrum of disease severity hamper progress in our understanding of this syndrome. Sudden hypoxemia, hypotension, and coagulopathy with onset during labor or immediately after delivery are hallmarks for a diagnosis of amniotic fluid embolism [2]. However, the mechanisms leading to hypoxemia in AFE are not well understood, although pulmonary hypertension at the initial phase of AFE has been documented in some cases of AFE [3–8].

Risk factors for AFE include cesarean section with or without labor and placenta previa [9–13]; for example, women with cesarean section without labor and those with placenta previa were reported to have 8.1-fold and 10.5-fold higher risks of AFE, respectively, compared to

Key Clinical Message

There have been no reports regarding imaging-documented bronchospasm in patients with amniotic fluid embolism (AFE). In a woman with scheduled cesarean section for placenta previa, transient bronchospasm and pulmonary hypertension were documented explaining a sudden drop in SpO₂. Mild AFE was the most likely diagnosis in this patient.

Keywords

Amniotic fluid embolism, anaphylaxis, C1 esterase inhibitor, maternal mortality, pulmonary thromboembolism.

those without the respective characteristics in New South Wales, Australia [13]. Here, we describe a woman that experienced dry cough with a subsequent gradual decrease in blood pressure prior to a sudden fall in PaO₂ 45 min after childbirth with scheduled cesarean section for placenta previa at term. The patient gave informed consent for this presentation.

Case Presentation

A 28-year-old nulliparous Japanese woman with prepregnancy body mass index of 23.6 kg/m² underwent scheduled cesarean section for placenta previa at gestational week 37-3/7. Her medical history was unremarkable, and she had never experienced an asthmatic attack. Her pregnancy was uneventful. In the morning of cesarean delivery, combined spinal and epidural analgesia was given, and cesarean section was started at 09:26 with latex-free procedures. She gave birth to a healthy female infant weighing 2555 g with 1- and 5-min Apgar scores of 7 and 9, respectively, at 09:32. Blood loss including amniotic

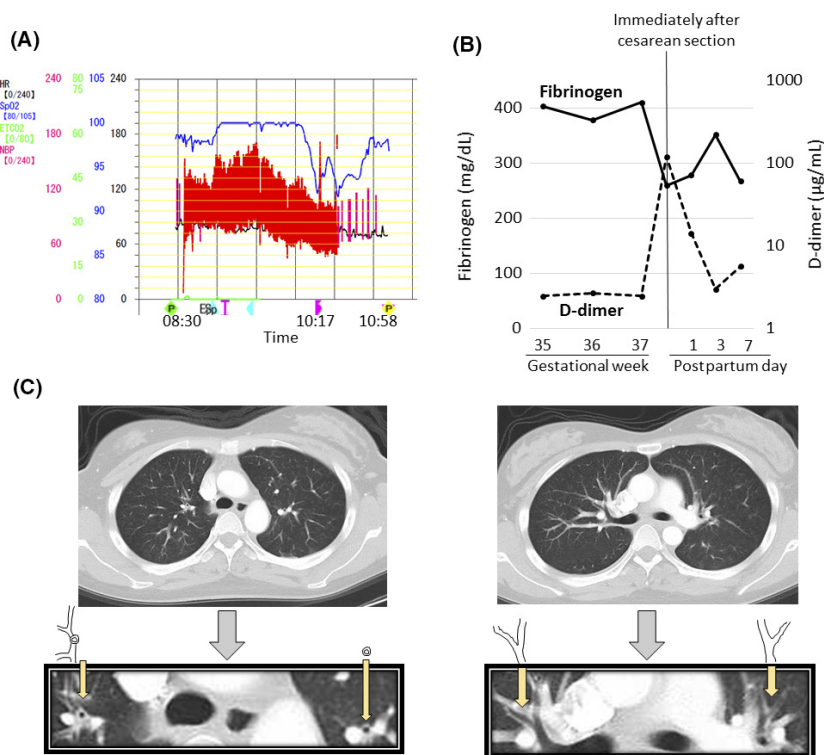


Figure 1. Findings in a woman with abrupt hypoxemia during cesarean section. (A) Changes in SpO₂ (indicated in blue), blood pressure (in red), and heart rate (in black) around the hypoxemic episode. (B) Perinatal changes in blood fibrinogen and D-dimer levels. (C) Computed tomography performed at 11:33 indicating thickened bronchus walls. Dry cough occurred at 10:00 and blood pressure 123/62 mmHg at 10:07 fell to 98/50 mmHg at 10:17. Hypoxemia occurred suddenly at 10:17, and normalization of SpO₂ occurred at 10:58. PaO₂ was 113, 225, and 68 mmHg, at 08:59, 09:50, and 10:20, respectively.

fluid was 1430 mL until the time of abdominal wall closure, at which time a hypoxemic event evidenced by a sudden fall in SpO₂ reading (from 100% to 92% under 6.0 L inhaled oxygen via a mask) occurred at 10:17 and lasted for 41 min until 10:58 (Fig. 1A). Dry cough occurred several times at 10:00 and a gradual decrease in blood pressure began at 10:07, reaching 98/50 mmHg at 10:17, preceding the event in this patient. PaO₂ was actually low (68 mmHg at 10:20), and the results of blood tests at 10:45 were as follows: hemoglobin concentration, 9.4 g/dL; platelet count, $182 \times 10^9/L$; fibrinogen, 259 mg/dL; antithrombin activity, 69%; high D-dimer level, 119 µg/mL (Fig. 1B); subnormal level of C1 esterase inactivator, 68%; and normal levels of complement components (C3, 94 mg/dL; C4, 31 mg/dL; and CH50, 45 U/mL). Drugs and fluid replacement given in this patient before and after the event are listed in Table 1. Transthoracic echocardiography performed during hypoxemia (at 10:45) suggested pulmonary hypertension with leftward deviation of interventricular septum (photographs of echocardiograms were not available). Chest computed tomography (CT) scan performed at 11:33 indicated thickened walls of bronchi and no thrombi, suggesting

Table 1. Drugs and fluid replacement given in this patient during cesarean section.

Until onset of hypoxemia (at 10:17) after entering the operating room (at 08:24)
20 mg of lidocaine at 08:51 into the epidural space
10 mg of bupivacaine (hyper) and 10 µg of fentanyl at 08:55 into the subdural space
100 and 50 µg of iv phenylephrine at 09:33 and 09:53, respectively
0.2 mg of iv methylergometrine at 09:33
10 mg of iv metoclopramide at 10:02
10 units of iv oxytocin and 10 units of oxytocin into uterine muscle at 09:33
1100 mL of iv bicarbonate Ringer's solution
500 mL of iv hydroxyethyl starch solution (Voluven® Fresenius Kabi Japan, Tokyo, Japan)
Until recovery from hypoxemia (at 10:58) after onset of hypoxemia (at 10:17)
100 mL of iv autologous blood starting at 10:27
350 mL of iv bicarbonate Ringer's solution

iv, intravenous.

bronchospasm but not pulmonary thromboembolism (Fig. 1C). Neither coagulopathy, uterine atony, nor shock ensued. The postoperative clinical course was uneventful,

and the patient and her daughter left hospital on postpartum day 8.

Discussion

This patient developed sudden hypoxemia at the time of abdominal wall closure preceded by dry coughing and a gradual decrease in blood pressure after uneventful elective cesarean section at term for placenta previa. Echocardiography during hypoxemia suggested pulmonary hypertension, and chest CT 32 min after recovery from hypoxemia indicated thickened bronchus walls suggesting bronchospasm. Thus, this patient may have suffered from hypoxemia caused by pulmonary hypertension and narrowing of the airways. It was speculated that narrowing of larger airway canals would have been seen if chest CT had been performed during hypoxemia.

Bronchospasm and pulmonary hypertension have a common pathology, that is, smooth muscle constriction of trachea/bronchioles and pulmonary arteries/arterioles, respectively [14]. Recent case reports demonstrated pulmonary hypertension on echocardiography in patients with acute phase AFE [3–8]. The pathophysiology leading to AFE appears to involve an abnormal maternal response to fetal tissue exposure associated with breaches of the maternal–fetal physiological barrier during parturition [2]. Bronchospasm and or laryngeal edema can occur in patients with anaphylaxis [15]. As trigger(s) of smooth muscle constriction were not specified in this patient, differential diagnoses included mild AFE and mild anaphylaxis against undetermined substance(s) given during cesarean section. However, mild AFE was the most likely diagnosis based on circumstantial evidence, including scheduled cesarean section for placenta previa under latex-free conditions (the usual procedure in our institution) and timing of the episode, that is, 45 min after childbirth; the former is a well-known risk factor for AFE [9–13], and the latter is a well-known danger period for the occurrence of AFE [2]. In addition, this patient coughed preceding the event, and coughing is listed as a clinical sign of AFE [12].

Coagulopathy and hypofibrinogenemia are characteristic clinical features of typical AFE [2]. The hypoxemia resolved spontaneously (at 10:58) without any specific treatment 41 min later, and coagulopathy was not seen, but the increase/decrease in D-dimer/fibrinogen was marked in this patient. The lack of coagulopathy and transient hypoxemia was reasonable if this patient had mild AFE.

The decrease in blood pressure preceding hypoxemia was not explained by vascular smooth muscle constriction. Causes of hypotension in typical AFE patients are

not well understood. It is unknown whether the decrease in blood pressure prior to hypoxemia is relevant to AFE, and it was possible that the decrease in blood pressure merely reflected blood loss in this patient. The hypotension of typical AFE can be considered as originating from left ventricular failure following pulmonary hypertension [11] and/or hypovolemia due to massive bleeding caused by coagulopathy. Our patient did not exhibit left ventricular dysfunction or coagulopathy.

To our knowledge, there have been no reports regarding imaging-documented bronchospasm in AFE patients. Further studies are needed to determine whether bronchospasm in addition to pulmonary hypertension is a contributing factor leading to hypoxemia in AFE patients.

Authorship

TU and HM: drafted the manuscript. TU, SH, FK, SI, and MM: treated the patient. All authors: participated in discussion about the patient and approved the final manuscript.

Conflict of Interest

None declared.

References

- Clark, S. L. 2014. Amniotic fluid embolism. *Obstet. Gynecol.* 123:337–348.
- Clark, S. L., G. D. V. Hankins, D. A. Dudley, G. A. Dildy, and T. F. Porter. 1995. Amniotic fluid embolism: analysis of the national registry. *Am. J. Obstet. Gynecol.* 172:1158–1167.
- Shechtman, M., A. Ziser, R. Markovits, and B. Rozenberg. 1999. Amniotic fluid embolism: early findings of transesophageal echocardiography. *Anesth. Analg.* 89:1456–1458.
- Rufforny-Doudenko, I., C. Sipp, and B. M. Shehata. 2002. Pathologic quiz case. A 30-year-old woman with severe disseminated intravascular coagulation during delivery. *Arch. Pathol. Lab. Med.* 126:869–870.
- Stanten, R. D., L. I. Iverson, T. M. Daugharty, S. M. Lovett, C. Terry, and E. Blumenstock. 2003. Amniotic fluid embolism causing catastrophic pulmonary vasoconstriction: diagnosis by transesophageal echocardiogram and treatment by cardiopulmonary bypass. *Obstet. Gynecol.* 102:496–498.
- James, C. F., N. G. Feinglass, D. M. Menke, S. F. Grinton, and T. J. Papadimos. 2004. Massive amniotic fluid embolism: diagnosis aided by emergency transesophageal echocardiography. *Int. J. Obstet. Anesth.* 13:279–283.

7. McDonnell, N. J., B. O. Chan, and R. W. Frengley. 2007. Rapid reversal of critical haemodynamic compromise with nitric oxide in a parturient with amniotic fluid embolism. *Int. J. Obstet. Anesth.* 16:269–273.
8. Evans, S., B. Brown, M. Mathieson, and S. Tay. 2014. Survival after an amniotic fluid embolism following the use of sodium bicarbonate. *BMJ Case Rep.* 2014: bcr2014204672.
9. Fitzpatrick, K. E., D. Tuffnell, J. J. Kurinczuk, and M. Knight. 2016. Incidence, risk factors, management and outcomes of amniotic-fluid embolism: a population-based cohort and nested case–control study. *BJOG* 123:100–109.
10. Kramer, M. S., J. Rouleau, T. F. Baskett, K. S. Joseph, and Maternal Health Study Group of the Canadian Perinatal Surveillance System. 2006. Amniotic-fluid embolism and medical induction of labour: a retrospective, population-based cohort study. *Lancet* 368:1444–1448.
11. Conde-Agudelo, A., and R. Romero. 2009. Amniotic fluid embolism: an evidence-based review. *Am. J. Obstet. Gynecol.* 201:445. e1–13.
12. Kaur, K., M. Bhardwaj, P. Kumar, S. Singhal, T. Singh, and S. Hooda. 2016. Amniotic fluid embolism. *J. Anaesthesiol. Clin. Pharmacol.* 32:153–159.
13. Roberts, C., C. Algert, M. Knight, and J. Morris. 2010. Amniotic fluid embolism in an Australian population-based cohort. *BJOG* 117:1417–1421.
14. Said, S. I., S. A. Hamidi, and L. Gonzalez Bosc. 2010. Asthma and pulmonary arterial hypertension: do they share a key mechanism of pathogenesis? *Eur. Respir. J.* 35:730–734.
15. National Institute for Health and Care Excellence. NICE clinical guideline [CG134], Anaphylaxis: assessment and referral after emergency treatment. Available at URL: <https://www.nice.org.uk/guidance/cg134> (accessed 22 March 2017).