

Psoriasiform eruptions secondary to phosphoinositide 3-kinase inhibition



Anna K. Dewan, MD,^a Sameer Gupta, MD,^b Daniel Q. Bach, MD,^b Saagar Jadeja, BS,^c
 Scott Granter, MD,^c Ann LaCase, MD,^d Robin Joyce, MD, MMSc,^c
 Matthew S. Davids, MD, MMSc,^d Victor Huang, MD,^b and Nicole R. LeBoeuf, MD, MPH^b
Nashville, Tennessee, and Boston, Massachusetts

Key words: cutaneous toxicity; immunotherapy; phosphoinositide 3-kinase inhibitors; psoriasis; small molecule inhibitors.

INTRODUCTION

The phosphoinositide 3-kinase (PI3K) pathway has key regulatory roles in cell survival, proliferation, and differentiation.¹ It is among the most frequently altered pathways in human cancers, and PI3K inhibitors are used to treat a variety of malignancies.¹ Class I PI3K, the best studied of the PI3K classes, is a heterodimer with both regulatory and catalytic subunits, the latter of which exists in 4 distinct isoforms (α , β , γ , and δ).² The α and β isoforms are expressed ubiquitously, but γ and δ isoform expression is mainly found on leukocytes and cells of the adaptive immune system.² PI3K inhibitors include pan-class I PI3K inhibitors, isoform-specific class I PI3K inhibitors, and dual PI3K-mechanistic target of rapamycin (mTOR) inhibitors. Dermatologic toxicities in patients on PI3K inhibitors have not been characterized to date. We report on 4 patients on PI3K inhibitors who had psoriasiform cutaneous eruptions.

REPORT OF CASES

A 59-year-old man with chronic lymphocytic leukemia (CLL) and progressive disease 24 months after completing 6 cycles of fludarabine, cyclophosphamide, and rituximab (FCR) was initiated on the combination of ibrutinib and a targeted p110 δ inhibitor. About 3 months after starting therapy, a solitary, scaling, nonpruritic plaque developed on his right leg. Fifteen months after starting therapy, he suffered a blistering sunburn. Within 2 weeks, a new, red,

Abbreviations used:

CLL:	chronic lymphocytic leukemia
FCR:	fludarabine, cyclophosphamide, rituximab
mTOR:	mechanistic target of rapamycin
PI3K:	phosphoinositide 3-kinase

scaling rash developed in the distribution of the burn on his arms and legs that subsequently generalized to the trunk. He had no personal or family history of psoriasis. At the time of presentation to the dermatology clinic, he had psoriasiform, erythematous, well-demarcated papules, and large plaques on his shoulders, arms, and bilateral lower extremities in a strikingly photo-distributed pattern (Fig 1, A and B). Punch biopsy of the left thigh found psoriasiform epidermal hyperplasia with mild spongiosis, confluent parakeratosis, and intraepidermal as well as intracorneal neutrophils with rare eosinophils (Fig 2, A). Both ibrutinib and the p110 δ inhibitor were held; the patient was started on triamcinolone 0.1% cream twice daily to the trunk and extremities. The eruption continued to spread to involve the face, scalp, back, chest, and soles. The patient then started acitretin, 10 mg daily, with clobetasol 0.05% ointment twice daily to affected areas on the trunk, and desonide 0.05% cream to affected areas on the face. Photoprotective behaviors were strictly enforced. His psoriasis improved significantly, and both drugs were

From the Department of Dermatology, Vanderbilt University Medical Center^a; the Department of Dermatology, The Center for Cutaneous Oncology, Dana-Farber Cancer Institute and Brigham and Women's Hospital^b; the Department of Pathology, Brigham and Women's Hospital^c; the Department of Medical Oncology, Dana-Farber Cancer Institute^d; and the Department of Medical Oncology, Beth Israel Deaconess Medical Center.^e

Funding sources: None.

Conflicts of interest: Dr Davids has served on scientific advisory boards for Gilead, TG Therapeutics, Infinity Pharmaceuticals, Janssen, Pharmacyclics, and Genentech. The other authors have no conflicts of interest to disclose.

Correspondence to: Nicole R. LeBoeuf, MD, MPH, Department of Dermatology, The Centers for Melanoma and Cutaneous Oncology, Dana-Farber Cancer Institute, 375 Longwood Avenue, Boston, MA 02115. E-mail: nleboeuf@partners.org.
 JAAD Case Reports 2019;5:401-5.

2352-5126

© 2018 by the American Academy of Dermatology, Inc. Published by Elsevier, Inc. This is an open access article under the CC BY-NC-ND license (<http://creativecommons.org/licenses/by-nc-nd/4.0/>).

<https://doi.org/10.1016/j.jidcr.2018.03.005>

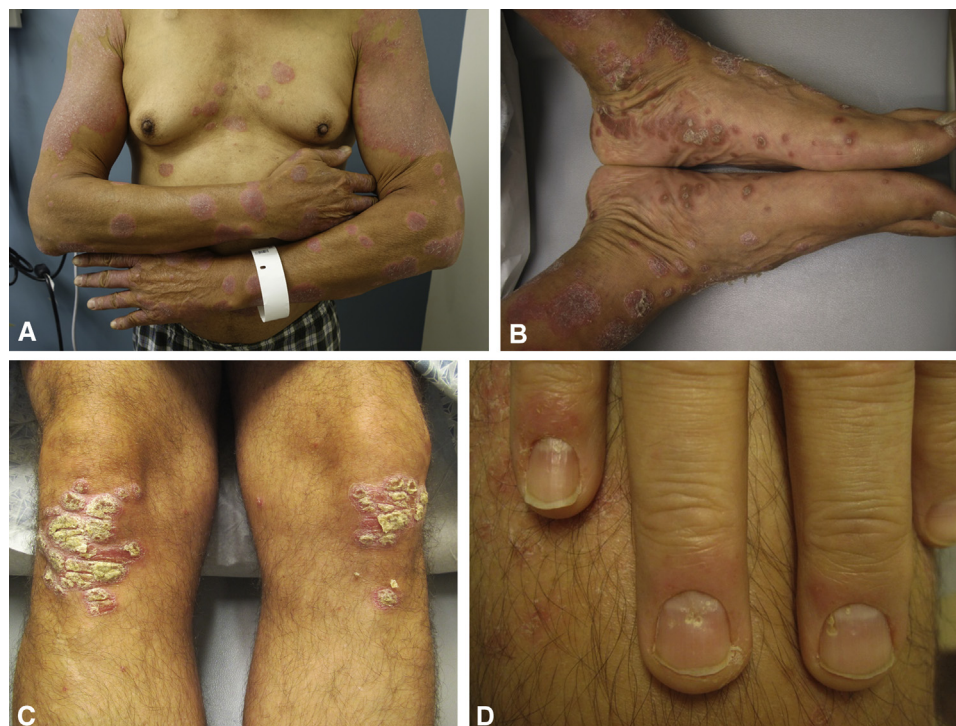

Fig 1. Clinical photographs of patients 1 and 2. **A**, Patient 1. Diffuse, discrete, annular, thin pink plaques with adherent scale on the trunk and extremities. **B**, Patient 1. Pink-to-orange hyperkeratotic papules and plaques with adherent scale on the bilateral ankles and plantar feet. **C**, Patient 2. Psoriasiform pink plaques of the bilateral lower extremities with overlying adherent, micaceous scale. **D**, Patient 2. Scattered fingernail pits.

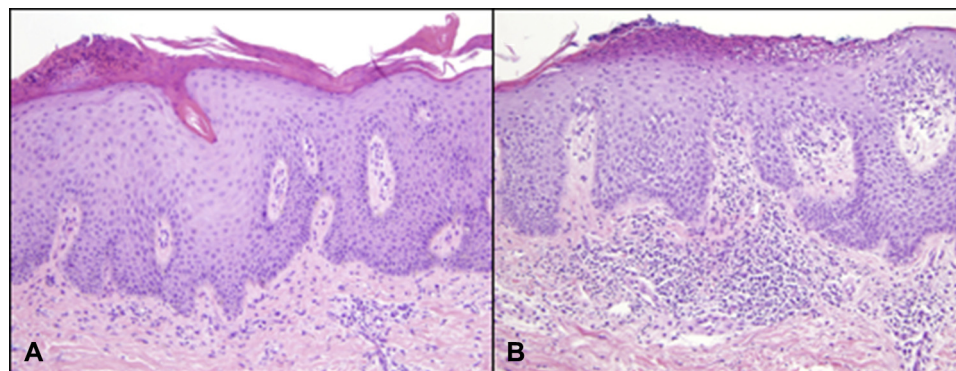


Fig 2. Histopathology for patients 1 and 2. **A**, Patient 1. Acanthosis with mounds of parakeratosis and subcorneal neutrophilic pustules. **B**, Patient 2. Acanthosis with mounds of parakeratosis. (**A** and **B**, Hematoxylin-eosin stain; original magnification $\times 40$.)

restarted without incident. The patient had a complete response to the CLL treatment. Cases 2 through 4 are presented in [Table I](#).

DISCUSSION

PI3K inhibitors are a relatively novel class of small molecule inhibitors currently approved for the treatment of chronic lymphocytic leukemia/small

lymphocytic lymphoma and follicular lymphoma; they are also under investigation for the treatment of a variety of solid tumors.¹ PI3K inhibitors are unique drugs in that their mechanism of action, depending on isoform(s) targeted, ranges from direct inhibition of the PI3K pathway to indirect anticancer effects such as inhibiting angiogenesis, disrupting interactions between cancer cells and tumor stroma, and

Table I. Clinical presentations and outcomes of patients 1 through 4

Patient no.	Malig	Sex	Age	Isoforms	Simultaneous anticancer drugs	Time to Sxs	Hx Pso	Clinical presentation	Pathologic condition	Treatment(s)	Cutaneous response	Therapy interruption	Cancer response
1	CLL	M	59	p110δ	Ibrutinib	17 mo	No	Erythematous papules coalescing into large plaques on arms and legs after blistering sunburn (Fig 1, A). Spread to involve face, scalp, trunk, gluteal cleft, and soles (Fig 1, B).	Psoriasiform epidermal hyperplasia with mild spongiosis, confluent parakeratosis, intraepidermal and intracorneal neutrophils. Rare eos. Negative PAS. Fig 2, A.	Face: desonide 0.05% cream bid prn. Trunk: triamcinolone 0.1% cream bid prn. For continued progression, transitioned to clobetasol 0.05% ointment bid to body and soles. Added acitretin 10 mg/d po. Photoprotective behaviors.	Good response to potent topical steroids and low-dose oral acitretin.	Yes, but successfully restarted with topical/oral psoriasis regimen.	CR
2	CLL	M	57	p110δ/γ	FCR q 4 weeks × 6 months with PI3K inhibitor, then PI3K inhibitor alone	15 d	Yes	Diffuse guttate papules, erythematous plaques with micaceous scale on the bilateral knees (Fig 1, C), nail pitting and oil spots (Fig 1, D), intertriginous involvement, palmoplantar pustulosis.	Psoriasiform dermatitis with inflamed parakeratosis. No eos. Negative PAS. Fig 2, B.	Palms/soles: clobetasol 0.05% ointment qam, tazarotene 0.1% gel qhs. Body: triamcinolone 0.1% cream bid prn. Skin folds: tacrolimus 0.1% ointment bid prn.	Good response with topicals. Improvement when PI3K inhibitor reduced to 15 mg/d for neutropenia.	Yes, but restarted successfully at lower dose (15 mg/d) with psoriasis regimen	PR
3	SLL/CLL	M	81	p110δ	Rituximab	5 mo	No	Erythematous thin papules coalescing into plaques with micaceous scale over the trunk and extremities.	Mixed spongiotic and suprabasilar acantholysis with superficial dermal lymphocytes and rare eos.	Halobetasol 0.05% cream bid prn.	Good response to topicals initially; with subsequent flare, PI3K inhibitor stopped.	Yes	PR

Continued

Table 1. Cont'd

Patient no.	Malign	Sex	Age	Isoforms	Simultaneous anticancer drugs	Time to Sxs	Hx Pso	Clinical presentation	Pathologic condition	Treatment(s)	Cutaneous response	Therapy interruption	Cancer response
4	MZL	M	72	p110δ	None	3 mo	No	Erythematous thin plaques in gluteal cleft and inguinal folds. Evolved into erythematous, discrete, thin plaques with micaceous scale on neck, chest, extremities, scalp.	N/A	Body: triamcinolone 0.1% cream bid prn. Scalp: ketoconazole shampoo TIV and fluocinolone 0.01% soln bid prn.	Good response to topicals; resolved with stopping PI3K inhibitor for colitis and PCP pna.	No	PD

CR, Complete response; eos, eosinophils; Hx, history; Malign, malignancy; MZL, marginal zone lymphoma; PAS, periodic acid-Schiff; prn, as needed; PD, progressive disease; pna, pneumonia; PR, partial response; Pso, psoriasis; qam, every morning; qhs, every evening; SLL, small lymphocytic leukemia; Sxs, symptoms; TIV, 3 times a week.

enhancing effector T-cell responses.³ Although cutaneous eruptions secondary to PI3K inhibitors have been reported in up to 58% of patients on selective p110δ inhibitors and 27% of patients on pan-PI3K inhibitors, these eruptions have not been further characterized to date.^{4,5}

We report on 4 patients with psoriasiform eruptions arising 15 days to 17 months after starting a PI3K inhibitor. The patient who had a psoriasiform eruption at the shortest interval after exposure to a PI3K inhibitor had a previous history of psoriasis. Although we cannot definitively prove that the PI3K inhibitors were the cause of the eruptions, 2 patients had clear improvement with dose reduction, and 1 eruption resolved entirely after discontinuing the PI3K inhibitor. Fludarabine, cyclophosphamide, rituximab, and ibrutinib, the concomitantly exposed drugs in our patients, have not been associated with psoriasiform dermatitis, despite their common use in leukemia treatment. In the patient with Koebnerization after a sunburn, the photosensitivity itself was ultimately attributed to the patient also taking ibrutinib, which is known to inhibit epidermal growth factor receptor.⁶ Epidermal growth factor receptor inhibitor-associated photosensitivity has been well described in the literature, and PI3K inhibitors have not been associated with photosensitivity to date.^{7,8}

It is notable that IL-22, a cytokine known to contribute to the pathogenesis of psoriasis, has been found to be upregulated by PI3K pathway activation.⁹⁻¹¹ Further, both p110δ and p110γ inhibitors have been found to reduce IL-17 production from peripheral blood monocyte cells of psoriatic or healthy donors.¹² It is therefore hypothesized that PI3K inhibitors may actually treat inflammatory skin disorders. These in vitro studies, however, do not take into account the global immunologic effects of PI3K inhibition. In particular, p110δ blockade inhibits regulatory T cells, promoting antitumor effector CD8⁺ T cells.¹³ Side effects of p110δ inhibitors include colitis, pneumonitis, and hepatitis associated with increased CD8⁺ T-cell infiltrates, decreased circulating regulatory T cells, and improvement with corticosteroids.^{4,14,15} Global p110δ inhibition may result in worsening or new autoinflammatory skin disorders such as psoriasis caused by unregulated, nonspecific T-cell activation.

Given the clinical findings in our patients, typical psoriasis therapies were instituted for treatment. Three of 4 patients were able to successfully control cutaneous symptoms with topical treatments alone; 1 patient did well with the addition of oral acitretin. Two patients continued on dose-reduced PI3K inhibitor therapy with good response. In keeping with

the psoriasis-specific therapeutic ladder, we suggest first-line skin-directed therapy for psoriasisiform cutaneous toxicities with topical steroids, calcineurin inhibitors, retinoids, and vitamin D analogs. If cutaneous findings are extensive, narrow-band ultraviolet B may be trialed, given its efficacy in psoriasis, with careful consideration taken to avoid concomitant photosensitizing medications. For refractory disease, acitretin, apremilast, and methotrexate are all systemic therapies that can be considered as adjuncts in the appropriate patient. Despite the recommendation for the use of prednisone for eruptions involving greater than 30% body surface area in many clinical trials, except in very rare cases of erythroderma, systemic steroids are not part of the management algorithm for psoriasis.

These cases emphasize the importance of early dermatologic evaluation to specifically classify the clinical features of cutaneous toxicities to PI3K inhibitors. With rapid institution of appropriate, targeted therapies, patients will hopefully be able to maintain a high quality of life and remain on life-prolonging therapies.

REFERENCES

1. Thorpe LM, Yuzugullu H, Zhao JJ. PI3K in cancer: divergent roles of isoforms, modes of activation and therapeutic targeting. *Nat Rev Cancer*. 2015;15(1):7-24.
2. Vanhaesebroeck B, Guillermet-Guibert J, Graupera M, Bilanges B. The emerging mechanisms of isoform-specific PI3K signalling. *Nat Rev Mol Cell Biol*. 2010;11(5):329-341.
3. Okkenhaug K, Graupera M, Vanhaesebroeck B. Targeting PI3K in cancer: impact on tumor cells, their protective stroma, angiogenesis, and immunotherapy. *Cancer Discov*. 2016;6(10):1090-1105.
4. O'Brien SM, Lamanna N, Kipps TJ, et al. A phase 2 study of idelalisib plus rituximab in treatment-naïve older patients with chronic lymphocytic leukemia. *Blood*. 2015;126(25):2686-2694.
5. Grana B, Burris HA, Rodon Ahnert J, et al. Oral PI3 kinase inhibitor BKM120 monotherapy in patients (pts) with advanced solid tumors: an update on safety and efficacy. *J Clin Oncol*. 2011;29(15_suppl):3043.
6. Gao W, Wang M, Wang L, et al. Selective antitumor activity of ibrutinib in EGFR-mutant non-small cell lung cancer cells. *J Natl Cancer Inst*. 2014;106(9).
7. Luu M, Lai SE, Patel J, Guitart J, Lacouture ME. Photosensitive rash due to the epidermal growth factor receptor inhibitor erlotinib. *Photodermatol Photoimmunol Photomed*. 2007;23(1):42-45.
8. Peus D, Vasa RA, Meves A, Beyerle A, Pittelkow MR. UVB-induced epidermal growth factor receptor phosphorylation is critical for downstream signaling and keratinocyte survival. *Photochem Photobiol*. 2000;72(1):135-140.
9. Mitra A, Raychaudhuri SK, Raychaudhuri SP. IL-22 induced cell proliferation is regulated by PI3K/Akt/mTOR signaling cascade. *Cytokine*. 2012;60(1):38-42.
10. Eyerich S, Eyerich K, Pennino D, et al. Th22 cells represent a distinct human T cell subset involved in epidermal immunity and remodeling. *J Clin Invest*. 2009;119(12):3573-3585.
11. Gittler JK, Shemer A, Suárez-Fariñas M, et al. Progressive activation of T(H)2/T(H)22 cytokines and selective epidermal proteins characterizes acute and chronic atopic dermatitis. *J Allergy Clin Immunol*. 2012;130(6):1344-1354.
12. Roller A, Perino A, Dapavo P, et al. Blockade of phosphatidylinositol 3-kinase PI3K δ or PI3K γ reduces IL-17 and ameliorates imiquimod-induced psoriasis-like dermatitis. *J Immunol*. 2012;189(9):4612-4620.
13. Ali K, Soond DR, Piñeiro R, et al. Inactivation of PI(3)K p110 δ breaks regulatory T-cell-mediated immune tolerance to cancer. *Nature*. 2014;510(7505):407-411.
14. Lampson BL, Kasar SN, Matos TR, et al. Idelalisib given front-line for treatment of chronic lymphocytic leukemia causes frequent immune-mediated hepatotoxicity. *Blood*. 2016;128(2):195-203.
15. Thompson PA, Stingo F, Keating MJ, et al. Outcomes of patients with chronic lymphocytic leukemia treated with first-line idelalisib plus rituximab after cessation of treatment for toxicity. *Cancer*. 2016;122(16):2505-2511.