


# Eczema Herpeticum Following Skin Microneedling Plus Platelet-Rich Plasma Therapy in a Patient with Atrophic Acne Scars

Rina Wu<sup>1,\*</sup>, Mengying Leng<sup>2,\*</sup>, Qila Sa<sup>1</sup>, Qiri Mu<sup>1</sup> , Haiguang Zhao<sup>2</sup>

<sup>1</sup>Department of Dermatology, International Mongolian Hospital of Inner Mongolia, Hohhot, 010020, People's Republic of China; <sup>2</sup>Department of Plastic Surgery, Qilu Hospital (Qingdao), Cheeloo College of Medicine, Shandong University, Qingdao, 266035, People's Republic of China

\*These authors contributed equally to this work

Correspondence: Qiri Mu, Department of Dermatology, International Mongolian Hospital of Inner Mongolia, 83 University East Street, Hohhot, 010020, Inner Mongolia, People's Republic of China, Email muqiri28@163.com

**Abstract:** With the rapid development of minimally invasive cosmetic procedures, the group receiving minimally invasive cosmetic procedures is gradually on the rise. The adverse reactions or complications of minimally invasive cosmetic procedures also show an upward trend, but clinicians especially the cosmetic dermatologist should be identified and pay attention to the prevention and treatment in such reactions associated with minimally invasive cosmetic procedures in clinical practice. Platelet-rich plasma (PRP), which as a novel treatment option for acne scars, has shown good cosmetic results. Here, we report a case with eczema herpeticum following skin microneedling plus PRP therapy in a patient with atrophic acne scars.

**Keywords:** microneedling, cosmetic, infection, complication, PRP

## Introduction

Acne vulgaris commonly results in the complication of acne scarring, various treatment options are considered for acne scars, but the great differences in treatment response are presented; microneedling and platelet-rich plasma (PRP) as novel options have led to an increased popularity in acne scar treatment.<sup>1</sup> Specifically, PRP is an autologous component with high concentrations of platelets and growth factors, the action mechanism for disease treatment was complex which mainly involved the three phases included inflammation, proliferation and remodeling but based on platelet growth factors support the wound healing and repair cascade.<sup>2</sup> Based on such an action mechanism, PRP treatment is widely used in different medical fields currently, like tissue regeneration, wound healing and so on, also in dermatology, it is mainly focused on the treatment of androgenic alopecia, alopecia areata, vitiligo, melasma, psoriasis, skin rejuvenation and others.<sup>3–5</sup> The combination therapies of PRP with laser therapy, microneedling probably leading to the better cosmetic results.<sup>5</sup> In most cases, although the microneedling with PRP is a safe and effective option for acne scar treatment, complications still exist.

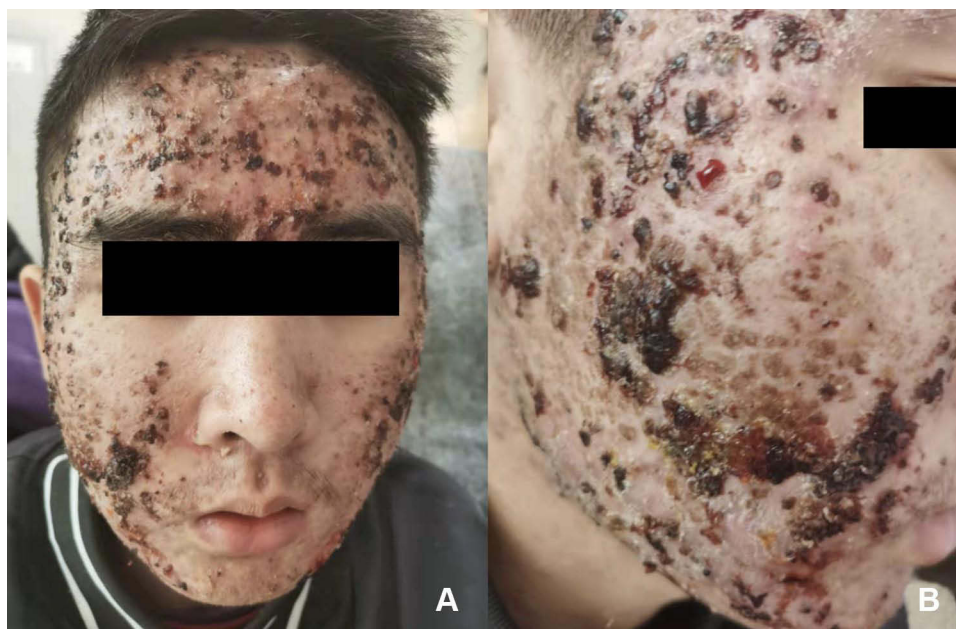## Case Presentation

A 19-year-old male presented with extensive facial skin lesions and fever for 3 days to our department. As he reported, he has 3 years history with moderate and severe acne, treated with topical 0.025% tretinoin cream and fusidic acid cream also with oral minocycline. After treatment, facial follicular papules and acne like lesions subsided, but atrophic scars remained on the lesion area. Then, he was recommended to an individual cosmetic clinic to improve the atrophic scars and skin microneedling plus platelet-rich plasma therapy was performed before this onset. On the next day after receiving therapy, his face began to feel as if it was burning and tingling also developed to eruption but he could not contact a doctor to treat him. In the next 24 hours, facial lesions expanded rapidly with fever and he came to our department to

seek further help. The history of herpes simplex was confirmed. Physical examination showed diffuse papulovesicle and pustules with erosion, exudation, and little scabs on the face which were distributed consistent with the treatment site (Figure 1A and B). Laboratory findings showed the absolute values of white blood cell, neutrophils, and erythrocyte sedimentation rate (ESR) were within the normal range, while the absolute values of lymphocytes had increased to  $4.2 \times 10^9/L$  (normal range  $1.1\text{--}3.2 \times 10^9/L$ ). Further, polymerase-chain-reaction (PCR) assay was performed, and the specimen of blister fluid from the lesion showed the positive reaction for herpes simplex virus type 1 (HSV-1), also the positive findings of HSV-1 IgM and IgG antibody in peripheral blood. These findings including clinical and laboratory were consistent with a diagnosis of eczema herpeticum. Subsequently, the treatment of valaciclovir (1g, twice a day for 7 days) was given and regression of skin lesions was confirmed in telemedicine follow-up, no evidence of recurrence was observed during the follow-up of up to 3 months.

## Discussion

Acne vulgaris, which is a chronic cutaneous inflammatory condition worldwide, it mainly involving a pilosebaceous unit comprising the hair follicle, hair shaft and sebaceous gland and commonly leading to adverse outcomes of scarring and results in the reduction of quality of life of patients.<sup>6</sup> A variety of safe and effective options for the treatment of acne scars are widely used at present, among them, the good therapeutic response of platelet-rich plasma (PRP) combined with multiple noninvasive and nonenergy procedures for treatment of atrophic acne scars is one of the options, although both microneedling and microneedling in combination with PRP represent satisfactory outcomes, the improvement of microneedling or subcision combined with PRP was better than microneedling or subcision alone.<sup>7,8</sup> Our case shows the chronological and close relationship between microneedling therapy and subsequent onset of eczema herpeticum, microneedling therapy as a traumatic, although minimally invasive, cosmetic treatment should be considered as an important inducing factor. Eczema herpeticum (also called Kaposi's varicelliform eruption), which is a severe cutaneous infectious complication induced by human simplex virus (HSV) infection, is also concomitant with dermatological conditions,<sup>9</sup> however, recent evidence shows that with the increase of minimally invasive cosmetic procedures, more related opportunistic infections are caused by non-tuberculous mycobacteria.<sup>10</sup> But in the chemical peeling procedure, recurrence of orofacial herpes simplex infection is indeed a potential risk, the risk of reactivation is mainly dependent on the depth of peel.<sup>11</sup> HSV commonly causes human infections in the orofacial region (HSV-1) and in the genital region



**Figure 1** Physical examination showed diffuse papulovesicle and pustules with erosion, exudation, and little scabs on the face which distributed consistent with the treatment site (A and B).

(HSV-2), latent infection within sensory neurons which is an important risk factor for recurrence and reactivation from latency results in recurrent infections and disease at or near the primary site of infection.<sup>12</sup> Reactivation and recurrence of the HSV infection associated with minimally invasive cosmetic procedures are rare but raising the awareness of cosmetic procedure related HSV infection for clinicians is necessary. In clinical practice, patients with a history of HSV infection should be warned to identify the risk of reactivation or recurrent infection with HSV, a standardized operation should be performed, and an infectious disease department consultation should be taken in time when necessary.

## Ethics Statement

The authors certify that they have obtained all appropriate patient consent forms. The patient gave written informed consent for publication of clinical information and photographs. No ethical committee approval was required because the data were analyzed in a retrospective manner.

## Funding

This work was supported by The Natural Science Foundation of Inner Mongolia Autonomous Region of China (2021ZD15).

## Disclosure

The authors declare no conflicts of interest.

## References

1. Schoenberg E, O'Connor M, Wang JV, et al. Microneedling and PRP for acne scars: a new tool in our arsenal. *J Cosmet Dermatol.* 2020;19(1):112–114. doi:10.1111/jocd.12988
2. Everts P, Onishi K, Jayaram P, et al. Platelet-rich plasma: new performance understandings and therapeutic considerations in 2020. *Int J Mol Sci.* 2020;21(20):7794. doi:10.3390/ijms21207794
3. Lin MY, Lin CS, Hu S, et al. Progress in the use of platelet-rich plasma in aesthetic and medical dermatology. *J Clin Aesthet Dermatol.* 2020;13(8):28–35.
4. Alves R, Grimalt R. A review of platelet-rich plasma: history, biology, mechanism of action, and classification. *Skin Appendage Disord.* 2018;4(1):18–24. doi:10.1159/000477353
5. Emer J. Platelet-rich plasma (PRP): current applications in dermatology. *Skin Therapy Lett.* 2019;24(5):1–6.
6. Moradi Tuchayi S, Makrantonaki E, Ganceviciene R, et al. Acne vulgaris. *Nat Rev Dis Primers.* 2015;1:15029. doi:10.1038/nrdp.2015.29
7. Long T, Gupta A, Ma S, et al. Platelet-rich plasma in noninvasive procedures for atrophic acne scars: a systematic review and meta-analysis. *J Cosmet Dermatol.* 2020;19(4):836–844. doi:10.1111/jocd.13331
8. Ibrahim MK, Ibrahim SM, Salem AM. Skin microneedling plus platelet-rich plasma versus skin microneedling alone in the treatment of atrophic post acne scars: a split face comparative study. *J Dermatolog Treat.* 2018;29(3):281–286. doi:10.1080/09546634.2017.1365111
9. Micali G, Lacarrubba F. Eczema herpeticum. *N Engl J Med.* 2017;377(7):e9. doi:10.1056/NEJMicm1701668
10. Lee WJ, Kang SM, Sung H, et al. Non-tuberculous mycobacterial infections of the skin: a retrospective study of 29 cases. *J Dermatol.* 2010;37(11):965–972. doi:10.1111/j.1346-8138.2010.00960.x
11. Johnson N. First-ever HSV-1 recurrence following superficial facial chemical peel after 30-year latency following neonatal primary infection. *J Cosmet Dermatol.* 2020;19(1):135–136. doi:10.1111/jocd.12975
12. Taylor TJ, Brockman MA, McNamee EE, et al. Herpes simplex virus. *Front Biosci.* 2002;7(1–3):d752–64. doi:10.2741/taylor

Clinical, Cosmetic and Investigational Dermatology

Dovepress

Publish your work in this journal

Clinical, Cosmetic and Investigational Dermatology is an international, peer-reviewed, open access, online journal that focuses on the latest clinical and experimental research in all aspects of skin disease and cosmetic interventions. This journal is indexed on CAS. The manuscript management system is completely online and includes a very quick and fair peer-review system, which is all easy to use. Visit <http://www.dovepress.com/testimonials.php> to read real quotes from published authors.

Submit your manuscript here: <https://www.dovepress.com/clinical-cosmetic-and-investigational-dermatology-journal>