

Primary myxoid melanoma with dermoscopic findings

Tugba K. Uzuncakmak¹, Ilkin Zindanci¹, Ebru I. Zemheri², Ayse S. Karadag¹,
Burce C. Kuru¹, Necmettin Akdeniz¹

¹ Department of Dermatology, Istanbul Medeniyet University, Goztepe Research and Training Hospital, Istanbul, Turkey

² Department of Pathology, Istanbul Medeniyet University, Goztepe Research and Training Hospital, Istanbul, Turkey

Key words: dermoscopy, interferon, myxoid melanoma

Citation: Uzuncakmak TK, Zindanci I, Zemheri EI, Karadag AS, Kuru BC, Akdeniz N. Primary myxoid melanoma with dermoscopic findings. *Dermatol Pract Concept*. 2017;7(2):13. DOI: <https://doi.org/10.5826/dpc.0702a13>

Received: November 25, 2016; **Accepted:** January 29, 2017; **Published:** April 30, 2017

Copyright: ©2017 Uzuncakmak et al. This is an open-access article distributed under the terms of the Creative Commons Attribution License, which permits unrestricted use, distribution, and reproduction in any medium, provided the original author and source are credited.

Funding: None.

Competing interests: The authors have no conflicts of interest to disclose.

All authors have contributed significantly to this publication.

Corresponding author: Tugba Kevser Uzuncakmak, MD, Istanbul Medeniyet University, Goztepe Training and Research Hospital, Dermatology, Istanbul, Turkey. Tel. +90- (530) 6640226. Email: drtugbakevser@gmail.com

ABSTRACT Myxoid melanoma is a rare variant of melanoma, which is characterized by atypical spindle cells and dense mucin deposition in dermis. This tumor is usually seen in elderly people with a similar progress in other variants of melanoma.

A 28-year-old male presented to our outpatient clinic with a 6-month history of a slowly growing asymptomatic pink lesion on his arm. Dermoscopic examination revealed pink-white crystalline structures and blue-grayish ovoid globules. The lesion was totally excised with initial diagnosis of basosquamous carcinoma, amelanotic melanoma and basal cell carcinoma. Histopathological examination was consistent with myxoid melanoma.

We present this case due to the rarity of myxoid melanoma and occurrence at such a young age.

Introduction

Melanoma is the malignant tumor of melanocytes which may present in a wide morphological spectrum including highly pigmented to amelanotic appearance. Clinically there are four main subtypes of cutaneous melanoma: superficial spreading melanoma, lentiginous melanoma, nodular melanoma and acral lentiginous melanoma. Any of these subtypes may present with pink amelanotic features. The diagnosis of amelanotic variants of melanoma may especially be challenging both clinically and histologically. In addition to clinical

variants of melanoma, in the literature various atypical histological variants of melanoma have been reported, such as fibroblastic, desmoplastic, chondroid, osteoid, and myxoid melanoma, which were classified according to stromal changes [1-3].

Myxoid melanoma is an unusual variant of malignant melanoma, which is characterized by atypical spindle cells and dense mucin deposition in dermis. The prevalence of this melanoma variant is not well known and may develop on cutaneous or extracutaneous sites, including the sino-nasal passages [4]. This tumor may be confused with other mucin-

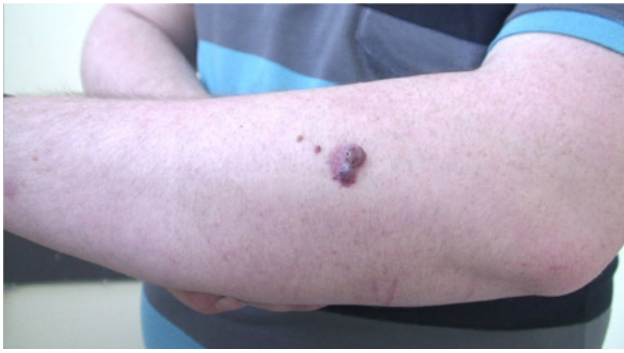


Figure 1. A 2.5 x 2 cm diameter pink, mildly infiltrated tumoral lesion with two pigmented papular lesions on the left arm. [Copyright: ©2017 Uzuncakmak et al.]

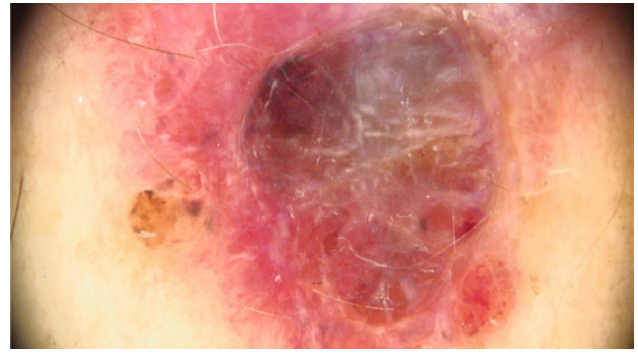


Figure 2. Pink-white crystalline structures and blue-grayish ovoid globules, nonpolarized dermoscopy. [Copyright: ©2017 Uzuncakmak et al.]

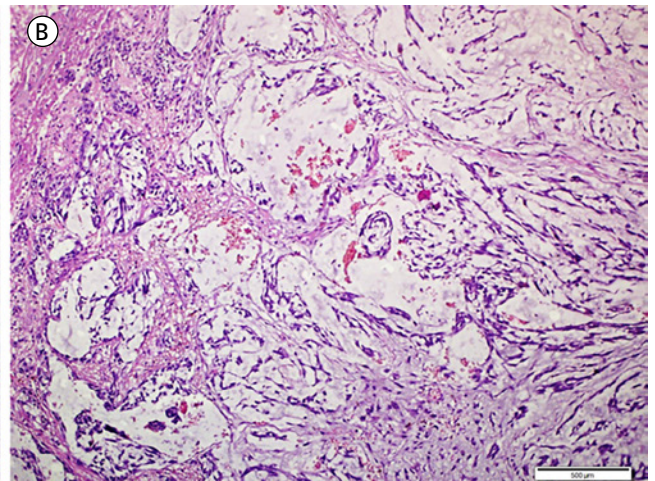
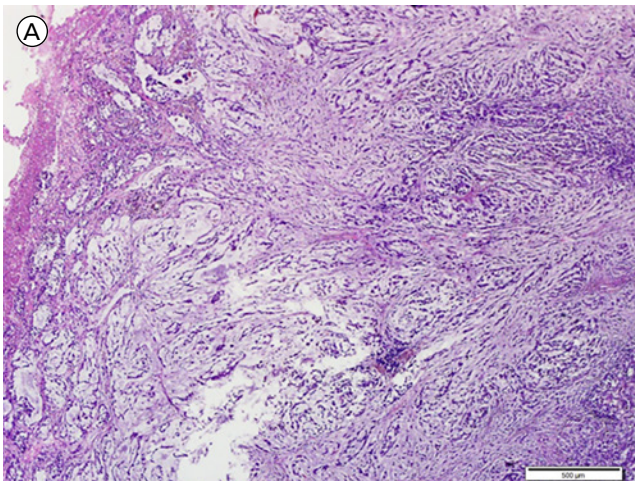


Figure 3. (A) Nests of atypical melanocytes surrounded by myxoid stroma. H&E x40 (B) Higher magnification, H&E x200. [Copyright: ©2017 Uzuncakmak et al.]

containing neoplasms, histologically benign or malignant, and clinically is usually reported in elderly people with a similar progress to other variants of melanoma.

Case Report

A 28-year-old male presented to our outpatient clinic with a history of an asymptomatic pink nodule which had been growing slowly for last 6 months. Dermatological examination revealed a 2.5 x 2 cm diameter pink, mildly infiltrated tumoral lesion with two pigmented papular lesions on left arm (Figure 1). Dermoscopic examination revealed pink-white crystalline structures and blue-grayish ovoid globules (Figure 2). The lesion was totally excised with 3 mm margins with the initial diagnosis of basosquamous carcinoma, amelanotic melanoma and basal cell carcinoma. Histopathological examination was consistent with myxoid melanoma with Breslow thickness 11.6 mm, Clark level V (Figure 3A,B). There was no vascular, lymphatic or perineural invasion histologically, and mitoses 2/1 per mm. Strong positivity was detected with S100 and HMB45 staining, and widespread positive staining was detected with PAS-Alcian blue for mucin deposition (Figure 4A,B). Laboratory tests, including complete

blood count, routine biochemistry, lactate dehydrogenase and beta-2 microglobulin and imaging test for metastasis, including PET-CT and sentinel lymph node biopsy, were all clear. Systemic adjuvant interferon therapy was administered. The patient is currently well and clinically free of recurrence 18 months after the diagnosis.

Discussion

The presence of myxoid stroma in malignant melanoma was first published by Bhuta et al in 1986 in four metastatic malignant melanomas [1,2]. Clinically these tumors were reported to be amelanotic, but in some cases melanogenesis was also shown with Fontana Masson preparations [2]. Histologically, this rare variant of melanoma is characterized by large malignant melanocytes and a basophilic mucinous matrix. In all cases, the myxoid stroma is comprised of mesenchymal acidic mucopolysaccharides, as opposed to neutral epithelial mucins. Mucinous material is usually located around the tumor cells, as in our case, but not within the tumor cells as in cytoplasmic localization, confirming that the myxoid matrix is produced as a response to the stromal cells in the tumor rather than being a product of the tumor cells. Myx-

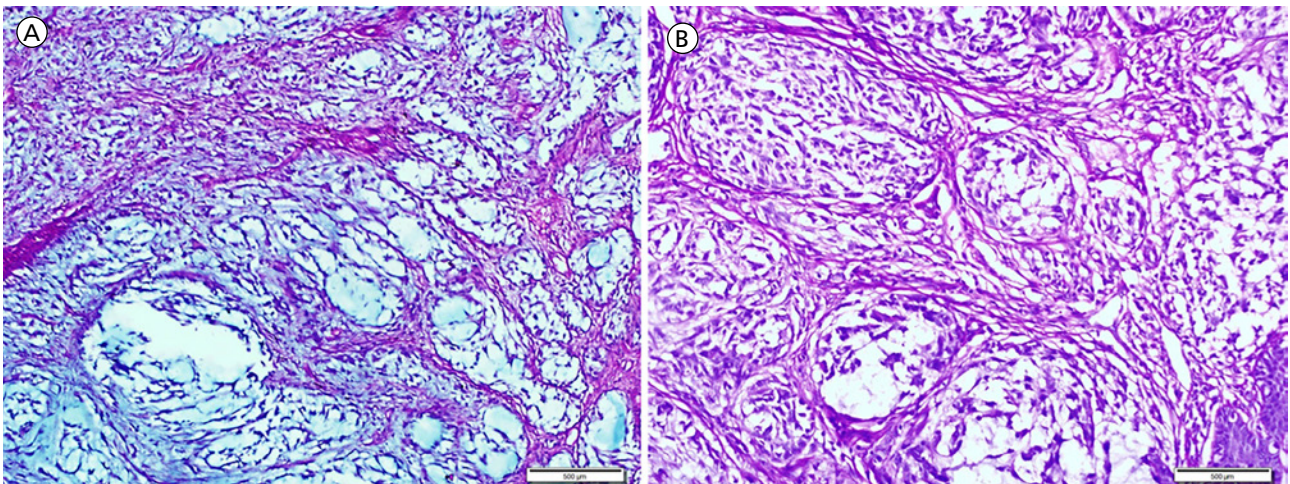


Figure 4. (A) PAS-alcian blue staining x100 and (B) PAS staining x200. [Copyright: ©2017 Uzuncakmak et al.]

oid changes are more often reported in metastatic tumors than in primary malignant tumors, but in our patient due to the completely intradermal location of tumor cells with no junctional component, with a nodular architecture, features of malignancy, no ulceration, the absence of peripheral nerves, and an absence of preexisting melanocytic nevus, he was diagnosed as primary dermal melanoma. Additionally, based on the histopathologically myxoid stromal changes, he was diagnosed as primary myxoid melanoma. Also no other metastatic or primary malignant lesion was detected with PET-CT scanning. Typically, S100 staining is strongly positive, but immunostaining with HMB-45 is less uniform and both positive and negative results were reported in the literature. In our patient both S100 and HMB45 staining were strongly positive.

The differential diagnosis of myxoid melanoma is broad, including several other benign and malignant myxoid neoplasms of soft tissue as well as epithelial cancers such as myxoid liposarcoma, myxoid malignant fibrous histiocytoma, low-grade fibromyxoid sarcoma, myxoid chondrosarcoma, myxoid peripheral nerve sheath tumors, dermatofibrosarcoma protuberans and metastatic adenocarcinomas [4].

The clinical and the prognostic significance of mucin deposition in melanomas is challenging due to presence of myxoid material both in primary benign or malignant tumors [5]. Some authors claimed that mast cells and secretion of transforming growth factor beta stimulates fibroblast secretion of

mucin contributing to the tumor's invasive potential; however, in the absence of compelling contrary data, the current series of cases suggests that myxoid stroma is more significant in diagnosis rather than prognosis of myxoid melanoma [5,6].

Although the real importance of myxoid changes in tumors is not well known, awareness of this stromal pattern in malignant melanomas may prevent misdiagnosis and therapeutic errors.

References

1. Hitchcock MG, White WL. Malicious masquerade: myxoid melanoma. *Semin Diagn Pathol.* 1998;15:195-202.
2. Inoue T, Misago N, Narisawa Y. Metastatic myxoid melanoma with partial regression of the primary lesion. *J Cutan Pathol.* 2007;34:508-512.
3. Harmse D, Saunders S, Evans A. Nonpigmented intradermal malignant melanoma with cribiform, myxoid, and spindle cell growth patterns. *Am J Dermatopathol.* 2010;32:829-831.
4. Magro CM, Crowson AN, Mihm MC. Unusual variants of malignant melanoma. *Mod Pathol.* 2006;19:S41-70.
5. Ulamec M, Soldo-Belić A, Vucić M, Buljan M, Kruslin B, Tomas D. Melanoma with second myxoid stromal changes after personally applied prolonged phototherapy. *Am J Dermatopathol.* 2008;30:185-187.
6. Nummela P, Lammi J, Soikkeli J, Saksela O, Laakkonen P, Hölttä E. Transforming growth factor beta-induced (TGFBI) is an anti-adhesive protein regulating the invasive growth of melanoma cells. *Am J Pathol.* 2012;180(4):1663-1674.