

## Original Article

# Clinical and radiographic assessment of mineral trioxide aggregate and calcium hydroxide as apexification agents in traumatized young permanent anterior teeth: A comparative study

S. G. Damle<sup>1</sup>, Hiteshwar Bhattal<sup>1</sup>, Dhanashree Damle<sup>2</sup>, Abhishek Dhindsa<sup>1</sup>, Ashish Loomba<sup>1</sup>, Sumit Singla<sup>1</sup>

Departments of <sup>1</sup>Pediatric and Preventive Dentistry and <sup>2</sup>Orthodontics and Dentofacial Orthopedics, Maharishi Markandeshwar University, Mullana, Ambala, Haryana, 133207, India

## ABSTRACT

**Background:** To evaluate and compare the efficacy of mineral trioxide aggregate (MTA) and traditionally used calcium hydroxide (Ca(OH)<sub>2</sub>) in inducing root end formation of immature roots of traumatized young permanent anterior teeth.

**Materials and Methods:** The study was carried out on 22 nonvital, immature permanent maxillary incisors. Samples were allotted into two groups – Group I MTA and Group II Ca(OH)<sub>2</sub>. Success rate was determined based upon the time duration required for apical barrier formation. The canals were obturated using gutta-percha points in MTA group, after 24 h, whereas in Ca(OH)<sub>2</sub> group, obturation was carried out after radiographic confirmation of the apical barrier. The clinical and radiographic evaluation was carried out at a follow-up periods of 3, 6, and 9 months and statistical analysis was carried out by SPSS version 15.0 statistical analysis software (Chi-square test and fisher exact test).

**Results:** In MTA Group, barrier formation was observed in 90.90% of the patients after 9 months whereas in Ca(OH)<sub>2</sub> Group, the same was observed in 81.81%. The mean time required for barrier formation in MTA group was 4.90 months and 5.33 months in Ca(OH)<sub>2</sub> group.

**Conclusion:** MTA and Ca(OH)<sub>2</sub>, as medicaments for apexification, were comparable in terms of the evaluation parameters. However, MTA was beneficial in terms of immediate obturation of immature roots with wide open apices.

**Key Words:** Apexification, calcium hydroxide, mineral trioxide aggregate

Received: August 2015

Accepted: December 2015

### Address for correspondence:

Dr. S. G. Damle,  
Department of Pediatric  
and Preventive Dentistry,  
Maharishi Markandeshwar  
University, Mullana,  
Ambala, Haryana, India.  
E-mail: sgdamle@gmail.com

## INTRODUCTION

The formative years of a child are filled with fervor and conjecture as they grow and explore the world around them. Concurrently, the child is susceptible to persistent exposure to the external environment. The fracture and luxation injuries to the anterior teeth constitute nearly 1/3 of all the traumatic injuries to human dentition. The treatment

of immature nonvital anterior teeth presents an exceptional challenge to the pediatric dentist. The endodontic treatment of these teeth with necrotic pulps and open apex involves induction of apical closure by apexification procedures to pave a way for optimal conditions for the conventional root canal filling.<sup>[1]</sup>

This is an open access article distributed under the terms of the Creative Commons Attribution-NonCommercial-ShareAlike 3.0 License, which allows others to remix, tweak, and build upon the work non-commercially, as long as the author is credited and the new creations are licensed under the identical terms.

**For reprints contact:** reprints@medknow.com

**How to cite this article:** Damle SG, Bhattal H, Damle D, Dhindsa A, Loomba A, Singla S. Clinical and radiographic assessment of mineral trioxide aggregate and calcium hydroxide as apexification agents in traumatized young permanent anterior teeth: A comparative study. Dent Res J 2016;13:284-91.

### Access this article online



Website: [www.drj.ir](http://www.drj.ir)  
[www.drjjournal.net](http://www.drjjournal.net)  
[www.ncbi.nlm.nih.gov/pmc/journals/1480](http://www.ncbi.nlm.nih.gov/pmc/journals/1480)

Calcium hydroxide (Ca(OH)<sub>2</sub>) has been the material of choice since the past few decades. It was introduced by Hermann in 1920. The use of Ca(OH)<sub>2</sub> in apexification was first introduced by Kaiser and Frank in the 1960s<sup>[2]</sup> and since then, has been used with great success to induce the formation of an apical hard tissue barrier in immature open apices.

Owing to its assorted biological effects, the time taken for complete apexification using Ca(OH)<sub>2</sub> has been reported to be variable, varying from 5 to 20 months or 12.9 months on an average.<sup>[1,3,4]</sup> Its efficacy has been demonstrated by several researchers through several clinical and long-term studies with a success rate ranging between 74 and 100%.<sup>[4]</sup> Furthermore, Ca(OH)<sub>2</sub> is readily available, easy to use, and relatively inexpensive. Therefore, Ca(OH)<sub>2</sub> apexification is still a widely used clinical procedure.<sup>[2]</sup>

The expedition and voyage for newer materials are never ending in the field of dentistry. A variety of materials have been formulated, tested, and standardized to obtain maximum benefit for high-grade clinical performance. Mineral trioxide aggregate (MTA) was introduced by Mahmoud Torabinejad at Loma Linda University, California, USA. Lee *et al.* first described this material to dental literature in 1993.<sup>[1]</sup>

There have been new advancements in the apexification procedure, with MTA representing a primary *mono block*. The gap that is induced owing to the material shrinkage phase after its placement is filled by apatite like interfacial deposits, which form during the maturation of MTA, thus improving the frictional resistance of MTA to root canal walls. MTA has superior biocompatibility, and it is less cytotoxic owing to its alkaline pH. It has attracted considerable attention owing to their superior sealing ability, biocompatibility, regenerative capabilities, and antibacterial properties.<sup>[5]</sup> The presence of calcium and phosphate ions in its formulation facilitates the attraction of blastic cells and promote favorable environment for cementum deposition.<sup>[6]</sup>

MTA has been advocated as a root-end-filling material for endodontic therapy as it displays minimal cytotoxicity as compared to other retrofilling materials with minor degrees of inflammation, promotion of hard tissue induction in the periodontal tissues, stimulation of dentin bridge formation adjacent to the dental pulp and superior sealing capabilities through enhanced marginal adaptation. MTA is one of the

most effective materials for sealing both iatrogenic and pathological communication between endodontic and periodontal spaces, and the presence of moisture does not affect its sealing ability.<sup>[7]</sup> MTA provides with the advantage of immediate obturation of immature roots with wide open apices. MTA has also been used for direct pulp capping, repair of root and furcal perforations.

Hence, the present study was conducted with the aim to determine the clinical and radiographic efficacy of MTA and traditionally used Ca(OH)<sub>2</sub> in inducing the root end formation of immature roots of the traumatized young permanent anterior teeth. The study also appraised the time taken for resolution of periapical radiolucency in both the groups (if present at baseline).

## MATERIALS AND METHODS

A total of 1000 school children in the age groups of 8–13 years were examined in six schools located in semi-urban/urban areas of the Ambala district, Haryana, India (Project No: Maharishi Markandeshwar University, India-IEC-124) Oral health status was assessed in terms of dental caries status, periodontal disease, dentofacial anomalies, and traumatic injuries to the anterior teeth and the findings were recorded on the WHO Oral Health Assessment Performa (2013).<sup>[8]</sup> The oral examination revealed 47 children had a fracture in one or two maxillary/mandibular anterior teeth. Visual examination was carried out under natural daylight. The particulars of each child, i.e. name, class, and address were recorded. Children with Class II, Class III, and Class IV fractures (Ellis and Daveys classification-1970)<sup>[9]</sup> were initially included. Ethics Committee approval was obtained by the Maharishi Markandeshwar University before instigating the study.

The parents were explained in brief about the oral health status of their child. After the survey and oral health education session, a total of 39 patients reported to the Department of Pediatric and Preventive Dentistry, Maharishi Markandeshwar College of Dental Sciences and Research, Mullana (Ambala). The benefits of available treatment modality, its methodology and the importance of the procedure, were explained in detail to parents and written informed consent was obtained. Finally, a total of 22 children, who met the inclusion criteria and had comparable features, were selected for the study.

The inclusion parameters were:

- Children in the age group of 8–13 years with Ellis Class-III or IV fracture of maxillary permanent incisors
- Children with affected tooth/teeth showing delayed response (s) to pulp sensibility test, i.e. cold test with dry ice snow (RCICE™, Prime Dental Products Pvt. Ltd., India)
- Children with the root length formation approximately two-thirds or more (Nolla's Stage 8, 9), adequate bone support
- Children free from any systemic illness and having good general health
- No evident internal/external root resorption radiographically.

The selected children were assigned sequential numbers and through a random draw of lots, they were then divided into two groups: Group I MTA (study group) and Group II Ca(OH)<sub>2</sub> (control group).

The radiographic examination was established preoperatively, intraoperatively, and postoperatively by intraoral periapical radiographs using paralleling technique and findings were recorded. Before the commencement of treatment, aseptic precautions were ensured. Single operator performed the apexification procedure using the same protocol for both groups as stated below:

- Preoperative radiograph was taken using paralleling technique
- Thereafter, under rubber dam isolation, access cavity was prepared with the help of a high-speed round and straight fissure diamond burs (diameter 014, Endo ZR bur; Dentsply) following the application of local anesthesia (Dentocaine, 2% lignocaine hydrochloride with 1:200000 adrenaline; Pharma health care product) [Figure 1]. Working length was established with the use of size 30 Hedstrom file, keeping it one mm short of radiographic apex
- Necrotic pulp was extirpated using large sized K/H files (Dentsply Maillefer; China), and complete debridement of the canal was done followed by copious irrigation with normal saline (0.9% w/v; Parenteral drugs Ltd; India)
- Minimal canal preparation was carried out so as to avoid damage to the thin dentinal walls
- Biomechanical preparation was carried out with light lateral pressure against the walls of the canal with an appropriate size of K/H file taking care of apical area during instrumentation, ensuring the instrument was kept within working length

- After drying the canals by paper points (Dentsply Maillefer; China), one of the two materials, i.e. MTA or Ca(OH)<sub>2</sub> was introduced into the canal space depending upon the group to which the tooth had been allotted. Ca(OH)<sub>2</sub> paste (Diapaste™, Diadent Co Ltd; Korea) (Ca(OH)<sub>2</sub>, methyl cellulose [base], barium sulfate [radio-opacifier]) was inserted and condensed into the canal space with hand pluggers, while the MTA (ProRoot™, Dentsply, Tulsa Dental; USA) powder was mixed with distilled water in the ratio of 3:1 and gently inserted at the apical one third of the root canal of teeth with the help of butt end of a large sized gutta-percha (GP) point and incrementally pushed upto the apex and slowly compacted (to avoid over insertion into periapical area) by repeated insertion of material
- The access cavity was restored with the temporary restorative material (Cavit™ ESPE, Cergy Pontoise, France) and radiograph was taken to confirm the extension/condensation of Ca(OH)<sub>2</sub> paste/MTA apical plug.

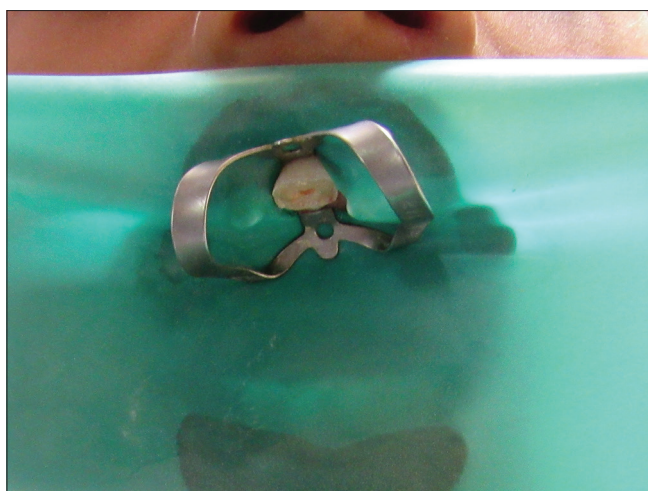#### Mineral trioxide aggregate group

A moist cotton pellet was left *in situ* for 24 h in close contact with MTA to augment its setting and the access cavity was sealed with the same temporary restorative material.

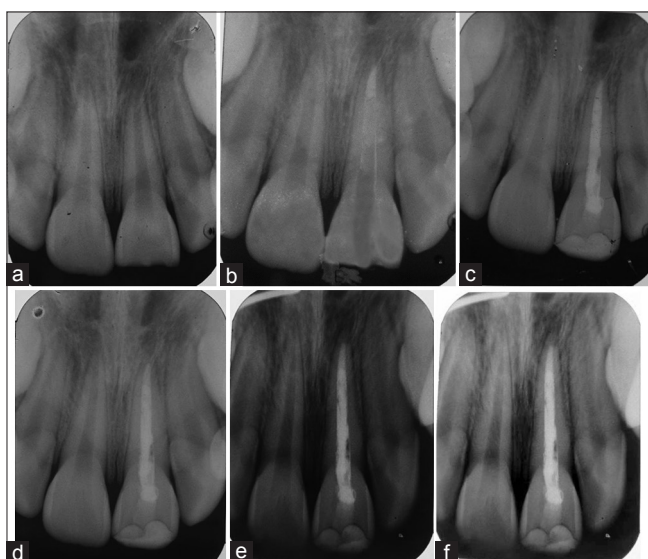
At the subsequent visit, after 24 h, the canal was re-accessed, cotton pellet was removed, and a file was inserted to check hardened MTA apical plug. Obturation was carried out using zinc oxide Eugenol Sealer (Prime Dental Products Pvt. Ltd, Thane, Maharashtra, India) and GP points by vertical condensation method. Access cavity was then sealed with Glass Ionomer Cement (Type II-restorative cement) (GC Fuji II, GC America, Inc., Alsip, IL) [Figure 2a-f].

#### Calcium hydroxide group

During the periodical recall period, after observing radiographic evidence of an apical barrier formation, canal was reassessed and Ca(OH)<sub>2</sub> was flushed out from the canals with normal saline and dried using paper points. Calcific barrier formation was checked clinically by inserting a GP point and upon obtaining a hard stop, a radiograph was taken for re-confirmation of a hard stop and thus the working length. Thereafter, canals were dried and obturated. Access cavity was sealed with Glass Ionomer Cement [Figure 3a-e].



**Figure 1:** Clinical photograph depicting tooth isolated using rubber dam after administration of local anesthesia.



**Figure 2:** (a) Preoperative radiograph of traumatized maxillary (Lt) central incisor (b) mineral trioxide aggregate placed in the traumatized maxillary (Lt) central incisor (Group I) (c) Postoperative radiograph showing apexification and obturation with gutta-percha (d) 3-month follow-up (e) 6-month follow-up (f) 9-month follow-up.

Clinical and radiographic assessment of both the groups were done at recall periods of 3, 6, and 9 months postoperatively and clinical features such as pain, tenderness to percussion, swelling/intraoral sinus, along with radiographic parameters like calcific bridge formation, periapical radiolucency (if present at baseline), intra-oral/extra oral root resorption were evaluated. Formation of the calcific barrier, the absence of pain, absence of tenderness to percussion, healing of intra-oral sinus, static or decreasing radiolucency indicated the success of treatment.

During the course of the study period, antibiotics/analgesics were not administered for any endodontic intervention undertaken. Results were tabulated and subjected to statistical analysis using Statistical Package for the Social Sciences version 15 (IBM Corporation, N.Y., USA statistical analysis software (Chi-square test and fisher exact test for cross-tabulation).

## RESULTS

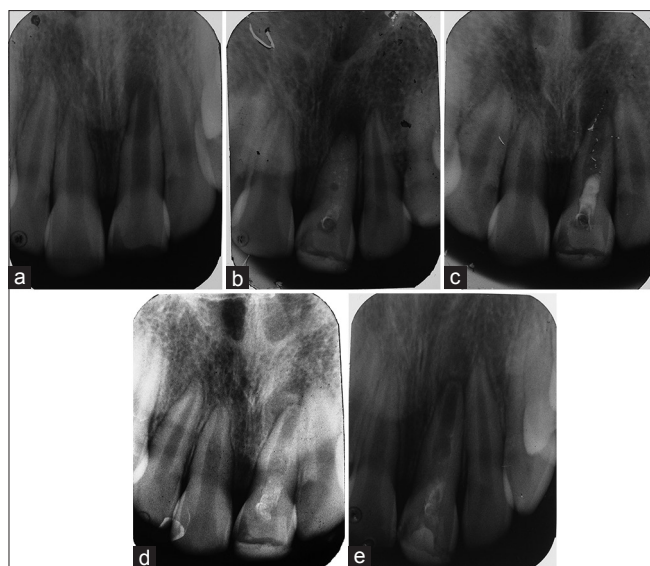
A total of 22 anterior teeth were treated. The mean age of children included in Group I (MTA group) was  $10 \pm 1.41$  years and in Group II, it was  $10.80 \pm 1.32$  years. Central Incisor was the most commonly involved tooth in both the groups, whereas lateral incisor was involved in only 2 children.

Tenderness on percussion was the most common clinical sign reported in both of the groups, followed by the absence of pulpal response (36.36% and 18.18% in Group I and II, respectively). Swelling, mobility and sinus were some of the less common findings [Table 1].

In Group I, barrier formation by 9 months was observed in 90.90% of subjects whereas in Group II, it was observed in 81.81% of subjects ( $P = 0.500$ ). The median time required for barrier formation in Group I was 4.90 months whereas for Group II, it was 5.33 months. The difference in time taken for barrier formation in two groups was statistically insignificant. In Group I, barrier formation in the majority of the subjects (70%) took place within 3 months as against only in 30% of subjects in Group II.

The relationship between adequacy of placement of medicament and time taken for barrier formation in Group I was statistically significant whereas in Group II it was insignificant [Table 2]. In Group I, seven teeth with adequately placed MTA at the apex had calcific barrier formation whereas out of the four teeth in which MTA was placed away from the apex, only two showed barrier formation. In Group II, medicament was placed at the apex in four teeth, and three of them showed barrier formation whereas medicament was placed away from the apex in four teeth and barrier was observed in all. However, the association was not statistically significant for both the groups.

The clinical and radiographical success of the material was judged on the basis of presence/absence



**Figure: 3:** (a) Pre-operative radiograph of traumatized maxillary (Lt) central incisor (b) calcium hydroxide placed in the traumatized maxillary (Lt) central incisor (Group -II) (c) 3-month follow -up (d) 6 -month follow -up (e) 9 -month follow -up.

of clinical criteria's [Table 1] and absence of any periapical pathology on radiographs. Clinical and radiographical success rate in Group I was 90.09% and in Group II, it was 81.81% [Table 3]. However, the difference between the two groups was not statistically significant ( $P = 0.9999$ ).

## DISCUSSION

There has been a continuous evolution of newer materials and a constant advancement in the treatment options, especially in the field of pediatric dentistry, as the children are at assorted stages of growth and development.

Sheehy and Roberts stated that pulp necrosis is a frequent complication of dental trauma in immature permanent teeth. Endodontic treatment of such teeth is often complicated.<sup>[10]</sup> Nonvital teeth with incomplete root formation require apexification which helps to achieve a root end seal more similar to the natural apical constriction as compared to filling the root in retrograde approach.<sup>[11]</sup> The goal of this treatment is to obtain an apical barrier, to prevent the passage of toxins and bacteria into the periapical tissues from the root canal and create an environment conducive to the production of mineralized tissue barrier or root end formation at the immature root end.<sup>[12]</sup>

Ca(OH)<sub>2</sub> has been widely studied and reported as the material of choice for apexification. The

**Table 1: Distribution of sample based upon preoperative clinical and radiological signs and symptoms**

Signs and symptoms	n	Group I (n=11)		Group II (n=11)		P (Fisher exact test)
		n	Percentage	n	Percentage	
Discoloration of teeth	15	7	63.63	8	72.72	0.9999
Pain	13	7	63.63	6	54.54	1
Pulpal response	6	4	36.36	2	18.18	0.6351
Swelling	4	2	18.18	2	18.18	1
Pus discharge/sinus	3	2	18.18	1	9.09	0.9999
Tenderness on percussion	12	6	54.54	6	54.54	1
Periapical radiolucency	10	4	36.36	6	54.54	0.6699

**Table 2: Relationship between extent of placement of medicament and barrier formation in both the groups**

Extent of placement of medicament	Group I (n=11)		Group II (n=11)	
	Calcific barrier present	Calcific barrier absent	Calcific barrier present	Calcific barrier absent
At the level of apex (n=11)	7	0	4	1
short of apex level (n=6)	0	2	4	0
Beyond apex level (n=3)	2	0	1	1
$\chi^2$ test (Fisher exact test)	$\chi^2=11$		$\chi^2=2.26$	
(at level vs. away from level)	P=0.0041 (<0.05)*		P=0.323	

\*Statistically significant

**Table 3: Clinical and radiographical success rate in two groups**

Success/failure	Clinical success		Radiographical success	
	Group I	Group II	Group I	Group II
Success	10	9	10	9
Failure	1	2	1	2
Success rate (%)	90.90	81.81	90.90	81.81
Fisher exact test	0.9999		0.9999	

method, popularized by Frank (1966), emphasized the importance of reducing contamination within the root canal by instrumentation, medication and decreasing the canal space temporarily with a resorbable paste.<sup>[13]</sup> Various biological properties have been attributed to Ca(OH)<sub>2</sub>, such as antimicrobial activity,<sup>[14]</sup> tissue-dissolving ability,<sup>[15,16]</sup> inhibition of tooth resorption<sup>[17]</sup> and induction of repair by hard tissue formation.<sup>[18]</sup> Ca(OH)<sub>2</sub>-based apexification procedures require excellent patient compliance because of the necessary long-term application of the dressing material from 3 to 24 months to obtain complete closure of the root apex. There may also

be a weakening of the root structure as well as susceptibility to reinfection.<sup>[7]</sup>

MTA also has an alkalinity (pH = 12.5) similar to that of Ca(OH)<sub>2</sub> (pH = 12)<sup>[19]</sup> and consists of several calcium salts in its composition.<sup>[20]</sup> The high pH activates alkaline phosphatase and antibacterial activities. The presence of a high calcium concentration further increases the activity of calcium-dependent pyrophosphatase<sup>[18]</sup> and so asepsis of lesions is achieved, and the process of bone healing is initiated. An MTA plug in the apical portion of the root promotes apical repair and prevents root canal overfilling, thus ensuring that the permanently bonded restoration enhances the retention of natural teeth, and it can increase the fracture resistance of immature teeth.<sup>[7]</sup>

The principle aim and objective of this study were to clinically and radiographically evaluate and compare the mean time taken for apical barrier formation between MTA and Ca(OH)<sub>2</sub> group. Additional parameter studied was the resolution of periapical radiolucency (if present at baseline).

A sample of 22 traumatized young permanent anterior teeth in children aged 8–13 years were included, by strictly following the laid down parameters. Samples were randomly divided into two groups of 11 teeth in each group, i.e. Group I (mineral trioxide), Group II [Ca(OH)<sub>2</sub>]. The age group of 8–13 years was selected as this period corresponds to eruption, the establishment of an occlusal level of incisors and continuing physiological root development (Nolla stage 8/9) as reported in similar studies.<sup>[19-23]</sup> Majority of children were in the age group of 11–12 years (10 children), with male: female ratio of 18:2 as boys tend to be involved more in sports and physical activities making them more prone to injuries. Similar findings have been confirmed in other studies.<sup>[19,24]</sup>

In the selected samples, 20 central incisors were affected as compared to two lateral incisors. This could be attributed to early chronological appearance and their prominent positioning in oral cavity coinciding with the increased physical activity of a child.

Children were initially questioned regarding their chief complaint. 70% cited a broken tooth as a main distressing factor. Additional complaints cited were presence of intermittent pain (7 in Group I and 6 in Group II), swelling of gingival tissue in relation to affected teeth (2 in Group I and 2 of Group II) and

presence of intra-oral sinus in relation to the affected teeth (one from both groups) with two giving history of unsuccessful previous endodontic treatment.

The preoperative clinical evaluation for the presence of pain and tenderness to percussion were correlated. In Group I, 6 teeth were tender on percussion at baseline examination, with 3 being associated with the presence of periapical radiolucency and in Group II, 6 teeth were tender and were associated with periapical radiolucency.

Presence of pain was recorded in 7 teeth of Group I at baseline, which subsided in 5 teeth following treatment. One of the patient complained of mild intermittent pain and tenderness postoperatively at 3 months examination, which was attributed to the inadvertent extrusion of MTA into the periapical region. In Group II, the presence of pain was elicited from 6 patients preoperatively. Postoperatively, four children gave a history of mild pain and were tender to percussion, at 3 months examination. In all these cases, Ca(OH)<sub>2</sub> had been pushed beyond the apical barrier. There was the absence of pain and tenderness in all children at 6-month examination. Similar findings were observed by Pradhan *et al.*<sup>[19]</sup> wherein they observed tenderness in teeth with extruded MTA till 3 months.

Intra-oral sinus formation was seen at baseline examination in relation to a single tooth in both the groups. In Group I, healing took place within 3 months, whereas in Group II, healing took place at 6 months. Healing could be attributed to biomechanical debridement, supplemented by copious irrigation to effectively remove necrotic tissue and infected dentin from the canals and aided by the antibacterial action of the material. The clinical parameters such as pain, tenderness to percussion and intra-oral sinus have also been evaluated as parameters for success, Pradhan *et al.* and El-Meligy and Avery.<sup>[19,23]</sup>

Upon initial examination, 10 teeth (4 in Group I and 6 in Group II) had periapical radiolucencies. Further, only 2 teeth exhibited sinus formation which was indicative of the chronic process of degeneration alternating with the reparative process and abundant vascular supply to the periapical region. This difference was not statistically significant ( $P > 0.005$ ). The radiolucencies were assessed during follow-up examinations to appraise any difference in the healing tendency between the two groups. In Group I, a single tooth out of 4 teeth revealed persistent periapical

radiolucency, whereas in Group II, it was observed in three out of 6 teeth, after 3 months. In both groups, it was observed that there was the resolution of periapical radiolucency at 6 months. Thus, MTA exhibited comparable healing ability as compared to  $\text{Ca(OH)}_2$  as MTA has an alkaline pH (pH = 12.5) similar to that of  $\text{Ca(OH)}_2$  (pH = 12) and consists of several calcium salts in its composition.<sup>[24]</sup>

In Group I, MTA had been placed approximating the radiographic apex in 7 teeth. Out of these, 6 confirmed evidence of barrier formation at 3 months and 1 had barrier formation at 6 months of examination. Two teeth, with MTA placement short of the radiographic apex, showed evidence of barrier formation at 3 months examination. In two teeth, MTA had inadvertently been placed beyond the radiographic apex. In these teeth, barrier formation was not evident even after 9 months, which may be due to extrusion of MTA. Similar findings were also specified by Pradhan *et al.*, who failed to ascertain the barrier formation (in three teeth) with extruded MTA in a 15 month study period.<sup>[19]</sup>

In Group II,  $\text{Ca(OH)}_2$  was placed approximating radiographic apex in 4 teeth. There was barrier formation in one at 3 months, two showed evidence at 6 months, and one at 9 months of follow-up. In four cases of overfilled material, the calcific barrier was observed in two cases at 3 months and for two at 6 months follow-up. In one of the tooth, in which material was short of apex, barrier formation was seen at 6 months. In one case, follow-up at 6 months revealed the absence of periapical radiolucency and sinus healing, this case was not considered for further inclusion in this study. Similar findings in the time taken for barrier formation were reported in other studies with  $\text{Ca(OH)}_2$  as an intracanal medicament. Ghose *et al.*<sup>[21]</sup> stated that in 78% of cases apical closure was obtained 5 or 6 months after completing treatment and two sessions of  $\text{Ca(OH)}_2$  treatment were usually required, Yates<sup>[25]</sup> stated that closure was obtained in 9 months, and same was reported by Dominguez Reyes *et al.*<sup>[4]</sup> in 12.19 months.

In Group I, barrier formation was seen in seven teeth after 3 months, whereas in Group II, barrier formation was observed in three teeth. At 6 months follow-up, barrier formation was seen in one of the tooth in Group I, as compared to five teeth in Group II. The 9-month follow-up revealed barrier formation in a single tooth in  $\text{Ca(OH)}_2$  group. There was the absence

of barrier formation in two teeth, in the MTA group, which was attributed to over extrusion of material into periapical area. In Group II, there was failure in one tooth due to resorptive process. The clinical and radiographic success of MTA was faster than  $\text{Ca(OH)}_2$ , however the difference in treatment outcome between both groups was found to be statistically insignificant.

## CONCLUSION

Consequently, it can be clinched that MTA and  $\text{Ca(OH)}_2$ , when used as materials for apexification, are comparable in terms of the evaluation parameters with MTA being advantageous in achieving immediate obturation of immature roots with wide open apices.

Conversely, before conclusive inferences regarding better efficacy among the two material can be drawn, a larger sample size with a longer follow-up clinically and radiographically needs to be undertaken at regular intervals so as to further substantiate the use of either one of the materials in barrier formation and apical healing of open apices of traumatized young permanent anterior teeth.

## Financial support and sponsorship

Nil.

## Conflicts of interest

The authors of this manuscript declare that they have no conflicts of interest, real or perceived, financial or non-financial in this article.

## REFERENCES

1. Lee SJ, Monsef M, Torabinejad M. Sealing ability of a mineral trioxide aggregate for repair of lateral root perforations. *J Endod* 1993;19:541-4.
2. Yassen GH, Chin J, Mohammedsharif AG, Alsoufy SS, Othman SS, Eckert G. The effect of frequency of calcium hydroxide dressing change and various pre- and inter-operative factors on the endodontic treatment of traumatized immature permanent incisors. *Dent Traumatol* 2012;28:296-301.
3. Kleier DJ, Barr ES. A study of endodontically apexified teeth. *Endod Dent Traumatol* 1991;7:112-7.
4. Dominguez Reyes A, Muñoz Muñoz L, Aznar Martín T. Study of calcium hydroxide apexification in 26 young permanent incisors. *Dent Traumatol* 2005;21:141-5.
5. Parirokh M, Torabinejad M. Mineral trioxide aggregate: A comprehensive literature review – Part I: chemical, physical, and antibacterial properties. *J Endod* 2010;36:16-27.
6. Kubasad GC, Ghivari SB. Apexification with apical plug of MTA-report of cases. *Arch Oral Sci Res* 2011;1:104-7.
7. Pace R, Giuliani V, Nieri M, Di Nasso L, Pagavino G. Mineral

- trioxide aggregate as apical plug in teeth with necrotic pulp and immature apices: A 10-year case series. *J Endod* 2014;40:1250-4.
8. World Health Organization. Oral Health Surveys: Basic Methods. 5<sup>th</sup> ed. Geneva, Switzerland: World Health Organization; 2013.
  9. Gojanur S, Yeluri R, Munshi AK. Prevalence and Etiology of Traumatic Injuries to the Anterior Teeth among 5 to 8 Years Old School Children in Mathura City, India: An Epidemiological Study. *Int J Clin Pediatr Dent* 2015;8:172-5.
  10. Sheehy EC, Roberts GJ. Use of calcium hydroxide for apical barrier formation and healing in non-vital immature permanent teeth: a review. *Br Dent J* 1997;183:241-6.
  11. Ham KA, Witherspoon DE, Gutmann JL, Ravindranath S, Gait TC, Opperman LA. Preliminary evaluation of BMP-2 expression and histological characteristics during apexification with calcium hydroxide and mineral trioxide aggregate. *J Endod* 2005;31:275-9.
  12. Simon S, Rilliard F, Berdal A, Machtou P. The use of mineral trioxide aggregate in one-visit apexification treatment: A prospective study. *Int Endod J* 2007;40:186-97.
  13. Frank AL. Therapy for the divergent pulpless tooth by continued apical formation. *J Am Dent Assoc* 1966;72:87-93.
  14. Bystrom A, Claesson R, Sundqvist G. The antibacterial effect of camphorated paramonochlorophenol, camphorated phenol and calcium hydroxide in the treatment of infected root canals. *Endod Dent Traumatol* 1985;1:170-5.
  15. Hasselgren G, Olsson B, Cvek M. Effects of calcium hydroxide and sodium hypochlorite on the dissolution of necrotic porcine muscle tissue. *J Endod* 1988;14:125-7.
  16. Andersen M, Lund A, Andreasen JO, Andreasen FM. *In vitro* solubility of human pulp tissue in calcium hydroxide and sodium hypochlorite. *Endod Dent Traumatol* 1992;8:104-8.
  17. Tronstad L. Root resorption – Etiology, terminology and clinical manifestations. *Endod Dent Traumatol* 1988;4:241-52.
  18. Foreman PC, Barnes IE. Review of calcium hydroxide. *Int Endod J* 1990;23:283-97.
  19. Pradhan DP, Chawla HS, Gauba K, Goyal A. Comparative evaluation of endodontic management of teeth with unformed apices with mineral trioxide aggregate and calcium hydroxide. *J Dent Child (Chic)* 2006;73:79-85.
  20. Schwartz RS, Mauger M, Clement DJ, Walker WA 3<sup>rd</sup>. Mineral trioxide aggregate: A new material for endodontics. *J Am Dent Assoc* 1999;130:967-75.
  21. Ghose LJ, Baghdady VS, Hikmat YM. Apexification of immature apices of pulpless permanent anterior teeth with calcium hydroxide. *J Endod* 1987;13:285-90.
  22. Walia T, Chawla HS, Gauba K. Management of wide open apices in non-vital permanent teeth with Ca(OH)<sub>2</sub> paste. *J Clin Pediatr Dent* 2000;25:51-6.
  23. El-Meligy OA, Avery DR. Comparison of apexification with mineral trioxide aggregate and calcium hydroxide. *Pediatr Dent* 2006;28:248-53.
  24. Andreasen JO. Etiology and pathogenesis of traumatic dental injuries. A clinical study of 1,298 cases. *Scand J Dent Res* 1970;78:329-42.
  25. Yates JA. Barrier formation time in non-vital teeth with open apices. *Int Endod J* 1988;21:313-9.