

Non-radiographic *versus* radiographic axSpA: what's in a name?

Xabier Michelena ^{1,2}, Clementina López-Medina^{3,4} and Helena Marzo-Ortega ^{1,2}

Abstract

Axial spondyloarthritis is a heterogeneous inflammatory condition with variable clinical presentations and outcomes. The complexity of its diagnosis and absence of biomarkers hamper the development of diagnostic criteria with the risk of misuse of the available classification criteria in clinical practice and its consequences. Axial spondyloarthritis should be regarded as a continuum in which some patients, but not all, will have a more severe phenotype characterized by progression into new bone formation and joint fusion. Growing understanding of the factors that might drive disease progression and treatment response will allow for better characterization of treatment options and outcome for each affected individual. The aim of this review is to update the current evidence of what is axial spondyloarthritis and to highlight the need to focus on the concept rather than its classification.

Key words: axial spondyloarthritis, non-radiographic axial spondyloarthritis, nomenclature

Rheumatology key messages

- Non-radiographic and radiographic axial spondyloarthritis is an artificial split of one single disease entity.
- Non-radiographic and radiographic axial spondyloarthritis carry a comparable disease burden, and may need equal treatment options.
- Axial spondyloarthritis should be seen as a continuum, to facilitate research in the different disease stages.

Introduction

The term 'axial spondyloarthritis' (axSpA) refers to chronic inflammatory disease of the axial skeleton [1]. Its prototype, AS, also known as radiographic axial spondyloarthritis (r-axSpA) is mandatorily defined by evident radiographic structural damage in the sacroiliac joints (SIJs), which becomes visible years after symptom onset [2]. To encompass earlier stages, the term 'non-radiographic axSpA' (nr-axSpA) was introduced in the Assessment of Spondyloarthritis International Society (ASAS) classification criteria to include patients with suggestive clinical features of axSpA but no radiographic sacroiliitis. As such, nr-axSpA may be identified by clinical features and MRI-detected inflammatory lesions

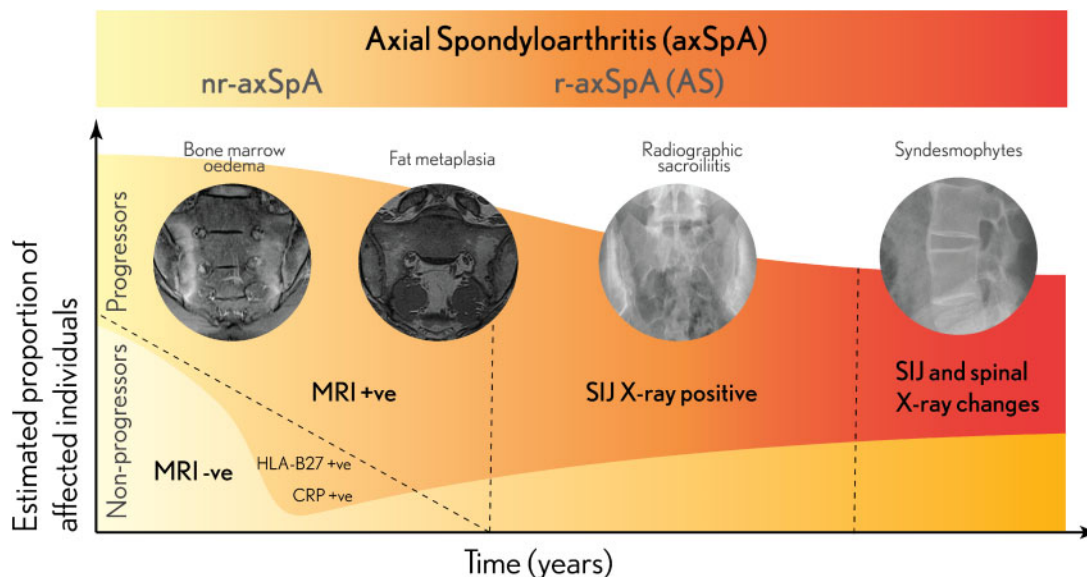
in the SIJs (imaging arm) or the presence of HLA-B27 positivity in the absence of MRI findings, when applying the so called 'clinical arm' of the ASAS classification criteria [3]. The introduction of these terms was never meant to define two separate entities but to capture the whole spectrum of axSpA and to allow for a 'staging' of the disease to facilitate research in this area. Crucially, classification criteria are only meant to be applied once the diagnosis has already been made. Unfortunately, the growing misuse of the classification criteria in order to make clinical diagnosis somehow led to controversy as to whether nr-axSpA may indeed represent a different clinical entity rather than a disease subset. The reasons argued towards supporting the former are the fact that many cases are diagnosed without imaging findings (clinical arm), hence lacking any 'objective' evidence of target tissue involvement (i.e. SIJ inflammatory lesions as seen on MRI) or damage (i.e. structural lesions of sclerosis, erosions of bone fusion as seen on conventional radiography) and importantly, the fact that a considerable number of cases with nr-axSpA may never develop radiographic sacroiliitis [4]. By contrast, many experts agree in understanding axSpA as a continuum (Fig. 1), considering nr-axSpA as an early stage of disease where radiographic damage may have not yet occurred.

¹NIHR Leeds Biomedical Research Centre, Leeds Teaching Hospitals Trust, ²Leeds Institute of Rheumatic and Musculoskeletal Medicine, University of Leeds, Leeds, UK, ³Department of Rheumatology, Hospital Cochin, Paris, France and ⁴Department of Medicine, University of Córdoba/IMIBIC/University Hospital Reina Sofía, Córdoba, Spain

Submitted 21 April 2020; accepted 17 June 2020

Correspondence to: Helena Marzo-Ortega, LIRMM, Second Floor, Chapel Allerton Hospital, Leeds LS7 4SA, UK.
E-mail: medhmo@leeds.ac.uk

Fig. 1 Axial spondyloarthritis continuum



Nr-axSpA, which may or may not be identified with and without bone marrow oedema as seen by MRI, may evolve over the years to r-axSpA previously known as AS, which is characterized by established changes of sclerosis, erosions and/or fusion in the sacroiliac joints and syndesmophytes or vertebral fusion in the spine in a proportion of cases. These changes are represented with the different colour grading (yellow/red) to illustrate the nr-axSpA–r-axSpA continuum. Those who will develop radiographic changes are represented as ‘progressors’ with risk factors such as a previously positive MRI, raised CRP and positive HLA-B27. A proportion of HLA-B27 positive subjects with negative MRIs may develop a raised CRP, placing them in the more severe or ‘progressor’ category. With time and a possible treatment effect, the number of ‘non-progressors’ can increase as shown. Fat metaplasia is represented as a post-inflammatory lesion after bone marrow oedema occurs and is a possible precursor of radiographic structural lesions. nr-axSpA: non-radiographic axial spondyloarthritis; r-axSpA: radiographic axSpA.

At the clinical level, the main challenge in the diagnosis of axSpA is the lack of biomarkers. This is in stark contrast with other diseases such as diabetes or rheumatoid arthritis to name a few, for which an abnormal blood sugar value or the presence of a specific serum antibody allow for a clinical diagnosis to be made with a high level of confidence and potentially at an early disease stage before irreversible damage occurs. In axSpA, however, the diagnostic toolkit is a composite of clinical, laboratory and imaging features put together by the specialist rheumatologist. It is this ‘expert opinion’ that was used to both develop and further validate the ASAS classification criteria [3]. Even inflammatory back pain, considered as the *princeps* symptom and widely adopted as a referral strategy, has been shown to have a limited specificity [5]. These are some of the reasons why, if classification criteria are used solely for diagnostic purposes, the risk of incorrect diagnosis and its consequences, such as overtreatment, might be high. In fact, if all expert judgement is removed, as in a recently published latent class analysis of axSpA early cohorts by Sepriano *et al.* [6], no identifiable division between nr- and r-axSpA can be found. The aim of this review is to update the current understanding of what is axSpA and the need to focus on the concept rather than its classification.

Prevalence and gender

There is a high heterogeneity in the prevalence reported for AS or r-axSpA spanning 0.007% to 0.54% with no specific studies reporting solely on nr-axSpA [7]. This increases to 1.4% when investigating the whole axSpA group [8]. These differences can be related to geographical distribution [9] and are probably driven by the prevalence of HLA-B27, which can be as high as 53% in a tribe in Papua Guinea [10]. The question remains whether patients in areas with a low prevalence of HLA-B27 are underdiagnosed whilst axSpA might be driven by other genetic factors [11].

The same proportion of patients with family history of SpA has been reported in nr- and r-axSpA reinforcing the idea of a common genetic background [12]. However, there is a paucity of data on immunopathogenesis, with some reports showing a difference in circulating cells with negative correlation between Th17 cells and disease activity in nr-axSpA compared with r-axSpA and controls [13]. Clearly, further research is needed to understand the pathogenesis of early axSpA and how it evolves throughout the disease.

One of the main misconceptions over time has been the consideration of axSpA as a predominantly male disease. The male: female ratio has decreased in recent

years with studies reporting nearly equivalent prevalence, particularly in nr-axSpA cohorts [14]. Differences in clinical presentation have been noted, with women presenting with more widespread pain, including neck and upper thoracic pain that may not conform to current ‘inflammatory back pain’ definitions [15] and less radiographic damage, all factors that may contribute to the reported longer diagnostic delay when compared with males [16]. Overall disease burden is higher in females [14], although this has not led to an increase in the overall biologic prescription [17].

Clinical presentation

Clinical presentation is crucial in identifying patients with axSpA, and therefore several studies have explored possible differences between nr-axSpA and r-axSpA [12]. As expected, presentation is similar in both subgroups although some particularities are worth discussing. Regarding symptom onset and diagnosis, nr-axSpA has a shorter disease duration and is diagnosed earlier in line with the continuum concept [18]. Remarkably, r-axSpA presents an earlier age at disease onset [19], and this has been shown to be significant in a recent meta-analysis [12]. The characteristics of the presenting low back pain between both subgroups have not been thoroughly studied, yet percentages of inflammatory back pain are similar in a referral study [20]. Focusing on peripheral manifestations, there are conflicting results depending on the inclusion criteria used by the two meta-analyses available [12, 21], with the largest study reporting a higher prevalence of peripheral arthritis, enthesitis and dactylitis on the nr-axSpA population, which may have reflected a selection bias as argued by the authors [12].

With regards to serum biomarkers, the main disparity is in the CRP, which appears to be higher in r-axSpA [12]. Intriguingly, a *post hoc* analysis of ABILITY-1 clinical trial revealed that a substantial amount of nr-axSpA patients with negative CRP at baseline developed an elevated CRP at week 12 [22]. If confirmed, this could suggest that CRP levels might rise as the disease evolves particularly in the subset of patients with more ‘severe’ phenotype who may become radiographic in time.

The burden of disease appears comparable regardless of the radiographic status, with disease activity measures such as the BASDAI reported as similar in several observational [19, 23] and randomized clinical trials [24, 25]. Comparable results were also found regarding the Ankylosing Spondylitis Disease Activity Score, with a similar performance in nr- and r-axSpA [26]. Unsurprisingly, radiographic axSpA is reported to have higher BASFI and BASMI [27], vindicated by a more severe radiographic involvement as discussed later in the text.

Imaging: progression vs non-progression

The diagnosis of axSpA is strongly anchored in imaging findings, particularly the presence of established

sacroiliitis features such as erosions or joint fusion. In consequence, imaging has had a fundamental role in the different classification criteria and these have been validated with clinician diagnosis, which is, otherwise, intricately influenced by imaging [3]. Hence the risk of possible overdiagnosis of axSpA if imaging findings are not interpreted correctly particularly in the context of MRI. Although MRI has become more widely available in the past two decades, clinicians’ understanding of MRI is not universal. Further, there are many shortcomings to the utility of MRI in axSpA. These include the lack of specificity of MRI lesions typically found in axSpA, such as bone marrow oedema (BMO), which can be found in other conditions including mechanically induced back pain or even in healthy subjects [28]. In addition, MRI may not identify active inflammatory lesions of BMO in up to 30% of HLA-B27 positive patients with clinical features of axSpA [29]. In fact, some studies have shown that only 15% of these subjects may eventually develop a so called ‘positive’ MRI over time, and this is restricted to those who are male and HLA-B27 positive [30, 31].

Yet, MRI has substantially aided the understanding of the natural history of axSpA. Motamedi *et al.* [32] compared the MRI findings between nr-axSpA and r-axSpA, identifying the same BMO score in both [when using the Spondyloarthritis Research Consortium of Canada (SPARCC) reading method], yet a higher erosion score was seen in the nr-axSpA group whereas more fat metaplasia was present in the r-axSpA group, supporting the concept that fat metaplasia might be a bone formation precursor as reported by other groups [33, 34]. Along the same lines, Maksymowych and colleagues [35] reported erosions in nr-axSpA even in the absence of BMO and higher spinal BMO scores in patients with structural lesions, adding evidence to the natural history of axSpA. Thus, prospective studies in early nr-axSpA have received major interest, especially when considering that treatment intervention might modify its evolution. A study performed in a cohort of young patients who had a diagnosis of enthesitis-related arthritis with axial involvement or nr-axSpA outlined a decrease of BMO scores after initiation of TNF inhibitors at a follow-up time of up to 9 years, yet progression of disease into SIJ fusion continued [36]. In contrast, in the RAPID-axSpA trial with certolizumab, a decrease in BMO scores was seen as well as limited radiographic progression in both the spine and SIJs although the follow-up time was much shorter at 4 years [37]. Taken together the available evidence suggests that baseline inflammation that is seen as BMO on MRI then develops into structural lesions that are visualized as definite changes of sclerosis, erosions or bone fusion with X-ray at a later stage, thus defining the continuity between nr-axSpA and r-axSpA in a subset of patients (Fig. 1).

Radiographic progression from nr-axSpA to r-axSpA has been established in around 10–40% of cases in a recent review of available literature [38] and is slow, taking many years to occur. Overall, although markers of

disease progression have been identified (HLA-B27 positivity, MRI detected BMO at baseline, elevated CRP) [38], the natural course of and treatment effect in nr-axSpA are not fully understood. Indeed, some reports highlight the fact that some patients classified as nr-axSpA may never progress to r-axSpA [39] suggesting that this milder, self-limiting form should not be considered the same disease. However and despite the fact that outcome is likely to be heterogeneous, as happens in other inflammatory conditions, there are many barriers for this to be fully characterized in nr-axSpA, since for instance, a substantial proportion of affected individuals are exposed to NSAIDs by the time they are first seen in secondary care, with the possible impact of these drugs on disease modification [40]. Further, long term observational studies in untreated cohorts would be impossible to perform due to ethical considerations.

Co-morbidities and extra-articular manifestations

Aside from spinal and articular features, patients with axSpA may present extra-articular manifestations, such as acute anterior uveitis (AAU), psoriasis and IBD. AAU is the most common extra-articular manifestation (32.7%), showing a higher frequency in r-axSpA compared with nr-axSpA [12, 21]. This could be explained by the difference in prevalence of HLA-B27 in some cohorts of nr- and r-axSpA, which is associated both with the development of AAU and with structural damage on SIJs [2, 41]. Moreover, the higher prevalence of AAU among r-axSpA patients can also be explained by the longer mean disease duration in this subgroup, leading to a higher cumulative probability of appearance of this symptom. By contrast, the prevalence of psoriasis and IBD seems to be similar in r-axSpA in comparison with nr-axSpA patients. However, when analysing the incidence of overall extra-articular and peripheral manifestations between r-axSpA and nr-axSpA over 5 years of follow-up, this was found comparable between the groups [42], supporting the concept of axSpA as one single disease irrespective of the presence of radiographic changes.

In addition to extra-articular manifestations, patients with axSpA may also suffer from other coexistent clinical disorders that appear as a consequence of persistent inflammatory activity and/or treatment outside the spectrum of SpA [9]. These coexistent disorders are named 'comorbidities'. Cardiovascular disease, specifically atherosclerosis, is responsible of the excess mortality in axSpA patients in comparison with the general population [43]. Gonzalez-Juanatey *et al.* [44] demonstrated that r-axSpA patients without cardiovascular disease showed a higher prevalence of subclinical atherosclerosis in comparison with healthy controls, while carotid plaques and intima-media thickness are not increased in patients with nr-axSpA [45]. These findings could be explained by the shorter disease duration and lower

CRP levels in nr-axSpA patients in comparison with r-axSpA patients. Despite this increased subclinical atherosclerosis in r-axSpA patients, a recent study using electronic medical records from two hospital in the USA demonstrated a comparable prevalence of coronary heart disease, heart failure and stroke between these two groups [46].

Osteoporosis is the most frequent comorbidity among patients with axSpA. Briot *et al.* [47, 48] demonstrated in the French DESIR cohort that radiographic sacroiliitis was not associated with low BMD either after 2 or after 5 years of follow-up, suggesting a similar risk of low BMD between r-axSpA and nr-axSpA patients. Consequently, both groups of patients demonstrated a comparable prevalence and incidence of vertebral fractures after 5 years of follow-up in this same cohort [49].

The prevalence of FM in axSpA patients is increased in comparison with the general population [50]. Interestingly, Baraliakos *et al.* [51] demonstrated that the prevalence of coexistent FM using both the 2010 and the 1990 criteria was more frequent in r-axSpA than in nr-axSpA, showing that nr-axSpA patients are not more especially prone to having FM-like symptoms than patients with established r-axSpA. These results were confirmed by Moltó *et al.* [52], who did not find an association between FM according to the FIRST questionnaire and the absence of radiographic sacroiliitis.

Treatment response

NSAIDs represent the cornerstone in axSpA treatment. No differences have been found either in the clinical response to these drugs or in the amount of NSAID usage between r-axSpA and nr-axSpA patients, confirming similarities in response rate and burden of disease [53].

Several randomized controlled trials have demonstrated the efficacy of biologic DMARDs in both r-axSpA and nr-axSpA with variable response rates likely due to the different inclusion criteria in the different studies [54]. The ESTHER trial, which included both r-axSpA and nr-axSpA treated with etanercept vs sulfasalazine, demonstrated similar results in terms of efficacy and safety data between r-axSpA and nr-axSpA groups up to year 4, suggesting a similar course of the disease [55]. Adalimumab has also demonstrated efficacy in both r-axSpA and nr-axSpA, but no studies evaluating direct comparisons between r-axSpA and nr-axSpA for adalimumab response have been conducted [56]. The RAPID-AS trial tested the efficacy of certolizumab vs placebo for both r-axSpA and nr-axSpA patients in the same study by including a stratified randomization for both groups. A direct comparison between the groups reported for the 6-month time point showed comparable ASAS40 responses [24]. Concerning golimumab, r-axSpA and nr-axSpA patients demonstrated significant improvement in their respective randomized controlled trials [57, 58]. However, patients with negative MRI and normal CRP levels at baseline did not differ in the response rate between golimumab and

placebo treatment in the nr-axSpA trial. Similarly, studies with the IL-17A blockers secukinumab and ixekizumab have been performed in both r-axSpA and nr-axSpA patients, demonstrating efficacy in both groups [59–61].

Real life data, however, remain scarce with only a few studies published to date. TNF inhibitor survival data and response are similar in both groups (nr-axSpA and r-axSpA) in the DANBIO registry [62] as well as two smaller studies [63, 64], whilst higher rates of response were seen in the r-axSpA group in the Swiss Clinical Quality Management cohort [19].

In summary, data available suggest comparable efficacy of biologic DMARDs between the two disease phenotypes, yet restrictions are in place in many countries worldwide in their use in nr-axSpA. Future clinical trials should include the entire disease spectrum rather than addressing r-axSpA and nr-axSpA as separate entities.

Conclusions

There is a growing body of evidence showing that nr- and r-axSpA is an artificial split of a single disease entity. The lack of a gold standard drives clinicians to rely heavily on imaging in order to make the diagnosis of axSpA with the consequent risks attached to the insufficient specificity and sensitivity of MRI and evident radiographic changes appearing too late in the disease course. axSpA should be regarded as a continuum to facilitate research in areas of unmet need including understanding the factors that determine disease progression, exploring treatment strategies that would allow for the best outcome for each affected individual and better characterizing the natural history of the disease.

Acknowledgements

H.M.-O. is supported by the National Institute for Health Research (NIHR) Leeds Biomedical Research Centre (LBRC). The views expressed are those of the authors and not necessarily those of the (UK) National Health Service (NHS), the NIHR, or the (UK) Department of Health.

Funding: No specific funding was received from any funding bodies in the public, commercial or not-for-profit sectors to carry out the work described in this manuscript. This paper was published as part of a supplement funded by Novartis.

Disclosure statement: H.M.-O. has received research grants from Janssen, Novartis and consultancy fees/honoraria from Abbvie, Celgene, Eli-Lilly, Janssen, Novartis, Pfizer, Takeda and UCB. The other authors have declared no conflicts of interest.

References

- 1 Sieper J, Poddubnyy D. Axial spondyloarthritis. *Lancet* 2017;390:73–84.
- 2 Dougados M, Sepriano A, Molto A *et al.* Sacroiliac radiographic progression in recent onset axial spondyloarthritis: the 5-year data of the DESIR cohort. *Ann Rheum Dis* 2017;76:1823–8.
- 3 Rudwaleit M, van der Heijde D, Landewe R *et al.* The development of Assessment of SpondyloArthritis International Society classification criteria for axial spondyloarthritis (part II): validation and final selection. *Ann Rheum Dis* 2009;68:777–83.
- 4 Mau W, Zeidler H, Mau R *et al.* Clinical features and prognosis of patients with possible ankylosing spondylitis. Results of a 10-year followup. *J Rheumatol* 1988;15:1109–14.
- 5 de Hooge M, van Gaalen FA, Renson T *et al.* Low specificity but high sensitivity of inflammatory back pain criteria in rheumatology settings in Europe: confirmation of findings from a German cohort study. *Ann Rheum Dis* 2019;78:1605–6.
- 6 Sepriano A, Ramiro S, van der Heijde D *et al.* What is axial spondyloarthritis? A latent class and transition analysis in the SPACE and DESIR cohorts. *Ann Rheum Dis* 2020;79:324–31.
- 7 Bohn R, Cooney M, Deodhar A, Curtis JR, Golembesky A. Incidence and prevalence of axial spondyloarthritis: methodologic challenges and gaps in the literature. *Clin Exp Rheumatol* 2018;36:263–74.
- 8 Reveille JD, Witter JP, Weisman MH. Prevalence of axial spondylarthritis in the United States: estimates from a cross-sectional survey. *Arthritis Care Res (Hoboken)* 2012;64:905–10.
- 9 Lopez-Medina C, Molto A. Update on the epidemiology, risk factors, and disease outcomes of axial spondyloarthritis. *Best Pract Res Clin Rheumatol* 2018; 32:241–53.
- 10 Bhatia K, Prasad ML, Barnish G, Koki G. Antigen and haplotype frequencies at three human leucocyte antigen loci (HLA-A, -B, -C) in the Pawaia of Papua New Guinea. *Am J Phys Anthropol* 1988;75: 329–40.
- 11 Kishimoto M, Yoshida K, Ichikawa N *et al.* Clinical characteristics of patients with spondyloarthritis in Japan in comparison with other regions of the world. *J Rheumatol* 2019;46:896–903.
- 12 López-Medina C, Ramiro S, van der Heijde D *et al.* Characteristics and burden of disease in patients with radiographic and non-radiographic axial Spondyloarthritis: a comparison by systematic literature review and meta-analysis. *RMD Open* 2019;5:e001108.
- 13 Bautista-Caro M-B, Arroyo-Villa I, Castillo-Gallego C *et al.* Decreased Th17 and Th1 cells in the peripheral blood of patients with early non-radiographic axial spondyloarthritis: a marker of disease activity in HLA-B27⁺ patients. *Rheumatology (Oxford)* 2013;52:352–62.
- 14 Rusman T, van Vollenhoven RF, van der Horst-Bruinsma IE. Gender differences in axial spondyloarthritis: women are not so lucky. *Curr Rheumatol Rep* 2018;20:35.

- 15 Slobodin G, Reyhan I, Avshovich N *et al*. Recently diagnosed axial spondyloarthritis: gender differences and factors related to delay in diagnosis. *Clin Rheumatol* 2011;30:1075–80.
- 16 Jovani V, Blasco-Blasco M, Ruiz-Cantero MT, Pascual E. Understanding how the diagnostic delay of spondyloarthritis differs between women and men: a systematic review and metaanalysis. *J Rheumatol* 2017;44:174–83.
- 17 Nieto RE, Plasencia Rodriguez C, Peiteado López D *et al*. Are we treating women patients with real axial spondyloarthritis? *Semin Arthritis Rheum* 2019;50:432–5.
- 18 Poddubnyy D, Brandt H, Vahldiek J *et al*. The frequency of non-radiographic axial spondyloarthritis in relation to symptom duration in patients referred because of chronic back pain: results from the Berlin early spondyloarthritis clinic. *Ann Rheum Dis* 2012;71:1998–2001.
- 19 Ciurea A, Scherer A, Exer P *et al*.; Rheumatologists of the Swiss Clinical Quality Management Program for Axial Spondyloarthritis. Tumor necrosis factor α inhibition in radiographic and nonradiographic axial spondyloarthritis: results from a large observational cohort. *Arthritis Rheum* 2013;65:3096–106.
- 20 Poddubnyy D, Callhoff J, Spiller I *et al*. Diagnostic accuracy of inflammatory back pain for axial spondyloarthritis in rheumatological care. *RMD Open* 2018;4:e000825.
- 21 de Winter JJ, van Mens LJ, van der Heijde D, Landewé R, Baeten DL. Prevalence of peripheral and extra-articular disease in ankylosing spondylitis versus non-radiographic axial spondyloarthritis: a meta-analysis. *Arthritis Res Ther* 2016;18:196.
- 22 Baraliakos X, Sieper J, Chen S, Pangan AL, Anderson JK. Non-radiographic axial spondyloarthritis patients without initial evidence of inflammation may develop objective inflammation over time. *Rheumatology (Oxford)* 2017;56:1162–6.
- 23 Rudwaleit M, Haibel H, Baraliakos X *et al*. The early disease stage in axial spondylarthritis: results from the German Spondyloarthritis Inception Cohort. *Arthritis Rheum* 2009;60:717–27.
- 24 Landewé R, Braun J, Deodhar A *et al*. Efficacy of certolizumab pegol on signs and symptoms of axial spondyloarthritis including ankylosing spondylitis: 24-week results of a double-blind randomised placebo-controlled Phase 3 study. *Ann Rheum Dis* 2014;73:39–47.
- 25 Song I-H, Weiß A, Hermann K-G *et al*. Similar response rates in patients with ankylosing spondylitis and non-radiographic axial spondyloarthritis after 1 year of treatment with etanercept: results from the ESTHER trial. *Ann Rheum Dis* 2013;72:823–5.
- 26 Fernández-Espartero C, de Miguel E, Loza E *et al*.; ESPERANZA Study Group. Validity of the Ankylosing Spondylitis Disease Activity Score (ASDAS) in patients with early spondyloarthritis from the Esperanza programme. *Ann Rheum Dis* 2014;73:1350–5.
- 27 Sieper J, Hu X, Black CM *et al*. Systematic review of clinical, humanistic, and economic outcome comparisons between radiographic and non-radiographic axial spondyloarthritis. *Semin Arthritis Rheum* 2017;46:746–53.
- 28 de Winter J, de Hooge M, van de Sande M *et al*. Magnetic resonance imaging of the sacroiliac joints indicating sacroiliitis according to the Assessment of Spondyloarthritis International Society definition in healthy individuals, runners, and women with postpartum back pain. *Arthritis Rheumatol* 2018;70:1042–8.
- 29 van Onna M, Jurik AG, van der Heijde D *et al*. HLA-B27 and gender independently determine the likelihood of a positive MRI of the sacroiliac joints in patients with early inflammatory back pain: a 2-year MRI follow-up study. *Ann Rheum Dis* 2011;70:1981–5.
- 30 Bakker PAC, Ramiro S, Ez-Zaitouni Z *et al*. Is it useful to repeat magnetic resonance imaging of the sacroiliac joints after three months or one year in the diagnosis of patients with chronic back pain and suspected axial spondyloarthritis? *Arthritis Rheumatol* 2019;71:382–91.
- 31 Sengupta R, Marzo-Ortega H, McGonagle D, Wadeley A, Bennett AN. Short-term repeat magnetic resonance imaging scans in suspected early axial spondyloarthritis are clinically relevant only in HLA-B27-positive male subjects. *J Rheumatol* 2018;45:202–5.
- 32 Motamedi D, Patel R, Devulapalli KK, Gensler LS, Steinbach L. MR distribution of active inflammatory and chronic structural sacroiliac joint changes in axial spondyloarthropathy: challenging conventional wisdom. *Clin Imaging* 2019;58:70–3.
- 33 Kang KY, Kim IJ, Yoon MA *et al*. Fat metaplasia on sacroiliac joint magnetic resonance imaging at baseline is associated with spinal radiographic progression in patients with axial spondyloarthritis. *PLoS One* 2015;10:e0135206.
- 34 Maksymowych WP, Wichuk S, Chiowchanwisawakit P, Lambert RG, Pedersen SJ. Fat metaplasia and backfill are key intermediaries in the development of sacroiliac joint ankylosis in patients with ankylosing spondylitis. *Arthritis Rheumatol* 2014;66:2958–67.
- 35 Maksymowych W P, Wichuk S, Dougados M *et al*. MRI evidence of structural changes in the sacroiliac joints of patients with non-radiographic axial spondyloarthritis even in the absence of MRI inflammation. *Arthritis Research & Therapy* 2017;19:10.1186/s13075-017-1342-9.
- 36 Bray TJP, Lopes A, Fisher C *et al*. Sacroiliac joint ankylosis in young spondyloarthritis patients receiving biologic therapy: observation of serial magnetic resonance imaging scans. *Arthritis Rheumatol* 2019;71:594–8.
- 37 van der Heijde D, Baraliakos X, Hermann K-G *et al*. Limited radiographic progression and sustained reductions in MRI inflammation in patients with axial spondyloarthritis: 4-year imaging outcomes from the RAPID-axSpA phase III randomised trial. *Ann Rheum Dis* 2018;77:699–705.
- 38 Protopopov M, Poddubnyy D. Radiographic progression in non-radiographic axial spondyloarthritis. *Expert Rev Clin Immunol* 2018;14:525–33.
- 39 Robinson PC, Wordsworth BP, Reveille JD, Brown MA. Axial spondyloarthritis: a new disease entity, not

- necessarily early ankylosing spondylitis. *Ann Rheum Dis* 2013;72:162–4.
- 40 Wanders A, Heijde D, Landewe R *et al.* Nonsteroidal antiinflammatory drugs reduce radiographic progression in patients with ankylosing spondylitis: a randomized clinical trial. *Arthritis Rheum* 2005;52:1756–65.
 - 41 Bacchiega ABS, Balbi GGM, Ochtrop MLG *et al.* Ocular involvement in patients with spondyloarthritis. *Rheumatology (Oxford)* 2017;56:2060–7.
 - 42 López-Medina C, Molto A, Claudepierre P, Dougados M. Clinical manifestations, disease activity and disease burden of radiographic versus non-radiographic axial spondyloarthritis over 5 years of follow-up in the DESIR cohort. *Ann Rheum Dis* 2020;79:209–16.
 - 43 Exarchou S, Lie E, Lindström U *et al.* Mortality in ankylosing spondylitis: results from a nationwide population-based study. *Ann Rheum Dis* 2016;75:1466–72.
 - 44 Gonzalez-Juanatey C, Vazquez-Rodriguez TR, Miranda-Filloo JA *et al.* The high prevalence of subclinical atherosclerosis in patients with ankylosing spondylitis without clinically evident cardiovascular disease. *Medicine (Baltimore)* 2009;88:358–65.
 - 45 Rueda-Gotor J, Llorca J, Corrales A *et al.* Subclinical atherosclerosis is not increased in patients with non-radiographic axial spondyloarthritis. *Clin Exp Rheumatol* 2016;34:159–60.
 - 46 Zhao SS, Ermann J, Xu C *et al.* Comparison of comorbidities and treatment between ankylosing spondylitis and non-radiographic axial spondyloarthritis in the United States. *Rheumatology (Oxford)* 2019;58:2025–30.
 - 47 Briot K, Etcheto A, Miceli-Richard C, Dougados M, Roux C. Bone loss in patients with early inflammatory back pain suggestive of spondyloarthritis: results from the prospective DESIR cohort. *Rheumatology (Oxford)* 2016;55:335–42.
 - 48 Fechtenbaum M, Molto A, Roux C *et al.* Baseline MRI inflammation is not a determinant of 5-year bone mineral density loss in patients with early spondyloarthritis. *Joint Bone Spine* 2020;87:63–8.
 - 49 Sahuguet J, Fechtenbaum J, Molto A *et al.* Low incidence of vertebral fractures in early spondyloarthritis: 5-year prospective data of the DESIR cohort. *Ann Rheum Dis* 2019;78:60–5.
 - 50 Zhao SS, Duffield SJ, Goodson NJ. The prevalence and impact of comorbid fibromyalgia in inflammatory arthritis. *Best Pract Res Clin Rheumatol* 2019;33:101423.
 - 51 Baraliakos X, Regel A, Kiltz U *et al.* Patients with fibromyalgia rarely fulfil classification criteria for axial spondyloarthritis. *Rheumatology (Oxford)* 2018;57:1541–7.
 - 52 Moltó A, Etcheto A, Gossec L *et al.* Evaluation of the impact of concomitant fibromyalgia on TNF alpha blockers' effectiveness in axial spondyloarthritis: results of a prospective, multicentre study. *Ann Rheum Dis* 2018;77:533–40.
 - 53 Baraliakos X, Kiltz U, Peters S *et al.* Efficiency of treatment with non-steroidal anti-inflammatory drugs according to current recommendations in patients with radiographic and non-radiographic axial spondyloarthritis. *Rheumatology (Oxford)* 2017;56:95–102.
 - 54 Rios Rodriguez V, Poddubnyy D. Tumor necrosis factor- α (TNF α) inhibitors in the treatment of nonradiographic axial spondyloarthritis: current evidence and place in therapy. *Ther Adv Musculoskelet Dis* 2017;9:197–210.
 - 55 Song I-H, Hermann K-G, Haibel H *et al.* Consistently good clinical response in patients with early axial spondyloarthritis after 3 years of continuous treatment with etanercept: longterm data of the ESTHER trial. *J Rheumatol* 2014;41:2034–40.
 - 56 van der Heijde D, Joshi A, Pangan AL *et al.* ASAS40 and ASDAS clinical responses in the ABILITY-1 clinical trial translate to meaningful improvements in physical function, health-related quality of life and work productivity in patients with non-radiographic axial spondyloarthritis. *Rheumatology (Oxford)* 2016;55:80–8.
 - 57 Inman RD, Davis JC Jr, van der Heijde D *et al.* Efficacy and safety of golimumab in patients with ankylosing spondylitis: results of a randomized, double-blind, placebo-controlled, phase III trial. *Arthritis Rheum* 2008;58:3402–12.
 - 58 Sieper J, van der Heijde D, Dougados M *et al.* A randomized, double-blind, placebo-controlled, sixteen-week study of subcutaneous golimumab in patients with active nonradiographic axial spondyloarthritis. *Arthritis Rheumatol* 2015;67:2702–12.
 - 59 Baraliakos X, Braun J, Deodhar A *et al.* Long-term efficacy and safety of secukinumab 150 mg in ankylosing spondylitis: 5-year results from the phase III MEASURE 1 extension study. *RMD Open* 2019;5:e001005.
 - 60 van der Heijde D, Cheng-Chung Wei J, Dougados M *et al.* Ixekizumab, an interleukin-17A antagonist in the treatment of ankylosing spondylitis or radiographic axial spondyloarthritis in patients previously untreated with biological disease-modifying anti-rheumatic drugs (COAST-V): 16 week results of a phase 3 randomised, double-blind, active-controlled and placebo-controlled trial. *Lancet* 2018;392:2441–51.
 - 61 Deodhar A, van der Heijde D, Gensler LS *et al.* Ixekizumab for patients with non-radiographic axial spondyloarthritis (COAST-X): a randomised, placebo-controlled trial. *Lancet* 2020;395:53–64.
 - 62 Grintborg B, Sørensen IJ, Østergaard M *et al.* Ankylosing spondylitis versus nonradiographic axial spondyloarthritis: comparison of tumor necrosis factor inhibitor effectiveness and effect of HLA-B27 status. An observational cohort study from the Nationwide DANBIO Registry. *J Rheumatol* 2017;44:59–69.
 - 63 Corli J, Flipo R-M, Philippe P *et al.* Tumor necrosis factor- α inhibition in ankylosing spondylitis and nonradiographic axial spondyloarthritis: treatment response, drug survival, and patient outcome. *J Rheumatol* 2015;42:2376–82.
 - 64 Wallman JK, Kapetanovic MC, Petersson IF, Geborek P, Kristensen LE. Comparison of non-radiographic axial spondyloarthritis and ankylosing spondylitis patients – baseline characteristics, treatment adherence, and development of clinical variables during three years of anti-TNF therapy in clinical practice. *Arthritis Res Ther* 2015;17:378.