



# Pulmonary Infections: Pneumonia

Roger Eibel and Jan Mueller

## Contents

1	<b>Definition</b> .....	384
2	<b>Pathogenesis</b> .....	384
3	<b>Classification</b> .....	384
3.1	Community-Acquired Acute Pneumonia (CAP).....	384
3.2	Community-Acquired Atypical Pneumonias.....	385
3.3	Nosocomial Pneumonia.....	386
3.4	Chronic Pneumonia.....	386
3.5	Pneumonia in the Immunocompromised Host.....	387
4	<b>MRI: Historical Development of Imaging Concepts</b> .....	389
5	<b>MRI: Comparison with CT</b> .....	393
6	<b>Morphology of Different Types of Pneumonia in MR Imaging</b> .....	395
7	<b>Protocol</b> .....	396
8	<b>Further Developments</b> .....	396
	<b>References</b> .....	399

## Abstract

The different appearances of pneumonia such as ill-defined nodules, ground-glass opacities, and consolidations can be easily detected and differentiated with MRI. Since very small nodules and calcifications are extremely challenging due to rather thick slices and loss of signal, MRI is highly recommended as a follow-up tool, to avoid repetitive investigations using ionizing radiation. With the sensitivity of T2-weighted sequences and the potential of contrast-enhanced T1-weighted sequences, important differential diagnostic considerations can be provided. Additionally, developing complications, such as pericardial or pleural effusions, empyema or lung abscess, are easily recognized. Current and future studies are to demonstrate that MRI is well suited as a monitoring and follow-up tool during and after therapy and compares favorably with CT or other imaging methods regarding sensitivity and specificity.

R. Eibel, MD (✉)

Department of Radiology, Pediatric- and  
Neuroradiology, HELIOS Kliniken Schwerin,  
Teaching Hospital of the University of Rostock,  
Wismarsche Str. 393, 19049 Schwerin, Germany  
e-mail: [roger.eibel@helios-kliniken.de](mailto:roger.eibel@helios-kliniken.de)

J. Mueller, MD

Diagnostic and Interventional Radiology, University  
Hospital Heidelberg,  
Im Neuenheimer Feld 110, 69120 Heidelberg,  
Germany  
e-mail: [jan.mueller@med.uni-heidelberg.de](mailto:jan.mueller@med.uni-heidelberg.de)

## Key Points

The different appearances of pneumonia such as ill-defined nodules, ground-glass opacities, and consolidations can be easily detected and differentiated with MRI. Since very small nodules and calcifications are extremely challenging due to rather thick slices and loss of signal, MRI is highly recommended as a follow-up tool, to

avoid repetitive investigations using ionizing radiation. With the sensitivity of T2-weighted sequences and the potential of contrast-enhanced T1-weighted sequences, important differential diagnostic considerations can be provided. Additionally, developing complications, such as pericardial or pleural effusions, empyema or lung abscess, are easily recognized. Current and future studies are to demonstrate that MRI is well suited as a monitoring and follow-up tool during and after therapy and compares favorably with CT or other imaging methods regarding sensitivity and specificity.

## 1 Definition

Pneumonia is an infection of the gas-exchanging units of the lung, caused most commonly by bacteria but occasionally by viruses, fungi, parasites, and other infectious agents.

Pneumonia is the sixth leading cause of death in the United States, and the leading cause of death from infectious disease (Niederman et al. 2001). In hospitalized patients, particularly those who are mechanically ventilated, pneumonia is the leading cause of death from nosocomial infection (Campbell et al. 1996).

## 2 Pathogenesis

Pneumonia can result whenever the pulmonary defense mechanisms are impaired or the resistance of the host in general is lowered. Factors that affect resistance in general include:

- Chronic diseases
- Immunologic deficiency
- Treatment with immunosuppressive agents
- Leukopenia
- Unusually virulent infections

The clearing mechanisms can be interfered with by many factors, such as the following:

- Loss or suppression of the cough reflex (coma, drugs)
- Injury to the mucociliary apparatus (cigarette smoke, gas inhalation, viral diseases)
- Interference with the phagocytic or bactericidal action of alveolar macrophages (alcohol, smoke)
- Pulmonary congestion and edema
- Accumulation of secretions (cystic fibrosis, bronchial obstruction)

Some other points need to be emphasized, before listing the different classification schemes. (1) One type of pneumonia sometimes predisposes to another, especially in debilitated patients. (2) Although the portal of entry for most pneumonias is the respiratory tract, hematogenous spread from other organs can occur. (3) Many patients with chronic disease acquire terminal pneumonias while hospitalized.

## 3 Classification

Pneumonias are classified by the specific etiologic agent which determines the treatment, or, if no pathogen can be isolated, by the clinical setting in which the infection occurs. In the following text, the different entities of the pneumonia syndromes are briefly discussed to clarify the terms, the characteristics, and the peculiarities.

### 3.1 Community-Acquired Acute Pneumonia (CAP)

CAP may be bacterial or viral. Often, the bacterial infection follows an upper respiratory tract viral infection. Bacterial invasion of the lung parenchyma causes the alveoli to be filled with an inflammatory exudate, thus causing consolidation of the pulmonary tissue (Husain and Kumar 2005). Predisposing conditions include extremes of:

- Age
- Chronic diseases (congestive heart failure, COPD, and diabetes)

- Congenital or acquired immune deficiencies
- Decreased or absent splenic function (post-splenectomy, sickle cell disease)

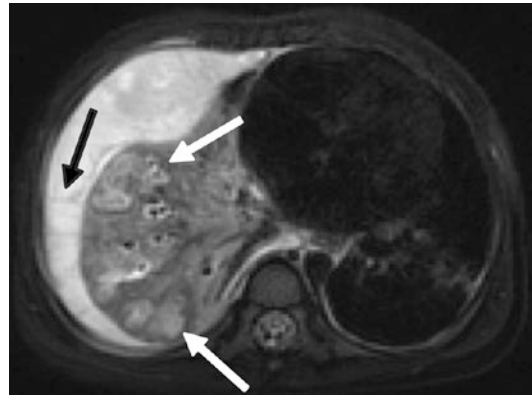
It is beyond the scope of this chapter to describe the different pneumonias caused by various organisms, but with regard to MRI it is necessary to mention the different morphologic features common to most pneumonias.

According to the anatomic distribution in the lung, the two major categories are lobar versus bronchopneumonia. *Lobar pneumonia* is a classic manifestation of pneumococcal pneumonia in which an entire lobe is affected by the inflammatory infiltrate, with extension to the pleura or a major fissure. In patients with this type, the stages of pneumonia progress from

- Edema to
- Red hepatization (alveolar fibrin, neutrophils, lymphocytes, and pneumocyte hyperplasia)
- Gray hepatization (predominantly neutrophilic infiltrates with lysis of erythrocytes and inflammatory cells)
- Resolution (organizing pneumonia, macrophages, proliferation of loose connective tissue in distal airspaces)

The basic *radiographic pattern* of this type of pneumonia is a homogeneous consolidation with or without air bronchogram. The consolidation is bounded by the fissure and in contrast to an atelectasis no shrinkage or volume loss can be observed in the acute phase.

*Bronchopneumonia* is also known as lobular or focal pneumonia. It is characterized by centrilobular inflammation that is concentrated around respiratory bronchioles, with spread to the surrounding alveolar ducts and alveolar spaces. When lobular pneumonia becomes confluent, it may be difficult to separate from lobar pneumonia. From a clinical standpoint, it is sometimes difficult to apply these classic categories, more important for imaging is the determination of the extent of disease and the delineation of complications (abscess formation, empyema, organization, and dissemination, e.g., Fig. 1).



**Fig. 1** A 3-year-old child with complicated pneumonia. T2-weighted MRI sequence clearly delineates intrapulmonary abscesses as focal areas of increased intensity with a hypointense rim in the right lower lobe (*white arrows*) and a large septated pleural effusion consistent with empyema (*black arrow*)

Common *radiographic findings* are nodular and patchy patterns due to involvement and sparing of acini. Sometimes volume loss can be found.

### 3.2 Community-Acquired Atypical Pneumonias

The term “atypical” refers to the following findings:

- Moderate amount of sputum
- No physical findings of consolidation
- Only moderate elevation of white cell count
- Lack of alveolar exudate

Most commonly this type of pneumonia is caused by *Mycoplasma pneumoniae*, viruses, and *Chlamydia pneumoniae*. These agents produce primarily an interstitial inflammation within the walls of the alveoli, resulting in thickening of the alveolar septa, later fluid accumulation, and cellular exudate into the alveolar spaces. Superimposed bacterial infection modifies the histologic and the subsequent radiologic picture (Husain and Kumar 2005).

Interpreting chest films and especially CT, *radiographic patterns* that can be found in this category are peribronchial, reticular, and

reticulonodular thickening; ground-glass opacification with filling of the acini; and sometimes a crazy-paving pattern. In some cases also a subsegmental collapse can be delineated.

### 3.3 Nosocomial Pneumonia

In 1995, the American Thoracic Society published a consensus statement defining nosocomial or hospital-acquired pneumonia (HAP) as a pneumonia that is

- Not incubating at the time of hospital admission
- Begins more than 48 h after admission (Campbell et al. 1996)

There are 300,000 cases of HAP annually in the United States, and it carries an associated mortality of 30–70% (McEachern and Campbell 1998). HAP is common in patients with severe underlying disease, prolonged antibiotics, intravascular devices, and mechanical ventilation. The latter is also termed ventilator-associated pneumonia (VAP). In a prospective study of 1014 mechanically ventilated patients, VAP developed in 177 patients. The mean time to onset was 9 days, with a median time to onset of 7 days after ICU admission. However, when the daily hazard rate of infection was calculated, it was estimated to be 3.3% at day 5, 2.3% at day 10, and 1.3% at day 15 (Cook et al. 1998). This documents a significant decline in pneumonia risk with time. Because the risk for pneumonia is so high early after intubation, pneumonias beginning within the first 5 days (*early-onset infection*) account for 50% of all episodes of VAP, and the natural history and pathogens of this infection differ from those associated with VAP of *late onset* (Prod'hom et al. 1994). Common isolates are gram-negative bacteria and *Staphylococcus aureus*. Typical radiologic patterns cannot be described. This is due to the different circumstances and risk factors, which contribute to the development of HAP. The other explanations are the different organisms responsible for the pneumonia. Within the first days the more common organisms are *Streptococcus pneumoniae*, *Moraxella catarrhalis*, *Staphylococcus aureus*, and

*Hemophilus influenzae* (Craven and Steger 1995). Later on, gram-negative rods predominate.

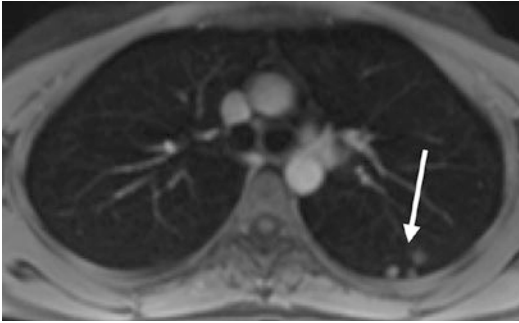
Microaspiration of contaminated oropharyngeal secretions seems to be the most frequent cause of HAP (McEachern and Campbell 1998). After macroaspiration, another subtype of pneumonia can occur, termed *aspiration pneumonia*. The resultant pneumonia is partly chemical, owing to the extremely irritating effects of the gastric acid appearing like pulmonary edema, and partly bacterial (from the oral flora). This type of pneumonia is often necrotizing, with abscess formation as a common complication (Husain and Kumar 2005). Typical radiographic pattern in this particular type of pneumonia are patchy consolidations in dependent portions of the lung with a multilobar and bilateral distribution.

Diagnosing HAP is difficult because there is no method for obtaining a diagnosis that is reliable in all cases. The diagnosis is initially made on clinical grounds by the finding of a new infiltrate on chest radiograph, fever, purulent sputum, or other signs of clinical deterioration. Unfortunately, this clinical method was shown to be specific for HAP in only 27 of 84 patients in a series reported by Fagon et al. (1993) because many other conditions such as congestive heart failure, pulmonary embolism, atelectasis, ARDS, pulmonary hemorrhage, or drug reactions may mimic pneumonia, particularly in critically ill patients. While there are many different testing modalities that may be employed, all have their limitations and none is sufficiently sensitive and specific to be considered a “gold standard” test (Rello et al. 2001).

### 3.4 Chronic Pneumonia

Chronic pneumonia results from granulomatous inflammation, due to bacteria (e.g., *Mycobacterium tuberculosis*, Fig. 2) or fungi (e.g., *Histoplasma capsulatum*, *Blastomyces dermatidis*, *Coccidioides immitis*). It is most often a localized lesion in the immunocompetent patient. Unlike tuberculosis, the abovementioned fungal species are geographic as they cause disease in particular areas in the United States and in Mexico.

In the lungs, these infections produce epithelioid cell granulomas, which usually undergo



**Fig. 2** A 31-year-old immunocompetent woman 12 months after exposure to tuberculosis. Positive QuantiFERONE test. Persistent sharply defined noduli in the posterior segment of the left upper lobe, consistent with tuberculomas (*arrow*). Tuberculomas can be found in primary and postprimary disease and may eventually calcify

coagulative necrosis and coalesce to produce larger areas of consolidation. Furthermore, they can liquefy to form cavities. Spontaneously or during therapy, these lesions can undergo fibrosis and concentric calcification. As a consequence, the typical *radiographic appearance* of this type of pneumonia is single or multiple lung nodules with or without calcification.

### 3.5 Pneumonia in the Immunocompromised Host

The appearance of pulmonary infiltrates and signs of infection (e.g., fever) are one of the most common and serious complications in patients whose immune and defense systems are limited by disease, immunosuppression for organ transplantation and tumors, or irradiation (Rosenow 1990).

The host defense system includes physical and chemical barriers to infection, the inflammatory response, and the immune response. Physical barriers, such as the skin and mucous membranes, prevent invasion by most organisms. Chemical barriers include lysozymes and hydrochloric acid. Lysozymes destroy bacteria by removing cell walls. Hydrochloric acid breaks down food and mucus that contains pathogens. The inflammatory response involves polymorphonuclear leukocytes, basophils, mast cells, platelets, and, to some extent, monocytes and macrophages. The immune response primarily involves the interaction of

lymphocytes (T and B), macrophages, and macrophage-like cells and their products. These cells may be circulating or may be localized in the immune system's tissues and organs (Springhouse 2007). Primary immune deficiency diseases are disorders in which part of the body's immune system is missing or does not function properly. In contrast to secondary immune deficiency disease in which the immune system is compromised by factors outside the immune system, such as viruses or chemotherapy, the primary immune deficiency diseases are caused by intrinsic or genetic defects in the immune system.

*Primary immunodeficiencies* are complex diseases. Since each one can be traced to the failure of one or more parts of the immune system, one of the more convenient ways to group them is according to the part of the immune system that is insufficient:

- B cell (antibody) deficiencies
- Combined T cell and B cell (antibody) deficiencies
- T cell deficiencies
- Defective phagocytes
- Complement deficiencies
- Deficiencies/cause unknown

Antibody deficiencies can hinder or prevent the immune system from recognizing and marking for destruction bacteria, viruses, and other foreign invaders. X-linked agammaglobulinemia, an inherited deficiency that appears in the first 3 years of life, leaves infants and young children with recurrent infections of the ears, lungs, sinuses and bones, and increased susceptibility to such viruses as hepatitis and polio.

Combined immunodeficiencies occur in people who lack the T lymphocytes that develop into killer cells that destroy infected cells or become helper cells that communicate with other immune cells. X-linked severe combined immunodeficiency, most often diagnosed during the first year of life, allows organisms that do not affect people with healthy immune systems to cause frequent and life-threatening infections.

Complement deficiencies usually involve an absence of one or several of the proteins that contribute to the complement system's ability to

attach to antibody-coated foreign invaders. In childhood or early adulthood, a complement deficiency can result in severe infections such as meningitis, or it can contribute to an autoimmune disease such as lupus erythematosus.

Phagocytic cell deficiencies result in the inability of cells that engulf and kill antibody-coated invaders to act efficiently to remove pathogens or infected cells from the body. Chronic granulomatous disease, the most severe form of phagocytic deficiency, usually appears in early childhood. It causes frequent and severe infections of the skin, lungs, and bones, leaving swollen collections of inflamed tissue called granulomas.

In comparison to the secondary syndromes, primary immunodeficiencies are rare.

There are a number of common conditions associated with *secondary immunodeficiency* (Bonilla et al. 2014).

A wide variety of so-called opportunistic infectious agents, many of which rarely cause infection in normal hosts, can cause these pneumonias where often more than one agent is involved. The mortality from these opportunistic infections is high. On the other hand, the list of differential diagnoses of such infiltrates is long and includes drug reactions, cardiac failure, and involvement of the lung by tumor or other underlying conditions. Table 1 lists some of the opportunistic agents according to their prevalence and whether they cause local or diffuse pulmonary infiltrates. The large group of immunocompromised patients sometimes is divided into AIDS and non-AIDS causes of immunosuppression. The types of infection to which HIV-positive patients become susceptible vary as cell-mediated immunity becomes less effective at eradicating viruses, fungi, protozoa, and facultative intracellular bacteria, such as *Mycobacterium tuberculosis*. Knowledge of the CD4 lymphocyte count can thus be helpful for interpretation of radiologic images in AIDS patients (Marquardt and Jablonowski 2003). Table 2 gives a short overview of the CD4 counts and corresponding infections.

As mentioned previously, the radiographic patterns in most of the cases are not pathognomonic and the pattern approach is limited by underlying and concomitant diseases, by the

**Table 1** Causes of pulmonary infiltrates in immunocompromised hosts

Diffuse infiltrates	Focal infiltrates
<i>Common</i>	<i>Common</i>
Cytomegalovirus	Gram-negative rods
<i>Pneumocystis jiroveci</i>	<i>Staphylococcus aureus</i>
Drug reaction	<i>Aspergillus</i>
	<i>Candida</i>
	Malignancy
<i>Uncommon</i>	<i>Uncommon</i>
Bacteria	Cryptococcus
<i>Aspergillus</i>	Mucor
Cryptococcus	<i>Pneumocystis jiroveci</i>
Malignancy	<i>Legionella pneumophila</i>

The table was published in Husain and Kumar (2005)

**Table 2** Overview of the CD4 counts and corresponding infections

HIV: complications at CD4 >500/mm <sup>3</sup>	HIV: complications at CD4 200–500/mm <sup>3</sup>
<i>Infectious</i>	<i>Infectious</i>
Acute retroviral syndrome	Pneumococcal pneumonia
Candida vaginitis	Tuberculosis
	Herpes zoster
	Kaposi sarcoma
	Oral hairy leukoplakia (OHL)
	Oropharyngeal candidiasis (thrush)
<i>Other</i>	<i>Noninfectious</i>
Generalized lymphadenopathy	Cervical carcinoma
Guillain-Barre (very rare)	Lymphomas
Vague constitutional symptoms	Immune thrombocytopenic purpura (ITP)

severity and time factor of manifestation, and by the treatment. It is frequently impossible for the clinician to identify the causative organism of a pneumonic infiltrate. Narrowing of the etiologic differential diagnosis may be possible using *radiologic pattern* recognition and the integration with clinical and laboratory information. Although with pattern recognition, specific etiologic diagnoses can hardly ever be established, patterns help to classify groups of potentially underlying organisms.

As a general rule of thumb, localized segmental or lobar alveolar densities can be attributed to typical or atypical bacterial infections. Diffuse bilateral interstitial and/or interstitial alveolar infiltrates most commonly are caused by viruses, atypical bacteria, and protozoa.

Micronodular disease is most often caused by military tuberculosis (miliary pattern), candidiasis, and histoplasmosis (small nodules), or viruses such as herpes or varicella zoster virus (diffuse nodules with hazy borders). Large, nodular lesions may represent bacterial abscesses, and in immunocompromised patients, may be caused by invasive aspergillosis and nocardia.

In conclusion, the important tasks of imaging the lung with respect to pneumonia are:

- Detection of pulmonary abnormalities
- Support in narrowing the etiology or differential diagnosis
- Recognition of developing complications
- Demonstration of a therapeutic effect (cave: radiographic patterns may change, even deteriorate with improvement of the immunologic status of the patient)

Looking at MRI for detection of pneumonia, the next part of this chapter is divided into a historical overview mentioning older and recent MR imaging concepts and a comparison of MRI with CT in the detection of pulmonary abnormalities suspicious for pulmonary infection.

---

## 4 MRI: Historical Development of Imaging Concepts

Moore et al. (1986) investigated the differentiation of various causes of pulmonary consolidations with MRI. They analyzed patients with pulmonary edema, postobstructive pneumonitis, alveolar proteinosis, *Pneumocystis* pneumonia, lobar nonobstructive pneumonia, pulmonary hemorrhage, and acute radiation pneumonitis. The study was performed with a 0.35-T MR scanner, using spin-echo pulse sequences with repetition times of 500 and 2000 ms and echo times (TE) of 28 and 56 ms. The authors could

demonstrate that measuring T1 and T2 values for different entities showed considerable overlap. The two patients with pulmonary alveolar proteinosis showed much lower values of T1, which probably reflects the relative absence of water within the airspaces and the presence of lipoprotein. In general, T1 and T2 values increase in proportion to the water content of fluids or tissue, but they are also influenced by the presence of lipids and by interaction between water and both large and small molecules with which they come in contact (Moore et al. 1986).

High-resolution computed tomography (HRCT) had become the gold standard in the evaluation of chronic infiltrative lung diseases, and it was shown that it accurately reflects the pathologic abnormalities. The aim of a study from Müller et al. (1992) was to compare MRI with HRCT in the assessment of these entities. All MR studies were performed on a 1.5-T MR imager. Cardiac-gated proton density-weighted and relatively T2-weighted images were obtained at two or three RR intervals. The slice thickness was 10 mm, with a 1- or 2-mm interslice gap. In comparison to this, the CT scans were obtained by using 1.5-mm collimation scans and 10-mm intervals.

As a result, MRI was consistently inferior in the anatomic assessment of lung parenchyma and in showing interstitial abnormalities, particularly fibrosis. Furthermore, areas of mild interstitial abnormalities seen on CT were often not apparent on MRI. But, on the other hand, MRI was comparable to CT in the assessment of air-space abnormalities. In all patients, areas with ground-glass opacities or air-space consolidation on CT corresponded to areas of increased signal intensity on MRI (Müller et al. 1992).

Primack et al. noticed that the use of MRI in the assessment of infiltrative lung disease has been limited by the low proton density of lung parenchyma and by loss of signal due to motion and the difference in diamagnetic susceptibility of air and soft tissue. On the other hand, the presence of pulmonary infiltrates leads to a marked increase in signal intensity. This is due to both the increase in proton density and a decrease in magnetic susceptibility effects. This study demonstrated that the MRI findings correlate with the pathologic

findings and that parenchymal opacification on MRI usually indicates an inflammatory process, and therefore potentially treatable disease (Primack et al. 1994).

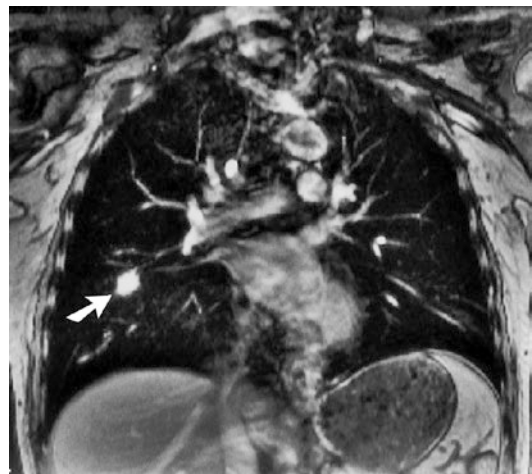
One of the earlier studies that focused on contrast-enhanced pulmonary MRI was published by Haraldseth et al. (1999). They reviewed different forms of contrast agent enhancement: MR perfusion imaging, contrast-enhanced MR angiography, and MR ventilation imaging. In the clinical context of pneumonia, they included 13 patients. The MR perfusion was obtained with a standard low flip-angle gradient-echo sequence with an inversion prepulse. The time-intensity curves after intravenous application of a gadolinium-based nonspecific contrast agent showed that in pneumonic tissue there was a steep increase without first passage peak; the dynamics of the contrast agent passage was different from normal lung tissue. The authors did not suggest replacement of chest X-rays for routine pneumonia diagnosis, but in cases where the differential diagnosis between pulmonary embolism and pneumonia were two main options, patients might benefit from an MR perfusion examination (Haraldseth et al. 1999).

A more detailed description of MRI of the pulmonary parenchyma was published by Kauczor and Kreitner (1999). As a brief summary of the technical considerations, the authors noticed the following three factors hampering the application of MRI to the lung and suggested the following strategies to resolve the problems:

1. *Low proton density*: This is valid for the normal lung parenchyma and especially for lung diseases with loss of tissue such as emphysema. In all other lung diseases, the amount of tissue, fluid, and/or cells is increased. The recommended investigation techniques are:
  - (a) T1-weighted spin-echo sequences with short echo times (<7 ms)
  - (b) T1-weighted gradient-echo sequences, such as fast low-angle shot (FLASH), with short echo times (3 ms)
  - (c) Higher number of acquisitions
  - (d) Administration of contrast agents
2. *Signal loss due to physiological motion*:

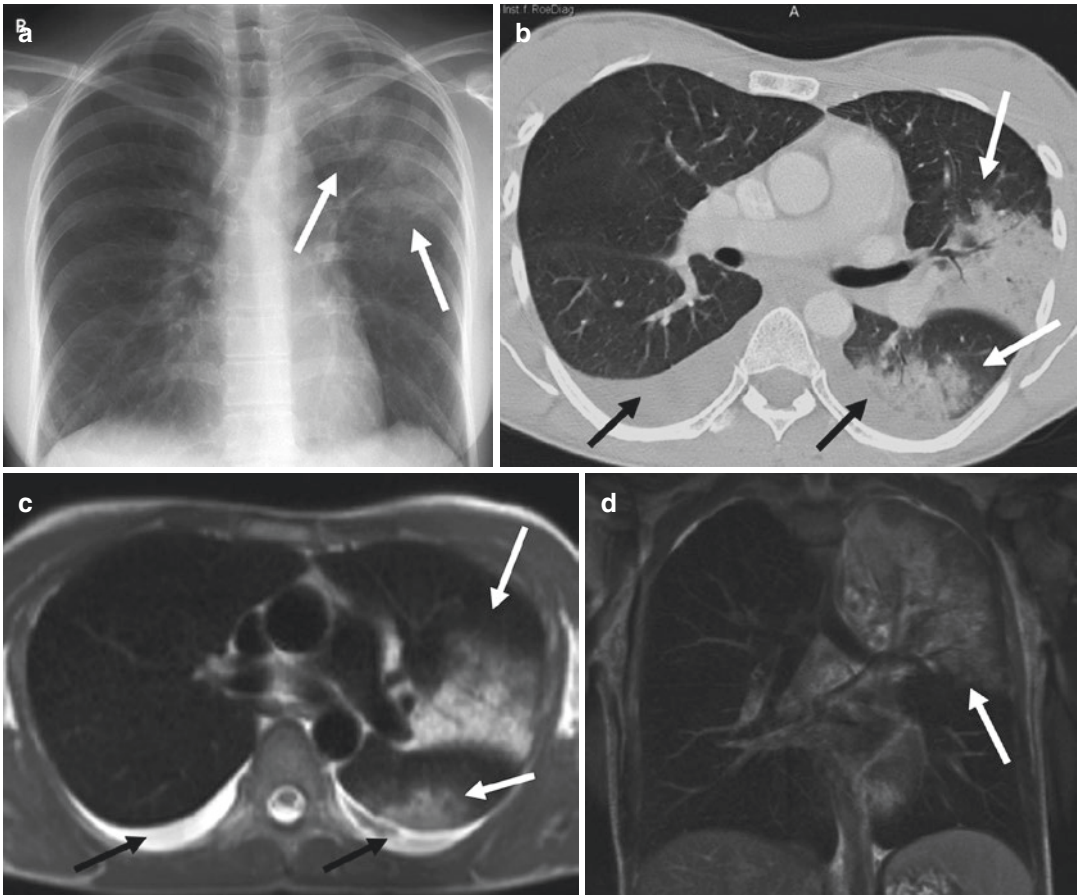
- (a) Breath-hold imaging with fast sequences like FLASH or half-Fourier acquisition single-shot turbo spin echo (HASTE)
  - (b) Respiratory gating with navigating techniques, gating in expiration using a belt, and respiratory compensation using reordering of phase encoding
  - (c) ECG triggering
3. *Susceptibility artifacts because of the multiple air-tissue interfaces*: As mentioned previously, these artifacts degrade imaging of normal lung tissue. After loss of air and concomitant increase of tissue, cells or fluid significantly reduces the number of air-tissue interfaces and the degree of susceptibility artifacts.
    - (a) Use of short echo times for T1-weighted spin-echo or gradient-echo sequences
    - (b) Use of T2-weighted turbo-spin-echo (TSE) sequences or T2-weighted ultrafast TSE-sequences with high turbo factors

With regard to infiltrations, the authors concluded that MRI can be used for the detection and characterization of inflammatory pulmonary round infiltrates in immunocompromised patients. Postcontrast T1-weighted FLASH showed a strongly enhancing, ill-defined round infiltration (Fig. 3), and with HASTE sequence moderate signal intensity was



**Fig. 3** A 45-year-old male patient with invasive aspergillosis. Postcontrast T1-weighted FLASH (TR >200 ms, TE = 4 ms, FA = 80°) shows a strongly enhancing, ill-defined round infiltration (arrow) (With permission of Springer: Kauczor and Kreitner 1999)





**Fig. 4** A 29-year-old female with bilobar pneumonia of the left lung (*white arrows*) and bilateral pleural effusions (*black arrows*). A pathogen could not be identified. (a) X-ray of the chest, (b) helical CT (slice thickness 3 mm),

and corresponding MRI (HASTE, TE 48 ms, slice thickness 6 mm) in (c) axial, and (d) coronal direction (With permission of Springer: Kauczor and Kreitner 1999)

found in a patient with bronchopneumonia (Fig. 4a–d) (Kauczor and Kreitner 1999).

Gaeta et al. (2000) revisited the value of gadolinium-enhanced MRI in the evaluation of chronic infiltrative lung disease. They found out that the presence of enhancing lesions on gadolinium-enhanced T1-weighted MRI studies may be a reliable indicator of inflammation and, consequently, indicates potentially treatable disease. Their study was performed on a 1.5-T scanner obtaining a spoiled gradient-echo T1-weighted sequence during full inspiration (TR 168 ms, TE 4.8 ms, FA 75°, slice thickness 5 mm) (Gaeta et al. 2000).

Another topic in literature is the differentiation between benign and malignant nodular lesions of the lung. Growth factors and calcification pattern

are only two of the noninvasive diagnostic criteria to separate benign from suspicious lesions and avoid unnecessary invasive tests. To overcome the limitation of morphological features, Li et al. (2000) included 62 patients to be evaluated for suspicious lung nodules with CT and dynamic Gd-DTPA-enhanced MRI. Axial T1-weighted images (TR 500 ms, TE 10 ms) with a slice thickness of 5 mm at 0, 15, 45, 75, 110, and 140 s, and 3, 5, 8, and 10 min were obtained. Additional T2-weighted images (TR 3000 ms, TE 80 ms) were acquired before contrast application. After correlation with pathological findings, they found that nodular fibrosis, inflammatory granulomas, cryptococcoma, and inflammatory pseudotumor had a more or less low rate of contrast uptake.

On the other hand, focal organizing pneumonia and sclerosing hemangioma had a significant and early enhancement. Taking into account that malignant nodules are characterized by a fast increase in signal intensity during the first pass of the contrast agent (Gückel et al. 1996), malignancy of some nodular lesions could be excluded by dynamic MRI (Li et al. 2000).

Rupprecht et al. (2002) performed a study without contrast agent and investigated a steady-state free precession sequence (true FISP) as a potential alternative to the conventional X-ray in pediatric patients with suspected pneumonia. A true FISP sequence was chosen because of its high spatial resolution and signal-to-noise ratio (S/N) in fluid- and thus T2-dominated infectious pulmonary disease. To overcome breathing artifacts in this particular patient group and to increase the S/N ratio, they obtained slice thicknesses of 30–55 mm at a 0.2-T low-field MR system. The true FISP sequence had the following parameters: TR 6 ms, TE 3 ms, FA 90°. The acquisition time for a triple slice scan was 4.8 s, and the door-to-door time was between 10 and 15 min. All pathological findings in the conventional chest X-ray could be identified in the corresponding MR investigation, and the MRI was superior in demonstrating pleural and pericardial effusions. Two small retrocardial pneumonic infiltrates were noted in the MRI only. The authors concluded that this technique could represent an alternative to the conventional chest X-ray (Rupprecht et al. 2002). Such an alternative might be of special interest in children with Nijmegen-Breakage syndrome. This entity is an autosomal recessive chromosomal instability syndrome, characterized by microcephaly, growth retardation, skin abnormalities, immunodeficiency, radiation sensitivity, and a strong predisposition to lymphoid malignancy. Because of their sensitivity to ionizing radiation, X-ray and CT examination should be avoided (Alibek et al. 2007).

Whether it is possible not only to detect but also to quantify pulmonary lesions due to pneumococcal pneumonia was investigated in a murine model by Marzola et al. (2005). Infection was induced in a group of mice ( $N = 5$ ) by intranasal administration of a sus-

pension containing *Streptococcus pneumoniae*, and a group of noninfected animals ( $N = 5$ ) was used as a control group. Axial, ECG-gated, spoiled GRE images with 1.2-mm slice thickness were acquired with a 4.7-T scanner. After sacrifice and histological evaluation, a good concordance with regard to the anatomical localization and a good correlation between the volume of the pneumoniae by histology and MRI was found (Marzola et al. 2005).

Another interesting experimental study was published by Tournebize et al. (2006). The aim of this work was to prove if MRI is able to provide spatiotemporal visualization of edema and inflammation caused by *Klebsiella pneumoniae*-induced pneumonia in mice. The study was performed with a 7-T scanner. After inoculation with avirulent and virulent strains of *Klebsiella*, treatment by bactericidal doses of antibiotics was initiated. Images were acquired up to 8 days post infection. The virulent strain caused an intense inflammation within 2 days in the whole lungs, while an avirulent strain did not show significant changes. The increase in cell density accompanied with extravascular leakage results in an increase in high water content detectable by MRI. After treatment with antibiotics, the inflammation disappeared after a week. The lesions observed by MRI correlated with the damage seen by histological analysis. In summary, MRI allows observing the appearance and regression of inflammation (Tournebize et al. 2006).

The next important topic was the investigation of the sensitivity of MRI in detecting alveolar infiltrates. To provide reliable data, Biederer et al. (2002) performed an experimental study using porcine lung explants and a dedicated chest phantom to evaluate the signal intensity of artificial alveolar infiltrates with T1- and T2-weighted MRI sequences. Ten porcine lung explants were examined with MRI at 1.5 T before and after intratracheal instillation of either 100 or 200 ml gelatine-stabilized liquid to simulate alveolar infiltrates. Control studies were acquired with helical CT.

After administration of the gelatine-stabilized liquid, the CT images demonstrated patchy areas of ground-glass opacities in both lungs. The 2D and 3D T1-weighted sequences could not

sufficiently visualize the infiltrates. In contrast, the T2-weighted sequences showed clearly visible infiltrates with an increase in signal intensity of approximately 30% at 100 ml ( $p < 0.01$ ) and 60% at 200 ml ( $p < 0.01$ ). For practical reasons, T2-weighted sequences can be highly recommended for the delineation of infiltrates in the lung. T1-weighted sequences without intravenous application of contrast agents are not sufficient for this task. Because of the extremely different acquisition times between HASTE and the T2-TSE, the HASTE sequence has to be preferred.

Based on these technical developments, it is necessary to evaluate the potential of MRI in detecting pneumonia in the immunocompromised patient. Especially in this particular group of patients, pneumonia is an important cause of morbidity and mortality. The imaging of infiltrates is very challenging, because the immunosuppression decreases the response of the lung to infectious agents. On the other hand, the patterns of pneumonia are highly variable and depend on multiple factors, like underlying diseases, time course, and treatment. By now, a considerable proportion of pulmonary fungal infections are not diagnosed antemortem in cancer patients. In addition, especially patients after bone marrow transplantation are often younger, and repetitive CT examinations carry an additional radiation burden.

Leutner et al. (2000) tried to find out how MRI compares with CT regarding the depiction of typical features of pneumonia and the detectability of lesions. MRI studies were performed with a 1.5-T system, and the imaging protocol consisted of a transversal T2-weighted ultrashort turbo spin-echo sequence (TR 2000–4000 ms, TE 90 ms, slice thickness 6 mm, and six numbers of excitation). In comparison to helical CT (slice thickness 8 mm), they evaluated presence, number, and location of pulmonary infiltrates (nodular, reticular, cysts, cavitation, consolidation, and ground-glass infiltration). In summary, most of the CT and MR examinations (75%) were rated as showing identical results concerning not only the number but also the morphology of different lesions that were due to opportunistic pneumonia. In addition, MRI was able to differentiate between consolidation and ground-glass infiltration (Leutner et al. 2000).

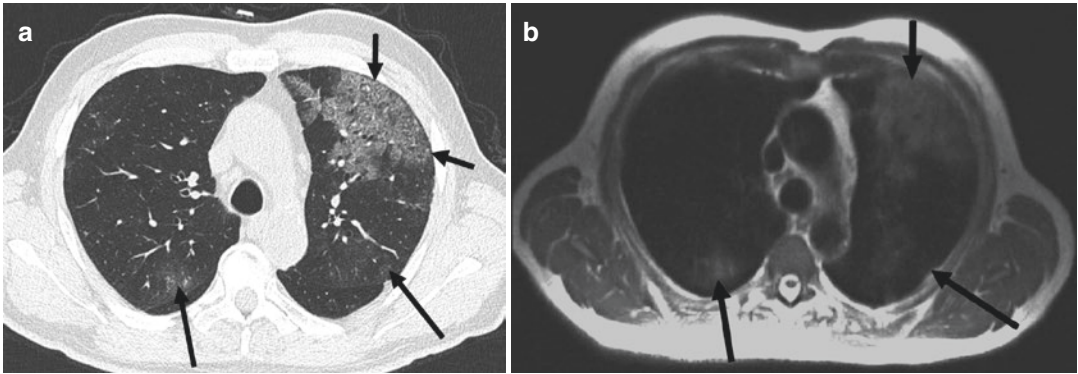
## 5 MRI: Comparison with CT

The advent of multidetector CT and the implementation of parallel imaging in MRI pushed the limits towards new possibilities with regard to examination volume, time, and slice thickness. Multidetector CT offers the opportunity to investigate the entire lung with 1-mm slice thickness or less in a couple of seconds. Parallel imaging in MRI reduced the examination time dramatically and made MRI of the lungs in a few seconds a reality.

Multidetector CT with thin sections is the gold standard for the evaluation of the lung even for very subtle lesions like small ground-glass opacities around lung nodules. That means, to classify the value of MRI of the lung, studies are necessary that compare MRI with the best CT techniques that are available nowadays.

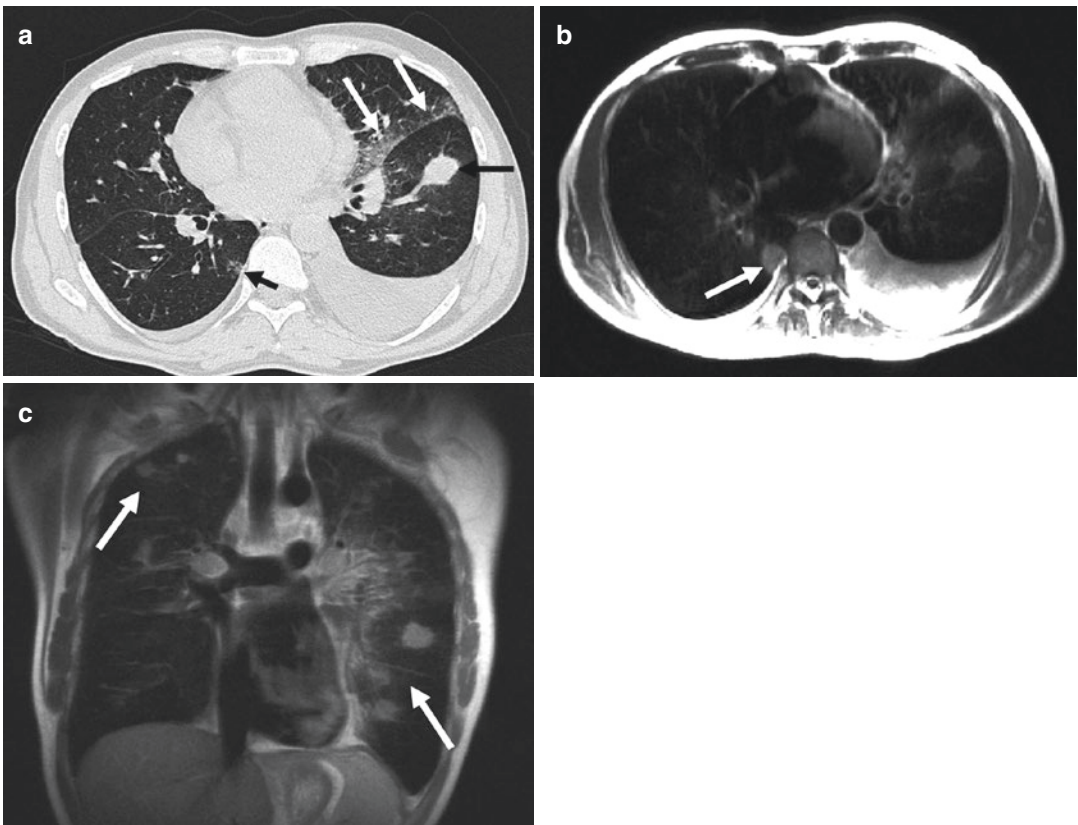
Eibel et al. (2006b) performed a study where they investigated pulmonary abnormalities in 30 immunocompromised patients with parallel MRI and thin-section helical CT. It was not the intention of this study to investigate the lung comprehensively. In order not to exceed 1-min examination time, only the HASTE sequence was selected. The resulting in-room-time was not more than 10 min. The motivation was that MRI can only serve as a real alternative to CT, when the examination time is short.

One of the inclusion criteria for this study was an X-ray of the chest that was either normal or did not show abnormalities suggestive of pulmonary infection. Ill-defined nodules, ground-glass opacity areas, and consolidations, their location and distribution, and their lesion characteristics (e.g., margin contour, cavitation, calcification) were systematically analyzed. Twenty-two patients had pulmonary abnormalities on CT. In 21 (95%) patients, pneumonia was correctly diagnosed with MRI. One false-negative finding occurred in a patient with ill-defined nodules smaller than 1 cm at CT. One false-positive finding with MR was the result of blurring and respiratory artifacts. That results in a sensitivity of MRI in comparison to 1-mm CT slices of 95%, specificity of 88%, positive predictive value of 95%, and a negative predictive value of 88% (Eibel et al. 2006a). In the detection of ground-glass opacity areas (Figs. 5 and 6), consolidations (Fig. 7),



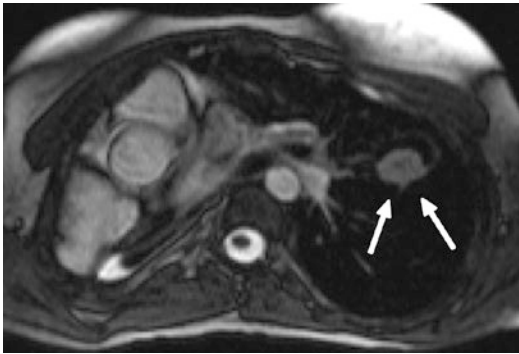**Fig. 5** A 76-year-old patient with myelodysplasia suffering from *Pneumocystis jirovecii* pneumonia (With the permission of Springer: Eibel et al. 2006a). (a) Thin-section CT above the level of the carina. Ground-glass opacity is the predominant finding in the ventral portion of the left

upper lobe (*short arrows*). Please note also the more subtle lesions in the dorsal parts of the both upper lobes (*long arrows*). (b) Axial HASTE sequence at the same level (TE 27 ms). All lesions in the upper lobes are easily detectable



**Fig. 6** A 45-year-old male with chronic lymphatic leukemia, now suffering from angioinvasive aspergillosis (With the permission of Springer: Eibel et al. 2006a). (a) Thin-section CT below the level of the carina shows a consolidation in the left lower lobe (*black arrow*), ground-glass opacity in the lingula adjacent to the fissure (*white*

*arrows*), and both-sided pleural effusions. Please note also the subtle lesion in the right lower lobe adjacent to the spine (*short arrow*). (b) Axial HASTE. (c) Coronal HASTE. The pathologic findings are again comprehensively delineated by MRI (*arrow*), even the subtle lesion in the right lower lobe adjacent to the spine (axial HASTE)



**Fig. 7** A 15-year-old girl with hyper IgE syndrome. Pneumectomy of the right lung due to recurrent complicated pneumonia (axial true FISP sequence). Preexisting thin-walled cavitary lesion in the left upper lobe with a new ovoid nodule in the dependent portion demonstrating the “air-crescent sign” in aspergilloma (arrows). The development of an “air-crescent sign” in a pulmonary nodule may also be interpreted as a sign of recovery when found in angioinvasive aspergillosis

and pleural effusion, MRI seems to be equal to thin-section CT. But the overall detection rate of nodules with MRI was only 72% (186/259). Detailed analyses found out that all nodules larger than 10 mm were reliably detected. The mean size of nodular lesions not found with MRI was 4 mm. This difference likely relates to the section thickness used with CT (1 mm) and MR imaging (6 mm). After this study, the authors came to the conclusion that pulmonary imaging for the detection and quantification of infiltrates is highly reliable with modern MR scanners (Eibel et al. 2006b).

Despite these encouraging results, it is important to keep in mind that CT has to be preferred in the detection of calcification, which can indicate some special disease entities and can be a sign of pulmonary scarring.

## 6 Morphology of Different Types of Pneumonia in MR Imaging

Before summarizing briefly the different MR features of pneumonia, already mentioned in the paragraphs before, the following statements are valid for MR imaging of pneumonia:

- Nodules larger than 1 cm in diameter, consolidations, and ground-glass opacifications are

**Table 3** MRI findings and corresponding likely causative organisms

MRI findings	Likely causative organisms
Lobar consolidation = lobar pneumonia	<i>Streptococcus pneumoniae</i> , <i>Klebsiella pneumoniae</i> , <i>Legionella pneumophila</i> , <i>Mycoplasma pneumoniae</i>
Patchy, sometimes bilateral interlobular consolidation = bronchopneumonia	Streptococci, gram-negative bacilli, <i>Legionella</i> , anaerobes, virus
Ground-glass opacification and reticular pattern = interstitial pneumonia	Virus, <i>Mycoplasma pneumoniae</i> , <i>Pneumocystis jiroveci</i> (Fig. 5)
Cavitation	<i>Staphylococcus aureus</i> , <i>Mycobacterium tuberculosis</i> , gram-negative bacilli, anaerobic bacteria
Round consolidation, halo, air-crescent sign, reverse target sign	<i>Aspergillus fumigatus</i> (Fig. 7)

detectable on MR images with a nearly identical sensitivity and accuracy with regard to lesion size and contour compared to CT. Obviously the definition of nodule, consolidation, and ground-glass according to the Fleischner Society seems to be valid even for MRI (Hansell et al. 2008).

- With MR images, it might be more challenging to delineate small nodules (<10 mm) and especially small areas of air or calcifications within lung nodules or consolidations in comparison to multidetector CT.

In Table 3, the most common and important features of pneumonia on MR images, derived from the findings on CT examinations, and the likely causative organisms are summarized. Of course, host conditions must be taken into account too.

Fungal pneumonia is an important topic, necessary to go a little bit more into detail, especially when dealing with MR imaging. Some organisms like *Histoplasma capsulatum* and *Coccidioides immitis* are primary pathogens, but are found only in specific geographic areas. On the other hand, organisms like *Aspergillus* and *Candida* species are opportunistic agents that affect

patients that already suffer from an underlying pulmonary disease or are immunocompromised. As invasive organisms, the latter can cause severe tissue destruction and can influence the clinical outcome dramatically.

The pathogenesis of *Aspergillus* infection is complex, but worthy to know is the fact that this fungus causes necrosis in lung parenchyma due to extensive vascular permeation and occlusion of small to medium arteries. This permeation and especially the separation of necrotic lung from viable parenchyma in the recovery phase of the patient can cause life-threatening intraalveolar hemorrhage.

Because of the different therapeutic approaches in patients with fungal pneumonia and because of the high morbidity and mortality in immunosuppressed patients with invasive aspergillosis, it is necessary to know the signs of this type of infection in imaging studies:

- Single or multiple nodular infiltrates
- Nodule with halo phenomenon
- Homogeneous consolidation in segmental or subsegmental spread
- Cavitation (air-crescent sign, Fig. 7)
- Reverse target sign

The ground-glass attenuation surrounding some of the nodules is termed as halo. Histopathologic studies delineated that the cause for this finding is hemorrhage around the nodule. With MR, the halo sign is clearly detectable and thus can help to differentiate the causative agents. Air crescent is a finding more commonly detectable in the recovery phase and relates to resorption of necrotic tissue in the periphery of the lesion or to retraction of the sequestrum from viable lung parenchyma (Kim et al. 2001). This crescent like air collection is associated with a higher risk of massive hemoptysis.

Blum et al. (1994) observed another characteristic feature of necrotizing pneumonia. On T2-weighted images, higher signal intensity in the center combined with comparatively lower signal intensity in the rim outlined a characteristic feature that they called “reverse target sign.” While the halo phenomenon is strongly suggestive of invasive aspergillosis in its early course, the reverse target sign is detectable in later stages.

Probably because of the excellent soft-tissue contrast on MR imaging, Leutner et al. (2000) found that MRI is superior to contrast-enhanced CT in diagnosing necrotizing pneumonia.

Barreto et al. summarized the correlation between common CT and MRI findings of parenchymal lung disease in patients suffering from pneumonia (Barreto et al. 2013).

Up to now, no comprehensive study compared the sensitivity and specificity of different imaging modalities for the diagnosis of invasive aspergillosis. Blum et al. (1994) found out that MRI may be of diagnostic value in later stages of the disease and for the follow-up of nodular infiltrates on unknown etiology in immunocompromised patients. So, further studies are necessary to lower the high mortality of angioinvasive aspergillosis by making the diagnosis earlier and with a higher reliability.

---

## 7 Protocol

In this paragraph, a short protocol recommendation (Table 4) is listed, confirmed, and illustrated by an upper lobe pneumonia (Fig. 8).

The T2-weighted HASTE sequence is the workhorse, necessary for detection and characterization of infectious lesions of the lung. Performing only the topogram and the axial HASTE in patients that are severely ill and breathless, the investigation time is below 2 min. The T1-weighted FLASH sequence with and without intravenous application of gadolinium is helpful for further characterization of infiltrates. This extends the investigation time to 15 min. The STIR and true FISP sequences can give additional information selected cases, but they are not required in routine settings.

---

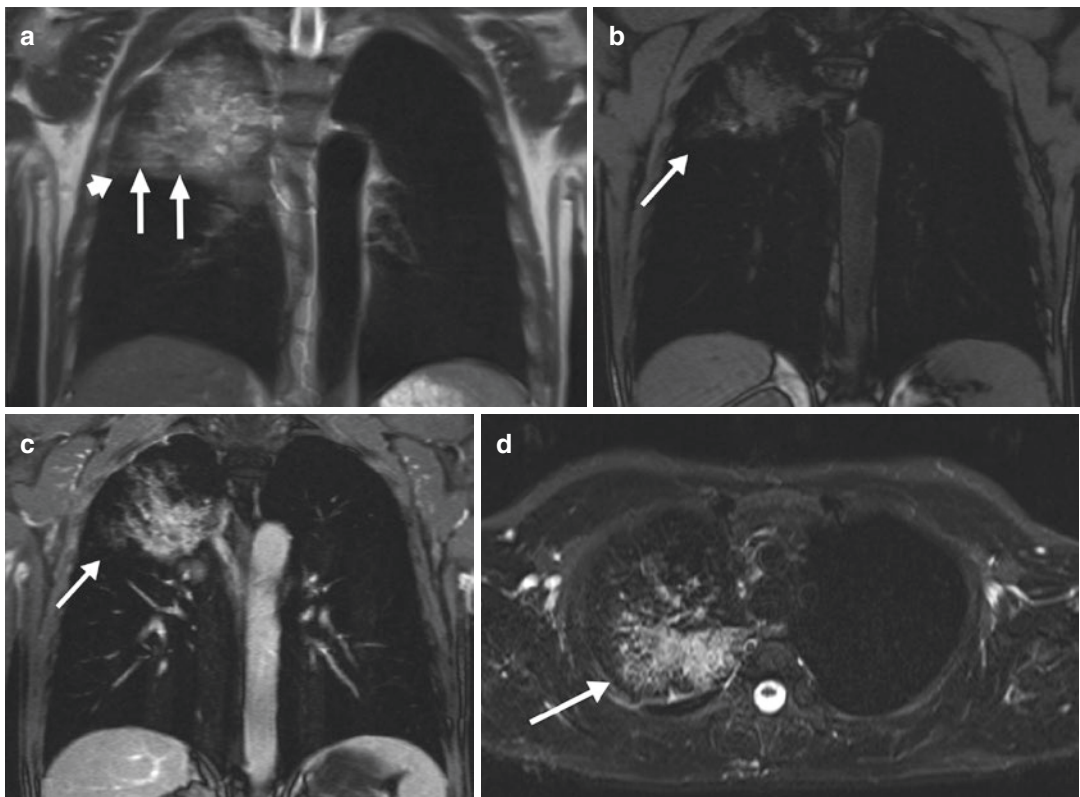
## 8 Further Developments

This chapter deals with some remarkable results of recent research and promising new applications and sequences of MRI in pulmonary infection imaging. Despite the benefits of CT in delineating abnormalities in the pulmonary parenchyma, the power in differentiating benign

**Table 4** Suggested investigation protocol at a 1.5 T MR scanner

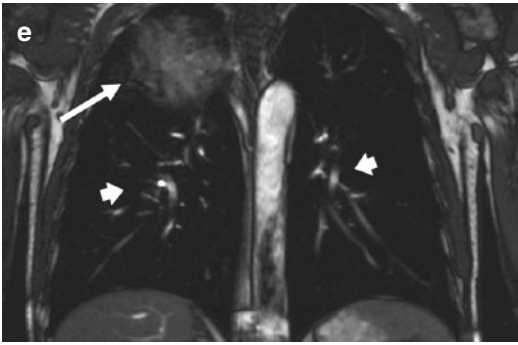
Sequence	Acronyms	Weighting	Slice orientation	TR (ms)	TE (ms)	Flip angle	FS	Slice thickness (mm)	Gd IV
Topogram									
Ultra-fast SE	UFSE, HASTE, SS-FSE	T2	Axial	1000	84	180		6	
		T2	Coronal	1000	84	180		6	
		T2	Sagittal	1000	84	180		6	
Spoiled GE	T1-FFE, FLASH, SPGR	T1	Axial	118	2	70		6	
		T1	Coronal	78	2	70	+	6	
STIR	STIR	T2	Axial	3980	100	150	+	6	
Balanced GE	Balanced FFE, true FISP, FIESTA	T2	Axial	3	1	60		6	
		T2	Coronal	3	1	60		6	
Spoiled GE	T1-FFE, FLASH, SPGR	T1	Axial	118	2	70	+	6	+
		T1	Coronal	78	2	70	+	6	+

*Abbreviations:* FFE fast field echo, FIESTA fast imaging employing steady-state acquisition, FLASH fast low-angle shot, FS fat saturation, Gd IV gadolinium intravenously, GE gradient echo, HASTE half-Fourier acquisition single-shot turbo spin echo, IR inversion recovery, SE spin echo, SPGR spoiled gradient recalled echo, SS-FSE single-shot fast spin echo, STIR short TI inversion recovery, TE time to echo, TR repetition time, true FISP true fast imaging with steady-state precession, UFSE ultra-fast spin echo



**Fig. 8** A 51-year-old male with right upper lobe pneumonia (*Streptococcus*). (a) Coronal HASTE. The horizontal fissure (short arrow) is not exceeded by the pneumonia (arrows). (b) Coronal FLASH with spectral fat saturation, before intravenous contrast administration. (c) Coronal FLASH, after delivery of 14 ml gadolinium IV (0.1 mmol/kg). (d) Axial STIR. The edema is clearly detectable in the right

upper lobe pneumonia (arrow), but the degree of artifacts and noise is higher in comparison to the HASTE sequence. (e) Coronal true FISP. The vessels are clearly detectable (short arrows). So this sequence can be an alternative to the contrast-enhanced FLASH to delineated adjacent vasculature. The pneumonia itself is not better appreciable in comparison to the HASTE and contrast-enhanced FLASH



**Fig. 8** (continued)

from malignant lesions is limited. This is especially true for the differentiation of pneumonia-like mucinous adenocarcinoma and infectious pneumonia. This type of carcinoma has a rising incidence and carries a poor prognosis. Because of the similarities to pneumonia at radiography and CT, the correct diagnosis is often performed with delay. Gaeta et al. found out that water-sensitive sequences (axial HASTE and coronal RARE) can add substantial information. In this study, the correct diagnoses of mucinous adenocarcinomas and pneumonia on CT images were possible in 74% and 73% for reader 1 and 65% and 80% reader 2, whereas both readers could make the correct diagnosis in 100% of cases with the aid of these two MR sequences. The most important finding was the so-called white lung sign, which is positive due to the high intratumoral content of mucin, but is negative in pneumonia (Gaeta et al. 2011).

An important topic is the use of MRI in young patients. It is known from a study of Pearce et al. (2012) that MDCT, which can deliver a cumulative radiation dose of approximately 50 mGy, may triple the risk of development of leukemia and that doses of approximately 60 mGy may triple the risk of brain cancer in children. So a major advantage of MRI is the lack of ionizing radiation. But therefore it is necessary to make confident diagnoses on MR images. Gorkem et al. could demonstrate that with contrast-enhanced MDCT findings as the reference standard, unenhanced MRI with fast-imaging-sequences accurately depicted 94%

lung abnormalities (consolidation, cystic hydatid disease, bronchiectasis, lung masses and nodules), 100% mediastinal masses, 100% pleural effusions, and 100% chest wall masses. The two undiagnosed findings with MRI were mild bronchiectasis and small pulmonary nodule (3 mm). Taking these results into account, the authors concluded that unenhanced MRI can be the first-line cross-sectional imaging in lieu of contrast-enhanced MDCT. This seems particularly true for pediatric patients who need multiple imaging studies for monitoring diseases (Gorkem et al. 2013).

In addition, Wielpütz et al. focused on a particular disease in the pediatric and adolescent group, the cystic fibrosis (CF). Demirkazik et al. (2001) found out that MDCT is more sensitive than chest radiograph in delineating the CF-associated pulmonary alterations. In recent development, MRI is increasingly replacing MDCT as the technique for diagnosing complications or monitoring the disease (Wielpütz et al. 2013). MRI shows the typical changes of bronchiectasis, wall thickening, mucus plugging, and infiltrates (“plus pathologies” on MRI) sensitively and with comparable clinical relevance compared to MDCT (Puderbach et al. 2007). Furthermore, MR perfusion imaging making use of hypoxic pulmonary vasoconstriction (Euler-Liljestrand reflex) shows potentially reversible perfusion and ventilation impairment. At present, MRI is being used for the first time in a German multicenter study in the framework of the neonatal cystic fibrosis screening program, providing a secondary surrogate endpoint for preventive treatment strategies (Wielpütz et al. 2014).

Despite further developments in MR imaging, CT outnumbers MRI in pulmonary imaging by far. Explanations are manifold like higher resolution, shorter scan times, availability, patient access during examination, and of course economic factors. Reducing artifacts, receiving more signal, and observing a higher degree of anatomical information will result in longer examination times which on the other hand is limited by the time the patient is able to stop breathing. Therefore, free breathing would be necessary which may lead to respiratory and blurring artifacts.



To overcome this problem, Völker et al. (2015) published a feasibility study using a versatile multishot radial TSE sequence under free breathing with modified golden-ratio-based reordering designed to prevent coherent streaking. They investigated healthy volunteers and patients with lung cancer and pneumonia, while the data were acquired during free respiration in a 90-s scan time. In conclusion, the authors found that this radial TSE sequence in combination with a modified golden-ratio-based reordering offers improved robustness towards motion. This allows for longer scan times over several respiratory cycles, thereby improving the SNR and facilitating high-quality morphological lung MRI which may help to improve the diagnosis of subtle disease. Restrictively, the performance with regard to making the diagnosis of pneumonia or lung cancer earlier, or with more confidence, was not evaluated in this study. Here further work is necessary.

## References

- Alibek S, Holter W, Staatz G (2007) The radiosensitive child: pulmonary MR tomography in EBV-induced lymphoproliferation in Nijmegen-breakage syndrome. *FortschrRöntgenstr* 179:1075–1077
- Barreto MM, Rafful PP, Rodrigues RS, Zanetti G, Hochegger B, Souza AS, Guimaraes MD, Marchiori E (2013) Correlation between computed tomographic and magnetic resonance imaging findings of parenchymal lung diseases. *Eur J Radiol* 82:492–501
- Biederer J, Busse I, Grimm J, Reuter M, Muhle C, Freitag S, Heller M (2002) Sensitivity of MRI in detecting alveolar infiltrates: experimental studies. *FortschrRöntgenstr* 174:1033–1039
- Blum U, Windfuhr M, Buitrago-Tellez C, Sigmund G, Herbst EW, Langer M (1994) Invasive pulmonary aspergillosis. MRI, CT, and plain radiographic findings and their contribution for early diagnosis. *Chest* 106:1156–1161
- Bonilla FA, Stiehm ER, Feldweg AM (2014) Secondary immunodeficiency due to underlying disease states, environmental exposures, and miscellaneous causes. In: *UpToDate Wolters Kluwer, Alphen aan den Rijn, NL*
- Campbell GD, Niederman MS, Broughton WA et al (1996) Hospital-acquired pneumonia in adults: diagnosis, assessment of severity, initial antimicrobial therapy, and preventative strategies: a consensus statement. *Am J Respir Crit Care Med* 153:1711–1725
- Cook DJ, Walter SD, Cook RJ et al (1998) Incidence of and risk factors for ventilator-associated pneumonia in critically ill patients: results from a multicenter prospective study on 996 patients. *Ann Intern Med* 129:433–440
- Craven DE, Steger KA (1995) Epidemiology of nosocomial pneumonia. New perspectives on an old disease. *Chest* 108:1S–16S
- Demirkazik FB, Ariyürek OM, Özçelik U, Göçmen A, Hassanabad HK, Kiper N (2001) High resolution CT in children with cystic fibrosis: correlation with pulmonary functions and radiographic scores. *Eur J Radiol* 37(1):54–59
- Eibel R, Herzog P, Dietrich O, Rieger C, Ostermann H, Reiser M, Schoenberg S (2006a) Magnetic resonance imaging in the evaluation of pneumonia. *Radiologe* 46:267–270. , 272–274
- Eibel R, Herzog P, Dietrich O, Rieger CT, Ostermann H, Reiser MF, Schoenberg SO (2006b) Pulmonary abnormalities in immunocompromised patients: comparative detection with parallel acquisition MR imaging and thin-section helical CT. *Radiology* 241:880–891
- Fagon JY, Chastre J, Hance AJ, Domart Y, Trouillet JL, Gibert C (1993) Evaluation of clinical judgment in the identification and treatment of nosocomial pneumonia in ventilated patients. *Chest* 103:547–553
- Gaeta M, Blandino A, Scribano E, Minutoli F, Barone M, Andò F, Pandolfo I (2000) Chronic infiltrative lung diseases: value of gadolinium-enhanced MRI in the evaluation of disease activity—early report. *Chest* 117:1173–1178
- Gaeta M, Ascenti G, Mazziotti S, Contiguglia R, Barone M, Mileto A (2011) MRI differentiation of pneumonia-like mucinous adenocarcinoma and infectious pneumonia. *Eur J Radiol* 81(11):3587–3591
- Gorkem SB, Coskun A, Yikilmaz A, Zurakowski D, Mulkern RV, Lee EY (2013) Evaluation of pediatric thoracic disorders: comparison of unenhanced fast-imaging-sequence 1.5-T MRI and contrast-enhanced MDCT. *Am J Roentgenol* 200(6):1352–1357
- Gükel C, Schnabel K, Deimling M, Steinbrich W (1996) Solitary pulmonary nodules: MR evaluation of enhancement patterns with contrast-enhanced dynamic snapshot gradient-echo imaging. *Radiology* 200:681–686
- Hansell DM, Bankier AA, MacMahon H, McLeod TC, Müller NL, Remy J (2008) Fleischner Society: glossary of terms for thoracic imaging. *Radiology* 246:697–722
- Haraldseth O, Amundsen T, Rinck PA (1999) Contrast-enhanced pulmonary MR imaging. *MAGMA* 8:146–153
- Husain AN, Kumar V (2005) The lung. In: Kumar V, Abbas AK, Fausto N (eds) *Robbins and Cotran pathologic basis of disease*, 7th edn. Elsevier Saunders, Philadelphia, USA. pp 711–772, table 15–9
- Kauczor HU, Kreitner KF (1999) MRI of the pulmonary parenchyma. *Eur Radiol* 9:1755–1764
- Kim MJ, Lee KS, Kim J, Jung KJ, Lee HG, Kim TS (2001) Crescent sign in invasive pulmonary

- aspergillosis: frequency and related CT and clinical factors. *J Comput Assist Tomogr* 25:305–310
- Leutner CC, Gieseke J, Lutterbey G, Kuhl CK, Glasmacher A, Wardelmann E, Theisen A, Schild HH (2000) MR imaging of pneumonia in immunocompromised patients: comparison with helical CT. *AJR Am J Roentgenol* 175:391–397
- Li F, Sone S, Maruyama Y, Takashima S, Yang ZG, Hasegawa M, Honda T, Yamada T, Kubo K (2000) Correlation between high-resolution computed tomographic, magnetic resonance and pathological findings in cases with non-cancerous but suspicious lung nodules. *Eur Radiol* 10:1782–1791
- Marquardt T, Jablonowski H (2003) Opportunistic diseases. Risk can be estimated. *MMW Fortschr Med* 145:33–37
- Marzola P, Lanzoni A, Nicolato E, Di Modugno V, Cristofori P, Osculati F, Sbarbati A (2005) (1)H MRI of pneumococcal pneumonia in a murine model. *J Magn Reson Imaging* 22:170–174
- McEachern R, Campbell GD Jr (1998) Hospital-acquired pneumonia: epidemiology, etiology, and treatment. *Infect Dis Clin North Am* 12:761–779
- Moore EH, Webb WR, Muller N, Sollitto R (1986) MRI of pulmonary airspace disease: experimental model and preliminary clinical results. *AJR Am J Roentgenol* 146:1123–1128
- Müller NL, Mayo JR, Zwirerich CV (1992) Value of MR imaging in the evaluation of chronic infiltrative lung diseases: comparison with CT. *AJR Am J Roentgenol* 158:1205–1209
- Niederman MS, Mandell LA, Anzueto A et al (2001) Guidelines for the management of adults with community-acquired lower respiratory tract infections: diagnosis, assessment of severity, antimicrobial therapy and prevention. *Am J Respir Crit Care Med* 163:1730–1754
- Pearce MS, Salotti JA, Little MP, McHugh K, Lee C, Kim KP, Howe NL, Ronckers CM, Rajaraman P, Sir Craft AW, Parker L, Berrington de González A (2012) Radiation exposure from CT scans in childhood and subsequent risk of leukaemia and brain tumours: a retrospective cohort study. *Lancet* 380(9840):499–505
- Primack SL, Mayo JR, Hartman TE, Miller RR, Müller NL (1994) MRI of infiltrative lung disease: comparison with pathologic findings. *J Comput Assist Tomogr* 18:233–238
- Prod'hom G, Leuenberger P, Koefler J et al. (1994) Nosocomial pneumonia in mechanically ventilated patients receiving antacid, ranitidine, or sucralfate as prophylaxis for stress ulcer: a randomized controlled trial. *Ann Intern Med* 120:653–662
- Puderbach M, Eichinger M, Haeselbarth J, Ley S, Kopp-Schneider A, Tuengerthal S, Schmaehl A, Fink C, Plathow C, Wiebel M, Demirakca S, Müller FM, Kauczor HU (2007) Assessment of morphological MRI for pulmonary changes in cystic fibrosis (CF) patients: comparison to thin-section CT and chest x-ray. *Invest Radiol* 42(10):715–725
- Rello J, Paiva JA, Baraibar J et al (2001) International conference for the development of consensus on the diagnosis and treatment of ventilator-associated pneumonia. *Chest* 120:955–970
- Rosenow EC III (1990) Diffuse pulmonary infiltrates in the immunocompromised host. *Clin Chest Med* 11:55–64
- Rupprecht T, Böwing B, Kuth R, Deimling M, Rascher W, Wagner M (2002) Steady-state free precession projection MRI as a potential alternative to the conventional chest X-ray in pediatric patients with suspected pneumonia. *Eur Radiol* 12:2752–2756
- Springhouse (2007) Professional guide to disease. An up-to-date encyclopedia of illnesses, disorders, and injuries and their treatments. Lippincott Williams and Wilkins, Philadelphia, USA
- Tournebise R, Doan BT, Dillies MA, Maurin S, Beloeil JC, Sansonetti PJ (2006) Magnetic resonance imaging of *Klebsiella pneumoniae*-induced pneumonia in mice. *Cell Microbiol* 8:33–43
- Völker M, Ehses P, Weick S, Breuer FA, Blaimer M, Hintze C, Biederer J, Jakob PM (2015) Free breathing 1H MRI of the human lung with an improved radial turbo spin-echo. *MAGMA* 28(3):227–238
- Wielpütz MO, Eichinger M, Puderbach M (2013) Magnetic resonance imaging of cystic fibrosis lung disease. *J Thorac Imaging* 28(3):151–159
- Wielpütz MO, Heußel CP, Herth FJ, Kauczor HU (2014) Radiologische Diagnostik von Lungenerkrankungen. Betrachtung der Therapieoption bei Wahl des Verfahrens. *Dtsch Arztebl Int* 111(11):181–187