

Necroptosis mediated by receptor interacting protein kinase 3 as critical players in experimental congenital hypothyroidism related neuronal damage

 Gulhan Duman,¹  Mehmet Eray Alcigir,²  Hayrettin Yavuz³

¹Department of Endocrinology and Metabolic Disorders, Sivas Cumhuriyet University Faculty of Medicine, Sivas, Turkey

²Department of Pathology, Kirikkale University Faculty of Veterinary Medicine, Kirikkale, Turkey

³Department of Biochemistry, Sivas Cumhuriyet University Faculty of Medicine, Sivas, Turkey

ABSTRACT

OBJECTIVE: Congenital hypothyroidism (CH) is literally described as congenital thyroid hormone imperfection. The primary objective of this research was to reveal the possible relation between receptor-acting protein kinase 3 (RIPK3) activity and neuronal damages in rat pups with CH. In addition, we evaluated the favorable impacts of 3,6-dibromo- α -([phenylamino] methyl)-9H-carbazole-9-ethanol (P7C3) reducing RIPK3 activity.

METHODS: Adult rats were accordingly assigned into four groups: Group 1, which is called congenital hypothyroid; Group 2, which is called congenital hypothyroid administered P7C3; Group 3, called CH administered P7C3 and L-thyroxine; and Group 4, control group. RIPK3 level in plasma concentration and its expression in tissue was determined in all groups.

RESULTS: Increased RIPK3 expressions were detected as high in the CH group when it is compared to the control group. Furthermore; the expressions in neuronal cytoplasm were found similar among Groups II and III. RIPK3 expressions in those two groups were relatively higher than in the control group. Most reacted parts of the brain were especially Purkinje cells in the cerebellum.

CONCLUSION: It is concluded that there is excellent parallelism among damaged neurons and high RIPK3 activity in CH pathogenesis. P7C3 compounds may have a safeguarding impact on CH due to decreasing RIPK3 activity.

Keywords: Congenital hypothyroidism; rat; receptor-acting protein kinase 3 activity; 3,6-Dibromo- α -([phenylamino] methyl)-9H-carbazole-9-ethanol.

Cite this article as: Duman G, Alcigir ME, Yavuz H. Necroptosis mediated by receptor interacting protein kinase 3 as critical players in experimental congenital hypothyroidism related neuronal damage. *North Clin Istanbul* 2021;8(5):472–478.

Congenital hypothyroidism (CH) is the most treatable cause of mental retardation [1]. Thyroid hormones (THs) are essential in terms of neurogenesis, myelination, neuronal migration, and synaptogenesis. Decreased thyroid hormone levels have been associated with changes that are irreversible after thyroid hormone supplementation including insufficient axon myelination, reduced interhemispheric connections, and white matter volume [2, 3]. Thus, many structural defects in gross mo-

tor experience, optical processing, optical attention, and event memory in the first trimester, as for maternal deficiency of TH [3, 4]. Efficacious treatments for CH primarily rely on several factors such as diagnosis at an early stage and determination of the optimal dose and timing of TH replacement. The lower and larger dose of levothyroxine which is known as synthetic thyroid hormone may solely bring about more inferior consequences and sign of excessive thyroid hormone itself, respectively [3, 5].

Received: March 09, 2021 *Accepted:* April 25, 2021 *Online:* October 22, 2021

Correspondence: Gulhan DUMAN, MD. Sivas Cumhuriyet Universitesi Tip Fakultesi, Endokrinoloji ve Metabolik Bozukluklar Bilim Dalı, Sivas, Turkey.

Tel: +90 346 219 10 10 e-mail: gulcavlak@hotmail.com

© Copyright 2021 by Istanbul Provincial Directorate of Health - Available online at www.northclinist.com



3,6-Dibromo- α -[(phenylamino) methyl]-9H-carbazole-9-ethanol (P7C3) is a novel neuroprotective and pro-neurogenic small molecule [6, 7]. It promotes the continuation of neurons and safeguards the hippocampus neural progenitor cells through the mechanism Nicotinamide Phosphoribosyltransferase activation and restoration of intracellular nicotinamide adenine dinucleotide (NAD⁺) levels. Recent studies have reported that neuroprotective properties of P7C3 in different rodent models of neurodegeneration, including Parkinson's disease, amyotrophic lateral sclerosis (ALS), psychological stress-related hippocampal cell death traumatic brain injury, peripheral nerve crush injury, and stroke. In the mentioned surveys, behavioral protection was affiliated with direct neuroprotective efficacy on neurons, without modulation of preceding pathological hallmarks of the disease [8].

In an animal study performed by Dogan et al. [9], protective effects of P7C3 have been reported in experimental CH in rat pups.

Receptor-interacting protein kinase 3 (RIPK3) triggers pro-inflammatory cell death termed necroptosis, which is defined as a caspase-independent, regulated, and morphologically necrosis-like death pattern [10, 11]. Increased RIPK3 levels and expressions are reported in various neurodegenerative diseases including Alzheimer's disease (AD), ALS, Multiple sclerosis (MS), and Gaucher disease (GD) [12–15]. However, little has been known as to the relationship between RIPK-3 and CH neuronal effect.

Accordingly, in the current investigation, a rat pup model of CH induced by methimazole (MMI) was utilized to examine the alteration of plasma RIPK3 concentrations and brain expressions. Finally, the effects of P7C3 supplementation on RIPK-3 tissue expressions and concentrations were also evaluated. This study might provide a high contribution to the potential role of RIPK3 for neuronal necroptosis in neonatal rats born with hypothyroidism.

MATERIALS AND METHODS

Animal Exposure

Authorization for the analysis was acknowledged by the Local Ethics Board of Cumhuriyet University (Decision no: 145/2018). Male and female rats which are known as Wistar rats were experimentally mated in the laboratory preserved at a degree of 22–24°C and 55% humidity within a 12-h light/12-h dark cycle (light between

Highlight key points

- RIPK3 may act as a marker in the detection of neuronal damage caused by congenital hypothyroidism.
- P7C3 molecule, which has beneficial effects in other neurodegenerative diseases, decreased brain RIPK3 levels of rats with congenital hypothyroidism.
- However, the treatment protocol in which levothyroxine was added to P7C3 resulted in further reductions in RIPK3 levels in the brain.
- Therefore, RIPK3 may serve in the diagnosis and monitoring of the treatment in congenital hypothyroidism.

6:00 am and 6:00 pm). The actualization of vaginal plugs was contemplated as gestation day 0 (GD 0). A colony of eight pregnant rats was randomly and equally categorized into 4 groups.

- **Group I (n:6):** MMI given the figures in the brackets (0.025% wt/vol) was conducted in a day in drinking water to the rats, which are pregnant ranging from day 9 of gestation to postnatal day 21 (P21) to produce pups within the CH
- **Group II (n:6):** MMI given the figures in the brackets (0.025% wt/vol) was conducted daily in drinking water to the pregnant rats ranging from day 9 of gestation to P21. Furthermore, the date mentioned from P1 to P21, the rat pups were accordingly conducted P7C3 (Tocris Bioscience, Bristol, UK, CAS no: 301353-96-8) at a dose of 10 mg/kg/day via oral gavage
- **Group III (n:6):** MMI (0.025% wt/vol) was conducted on a daily base in drinking water to the rats which are pregnant ranging from day 9 of gestation to P21. From P1 to P21, the rat pups were accordingly conducted with P7C3 at a dose of 10 mg/kg/day via oral gavage and levothyroxine (L-thyroxine) dissolved in 0.9% NaCl at a dose 7.5 μ g/day/kg was injected subcutaneously
- **Group IV (n:6):** The pregnant rats, in the end, were fed truly ad libitum and optimum tap water except for MMI ranging from GD0 to P21. The rat pups also were truly fed breast milk coming from their lactating mothers and also were captured in the identical cage as their own dams until P21.

Blood Samples

Blood samples were obtained from all of the rat pups towards pediatric lavender top tubes (Becton Dickinson, UK). Following centrifugation, at 4°C some 15 min at

3500 rpm, and resulted the plasma was aliquoted and immediately frozen at -80°C (Wisecryo, Korea). To figure the efficacy of MMI administration, free thyroxin (fT4) concentrations of the pregnant rats were revealed in the 2nd week of gestation.

Assessment of Plasma freeT4 and RIPK3 Concentrations

The style which has been known as a quantitative sandwich ELISA was utilized with the purpose of the clarification of plasma RIPK3 level. The mentioned tests were conducted accordingly with the manufacturer's advice. The kits' values calculated according to the intra-assay and inter-assay CV ones were $<10\%$ and $<12\%$, respectively. FreeT4 levels were measured using electrochemiluminescence method (Roche, Germany).

Detection of RIPK3 Expressions in Central Nervous System Tissues

The whole brain was removed at necropsy, and the morphological alterations were observed according to macroscopical criteria. The brain tissues were fixed in buffered formalin 10% and ordinary tissue follow-up was implemented. After embedding of tissues by sagittal cutting into paraffin wax, slices of 6 μm thickness of the substance were taken from the paraffin blocks. During examinations, it was utilized from localizations enumerated within the neonatal rat brain atlas (Ramachandra and Subramanian, 2011). For showing RIPK3 activity in the tissues, avidin-biotin complex peroxidase (ABC-P) was preferred. The pieces obtained from the paraffin blocks were received by xylol and ethanol series (5 min for each), and afterward deparaffinized and rehydrated. All sections were also digested for 10 min utilizing proteinase K at 45°C . In this case, all sections placed in citrate buffer-EDTA (pH:6.0) were preserved in a microwave oven at 750 W for 20 min and the antigenic determinants were disclosed. To eradicate endogenous peroxidase activity, the tissues were preserved in 3% hydrogen peroxide (H_2O_2)-methanol solution lasting for 20 min. Non-specific protein activity was hindered using blocking serum (Novocastra, Leica). Incubation with RIPK3 primary antibody (polyclonal rabbit anti RIPK3 antibody- Antibodiesonline.com, ABIN2792102, at 1/200) was performed at 45°C overnight at $+4^{\circ}\text{C}$. The rest of the procedure was performed in accordance with the ABC-P staining method (Novocastra, Leica). In the regulation, the tissue slices were also truly rinsed twice for 5 min each time,

using phosphate buffered saline (PBS) at the end of each phase, except for the protein blocking phase. In order for the control slices, PBS was preferred in reverse of the primary antibody in the negative control. As a positive control, mice brain was used for showing cross-reaction. Diaminobenzidine was used as chromogen, while Gill's hematoxylin was used as cross staining. The slices were fixated using a non-aqueous mounting medium.

All of the results were semi-quantitatively obtained by utilizing a light microscope at $\times 40$ magnification; field counting was implemented 10 times and the average value was computed (Olympus BX51). For the calculation of mean (\pm) standard deviation, the mean rates were entered in one of the columns on the Excel spreadsheet (Microsoft Excel Program).

Statistical Analysis

The regular dispersion of data was calculated with the Shapiro-Wilk test. Numerical volatilities were indicated as mean \pm SD. The analysis of variance (ANOVA) analysis and Greenhouse-Geisser modification were utilized to measure the plasma RIPK-3 concentrations within groups, and the Tukey's diversified contrasting analysis was adopted in all dual comparisons. ANOVA and Bonferroni's post-hoc tests were selected to measure histopathological rates within groups. Data analyses were executed with GraphPad Prism version 7.00 for Windows software (GraphPad Software, La Jolla California USA, www.graphpad.com).

RESULTS

Plasma RIPK-3 and FreeT4 Concentrations

Plasma FreeT4 (FT4) concentrations of pregnant rats in the 2nd week of gestation were given in Table 1. Mean plasma RIPK-3 levels were 8.2 ± 1.8 , 7.6 ± 2.8 , 5.65 ± 3.1 and 5.58 ± 1.16 pg/mL in Group1, Group 2, Group 3, and Group 4, respectively. Plasma RIPK-3 levels were found higher in Group 1 compared to the control group and Group 4. Higher RIPK-3 concentrations also found in Group 1 compared to Group 3 but the differences between groups were not statistically significant ($p=0.159$) (Fig. 1).

RIPK3 Expressions in Brain Tissue

Cerebrum

The moderate reactions were localized in the cytoplasm of migrational neurons of the brain cortex in

TABLE 1. Plasma fT4 concentrations of pregnant rats in the second week of gestation

Groups	Pregnant rats	fT4 (ng/dL)
Group 1	PR1	0.64
	PR2	0.7
Group 2	PR1	1.2
	PR2	0.8
Group 3	PR1	0.55
	PR2	0.41
Group 4 (control)	PR1	2.34
	PR2	2.13

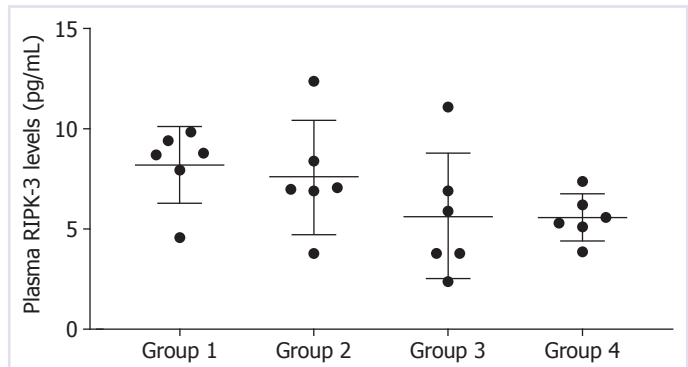
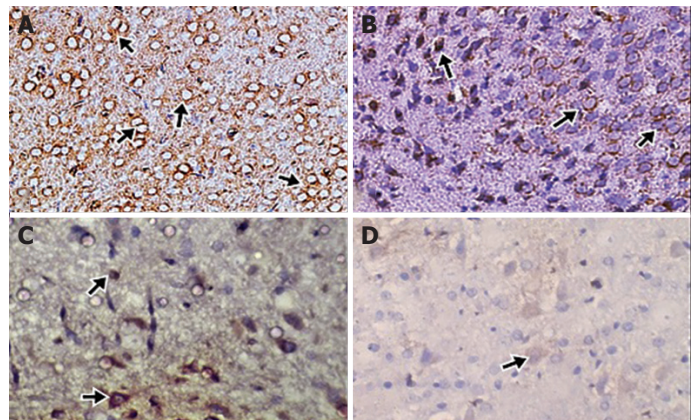
Results are expressed as mean±SD with 95% confidence intervals. PR: Pregnant rat; fT4: Free thyroxine; TSH: Thyroid stimulant hormone; SD: Standard deviation.

TABLE 2. Scoring of RIPK3 expression in fore brain, mid brain and hind brain

Experimental groups	Cerebrum	Cerebellum
	Mean±SD	Mean±SD
Group I	24.2±2.4	31.2±1.9
Group II	12.2±2.1	10.6±2.8
Group III	1.9±2.8	4.2±2.6
Group IV	0	0

RIPK3: Receptor-interacting protein kinase 3; SD: Standard deviation.

6 rat pups. However, myelin of substantia alba also gave mild reactions in 6 rat pups in Group I. In Group II, the distribution of positivity's was found higher ($p<0.01$) than that of Group III in spite of lower than Group I ($p<0.01$). The density of positivity's was less when compared to the first group in terms of regions of the brain cortex. The migrational neuron reactions were seen in 5 of rat pups in Group II and 3 of the rat pups in Group III. Myelinic reactions in substantia alba were observed mildly in 3 rat pups for each group. However, one rat pup in Group II and 3 rat pups in Group III did not give any reaction in the cerebral cortex. In addition, any reaction was also not observed in other parts of the cerebrum in these animals. In Group IV or control group, the reactions were not seen in any pups except cytoplasmic positivity in a couple of migrational neurons. The differences were found meaningful statistically when compared to other groups ($p<0.01$ for each group) (Fig. 2a–d).

**FIGURE 1.** Plasma receptor-acting protein kinase 3 concentrations.**FIGURE 2.** Receptor-acting protein kinase 3 (RIPK3) expressions in cerebrum tissue. **(A)** Strong RIPK3 positivity's in cytoplasm of migrational neurons (arrows), Group I, ×250, avidin-biotin complex peroxidase (ABC-P). **(B)** Moderate RIPK3 positivity's in cytoplasm of migrational neurons (arrows), Group II, ×250, ABC-P. **(C)** Mild RIPK3 positivity's in cytoplasm of migrational neurons (arrows), Group III, ×250, ABC-P. **(D)** A few RIPK3 positivity's in cytoplasm of migrational neurons (arrows), Group IV, ×250, ABC-P.

Cerebellum

In Group I, cytoplasm of Purkinje cells in particular, and granular cells, as well as myelin in substantia alba, gave moderate reactions in all the pups. Especially, Purkinje cells gave more reactions in those cases when compared to granular cells and myelin. In Groups II and III, other neurons and myelin gave mild reaction in 3 of rat pups in the second group and 2 of rat pups in the third group. The rest of the rat pups of Groups II and III did not give any specific reaction in either Purkinje-granular cells or myelin. The differences in terms of positivity's in those cells between Group I and Group III were found

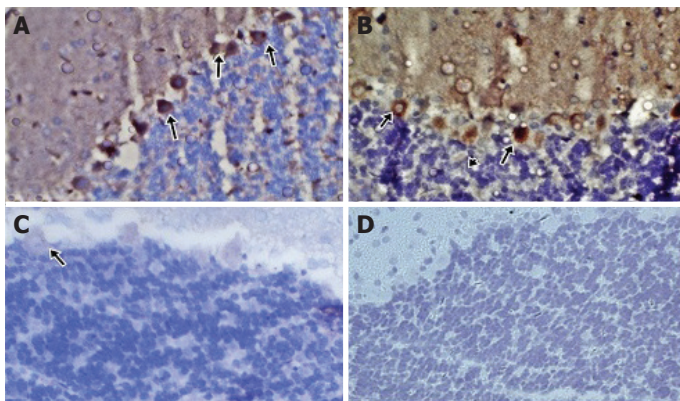


FIGURE 3. Receptor-acting protein kinase 3 (RIPK3) expressions in cerebellum tissue. **(A)** Strong RIPK3 positivity's in cytoplasm of Purkinje cells (arrows), Group I, $\times 250$, avidin-biotin complex peroxidase (ABC-P). **(B)** Moderate RIPK3 positivity's in cytoplasm of Purkinje cells (arrows), Group II, $\times 250$, ABC-P. **(C)** Mild RIPK3 positivity's in cytoplasm of Purkinje cells (arrows), Group III, $\times 250$, ABC-P. **(D)** No any positivity's in Purkinje cells, Group IV, $\times 250$, ABC-P.

meaningfully ($p < 0.01$). The same statistical differences were found between Groups I and III and also Group II and III. Finally, Group IV or control group, there was no meaningful reactions. The previous three groups were different as regards to statistical analysis ($p < 0.001$ for each group) (Fig. 3a–d).

The scores in all groups are demonstrated in Table 2 and Figure 4. The RIPK3 expression-maps were given according to the group in visual brain atlas (Fig. 5).

DISCUSSION

In the present research, we searched on the role of RIPK3-mediated necroptosis in the pathology process of CH and the neuroprotective effect of P7C3. The main findings are indicated as follows (i) increased RIPK3 expressions were found in CH group of cerebrum and cerebellum compared to control group, (ii) lower cerebral and cerebellar RIPK-3 expressions were detected in P7C3 administrated group than CH group, and (iii) decreased expressions cerebral and cerebellar RIPK-3 expressions have been found in both P7C3 and levothyroxine administrated group than only P7C3 administrated and CH group.

In the present study, we determined increased tissue RIPK-3 expressions localized in different parts of the cerebrum and cerebellum and plasma RIPK-3 levels in CH group compared to the control group. Although

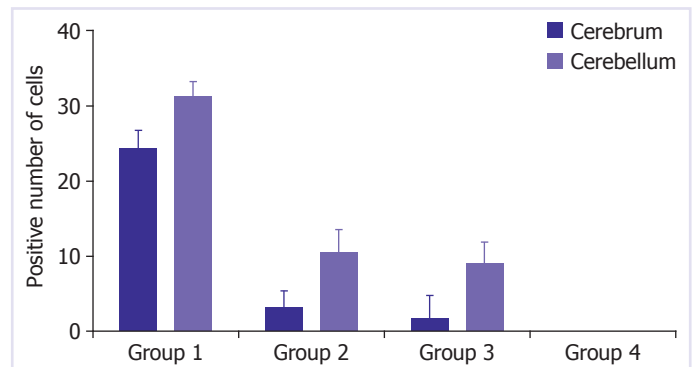


FIGURE 4. Colored points showing density of receptor-acting protein kinase 3 expressions in experimental groups and colored bar scale in mean positivity in 10-High Power Fields.

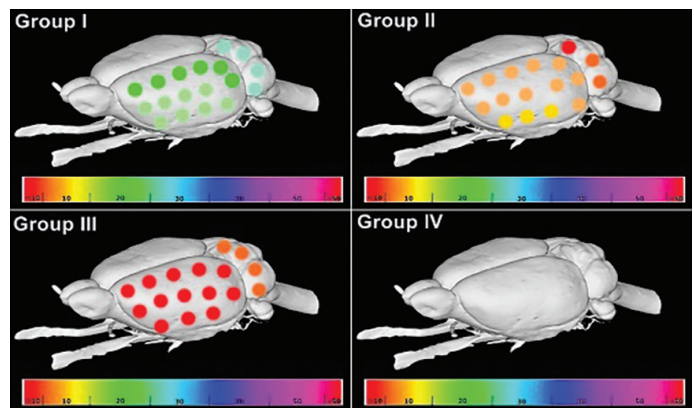


FIGURE 5. The receptor-acting protein kinase 3 expression-maps were given according to group in visual brain atlas.

previous studies have been reported the possible role of RIPK-3 in neuronal necroptosis, it's unclear to what extent RIPK-3 to CH [16, 17]. Yang et al. [16] found that RIPK3/MLKL signaling might play an important role in the modulation of microglia and macrophages in the ischemic cortex. The researchers also reported higher RIPK-3 m(RNA) expressions *in vitro* model of cerebral ischemia-reperfusion injury. Decreased RIPK-1, AD-related proteins such as Amyloid-beta and Tau levels were detected in aluminum treated primary cultures of newborn mice cortical cells after administrated neuroprotective substance [18]. Mohan et al. [19] reported that increased apoptosis due to maternal thyroid hormone deficiency in rats. Recently, it has been shown aerosolized thyroid hormone or the use of the thyroid hormone mimetic sobetirome-associated with decreased apoptosis in alveolar epithelial cells. Accordingly, we think that decreased thyroid hormone levels in the prenatal period related to the increased RIPK-3 expressions.

In this study, mild and moderate RIPK-3 reactions were detected in the cytoplasm of emigrational neurons of the brain cortex and in the myelin of substantia alba in CH group, respectively. In addition, moderate RIPK-3 reactions were determined in the cytoplasm of Purkinje cells, granular cells and myelin part of substantia alba.

TH deficiency causes wide range abnormalities in the offspring including defective in the neuronal migration, reduced myelination, growth of axons, and dendrites which are associated with motor, visual, and auditory functions [20]. Hypothyroidism also associated with other histomorphological changes within the cerebellum, involving fostered neuronal death with the internal granular layer, fostered perdurance of the external granular layer, defects within granular cell migration, impaired Purkinje cell dendritogenesis, delayed myelination, and increased cell apoptosis [21]. In two animal models of MS and in culture showed that RIPK1-RIPK3-dependent necroptosis mediates oligodendrocyte degeneration and inflammation *in vivo* [14]. In this context, as we showed in our study, such kind of neuronal defects linked to increased RIPK3 in hypothyroidical next generations may create an alteration in histoarchitecture in the central nervous system. Thus, we think that related decreased myelination and the other abnormalities in Purkinje cells due to CH may be associated with increased RIPK-3 expressions in the cerebrum and cerebellum, and also cause motoric and functional skill disabilities in next-generation suffered from hypothyroidism.

In our study, decreased cerebral and cerebellar RIPK-3 expressions have been found in P7C3 and levothyroxine (L-thyroxin) administrated and only P7C3 administrated groups. A recent study has been shown hypothyroidism as an inducer of oxidative stress [22]. In both thyroid status (hyper and hypothyroidism), increased oxidative damage has been demonstrated related with the increased lipid peroxidation (LPO) and the inhibition of enzymatic and non-enzymatic antioxidants [23, 24]. Recent results demonstrated that CH induces reactive oxygen species production, which is affiliated with LPO and GSH depletion, these results suggest that hypothyroidism causes redox imbalance and oxidative stress in the cerebral cortex of immature rats. It has been reported that increased oxidative stress in granulosa cell and oocyte necroptosis due to RIPK signaling pathways [20]. In a study RIPK3 has been associated with microvascular ischemia-reperfusion injury through increased xanthine oxidase-dependent oxidative damage. NAD⁺ and

its phosphorylated forms NADP⁺ and NADPH have an important role in reducing oxidative stress [25]. P7C3 restores cellular NAD⁺. Therefore, we speculated that restored NAD⁺ levels due to P7C3 related to the decreased expressions of RIPK-3 in CH rat pups. Decreased oxidative stress has been reported after levothyroxine treatment in patients with hypothyroidism. Masullo et al. [26] reported significantly decreased levels of malonaldehyde and increased catalase activity in female hypothyroid patients. Ates et al. [27] found decreased oxidant status and increases antioxidant status following the 6 months of levothyroxine replacement in hypothyroidism.

Therefore, we postulate that decreased expressions of RIPK-3 might have a role in the molecular mechanism of lower oxidative stress after levothyroxine replacement therapy together with neuroprotective-P7C3 although a maternal deficiency in TH may trigger increased oxidative stress in developing brain and subsequently RIPK3-intermediated neuronal alterations. However, new studies should be designed to define the molecular basis for this effect.

Conclusions

RIPK-3 is a useful marker for showing necroptosis signals in neuronal damages in maternal hypothyroidism. P7C3 has the negative effect of RIPK-3 expressions in the cerebrum and cerebellum of CH rat pups. The combination of P7C3 and L-thyroxine combination might be more beneficial in decreasing RIPK-3 related necroptosis. This study first explored the role of RIPK-3 in the experimental RIPK3 CH.

Ethics Committee Approval: The Cumhuriyet University Animal Experimentation Ethics Committee granted approval for this study (date: 05.07.2018, number: 145/2018).

Conflict of Interest: No conflict of interest was declared by the authors.

Financial Disclosure: The authors declared that this study has received no financial support.

Authorship Contributions: Concept – GD; Design – GD; Supervision – GD; Fundings – GD; Materials – MEA, HY; Data collection and/or processing – GD; Analysis and/or interpretation – MEA, HY; Literature review – GD, MEA, HY; Writing – GD; Critical review – GD.

REFERENCES

1. van Tellingen V, Finken MJ, Israëls J, Hendriks YM, Kamp GA, van Santen HM. Poorly controlled congenital hypothyroidism due to an underlying allgrove syndrome. *Horm Res Paediatr* 2016;86:420–4.
2. Powell MH, Nguyen HV, Gilbert M, Parekh M, Colon-Perez LM,

- Mareci TH, et al. Magnetic resonance imaging and volumetric analysis: novel tools to study the effects of thyroid hormone disruption on white matter development. *Neurotoxicology* 2012;33:1322–9.
3. Moog NK, Entringer S, Heim C, Wadhwa PD, Kathmann N, Buss C. Influence of maternal thyroid hormones during gestation on fetal brain development. *Neuroscience* 2017;342:68–100.
 4. Gilbert ME, Rovet J, Chen Z, Koibuchi N. Developmental thyroid hormone disruption: prevalence, environmental contaminants and neurodevelopmental consequences. *Neurotoxicology* 2012;33:842–52.
 5. Toft AD. Thyroxine therapy. *N Engl J Med* 1994;331:174–80.
 6. Pieper AA, McKnight SL, Ready JM. P7C3 and an unbiased approach to drug discovery for neurodegenerative diseases. *Chem Soc Rev* 2014;43:6716–26.
 7. Bauman MD, Schumann CM, Carlson EL, Taylor SL, Vázquez-Rosa E, Cintrón-Pérez CJ, et al. Neuroprotective efficacy of P7C3 compounds in primate hippocampus. *Transl Psychiatry* 2018;8:202.
 8. Voorhees JR, Remy MT, Cintrón-Pérez CJ, El Rassi E, Khan MZ, Dutca LM, et al. (-)-P7C3-S243 protects a rat model of Alzheimer's disease from neuropsychiatric deficits and neurodegeneration without altering amyloid deposition or reactive glia. *Biol Psychiatry* 2018;84:488–98.
 9. Dogan HO, Alçigir ME. The protective effect of P7C3 against DNA and neuron damage in rat pups with congenital hypothyroidism. *Biomed Pharmacother* 2018;99:499–503.
 10. Golstein P, Kroemer G. Cell death by necrosis: towards a molecular definition. *Trends Biochem Sci* 2007;32:37–43.
 11. Kroemer G, Galluzzi L, Vandenabeele P, Abrams J, Alnemri ES, Baehrecke EH, et al; Nomenclature Committee on Cell Death 2009. Classification of cell death: recommendations of the Nomenclature Committee on Cell Death 2009. *Cell Death Differ* 2009;16:3–11.
 12. Re DB, Le Verche V, Yu C, Amoroso MW, Politi KA, Phani S, et al. Necroptosis drives motor neuron death in models of both sporadic and familial ALS. *Neuron* 2014;81:1001–8.
 13. Vitner EB, Salomon R, Farfel-Becker T, Meshcheriakova A, Ali M, Klein AD, et al. RIPK3 as a potential therapeutic target for Gaucher's disease. *Nat Med* 2014;20:204–8.
 14. Ofengeim D, Ito Y, Najafov A, Zhang Y, Shan B, DeWitt JP, et al. Activation of necroptosis in multiple sclerosis. *Cell Rep* 2015;10:1836–49.
 15. Caccamo A, Branca C, Piras IS, Ferreira E, Huentelman MJ, Liang WS, et al. Necroptosis activation in Alzheimer's disease. *Nat Neurosci* 2017;20:1236–46.
 16. Yang J, Zhao Y, Zhang L, Fan H, Qi C, Zhang K, et al. RIPK3/MLKL-Mediated Neuronal Necroptosis Modulates the M1/M2 Polarization of Microglia/Macrophages in the Ischemic Cortex. *Cereb Cortex* 2018;28:2622–35.
 17. Yang M, Lv Y, Tian X, Lou J, An R, Zhang Q, et al. Neuroprotective effect of β -caryophyllene on cerebral ischemia-reperfusion injury via regulation of necroptotic neuronal death and inflammation: *in vivo* and *in vitro*. *Front Neurosci* 2017;11:583.
 18. Qinli Z, Meiqing L, Xia J, Li X, Weili G, Xiuliang J, et al. Necrostatin-1 inhibits the degeneration of neural cells induced by aluminum exposure. *Restor Neurol Neurosci* 2013;31:543–55.
 19. Mohan V, Sinha RA, Pathak A, Rastogi L, Kumar P, Pal A, et al. Maternal thyroid hormone deficiency affects the fetal neocortico-genesis by reducing the proliferating pool, rate of neurogenesis and indirect neurogenesis. *Exp Neurol* 2012;237:477–88.
 20. Domingues JT, Wajima CS, Cesconetto PA, Parisotto EB, Winkelmann-Duarte E, Santos KD, et al. Experimentally-induced maternal hypothyroidism alters enzyme activities and the sensorimotor cortex of the offspring rats. *Mol Cell Endocrinol* 2018;478:62–76.
 21. Amano I, Takatsuru Y, Toya S, Hajjima A, Iwasaki T, Grasberger H, et al. Aberrant cerebellar development in mice lacking dual oxidase maturation factors. *Thyroid* 2016;26:741–52.
 22. Salami M, Bandegi AR, Sameni HR, Vafaei AA, Pakdel A. Hippocampal up-regulation of apolipoprotein d in a rat model of maternal hypo- and hyperthyroidism: implication of oxidative stress. *Neurochem Res* 2019;44:2190–201.
 23. Ahmed OM, Ahmed RG, El-Gareib AW, El-Bakry AM, Abd El-Tawab SM. Effects of experimentally induced maternal hypothyroidism and hyperthyroidism on the development of rat offspring: II-the developmental pattern of neurons in relation to oxidative stress and antioxidant defense system. *Int J Dev Neurosci* 2012;30:517–37.
 24. Cattani D, Goulart PB, Cavalli VL, Winkelmann-Duarte E, Dos Santos AQ, Pierozan P, et al. Congenital hypothyroidism alters the oxidative status, enzyme activities and morphological parameters in the hippocampus of developing rats. *Mol Cell Endocrinol* 2013;375:14–26.
 25. Belenky P, Bogan KL, Brenner C. NAD⁺ metabolism in health and disease. *Trends Biochem Sci* 2007;32:12–9.
 26. Masullo LF, Magalhães RA, Lemes RPG, de Almeida Filho TP, de Castro MF, Maia Filho PA, et al. Levothyroxine replacement improves oxidative status in primary hypothyroidism. *Front Endocrinol (Lausanne)* 2018;9:655.
 27. Ates I, Altay M, Yilmaz FM, Topcuoglu C, Yilmaz N, Berker D, et al. The impact of levothyroxine sodium treatment on oxidative stress in Hashimoto's thyroiditis. *Eur J Endocrinol* 2016;174:727–34.