

# The X-Pulley Technique for Subpectoral Long Head of the Biceps Tenodesis Using All-Suture Anchors



Paolo Consigliere, M.D., Shadi Salamat, Nardeen Kader, M.B.B.S.,  
Mohamed Imam, M.D., F.R.C.S.(Orth&Trauma),  
Abhilash Gowda, F.R.C.S.(Orth&Trauma), and  
A. Ali Narvani, M.B.B.S.(Hons), B.Sc.(Hons), M.Sc.(Sports Med)(Hons),  
F.R.C.S.(Orth&Trauma), M.F.S.E.M.(UK)

**Abstract:** Subpectoral long head of the biceps tenodesis is gaining popularity as a technique for treating patients with various pathologies of the tendon or its anchor to the superior labrum. It has the added advantage of addressing bicipital groove pathologies. Various techniques for performing it have been described, but none is without problems. We present a modification of the previously described techniques that involves 2 all-suture anchors and offers the added advantage of a reduced risk of fracture without sacrificing the biomechanical strength of the construct. We also believe that it may potentiate healing by providing an adequate surface contact area between the tendon and bone with a minimal risk of damage to the tendon and neurovascular structures.

**P**ain associated with the long head of the biceps (LHB) is common and may be due to a number of pathologies including tendinopathy, instability, entrapment, and traumatic and sport-related types. Common surgical options include LHB tenotomy and tenodesis. Although tenotomy is quick and technically simple to perform with a short rehabilitation period, it may be associated with the Popeye sign, as well as a cramping sensation over the biceps and, arguably, loss of elbow supination strength. Tenodesis is therefore generally the more preferred option in younger and active patients and in patients who are bothered by the cosmetic

appearance of the Popeye sign who do not respond to the nonoperative route.

A number of surgical techniques have been described for tenodesis depending on the location of the tenodesis (supraperotoral<sup>1</sup> vs subpectoral<sup>2</sup>), the fixation device used in either a unicortical or bicortical manner (anchors, interference screws, and EndoButtons [Smith & Nephew Endoscopy]), and the suture technique (including simple sutures, the lasso-loop stitch, the Krackow stitch, and the triple-loop stitch), as well as whether the procedure is performed by open or arthroscopic means (Table 1). The main advantage of the subpectoral technique is the decreased risk of residual pain due to the bicipital groove pathology because the tendon is removed from the bicipital groove. The disadvantage of subpectoral tenodesis is that it may be associated with an increased risk of fracture as a result of fixation in the metaphyseal-diaphyseal bone or the diaphyseal bone giving rise to potential stress risers particularly with larger fixation devices such as interference screws and EndoButtons and with techniques that involve bicortical fixation.<sup>3</sup> Generally speaking, using suture anchors involves smaller holes in 1 cortex, but the worry is that the construct may not be biomechanically as strong with lower ultimate failure loads. In addition, with suture anchor techniques, the tendon is required to heal to the surface of the humeral cortex instead of within the canal, which may compromise healing.

From the Rowley Bristow Orthopaedic Unit, Ashford & St Peter's Hospitals National Health Service Foundation Trust (P.C., S.S., N.K., M.I., A.G., A.A.N.), Chertsey; and Fortius Clinic (A.A.N.), London, England.

The authors report the following potential conflicts of interest or sources of funding: P.C. receives clinical fellowship funding and research funding from Arthrex. A.A.N. receives education support from Stryker and research funding support from Arthrex. Full ICMJE author disclosure forms are available for this article online, as [supplementary material](#).

Received August 7, 2018; accepted October 19, 2018.

Address correspondence to Paolo Consigliere, M.D., Rowley Bristow Orthopaedic Unit, Ashford & St Peter's Hospitals NHS FT, Guildford Road, Chertsey, Surrey KT16 0PZ, England. E-mail: [paoloconsigliere@gmail.com](mailto:paoloconsigliere@gmail.com)

Crown Copyright © 2018 Published by Elsevier on behalf of the Arthroscopy Association of North America. This is an open access article under the CC BY-NC-ND license (<http://creativecommons.org/licenses/by-nc-nd/4.0/>).

2212-6287/18980

<https://doi.org/10.1016/j.eats.2018.10.012>

**Table 1.** Tenodesis Technique for LHB

	Tenodesis Position	Tenodesis Technique
Suprapectoral—arthroscopic	Intra-articular Bicipital groove	Onlay: bone anchor technique Inlay: interference screw Tunnel technique Biceps tenodesis in soft tissue
Subpectoral—open	Bicipital groove	Onlay: bone anchor technique Inlay: interference screw Monocortical: metal button, all-suture anchors Bicortical fixation: metal button, all-suture anchors
Transfers—open	Conjoint tendon	Biceps tenodesis to conjoint tendon

LHB, long head of biceps.

In this article, we describe a technique that uses 2 all-suture anchors using the “pulley” technique with a special suture configuration (X shaped) for subpectoral tenodesis (Video 1). We believe that this technique reduces the risk of fracture because the holes for the all-suture anchors are small and involve 1 cortex. Furthermore, by using 2 double-loaded suture anchors with a particular suture pattern through the tendon, we believe that we have optimized the biomechanical properties of the construct, as well as the surface area for healing of tendon to bone. In addition, the pulley technique used here facilitates the delivery of tendon to bone and the tensioning of the construct (Table 2).

### Surgical Technique

The procedure (Table 3) is performed with the patient in the beach-chair position, under general anesthesia combined with an interscalene nerve block. The beach-chair position facilitates access to the LHB for subpectoral biceps tenodesis. Pump pressure is typically around 40 mm Hg, and visualization is further aided by hypotensive anesthesia with a systolic blood pressure goal of 90 mm Hg.

#### Arthroscopic Tenotomy

A standard posterolateral portal is used to perform a diagnostic arthroscopy to assess the intra-articular portion of the LHB. A lesion to the anchor, pulleys, or tendon itself can be visualized. By use of an anterior portal through the rotator interval, the tendon is pulled into the joint with a grasper or probe to visualize the portion hidden in the bicipital groove, which can be affected by tendinitis or tendinopathy. A stay stitch is passed through the articular portion of the tendon with a suture passer, and by use of a radiofrequency device (DePuy Mitek) at 90°, a tenotomy is performed at the insertion of the tendon to the labrum (Fig 1).

#### Subpectoral Approach

A 2- to 4-cm strap incision is performed in the anterior aspect of the shoulder just distal to the pectoralis major tendon (Fig 2), lateral to the axillary fold (standard subpectoral approach). Most of the time, excluding cases

of excessive shoulder swelling, the LHB is palpable under the skin and can help to locate the incision position. After sharp dissection of the skin and fat, hemostasis is performed. The fascia immediately inferior to the pectoralis major tendon is incised, and the inferior edge of the pectoralis major tendon is retracted superiorly to expose the LHB tendon.

#### Tendon Preparation

The tendon is withdrawn through the incision and retracted from the joint. The most proximal part (intra-articular and intra-bicipital groove portions) is usually affected by significant synovitis and tearing and is therefore first marked and then excised (2 cm proximally to the muscle-tendon junction) (Fig 3).

#### Bone Preparation

The distal third of the bicipital groove is prepared using a 4-mm burr. The cortical surface is prepared enough to cause bleeding without decorticating the bone to avoid weakening it. Irrigation with saline solution in a 50-mL syringe is used to reduce thermal necrosis and the formation of heterotopic ossification.

#### Anchor Position

The superior border of the pectoralis major muscle is identified and used as a reference to decide the level of the tenodesis, which will be 2 cm distal to it. This technique uses two 2.3-mm double-strand all-suture anchors (Iconix; Stryker) (Fig 4). The more proximal anchor is inserted first, 2 cm distal to the superior margin of the pectoralis tendon. The second anchor follows and is inserted 2 cm distal to the first (Figs 5 and 6). A 2.3-mm drill is used to drill through the anterior

**Table 2.** Key Points

Reduces the risk of fracture because the holes for the all-suture anchors are small and involve 1 cortex
Reduces the risk of neurovascular injuries
Optimizes the biomechanical properties of the construct
Increases the tendon-bone surface contact, which is mandatory to achieve good results
Facilitates the delivery of the tendon to bone

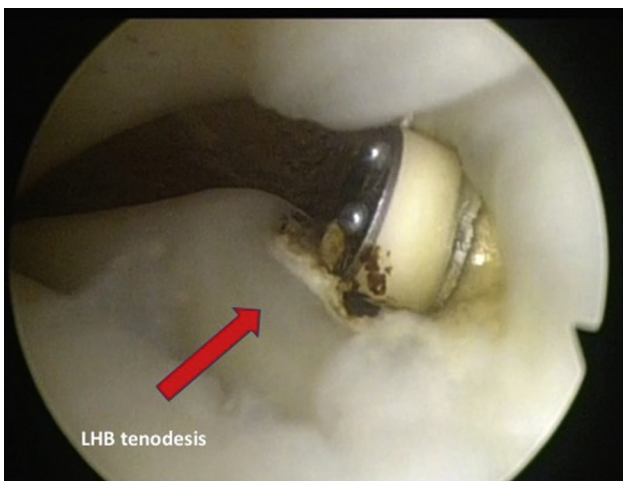**Table 3.** Surgical Steps Involved in X-Pulley Technique

---

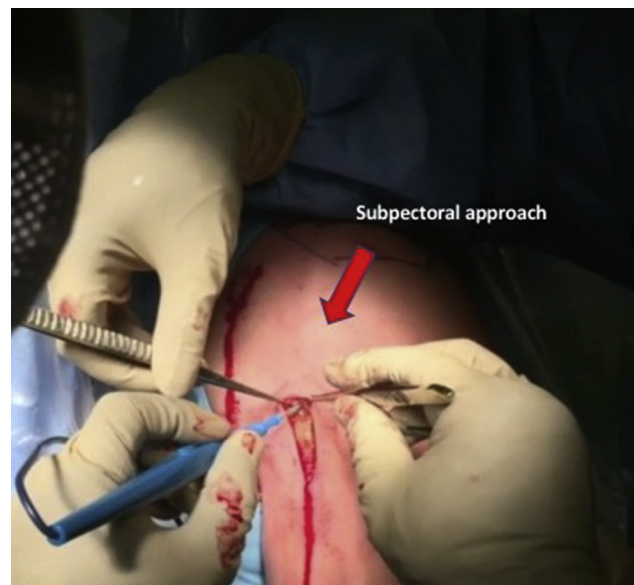
Patient position	
General anesthesia and a regional block are administered.	
The beach-chair position is used.	
Arthroscopy	
Exploration of the glenohumeral joint is performed, with evaluation of the LHB tendon.	
A stay stitch is passed into the intra-articular portion of the LHB tendon with a suture passer.	
Biceps tenotomy at the junction between the LHB and superior labrum is performed with a Vaprr device (DePuy Mitek) at 90°.	
Open approach	
The shoulder is placed in 40° of flexion, 30° of abduction, and neutral rotation.	
A subpectoral approach is used, with a 2- to 4-cm incision centered on the LHB and pectoralis major tendon.	
Sharp dissection is performed through the skin, fat, and pectoralis fascia.	
Blunt dissection is performed to isolate the LHB from the pectoralis tendon.	
Biceps tendon preparation	
The LHB tendon is withdrawn through the incision.	
Excision of the intra-articular and groove portions of the LHB tendon is performed (2 cm from the muscle-tendon junction).	
The LHB tendon is secured with a clamp.	
Bone preparation	
By use of a small 4-mm burr, the cortex is prepared enough to cause bleeding without decorticating the bone.	
A 2.3-mm drill is used to drill through the anterior cortex of the humerus in the distal third of the groove.	
A proximal hole is made 2 cm distal to the superior edge of the pectoralis tendon.	
A distal hole is made 2 cm distal to the proximal hole.	
Anchor insertion	
Two 2.3-mm double-strand all-suture anchors (Iconix) are inserted.	
The stability of the anchor is assessed.	
Suture passes	
Mattress stitches using 1 suture from each anchor (A-B and A1-B1) are passed through the tendon; knots are not tied at this stage.	
One cross (X) stitch is performed using 1 suture from each anchor (C-D and C1-D1).	
Tenodesis	
Two free ends are tied together (C-D), and the suture ends are trimmed.	
The other 2 free ends (C1-D1) can be used to parachute the tendon into the wound (parachute technique).	
Once good tension and good tendon-to-bone contact are achieved, the other knot can be tied (C1-D1).	
The mattress knots can now be tied (A-B and A1-B1).	
The suture ends are trimmed.	
Tension and stability are tested on the table.	
Closure	
Closure by layers is performed.	

---

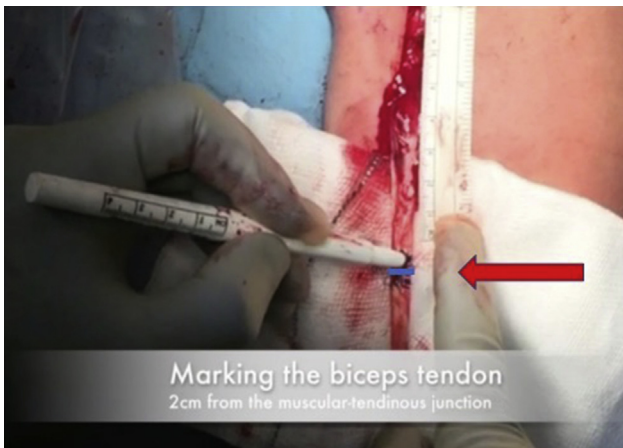LHB, long head of biceps.



**Fig 1.** Arthroscopic tenotomy. The patient is in the beach-chair position, with viewing of the left shoulder joint from the posterior portal. A radiofrequency device (DePuy Mitek) at 90° is used to perform tenotomy of the long head of the biceps (LHB) at its insertion to the labrum.



**Fig 2.** Subpectoral approach. The patient is in the beach-chair position, left shoulder, and sharp dissection is performed through the skin, fat, and fascia. The incision starts proximally at the level of the inferior edge of the pectoralis major muscle and runs distally for 2 to 4 cm.



**Fig 3.** Marking of long head of biceps (arrow). The patient is in the beach-chair position, left shoulder. Through a subpectoral approach, the biceps tendon is retrieved through the wound and is marked 2 cm from the musculotendinous junction. At this level, the tendon will be cut to eliminate the most proximal part, which is usually affected by severe tenosynovitis. This mark also helps to find the correct tension because this end will be sutured 2 cm distal to the proximal edge of the pectoralis tendon (distal third of bicipital groove).

cortex of the humerus (Fig 7). With this technique, drilling of the second cortex of the humerus is not expected, thus reducing the risk of nerve injury using a bicortical guidewire and reducing the risk of fracture (which is believed to be higher with bicortical techniques).<sup>4</sup> In addition, during this step, irrigation with saline solution in a 50-mL syringe is used to reduce thermal necrosis and the formation of heterotopic ossification.

### Tenodesis

The first step is to pass 1 suture from each anchor to the tendon (Fig 8): 2 horizontal mattress stitches (A-B and

A1-B1) are passed through the biceps tendon, 2 cm from each other (Fig 9). The second step is to pass 1 suture from each anchor (C-D and C1-D1) through the tendon, between the 2 mattress stitches, in an X-shaped configuration. The first knot (C-D) is tied outside the shoulder, and the suture ends are trimmed (Fig 10). This allows the surgeon to use the other suture extremities (C1-D1) to parachute the knot down into the wound and achieve good tendon-to-bone contact (pulley technique) (Fig 11).

Once good tension and tendon-to-bone contact are secured, the knot between C1 and D1 is tied. An arthroscopic knot pusher can be used to facilitate this step (Fig 12). After this step, the knots from the mattress stitches are tied in the same fashion (A-B and A1-B1) (Figs 13 and 14).

### Assessment and Closure


The tenodesis strength and stability are checked on the table by performing flexion-extension movements. Standard closure by layers is performed after profuse irrigation is completed.

### Rehabilitation

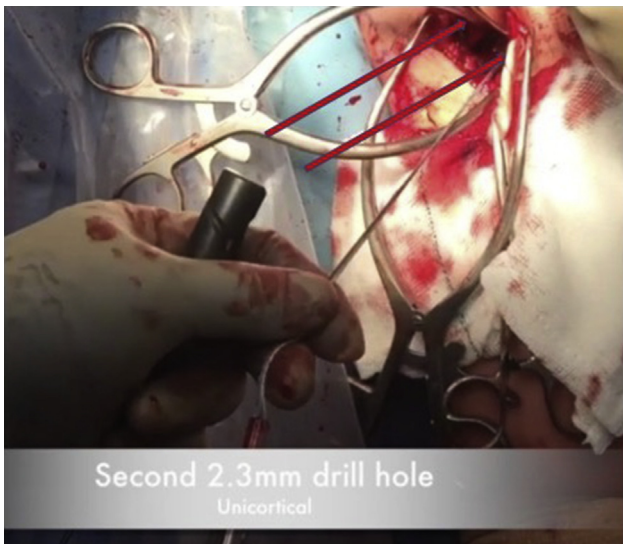
Postoperatively, the shoulder is kept in a poly-sling for 6 weeks. Active elbow flexion and forearm supination are limited. Passive range of motion is encouraged and physical therapy begins 3 to 5 days after surgery. If other procedures are performed in the same setting (rotator cuff repair, labral repair), the rehabilitation regimen might vary.

### Discussion

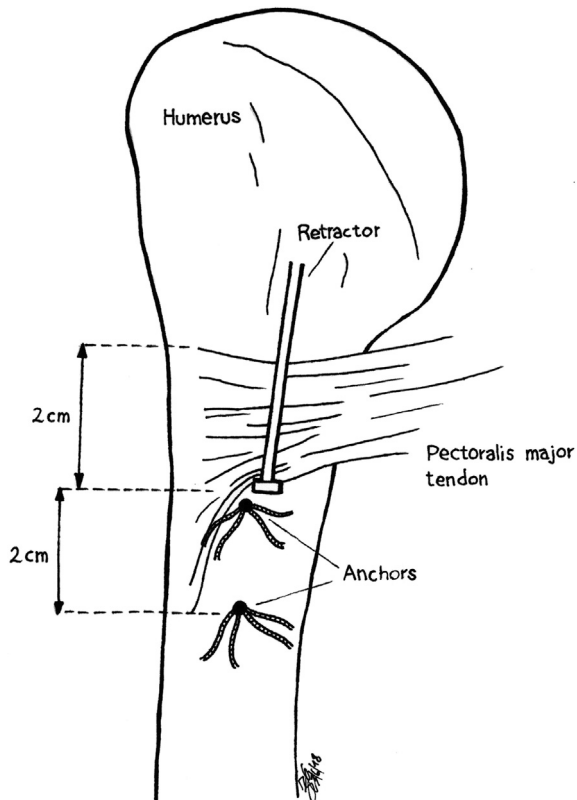
In recent years, subpectoral tenodesis has gained popularity in the management of patients with symptomatic LHB pathologies and some types of SLAP lesions. Because the tendon is removed from the bicipital groove, it is proposed that this technique reduces the risk of



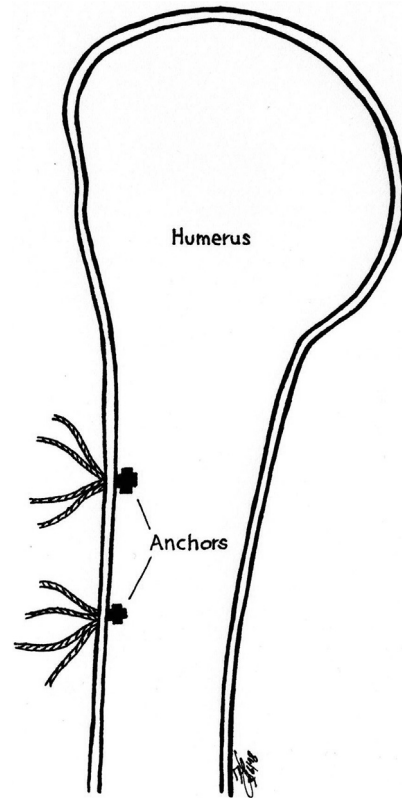
**Fig 4.** Anchors (2.3-mm Iconix). All-suture anchors are used to perform the tenodesis in the described technique. Each anchor has 2 strands.



**Fig 5.** Second drill hole. The patient is in the beach-chair position, left shoulder. Through a subpectoral approach, the bone is exposed and two 2.3-mm all-suture anchors are inserted (in line, proximal to distal, 2 cm apart) to perform the tenodesis. The more proximal anchor is inserted first, 2 cm distal to the superior margin of the pectoralis tendon. The second anchor follows and is inserted 2 cm distal to the first. A 2.3-mm drill is used to drill through the anterior cortex of the humerus. The all-suture anchor is inserted, and stability is immediately tested on the table.

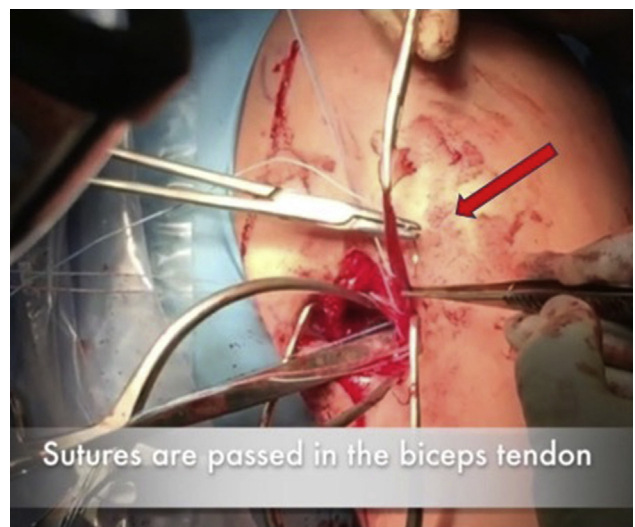


**Fig 6.** Anchor position. The pectoralis tendon is retracted superiorly to expose the bicipital groove. The most proximal anchor is localized 2 cm distal to the superior edge of the pectoralis major tendon and the second anchor, 2 cm distal to the first.

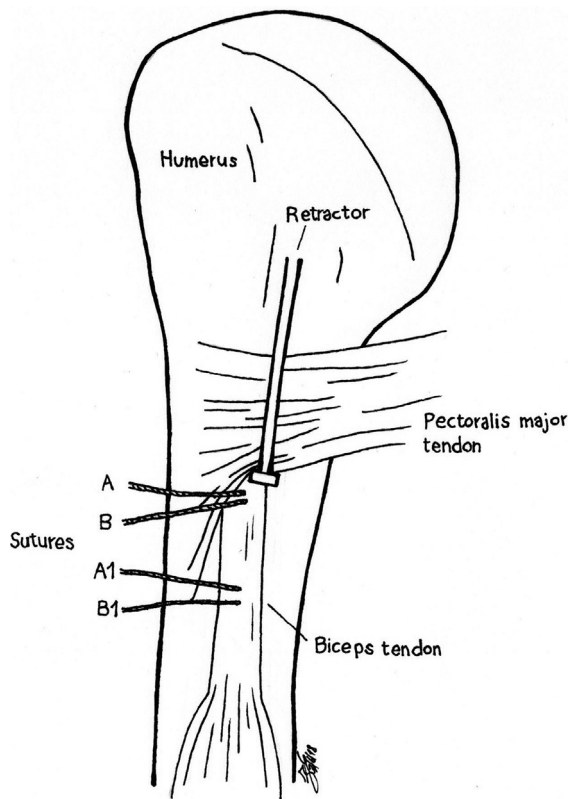


**Fig 7.** Monocortical hold of all-suture anchors in distal third of bicipital groove of humerus. This reduces iatrogenic neurovascular injuries.

residual pain due to bicipital groove pathology. The worry, however, is the risk of fracture as a result of fixation in the metaphyseal-diaphyseal bone or the diaphyseal bone giving rise to potential stress risers particularly with larger fixation devices such as interference screws



**Fig 8.** Suture passes. The patient is in the beach-chair position, left shoulder. The tendon is retrieved outside the wound (arrow). After the more proximal part of the tendon is resected, the sutures are passed through the tendon.



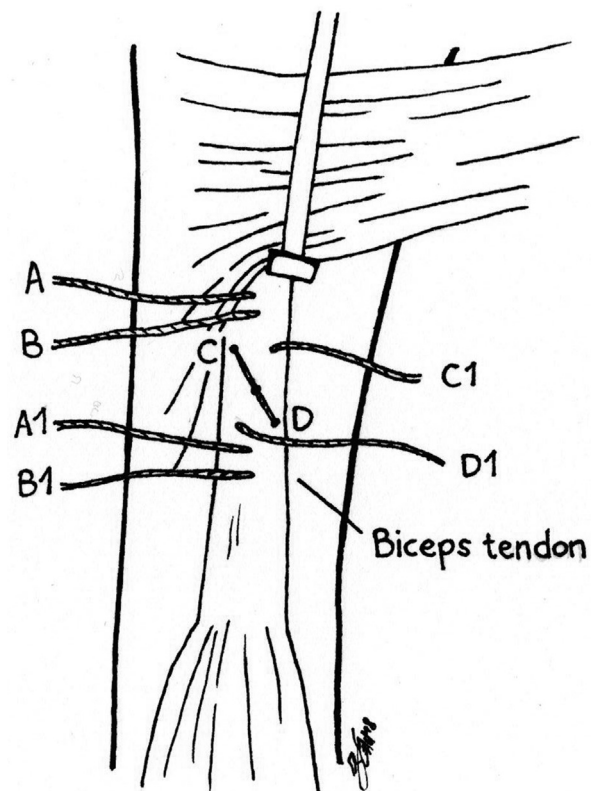
**Fig 9.** Step 1. The pectoralis tendon is retracted superiorly to expose the bicipital groove. The first 4 suture ends (1 suture from each anchor) are passed through the tendon in a mattress fashion (A-B and A1-B1). These sutures are passed at the same level as the anchors (2 cm from each other) oriented in line with the tendon (proximal to distal).

and EndoButtons and particularly with techniques that involve bicortical fixation.<sup>5</sup> Large holes (up to 8 mm) may be required for interference screws, and these may act as stress risers. The incidence of humeral fracture in young adults has been documented.<sup>6</sup> In addition, the findings of a recent biomechanical study suggested that drilling an 8-mm unicortical tunnel decreased the torsional load to failure by 30% compared with an intact specimen.<sup>3</sup> Insertion of an 8-mm PEEK (polyether ether ketone) screw did not influence this reduction, but insertion of the biceps tendon into the tunnel in addition to the screw reduced the torsional load to failure by 20%.<sup>3</sup>

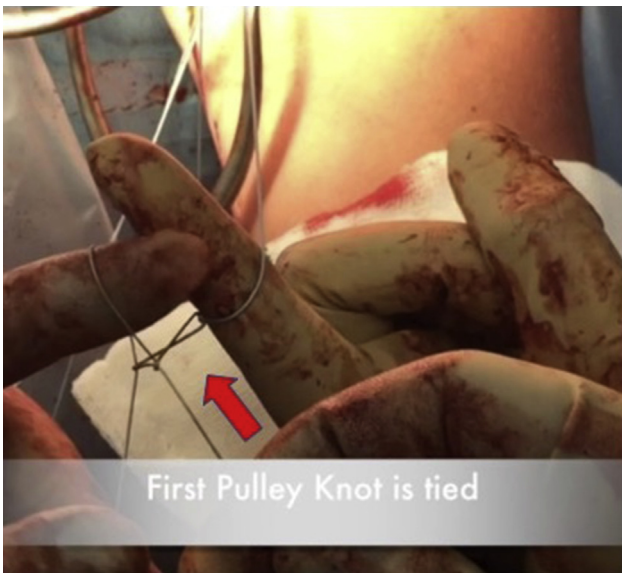
The other possible drawback of an interference screw is the theoretical weakening of the tendon by the screw during insertion.<sup>7</sup> The risk of this tendon damage appears to be lower with cortical buttons; nevertheless, the cortical holes are still reasonably large and will involve both cortices with bicortical techniques. Therefore, the risk of fracture may persist with the buttons.<sup>8</sup> Furthermore, biomechanically, the construct with the button may not be the strongest. In addition, there are concerns of neurovascular damage with bicortical techniques.<sup>4,8</sup>

Another fixation option is suture anchors, which generally require smaller holes and involve unicortical techniques; therefore, the risk of fracture and neurovascular damage is possibly lower. The issue, however, is that most publications have shown a weaker biomechanical construct than with the interference screw. Yet, the ultimate failure load may be increased by using 2 suture anchors.<sup>7</sup> In recent years, all-suture anchors have been gaining popularity in arthroscopic shoulder surgery. They offer several advantages in that they do not involve inserting large metallic, PEEK, or biocomposite anchors into bone and they require very small holes. As the anchor is placed through the bone cortex and tensioned, the all-suture anchor expands laterally through the hole to grip and provide an anchoring effect. The use of these anchors has also been documented in subpectoral LHB tenodesis, in which the authors used them as bicortical fixation devices<sup>4</sup> (Table 4).

The X subpectoral tenodesis technique with 2 all-suture anchors described in this article is a combination

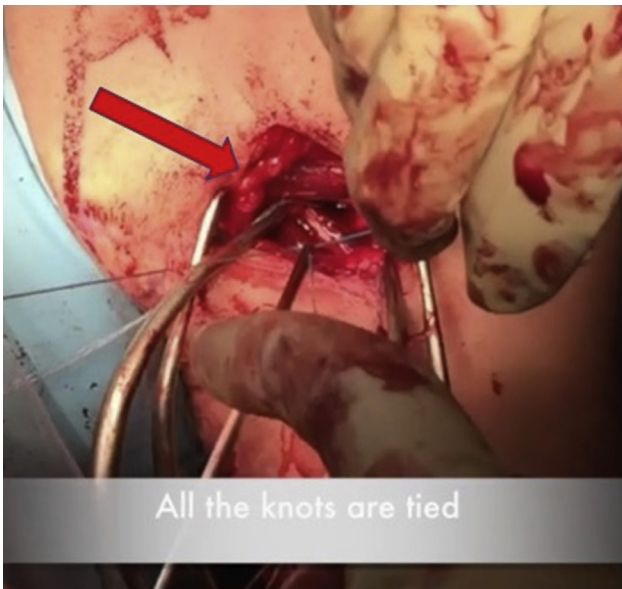


**Fig 10.** The patient is in the beach-chair position. Once the anchors have been inserted and the sutures have been passed through the tendon, the surgeon ties 1 suture from each anchor (C-D) together and trims the ends. This knot will pull the tendon over into the wound, ensuring good tendon-bone contact (pullover technique—the other 2 free ends of the sutures [C1-D1] are concurrently pulled to advance the knot into the wound).

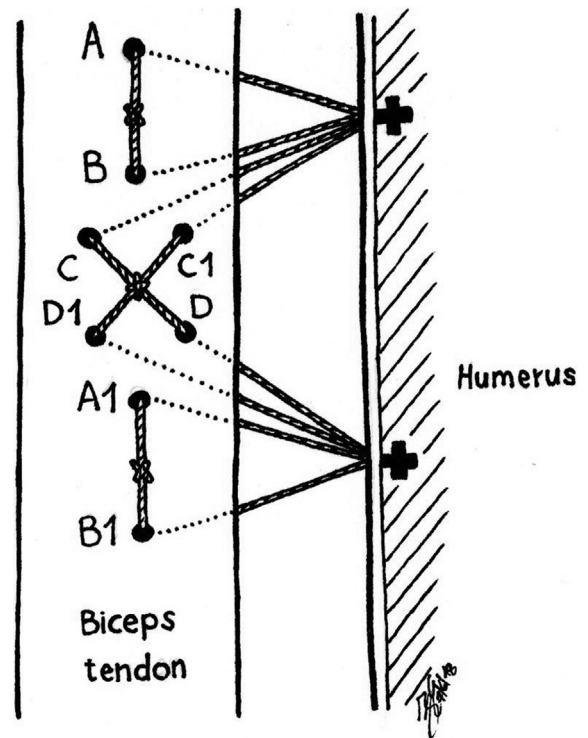


**Fig 11.** Step 2. The pectoralis tendon is retracted superiorly to expose the bicipital groove. The other 4 ends (C-D and C1-D1) are passed through the biceps tendon to create an X-type configuration. The surgeon ties 1 suture from each anchor (C-D) together and trims the ends (arrow). The other 2 free ends (C1-D1) are tensioned and used to parachute the tendon into the wound (pulley technique).

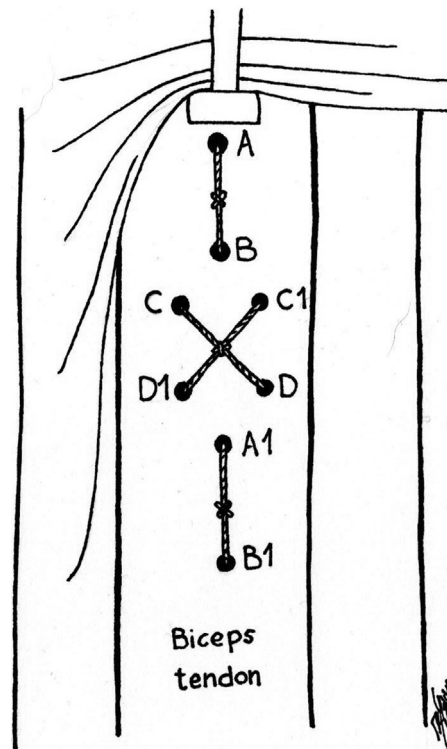
of a number of previously described techniques, with the added advantage of offering a reduced risk of fracture because the holes for the all-suture anchors are small and involve 1 cortex without sacrificing the biomechanical strength of the construct. We also believe that it offers optimized healing by providing an adequate surface contact area between the tendon and bone.



**Fig 12.** Knot tying. The patient is in the beach-chair position, left shoulder. Once all the sutures are passed through the tendon, all the knots are tied. A knot pusher can be used to facilitate this step (arrow).



**Fig 13.** Suture configuration. At this stage, a knot between the other 2 free ends (C1-D1) is tied (an arthroscopic knot pusher can be used for this step) and good tendon-to-bone contact is achieved. The sutures of the 2 horizontal mattress stitches (A-B and A1-B1) are tensioned, and knots are tied.



**Fig 14.** Final result of X-pulley subpectoral tenodesis. The suture configuration as should be seen by the surgeon at the end of the procedure is shown.

**Table 4.** Comparison of X-Pulley Technique With Other Known Techniques

X-Pulley Technique	Other Techniques
Small anchors used	Larger anchors used
Smaller cortical holes	Larger holes in cortex
Reduced risk of fracture	Higher risk of iatrogenic fracture
Monocortical anchor fixation	Bicortical shaft insertion
Reduced risk of neurovascular injury	Higher risk of neurovascular damage
Lower fracture risk	Higher risk of fracture
Easier and quicker to perform	
All-suture anchors used	Metal or PEEK anchors used
No metal inserted	Metal or PEEK material left in shoulder
Amenable to revision surgery	Need for removal in revision surgery or further surgery
Particularly indicated in cortical bone	Risk of migration or mobilization
	Interference screw weakens tendon during insertion
	Designed to have good hold in cancellous bone but not so much in cortical bone
Subpectoral fixation	Suprapectoral fixation
Treats pathology in groove	Does not address tendon pathology in groove
Allows good length and tension to be restored	Difficult to restore appropriate length and tension
	Possible over-tensioning
Wide contact surface (tendon-bone)	Single-anchor tenodesis
Offers optimized healing	Minimal contact surface
Good long-term stability	Risk of no healing or delayed healing and tenodesis failure
	Weaker fixation in case of osteoporotic bone
Pulley technique allows tendon to be delivered or parachuted into wound with good tendon-to-bone contact	Good tendon-to-bone contact can be difficult to obtain

The holes made for the anchors are 2.3 mm in diameter, are unicortical, and are 2 cm apart; therefore, the risk of fracture may be lower than with techniques that involve large holes with insertion of large anchors or EndoButtons in a bicortical manner. Because the 2 all-suture anchors are 2 cm apart, there is a large surface contact area between the tendon and bone, which we believe will maximize the healing potential. The insertion of 2 anchors coupled with our X suture configuration through the LHB leads to a biomechanically strong construct. In addition, this technique uses the pulley technique, which facilitates the delivery of the LHB to anchors and the tensioning of the sutures. Furthermore, no damage to the tendon occurs as the result of the interference screw and the risk of neurovascular damage is minimized because the technique is unicortical<sup>4</sup> (Table 5).

There are a number of possible concerns with our technique. Some investigators may argue that any construct involving anchors is not going to match the

biomechanical strength of fixation involving interference screws. This may be the case with 1 anchor but does not appear to be the case with a dual-anchor technique. In a biomechanical study by Tashjian et al.,<sup>9</sup> ultimate failure loads were similar between interference screw and dual-anchor constructs. In addition, we believe that our suture configuration through the tendon potentially provides additional biomechanical strength. Another possible drawback of suture anchor and EndoButton unicortical techniques is that the tendon is required to heal to the surface of the humeral cortex instead of within the canal, which may compromise healing. We have tried to address this issue by using a 2-cm gap between the 2 anchors to increase the surface contact area between the tendon and bone. This coupled with freshening of the bone surface between the 2 anchors would help to potentiate tendon-to-bone healing.

In summary, the X subpectoral tenodesis technique with 2 all-suture anchors described in this article is a

**Table 5.** Pearls and Pitfalls

Pearls	Pitfalls
Extra-articular, avoiding intra-articular chondral damage	Extra-articular, with possible neurovascular damage
Excision of inflammatory distal portion of long head of biceps	No access to bicipital groove's inflamed soft tissues
Procedure is often performed in combination with shoulder arthroscopy; therefore, swelling in soft tissue is not uncommon	Difficult to recognize anatomy if swelling is severe
Patient positioning and theater setup need to be planned in advance	Difficult to perform approach if patient is not correctly positioned
All-suture anchors allow small cortical holes and reduce risk of fracture	Open surgery instruments are required
X-type configuration increases tendon-bone surface contact	Increase in operative time
Pulley technique allows bone-tendon contact to be maximized	Wound complication risks



combination of a number of previously described techniques that offers the added advantage of a reduced risk of fracture because the holes for the all-suture anchors are small and involve 1 cortex without sacrificing the biomechanical strength of the construct. We also believe that it offers optimized healing by providing an adequate surface contact area between the tendon and bone with a minimal risk of damage to the tendon and neurovascular structures.

### References

1. Moros C, Levine WN, Ahmad CS. Suture anchor and percutaneous intra-articular transtendon biceps tenodesis. *Sports Med Arthrosc* 2008;16:177-179.
2. Patzer T, Santo G, Olender GD, Wellmann M, Hurschler C, Schofer MD. Suprapectoral or subpectoral position for biceps tenodesis: Biomechanical comparison of four different techniques in both positions. *J Shoulder Elbow Surg* 2012;21:116-125.
3. Mellano CR, Frank RM, Shin JJ, et al. Subpectoral biceps tenodesis with PEEK interference screw: A biomechanical analysis of humeral fracture risk. *Arthroscopy* 2018;34:806-813.
4. Su WR, Ling FY, Hong CK, Chang CH, Lin CL, Jou IM. Subpectoral biceps tenodesis: A new technique using an all-suture anchor fixation. *Knee Surg Sport Traumatol Arthrosc* 2014;23:596-599.
5. Sears B, Marra G, Gramstad G. Variation of tension in the long head of the biceps tendon as a function of limb position with simulated biceps contraction. *Int J Shoulder Surg* 2010;4:8-14.
6. Sears BW, Spencer EE, Getz CL. Humeral fracture following subpectoral biceps tenodesis in 2 active, healthy patients. *J Shoulder Elbow Surg* 2011;20:e7-e11.
7. Jacxsens M, Granger EK, Tashjian RZ. Clinical and sonographic evaluation of subpectoral biceps tenodesis with a dual suture anchor technique demonstrates improved outcomes and a low failure rate at a minimum 2-year follow-up. *Arch Orthop Trauma Surg* 2018;138:63-72.
8. Gomes N, Ribeiro da Silva M, Pereira H, Aido R, Sampaio R. Long biceps subpectoral tenodesis with suspensory button and bicortical fixation. *Arthrosc Tech* 2017;6:e1049-e1055.
9. Tashjian RZ, Henninger HB. Biomechanical evaluation of subpectoral biceps tenodesis: Dual suture anchor versus interference screw fixation. *J Shoulder Elb Surg* 2013;22:1408-1412.