



Contents lists available at ScienceDirect

International Journal of Surgery Case Reports

journal homepage: www.casereports.com

Unusual pneumoperitoneum secondary to ruptured liver abscess-A case report

Nagamallesh C S*, Harish K L

Dept of General Surgery, Saphthagiri Institute of Medical Sciences & Research Centre, Karnataka, 570001, India

ARTICLE INFO

Article history:

Received 9 December 2020

Received in revised form

26 December 2020

Accepted 27 December 2020

Available online 2 January 2021

Keywords:

Pyogenic liver abscess

Pneumoperitoneum

Klebsiella

Hollow viscus perforation

Laparotomy

ABSTRACT

INTRODUCTION: Pyogenic liver abscess is important cause of hospitalization and life threatening disease in low-middle income countries. Clinical spectrum of ruptured GFPLA can mimic hollow viscus perforation as it usually accompanied by pneumoperitoneum and peritonitis.

CASE PRESENTATION: We reported here a case with pneumoperitoneum caused by ruptured liver abscess in a 27-year-old man with a history of uncontrolled type II diabetes mellitus. He had an abdominal pain, distension of abdomen associated with a high fever. Patient was diagnosed peritonitis and pneumoperitoneum presumed to be secondary to perforation of a hollow viscus and subjected to emergency laparotomy. We did not find any gastrointestinal perforation. Surprisingly, we detected a ruptured liver abscess in the right lobe of the liver. The patient was in septic shock and hence shifted to ICU with inotropic support. Antibiotic therapy was started according to pus culture sensitivity. Even with the above treatment patient was not improved and on 4th postoperative day the patient collapsed and declared dead.

DISCUSSION: Pneumoperitoneum secondary to ruptured gas containing pyogenic liver abscess is rare and could represent as life threatening infection. It should be distinguished from perforation of hollow organ by clinical symptoms and image examinations, particularly like CT. Accurate diagnosis with adequate drainage and antibiotic therapy would bring good outcome.

CONCLUSION: We are aware that not every case of pneumoperitoneum is attributable to a perforated hollow viscus. A rapid and prompt surgical intervention with appropriate antibiotics are essential to save a life.

© 2020 Published by Elsevier Ltd on behalf of IJS Publishing Group Ltd. This is an open access article under the CC BY-NC-ND license (<http://creativecommons.org/licenses/by-nc-nd/4.0/>).

1. Introduction

The work has been reported in line with the SCARE guidelines [1]. Pyogenic liver abscess (PLA) is important cause of hospitalization and life threatening disease in low-middle income countries [2]. A recent population based study from North America calculated an annual incidence of 3.6 cases/100,000 population. Comorbid conditions associated with pyogenic abscess are cirrhosis, diabetes, chronic renal failure, and a history of malignant disease. The potential routes of hepatic exposure to bacteria are the biliary tree, portal vein, hepatic artery, direct extension of a nearby nidus of infection, and trauma. The most common organisms cultured are *Escherichia coli* and *Klebsiella pneumoniae*. *Klebsiella* is frequently associated with gas-forming abscesses. The classic description of the presenting symptoms of hepatic abscess is fever, jaundice, and right upper quadrant pain, with tenderness to palpation [3]. Unfor-

tunately, this presentation is present in only 10 % of cases. Fever, chills, and abdominal pain are the most common presenting symptoms, but a broad array of nonspecific symptoms can be present. Rarely patients can present with peritonitis secondary to rupture of liver abscess.

Nonspecific abnormalities of blood tests are common in pyogenic abscesses. Leukocytosis is present in 70%–90% of patients and anemia is commonly encountered. Abnormalities of LFT results are generally present. The ALP level is mildly elevated in 80 % of patients. Transaminases are mildly elevated in approximately 60 % of patients. Ultrasound and CT are the mainstays of diagnostic modalities for hepatic abscess. Once the diagnosis of pyogenic hepatic abscess is suspected, broad-spectrum IV antibiotics should be started immediately to control ongoing bacteremia and its associated complications. Blood samples and specimens of the abscess from aspiration should be sent for aerobic and anaerobic cultures. Percutaneous catheter drainage has become the treatment of choice for most patients. For a ruptured abscess, surgery is essential, not only to drain the abscess but also to clean the contaminated abdominal cavity [4]. Liver resection is occasionally required for hepatic abscess. This may be required for an infected hepatic malig-

* Corresponding author at: #1648, 2nd Stage, Sardar Vallabhai Patel Nagar, TN Pura Road, Mysore, 570028, Karnataka, India.

E-mail address: Attitudemys95@gmail.com (N. C S).

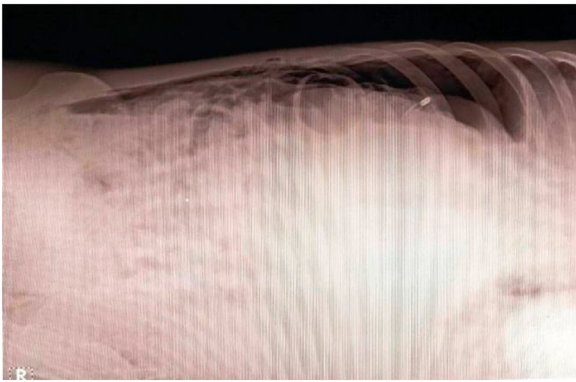


Fig. 1. X-ray abdomen in left lateral decubitus position showing pneumoperitoneum.

nant neoplasm, hepatolithiasis, or intrahepatic biliary stricture. If hepatic destruction from infection is severe, some patients may benefit from resection. Spontaneous gas-forming pyogenic liver abscess is a rare complication with a high fatality rate in spite of aggressive management [5]. Pneumoperitoneum is an unusual presentation for a liver abscess. Conversely liver abscess is rarely the cause of such a finding. Air in the peritoneum is usually attributed to perforation somewhere in the gastrointestinal tract. In our case no perforation of the gastrointestinal tract was found at laparotomy, but the pus obtained during the procedure grew pure *K. pneumoniae* indicating that the rupture of the abscess accounted for the pneumoperitoneum. Clinical spectrum of ruptured GFPLA can mimic hollow viscus perforation as it usually accompanied by pneumoperitoneum and peritonitis.

2. Case presentation

A 27 year male patient presented to the emergency ward with complaints of pain abdomen, distention of abdomen, vomiting and fever since 7 days. Patient was known case of chronic pancreatitis with diabetes on treatment. On examination, his pulse rate was 114/min and blood pressure was 80/50 mmHg and he was febrile with 39.6 °C. On per abdomen examination, abdomen was diffusely distended with guarding and rigidity with absent bowel sounds. His HB% was 8.7 g/dl, wbc 4280 cells/cumm, RBS 265 mg/dl, HBA1C was 12.26 %, AST 395IU/L, ALT 200 IU/L, ALP 260 IU/L, Urea 86 mg/dl and Creatinine 1.4 mg/dl. X-ray abdomen in left lateral decubitus position showed subdiaphragmatic air (Fig. 1), indicating pneumoperitoneum and USG abdomen revealed as tense abdomen with turbid ascites. The patient was diagnosed with a pneumoperitoneum, the latter presumed to be secondary to perforation of a hollow viscus.

Intravenous metronidazole and cefotaxime were immediately started, and an emergency laparotomy was performed. At surgery, around 1 L of turbid pus was drained from the subphrenic and subhepatic spaces. No gastrointestinal perforation was found. During peritoneal lavage, ruptured abscess cavity found on anterior surface of the liver (Fig. 2). Hence we concluded that the pneumoperitoneum resulted from rupture of the hepatic abscess. Later de-roofing of the abscess cavity has been done and the cavity was closed with omentum. A sub hepatic drain was placed and abdomen was closed. The patient was transfused with 2 pints of PRBC and 4 pints of FFP intraoperatively. The patient was in septic shock and hence shifted to ICU with inotropic support. *K. pneumoniae* was isolated from culture of the abscess and was sensitive for piperacillin and tazobactam. Even with the above treatment patient was not improved and on 4th postoperative day the patient collapsed and declared dead after following ACLS guidelines.

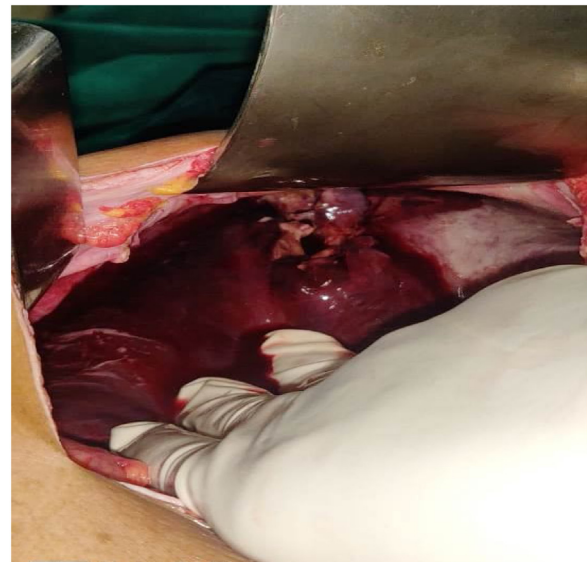


Fig. 2. Intra operative finding showing ruptured liver abscess.

3. Discussion

Pyogenic liver abscess is a common infectious disease worldwide relating to a mortality rate ranging between 15 and 19 % [6,7]. Gas-forming pyogenic liver abscess remains one of the most dangerous complication with a high fatality rate in spite of aggressive management [8]. *Klebsiella pneumoniae* is considered to surpass *Escherichia coli* (*E. coli*) to become the major pathogen of pyogenic liver abscesses, especially in GFPLA and in patients with diabetic mellitus (DM) [9]. Here, we reported a case of *Klebsiella pneumoniae*-induced gas-forming pyogenic liver abscess with uncontrolled DM history. By presenting this case of GFPLA, we aimed to highlight the importance of careful examination by the surgeons when abdominal peritonitis and pneumoperitoneum were present without any perforation of a hollow viscus. This case also implied that CT scan should be performed wherever it is possible to make an early and correct diagnosis of ruptured liver abscess which in turn, help to decrease the operative time and improve the patient outcomes.

4. Conclusion

To conclude, we are aware that not every case of pneumoperitoneum is attributable to a perforated hollow viscus. Additionally, a ruptured hepatic abscess is more life-threatening than an unruptured one. A rapid accurate diagnosis and prompt surgical intervention with appropriate antibiotics are essential to save the life.

Declaration of Competing Interest

The author discloses no conflicts of interest.

Funding

No funding for research.

Ethical approval

None.

Consent

Written informed consent was obtained from the patient for publication of this case report and accompanying images. A copy of the written consent is available for review by the Editor-in-Chief of this journal on request.

Author contribution

Nagamallesh C S, contributed to design, data collection, Writing the paper, critical editing and final approval of the version to be published.

Harish K L contributed to data collection and writing the paper to be published.

Registration of research studies

Not Applicable.

Guarantor

Nagamallesh C S. MS (General surgery).

Provenance and peer review

Not commissioned, externally peer-reviewed.

References

- [1] R.A. Agha, M.R. Borrelli, R. Farwana, K. Koshy, A. Fowler, D.P. Orgill, For the SCARE Group, The SCARE 2018 statement: updating consensus Surgical Case Report (SCARE) guidelines, *Int. J. Surg.* 60 (2018) 132–136.
- [2] G. Khim, S. Em, S. Mo, N. Townell, Liver abscess: diagnostic and management issues found in the low resource setting, *Br. Med. Bull.* 132 (1) (2019) 45–52.
- [3] Section 9. Sabiston Textbook of surgery, The biological Basis of Modern Surgical Practice Edited by Courtney M. Townsend, JR., MD; R Daniel Beauchamp, MD; B. Mark Evers, MD and Kenneth L. Mattox, MD, 19th ed, Elsevier India Private limited, New Delhi, PP, 1445–1449.
- [4] F.F. Chou, S.M. Sheen-Chen, T.Y. Lee, Rupture of pyogenic liver abscess, *Am. J. Gastroenterol.* 90 (1995) 767–770.
- [5] Y.-W. Chiou, Y.-T. Lin, Gas-forming *Klebsiella pneumoniae* liver abscess in a patient without diabetes, *J. Microbiol. Immunol. Infect.* (2014) 48.
- [6] Y. Qian, C.C. Wong, S. Lai, H. Chen, X. He, L. Sun, et al., A retrospective study of pyogenic liver abscess focusing on *Klebsiella pneumoniae* as a primary pathogen in China from 1994 to 2015, *Sci. Rep.* 6 (2016) 38587.
- [7] M. Zizzo, C. Zaghi, A. Manenti, D. Luppi, L. Ugoletti, S. Bonilauri, Abdominal wall abscess secondary to spontaneous rupture of pyogenic liver abscess, *Int. J. Surg. Case Rep.* 25 (2016) 110–113.
- [8] H.L. Lee, H.C. Lee, H.R. Guo, W.C. Ko, K.W. Chen, Clinical significance and mechanism of gas formation of pyogenic liver abscess due to *Klebsiella pneumoniae*, *J. Clin. Microbiol.* 42 (6) (2004) 2783–2785.
- [9] E.R. Lederman, N.F. Crum, Pyogenic liver abscess with a focus on *Klebsiella pneumoniae* as a primary pathogen: an emerging disease with unique clinical characteristics, *Am. J. Gastroenterol.* 100 (2) (2005) 322–331.

Open Access

This article is published Open Access at [sciencedirect.com](https://www.sciencedirect.com). It is distributed under the [IJSCR Supplemental terms and conditions](#), which permits unrestricted non commercial use, distribution, and reproduction in any medium, provided the original authors and source are credited.