

The Implications of Lighted Ureteral Stenting in Laparoscopic Colectomy

Fadi Chahin, MD, Amit J. Dwivedi, MD, Anil Paramesh, MD, Wai Chau, MD, Sunita Agrawal, MD, Chadi Chahin, MD, Anil Kumar, MD, A. Tootla, MD, Farooq Tootla, MD, Yvan J. Silva, MD

ABSTRACT

Objective: The placement of indwelling ureteral catheters during colorectal surgery has been recommended for prevention of ureteral injuries. With the advent of laparoscopic colectomy (LCo), the role of preoperative placement of lighted ureteral stents (LUS) has also become commonplace. We sought to evaluate the value of lighted ureteral stent placement in laparoscopic colectomy.

Methods: Sixty-six patients underwent LCo with LUS inserted preoperatively. Stents were removed in the immediate postoperative period. Two surgeons performed all the colectomies; 32 patients were males and 34 were females. Fifty patients underwent sigmoid colectomy, 4 had abdominoperineal resection, 4 had right colectomy, and 1 each had transverse or subtotal colectomy. Eighteen patients had a diagnosis of cancer, 34 had diverticular disease, and 14 had neoplastic polyps. Forty patients had bilateral and 26 had unilateral stent placement. A review of the incidence of ureteral injuries, hematuria, and anuria as the cause of acute renal failure was accomplished, comparing the unilateral and bilateral stented groups.

Results: One (1.5%) patient suffered a left ureteral laceration during sigmoid colectomy. This was managed successfully with stent reinsertion. Sixty-five (98.4%) patients had gross hematuria lasting 2.93 days (1 to 6 days). The cost of bilateral stent placement was \$1504.32. A statistically significant difference occurred in the duration of hematuria (days) between patients who had unilateral (2.5 ± 0.82) and bilateral stent placement (3.37 ± 1.05), ($P < 0.001$). Four patients suffered from anuria, 2

required renal support needing hemodialysis for 3 to 6 days, 3 (75%) had bilateral stents, and 1 (25%) had a unilateral stent.

Conclusions: We recommend the placement of lighted ureteral stents as a valuable adjunct to laparoscopic colectomy to safeguard ureteral integrity. Transient hematuria is common but requires no intervention. Reflux anuria occurs infrequently and is reversible.

Key Words: Laparoscopy, Colectomy, Lighted Ureteral Stent (LUS), Hematuria.

INTRODUCTION

Iatrogenic injury to the ureter after colorectal surgery is an infrequent but serious complication.¹ The reported incidence of ureteral injury during colorectal surgery has ranged from 0.2 to 4.5%.² The use of prophylactic lighted ureteral stent (LUS) placement has gained more importance with the advent of laparoscopic colectomy.³ Lighted stents help in the visual identification of the ureters during a laparoscopic procedure.

Despite the apparent advantages of prophylactic ureteral stent placement, its effectiveness⁴ is still controversial. Occasionally, prophylactic ureteral catheters are associated with significant morbidity. Injury to the ureters in spite of stent placement, hematuria, and reflux anuria⁵ have also been reported. We report here our experience with prophylactic placement of lighted ureteral stents during laparoscopic colectomy and discuss the value and the outcomes of this procedure.

METHODS

A retrospective analysis was done of 66 patients who underwent laparoscopic colectomy (LCo) with preoperative placement of LUS at North Oakland Medical Centers, Pontiac, Michigan, between April 1996 and January 2000. The catheter used was a polyurethane Bard 6 lighted ureteral catheter™.

The parameters evaluated included age and sex of patients, the indication for surgery, the location of the

Department of Surgery, North Oakland Medical Centers, Pontiac, Michigan USA (all authors).

Wayne State University, Detroit, Michigan USA (Drs F. Chahin, Dwivedi, Paramesh, Chau, Agrawal, C. Chahin, Silva).

Address reprint requests to: Amit Dwivedi, MD, Department of Surgery, 461 W. Huron, North Oakland Medical Centers, Pontiac, MI 48341, USA. Telephone: (248) 857-7314, Fax: (248) 857-6793, E-mail: amitdwivedi@hotmail.com

© 2002 by JSLS, *Journal of the Society of Laparoendoscopic Surgeons*. Published by the Society of Laparoendoscopic Surgeons, Inc.

pathology, the presence or absence of preoperative urinary tract symptoms. The urologic operative reports were reviewed for pathology identified during cystoscopy and ureteral catheterization, duration of the procedure, unilateral or bilateral placement of the catheters, and the size of the ureteral catheter used.

Complications related to ureteral catheter insertion, timing of catheter removal, intraoperative ureteral injury, occurrence of postoperative urinary tract infection, hematuria, and reflux anuria were also reviewed. Operating room charges were also considered along with a comparison of the complications between unilateral and bilateral stent placement.

RESULTS

The study period included patients who underwent surgery between April 1996 and January 2000. A total of 66 patients had LUS placed before laparoscopic colectomy. Thirty-two patients were males and 34 were females. The average age of patients was 62.27 years.

The indications for surgery are summarized in **Table 1**. Diverticular disease was the most common indication for laparoscopic colectomy in 51.5% of patients. The location of the pathology is summarized in **Table 2**. The diverticular disease was located in the sigmoid colon in all the cases. The majority of the colonic polyps were present in the sigmoid colon. Of the 32 male patients, 3 (9.4%) had a history of urinary frequency and 4 (12.5%) had a history of dysuria. Two (5.9%) of 34 female patients studied had stress incontinence. The Bard 6 F lighted ureteral catheter costing \$236.80 was used. The urologic reports for pathology identification, duration of the procedure, and the side of catheter insertion are described in **Table 3**. Complications related to catheter insertion are illustrated in **Table 4**. Sixty-five patients (98.4%) experienced hematuria after catheter insertion. Urinary tract infection (UTI) was assessed with the urine culture reports postoperatively. In spite of the ureteral catheterization, 1 patient suffered an incomplete left ureteral injury during sigmoid colectomy, which was managed conservatively with the reinsertion of a left ureteral stent. The ureteral stents were removed in the immediate postoperative period. The complications following unilateral stenting and bilateral stenting were compared as illustrated in **Figure 1**. The duration of hematuria (days) poststenting between patients who had unilateral (2.5 ± 0.82) and bilateral (3.37 ± 1.05) stent placement was statistically significant with *P*

< 0.001. The cost involved in stent placement included \$1504.32 with an average increase of 26 minutes in operating room time costing \$578, the urologist's charges of \$452.72, and each stent costing \$236.80.

Table 1.
Indications for Operation.

Disease	No. of Patients/Percent (%)
Adenocarcinoma	18/(27.3)
Diverticulitis	34/(51.5)
Neoplastic polyps	14/(21.2)

Table 2.
Location of Pathology.

Location of Pathology	No. of Patients/Percent (%)
Sigmoid	56/(84.8)
Ascending colon	4/(6.1)
Transverse colon	1/(1.5)
Rectum	4/(6.1)
Ascending and Transverse colon	1/(1.5)

Table 3.
Comparison of Unilateral and Bilateral Catheterization

Side of Catheterization	Unilateral	Bilateral
No. of patients	26 (39.4%)	40 (60.6%)
Duration in minutes	16 ± 0.67	29 ± 0.46
Cystoscopy findings	none	Bladder wall edema in 1 patient

Table 4.
Complications of Ureteral Catheterization.

Complications	No. of Patients/ Percent (%)
Hematuria	65/(98.4)
Ureteral injury	1/(1.5)
Reflux Anuria	4/(6.1)
UTI	4/(6.1)

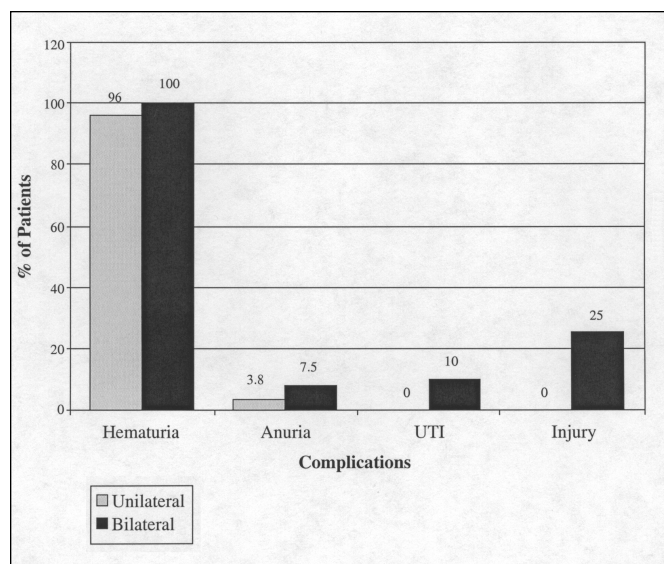


Figure 1. Comparison of complications between unilateral and bilateral stenting. The total percentage of patients with unilateral and bilateral stenting with complications is depicted in the figure.

DISCUSSION

The usefulness and outcomes of prophylactic ureteral stenting during open colorectal surgery has been well documented in the literature.^{3,6} Ureteral catheter placement allows intraoperative tactile localization of the ureters and is helpful in immediate recognition of ureteral injuries. With the introduction of laparoscopic colectomy as an alternative for traditional colorectal surgery, the placement of LUS during laparoscopic colectomy has gained more importance because of visual identification of the ureters. Very few authors have addressed this subject.⁷

In this study, we evaluated the value of prophylactic placement of lighted ureteral stents in laparoscopic colectomy. The most common indication was for diverticular disease followed by colon cancer. Fifty-six (84.8%) of these colectomies involved the sigmoid colon. Unilateral catheterization of the ureters would suffice for most of the segmental colectomy. The majority of our patients had bilateral stents placed initially. As the surgeons gain more experience, the number of stents placed depends on the location of the pathology and the surgeon's preference. Prophylactic stent placement resulted in a 26-minute prolongation of anesthetic time costing \$578.

Ureteral injuries during laparoscopic colectomy have occurred and have also been reported during laparoscopic hysterectomy.⁸⁻¹⁰ Ureteral injuries are of 4 types: laceration, ligation, crush, and devascularization.¹¹ These injuries may be detected either intraoperatively or postoperatively. The placement of prophylactic ureteral stents helps in detecting the ureteral injuries intraoperatively and adequate action to be taken immediately. One (1.5%) patient suffered an incomplete left ureteral injury during sigmoid colectomy. The diagnosis was made with retrograde cystoureterogram. This injury was recognized on postoperative day 2 with urinary ascites and was managed by reinserting the left ureteral stent temporarily. The stent was removed on postoperative day 11, and the patient was discharged.

The placement of ureteral catheters results in postoperative gross hematuria in almost all the patients. Hematuria is present on average for 3 days postoperatively. The placement of bilateral stents significantly increased the duration of hematuria. Overall, this hematuria is of no clinical significance as no blood transfusion is required. On the other hand, reflux anuria is more infrequent but serious and may result in acute renal failure. Anuria is suggested to be the result of neurogenic factors initiated by ureteral manipulation and mediated through the autonomic nervous system.¹²

Studies have demonstrated that anuria after ureteral catheterization is due to edema which causes mechanical obstruction at the ureterovesical junction.¹² Recognition of this symptom, which usually requires repeated ureteral catheterization, is important. In our series, 4 (6.1%) patients had this symptom postoperatively. None of these patients were stented subsequently. Two of these patients developed acute renal failure and required renal support temporarily. Two patients improved without any further intervention. It is possible that the 2 patients who had acute renal failure could have benefited from repeated ureteral stenting.

The incidence of urinary tract infections was acceptable and in most cases was not troublesome. It may be attributable to the postoperative foley catheter that these patients received rather than the ureteral stents.

CONCLUSION

We conclude that prophylactic lighted ureteral catheter placement in laparoscopic colectomy is a safe and cost-

effective procedure. The placement of LUS helps to safeguard against intraoperative ureteral injury. Unilateral stent placement is recommended over bilateral stent placement to reduce operative time and postoperative hematuria. Transient gross hematuria is common but of no clinical significance. Urinary tract infections may occur but are not troublesome. Acute renal failure occurs infrequently but should be recognized immediately. Repeated stent placement could be helpful and renal hemodialysis may be required temporarily.

References:

1. Leff EI, Groff W, Rubin RJ, Eisenstat TE, Salvati EP. Use of ureteral catheters in colonic and rectal surgery. *Dis Colon Rectum*. 1982;25:457-460.
2. Kyzer S, Gordon PH. The prophylactic use of ureteral catheters during colorectal operations. *Am Surg*. 1994;60:212-219.
3. Senagore AJ, Luchtefeld M. An initial experience with lighted ureteral catheters during laparoscopic colectomy. *J Laparoendosc Surg*. 1994;4:399-403.
4. Fry DE, Milholen L, Harbrecht PJ. Iatrogenic ureteral injury. *Arch Surg*. 1983;118:454-457.
5. Sheikh FA, Khubchandani IT. Prophylactic ureteric catheters in colon surgery- How safe are they? Report of three cases. *Dis Colon Rectum*. 1990;33:508-510.
6. Higgins CC. Ureteral injuries during surgery: a review of 87 cases. *JAMA*. 1967;199:118-124.
7. Remington JH. Prevention of ureteral injuries in surgery of the pelvic colon. *Dis Colon Rectum*. 1959;2:340-349.
8. Woodland MB. Ureter injury during laparoscopy-assisted vaginal hysterectomy with the endoscopic linear stapler. *Am J Obstet Gynecol*. 1992;167:756-757.
9. Nezhat C, Nezhat F. Laparoscopic repair of ureter resected during operative laparoscopy. *Obstet Gynecol*. 1992;80:543-544.
10. Steckel J, Badillo F, Waldbaum RS. Uretero-fallopian tube fistula secondary to laparoscopic fulguration of pelvic endometriosis. *J Urol*. 1993;149:1128-1129.
11. Bothwell WN, Bleicher RJ, Dent TL. Prophylactic ureteral catheterization in colon surgery. A five-year review. *Dis Colon Rectum*. 1994;37:330-334.
12. Sirota JH, Narins L. Acute urinary suppression after ureteral catheterization: the pathogenesis of "reflux anuria." *N Engl J Med*. 1957;257:1111-1113.