

Isolated vertigo in a young male, HINTS examination and vertebral artery dissection in emergency department – A case report

Ankit Kumar Sahu, Prawal Shrimal, Meera Ekka, Amrithanand V T, Jamshed Nayer, Praveen Aggarwal

Department of Emergency Medicine, All India Institute of Medical Sciences, New Delhi, India

ABSTRACT

Vertigo is not an uncommon presenting symptom in patients presenting to the emergency department (ED) and primary physician's clinic, and around one-tenth of these patients have a central cause, i.e., posterior circulation stroke. HINTS, the acronym for head impulse (HI) test, nystagmus (N), and test of skew (TS), is a neurological examination utilized for differentiating a peripheral cause of vertigo from a sinister central cause. It is a simple, easy-to-do, inexpensive, and less time-consuming test. Here, we present a 27-year young male case without any known comorbidity or trauma, presented to the ED, with complaints of sudden onset isolated vertigo for 2 hours. HINTS examination pointed towards a central cause (normal head impulse test and direction-changing nystagmus). Other neurological and systemic examinations were normal. Non-contrast computed tomography of the brain was normal. Further, computed tomography angiography of head and neck vessels was performed, showing left vertebral artery dissection (VAD). The patient's neurological status deteriorated in the next 8 hours. The patient underwent decompressive craniotomy and got discharged after two weeks. Early performance of the HINTS examination by the primary care physicians and emergency physicians lead to early diagnosis and treatment of this common cause of posterior circulation stroke in young patients. Essential take-home points are the importance of the HINTS test and not to forget VAD as a cause of isolated vertigo without any neck manipulation or trauma.

Keywords: HINTS, vertebral artery dissection, vertigo

Introduction

Patients presenting to the emergency department (ED) and primary care physician's clinic with isolated vertigo (IV) is not uncommon. A first-contact physician (FCP) i.e., emergency physician or primary care physician, must differentiate vertigo's peripheral causes from central causes like posterior circulation strokes (PCS). Here, we present an illustrative case of acute

vertigo and the importance of a bedside clinical examination, i.e., HINTS test (head impulse, nystagmus, and test of skew) in diagnosing a central cause of vertigo.

Case Report

A 27-year young man, without any known comorbidity, presented to the ED with a history of acute onset vertigo for 2 hours. The primary survey was normal. There was no history of weakness in any limbs, facial deviation, symptoms of cranial nerve abnormalities, walking difficulty, fever, headache, vomiting, seizures, and trauma. Neurological examination was normal except direction-changing nystagmus. Other systemic examinations were unremarkable.

Address for correspondence: Dr. Meera Ekka,
Department of Emergency Medicine, All India Institute of Medical
Sciences, Ansari Nagar, Aurobindo Marg,
New Delhi - 110 029, India.
E-mail: drmeera_2004@yahoo.co.in

Received: 24-06-2021

Revised: 01-10-2021

Accepted: 16-10-2021

Published: 16-02-2022

Access this article online

Quick Response Code:



Website:
www.jfmpc.com

DOI:
10.4103/jfmpc.jfmpc_1248_21

This is an open access journal, and articles are distributed under the terms of the Creative Commons Attribution-NonCommercial-ShareAlike 4.0 License, which allows others to remix, tweak, and build upon the work non-commercially, as long as appropriate credit is given and the new creations are licensed under the identical terms.

For reprints contact: WKHLRPMedknow_reprints@wolterskluwer.com

How to cite this article: Sahu AK, Shrimal P, Ekka M, Amrithanand VT, Nayer J, Aggarwal P. Isolated vertigo in a young male, HINTS examination and vertebral artery dissection in emergency department – A case report. *J Family Med Prim Care* 2022;11:784-6.

Beside HINTS examination showed – head impulse was normal, i.e., absence of corrective saccades and direction-changing nystagmus was present. Blood sugar was normal. A non-contrast computed tomography (NCCT) of the brain was done, which was normal [Figure 1]. Computed tomography with angiography (CTA) revealed left vertebral artery dissection (VAD) [Figure 2]. The stroke team was activated immediately, and the patient was admitted to the stroke unit. Around 8 hours later, the patient's sensorium worsened. The patient underwent suboccipital decompressive craniotomy and discharged in E4-VT (tracheostomized)-M6 status after two weeks.

Discussion

Vertigo is responsible for approximately 3-5% of unselected presentations to emergency departments or outpatient clinics.^[1,2] In a large retrospective study, 6.4% of patients with acute vertigo had central vascular causes, including PCS.^[2] It was found that FCP missed up to 35% of strokes/transient ischemic attacks in patients who presented with IV.^[3] Most PCS patients usually present without any obvious sign of focal neurological deficits (FND), and relying on NCCT in these patients leads to false-negative results.^[4] Moreover, the imaging modality of choice for PCS diagnosis is magnetic resonance imaging (MRI) of the brain, which is not feasible in an acute care setting for the diagnosis and was found to be falsely negative in 12% of PCS if presented within 48-hours.^[5] Hence, the easy-to-do, inexpensive, faster bedside screening test like HINTS is crucial for an FCP.^[5]

The HINTS consists of head impulse test (HI), assessing nystagmus (N), and the test of skew (TS). The presence of positive HINTS test consists of the normal vestibulo-ocular reflex (normal HI), direction-changing nystagmus (abnormal N) and/or vertical ocular misalignment (abnormal TS) was 100% sensitive and 96% specific for stroke [Figure 3].^[5] A meta-analysis examined the accuracy of positive HINTS in identifying PCS in acute vertigo patients and found it to be 95.5% (95% CI: 92.6–98.4%) sensitive and 71.2% (95% CI: 67.0–75.4%) specific.^[6]

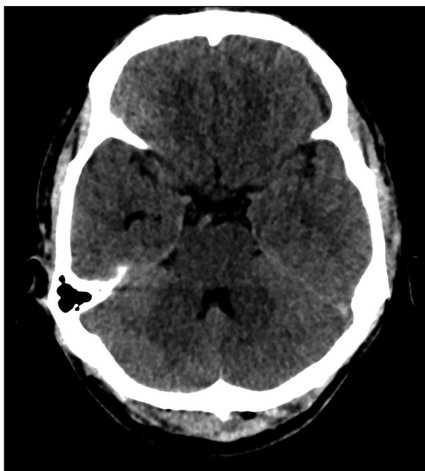

Figure 1: Normal appearance of an axial section of non-contrast computed tomography of the brain

This case was also illustrative of a young male presenting with IV, with HINTS positive in the ED, finally diagnosed as VAD. VAD is the most common cause of ischemic stroke in young and middle-aged patients.^[7,8] Frank presentations of stroke with FND are likely to initiate an emergency diagnostic workup in the ED. Still, patients with VAD may present with nonspecific complaints such as dizziness, neck pain, headaches, etc.^[9] In a meta-analysis of 1972 patients with VAD, the incidence of symptoms was vertigo (58%), followed by headache (51%) and then neck pain (46%).^[9] But, IV as the initial presentation in VAD is rare.^[10] Rane *et al.*^[11] described a case of a 24-year old female presenting as sudden onset vertigo after singing, finally diagnosed with VAD. Hence, an FCP needs to investigate a patient with IV. Risk factors like connective tissue disorder are present in fewer than 8% of patients, and fewer than half have apparent trauma.^[9] As VAD can have a varied presentation, bedside HINTS in patients with vertigo can aid in diagnosis. HINTS examination, which includes HI, might raise a concern of worsening the VAD, but researchers had found no relationship between VAD and HI.^[12] Hence, HINTS in any vertigo patients helps the FCP rule in or rule out the sinister central cause and appropriately initiate the time-sensitive management.

Conclusion

We have presented a case of a young male with isolated vertigo, where the importance of the bedside clinical examination – HINTS was performed, pointing towards a

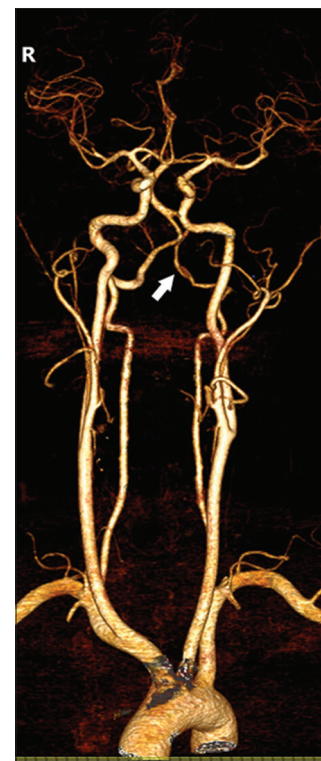

Figure 2: Reconstructed computed tomography with angiography (CTA) revealed dissection of the third and fourth segment of the left vertebral artery (white arrow)

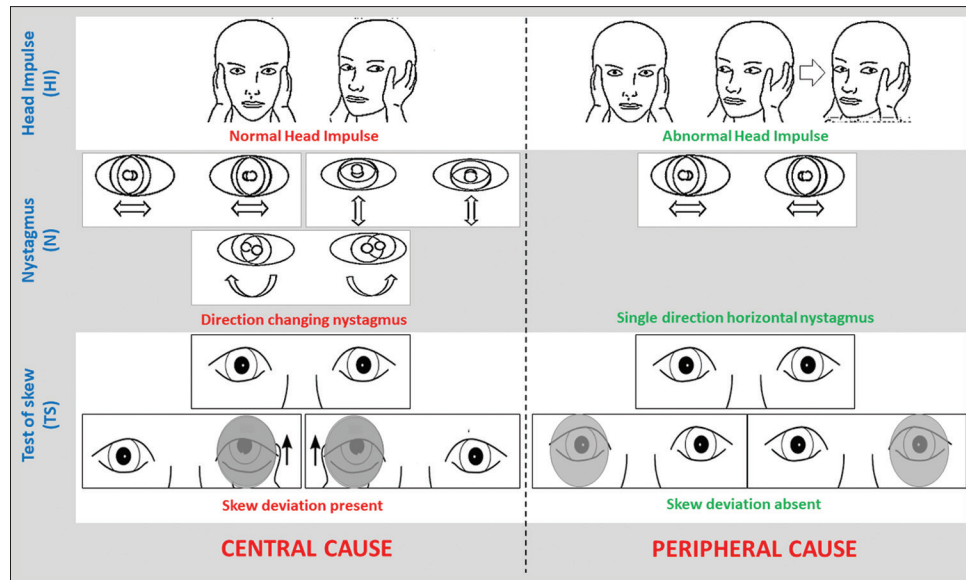


Figure 3: Performing the HINTS examination, HI - During the head impulse test (HI), the patient sits opposite the examiner and fixes their gaze on the examiner's nose. The examiner then moves the head in one direction, followed by a move to the center and another move in the opposite direction. The head turn should be rapid from an eccentric (lateral) position back to the center (midline) with an excursion angle of 10°. The examiner looks for any quick eye movement sign, a so-called corrective saccade. The absence of saccadic corrections points towards a central cause, whereas, on the contrary, the presence of saccades is suggestive of a peripheral cause. N - For testing nystagmus (N), the patient is asked to look to the left, right, and center position. The direction-changing nystagmus or vertical nystagmus is suggestive of central causes of vertigo, whereas, on the contrary, single directional horizontal nystagmus is suggestive of a peripheral cause. TS - In the test of skew (TS), the eyes of the patient are fixed on a distant target. The eyes of the patient are covered and uncovered in a slow alternating manner. A vertical skew deviation is seen in central causes of vertigo, whereas the absence of any skew deviation suggests a peripheral cause

sinister central cause of vertigo. Finally, vertebral artery dissection was diagnosed and managed. Essential learning points include the significance of HINTS in vertigo patients in the clinics and isolated vertigo as a presenting feature of vertebral artery dissection.

Acknowledgements

We thank the Department of Emergency Medicine for the support. We also thank our institution's professional English editing services for extending their help in correcting the manuscript in terms of language.

Financial support and sponsorship

Nil.

Conflicts of interest

There are no conflicts of interest.

References

- Newman-Toker DE, Hsieh Y-H, Camargo CA, Pelletier AJ, Butchy GT, Edlow JA. Spectrum of dizziness visits to us emergency departments: Cross-sectional analysis from a nationally representative sample. *Mayo Clin Proc* 2008;83:765-75.
- Kerber KA, Meurer WJ, West BT, Fendrick AM. Dizziness presentations in us emergency departments, 1995-2004. *Acad Emerg Med* 2008;15:744-50.
- Kerber KA, Brown DL, Lisabeth LD, Smith MA, Morgenstern LB. Stroke among patients with dizziness, vertigo, and imbalance in the emergency department: A population-based study. *Stroke* 2006;37:2484-7.
- Stanton VA, Hsieh Y-H, Camargo CA, Edlow JA, Lovett PB, Lovett P, et al. Overreliance on symptom quality in diagnosing dizziness: Results of a multicenter survey of emergency physicians. *Mayo Clin Proc* 2007;82:1319-28.
- Kattah JC, Talkad AV, Wang DZ, Hsieh YH, Newman-Toker DE. HINTS to diagnose stroke in the acute vestibular syndrome. *Stroke* 2009;40:3504-10.
- Krishnan K, Bassilious K, Eriksen E, Bath PM, Sprigg N, Brækken SK, et al. Posterior circulation stroke diagnosis using HINTS in patients presenting with acute vestibular syndrome: A systematic review. *Eur Stroke J* 2019;4:233-9.
- Malm J, Kristensen B, Carlberg B, Fagerlund M, Olsson T. Clinical features and prognosis in young adults with infratentorial infarcts. *Cerebrovasc Dis* 1999;9:282-9.
- Schievink WI. Spontaneous dissection of the carotid and vertebral arteries. *N Engl J Med* 2001;345:467-7.
- Gottesman RF, Sharma P, Robinson KA, Arnan M, Tsui M, Ladha K, et al. Clinical characteristics of symptomatic vertebral artery dissection. A systematic review. *Neurologist* 2012;18:245-54.
- Fukuhara K, Ogata T, Ouma S, Tsugawa J, Matsumoto J, Abe H, et al. Impact of initial symptom for accurate diagnosis of vertebral artery dissection. *Int J Stroke* 2015;10(Suppl A100):30-3.
- Rane NJ, McAuley D. Vertebral artery dissection presenting as isolated vertigo. *Emerg Med J* 2007;24:732-2.
- Kaski D, Bronstein AM. Making a diagnosis in patients who present with vertigo. *BMJ* 2012;345:e5809.