

Argyrophilic nuclear organizer region and p73 expression in head and neck squamous cell carcinomas: Teammates or adversaries?

Sunil Pazhayanur Venkateswaran, Leviana Ercylina Nathan¹, Vimi Sunil Mutalik², Noor Hasni Shamsuddin³

Department of Pathology, International Medical University, Kuala Lumpur, Malaysia, ¹Department of Medical Sciences, University of Queensland, Brisbane, Australia, ²Department of Oral and Maxillofacial Pathology and Radiology, The Ohio State University, Columbus, Ohio, United States of America, ³Department of Pathology, Hospital Tuanku Ja'afar, Seremban, Negeri Sembilan, Malaysia

Abstract

Context: Head and neck squamous cell carcinoma (HNSCC) consists of squamous cell carcinomas (SCCs) arising in the upper aerodigestive tract and accounts for 5% of cancers worldwide. In Malaysia, cancers of the nasopharynx, larynx, tongue and oral cavity are among the top twenty most common cancers in men. Argyrophilic nuclear organizer regions (AgNORs) are increased from normal mucosa to premalignant lesions to malignant lesions and have been associated with tumor grade and prognosis of patients. Although p73 is not mutated in human cancers, high levels of p73 expression have been associated with tumor differentiation status and patient prognosis.

Aims: To investigate the correlation between AgNORs and p73 immunoeexpression.

Settings and Design: Fifty-two formalin-fixed, paraffin-embedded HNSCC cases and ten controls were collected from the Hospital.

Subjects and Methods: Tissue blocks were sectioned, dewaxed and rehydrated before silver nitrate staining to determine the AgNOR count and immunohistochemical staining to determine the p73 expression. Adopting the scoring system used by Chen *et al.* for p73 staining, the proportion of positively stained cells in the whole epithelial layer was determined. Staining was considered positive if > 10% of epithelial cells were stained.

Statistical Analysis Used: Spearman's correlation coefficient was calculated using SPSS 18 software to determine the relationship between the p73 score against tumor differentiation, mean AgNOR counts and tumor grade and between the mean AgNOR count and p73 score.

Results: Positive results were found in the immunoeexpression of p73. Positive results were seen with the staining of AgNOR; however, in comparison with the entire sample size, a significant correlation between mean AgNOR count and p73 immunohistochemical expression was not obtained.

Conclusions: AgNOR count showed a linear and decreasing trend as the p73 score increases. This correlation was statistically insignificant.

Key Words: Argyrophilic nuclear organizer regions, p73 protein, head and neck squamous cell carcinoma

Address for correspondence:

Dr. Sunil Pazhayanur Venkateswaran, International Medical University, No. 126, Jalan Jalil Perkasa 19, Bukit Jalil, 57000 Kuala Lumpur, Malaysia.

E-mail: sunil_venkateswaran@imu.edu.my

Received: 20.06.2016, Accepted: 04.08.2016

Access this article online

Quick Response Code:



Website:

www.jomfp.in

DOI:

10.4103/0973-029X.190945

This is an open access article distributed under the terms of the Creative Commons Attribution-NonCommercial-ShareAlike 3.0 License, which allows others to remix, tweak, and build upon the work non-commercially, as long as the author is credited and the new creations are licensed under the identical terms.

For reprints contact: reprints@medknow.com

How to cite this article: Venkateswaran SP, Nathan LE, Mutalik VS, Shamsuddin NH. Argyrophilic nuclear organizer region and p73 expression in head and neck squamous cell carcinomas: Teammates or adversaries?. J Oral Maxillofac Pathol 2016;20:427-35.

INTRODUCTION

Head and neck squamous cell carcinomas (HNSCCs) are malignant epithelial neoplasms originating from the mucosal epithelium of the upper aerodigestive tract.^[1] HNSCC is of multifactorial etiology, and the most important risk factors are tobacco use, consumption of alcohol and human papillomavirus (HPV) infection.^[2] They account for more than 90% of oral malignancies that occur in the upper aerodigestive tract.^[3] Oral and pharyngeal cancer combined, is the sixth most common malignancy in the world, two-thirds of which occurs in the developing countries.^[4] In Malaysia, oral cancer was the 16th most common cancer for females and the 21st for males of the overall incidence per 1,000,000 population in the year 2002. In a report by the National Medical Registry in 2003, cancers of the nasopharynx, larynx, tongue and oral cavity accounted for the top twenty cancers among males in Malaysia.^[5]

Although the standard mode of diagnosis of cancer is based on routine hematoxylin and eosin staining, diagnosis is further confirmed by fine-needle aspiration of enlarged lymph nodes, if any present.^[6]

The accumulation of genetic and epigenetic alterations results in a multistep process which includes the activation of oncogenes and the inactivation of tumor suppressor genes, leading to the development of HNSCC, much like many other human cancers.^[7,8] Two genes homologous to the tumor suppressor gene p53 have been described, i.e. p73 and p63, which function in cell cycle arrest and cell death.

Tumor suppressor gene p53 acts as the “guardian of the genome” by arresting cell cycle and initiating apoptosis of cells with DNA damage through stimulation of the expression of downstream genes.^[9] It is the most commonly altered gene observed in human cancers, being detected in more than half of many types of cancers,^[10] and in 69% of HNSCCs.^[11] Two genes homologous to p53 have been described, i.e. p73 located at chromosome 1p36.33^[12] and p63 mapped to chromosome 3q27 ± 29.^[13] p63 and p73 share similar sequences with p53, notably in the regions corresponding to p53 central DNA-binding domain and C-terminal oligomerization domain.

It is important to note that in contrast to p53, p63 and p73 are not mutated in human cancers.^[14,15] However, ectopic expression of full-length (transactivation [TA]) isoforms of p73 and p63 can transactivate p53 target genes and indirectly induce growth arrest and/or cell death. In contrast to these TAp73 isoforms, ΔNp73 retain DNA-binding activity; but, fail to transactivate p53 reporter genes.^[11] In other words, TAp73 and ΔNp73 have antagonistic effects, with TAp73

having apoptotic properties and ΔNp73 having antiapoptotic properties. The p73 is associated with homeostasis and control of differentiation of head and neck squamous epithelium probably in concert with p53 and p63. Downregulation of p73 expression could participate in squamous epithelium of the head and neck (HNSE) carcinogenesis.^[16]

Nucleolar organizer regions (NORs) are loops of chromosomal DNA within the nucleolus of a cell which contain clusters of ribosomal RNA (rRNA). As the rate of protein synthesis is faster in rapidly proliferating cells than in slowly proliferating ones, there should be an increase in the nucleolar structures (argyrophilic nuclear organizer regions [AgNORs]) where rRNA production occurs. An increase in rRNA transcription occurs in the case of precancerous and cancerous lesions. AgNOR staining technique is a useful diagnostic tool since differences in AgNOR numeric values can be identified in the different types of HNSCC.^[17] Therefore, AgNORs have been suggested as a reliable marker to evaluate the cell proliferation rate in routinely processed histological samples.^[18]

The aim of this study was to find out whether there was an association between mean AgNOR counts and the immunohistochemical expression of p73 in HNSCC.

The objectives of the study were to:

- Determine the AgNOR counts and immunohistochemical expression of p73 in HNSCC
- Determine the association between mean AgNOR counts and the immunohistochemical expression of p73
- Compare the above results with demographic particulars (age, sex and gender) of the patients included in this study.

SUBJECTS AND METHODS

This retrospective study involved 52 formalin-fixed, paraffin-embedded tissue blocks of cases and controls, which were collected from January 2012 to June 2014 from the Department of Pathology, after obtaining appropriate ethical clearance from the Ethical Board of the institution.

Forty-six patients with primary/recurrent HNSCCs were included in the study. Six patients were excluded from the study as the paraffin blocks were of poor quality. The criteria for defining a malignancy were as follows: (i) The tumor must be clearly malignant by histopathologic examination, (ii) the tumor must be histopathologically graded and (iii) possibility of the tumor representing a metastasis must be excluded. Resection specimens were reexamined to confirm the diagnosis and assign a grade.

Ten controls from mucosal specimens of patients with benign oral mucosal lesions were also obtained for this study. Only patients with available formalin-fixed, paraffin-embedded tissue blocks were included in the study.

Tissue sectioning

The routinely processed formalin-fixed, paraffin-embedded tissue blocks were cut using a microtome with the clearance angle set at 5°. Parallel sections were cut at a thickness of 4 µm using a microtome blade (Leica). Two sections were cut from each block to be used in the two different staining procedures. Sections were floated out in a hot water bath at 50°C. Sections were then “fished” out using microscope slides and placed vertically on a slide rack. Slides were allowed to air-dry overnight at room temperature and then placed on a hot plate set at 60°C for about 1 h to melt away the wax. Slides were then deparaffinized and dehydrated before being subjected to their respective staining procedures.

Immunohistochemical staining of p73

Immunoperoxidase staining was done on formalin-fixed, paraffin-embedded, 4 µm tissue sections using the Dako REAL™ EnVision™/HRP, Rabbit Mouse ENV (DAKO Corp., Carpinteria, CA, USA) following the manufacturer's instructions. Antigen retrieval was done using a pressure declocking chamber for 25 min; a p73 monoclonal antibody (Rabbit Monoclonal [EP436Y] [ab40658] Antibody to p73; Abcam, USA) was used in a dilution of 1:200.

Slides of the cases were then analyzed by two authors of the study. Only nuclear positivity was assessed quantitatively as p73 is a nuclear protein; cells expressing only cytoplasmic staining were excluded. Only the proportion of cells demonstrating nuclear expression of p73 was quantified and not the associated intensity of immunohistochemical staining.^[19]

Adopting the scoring system used by Chen *et al.*,^[20] the proportion of positively stained cells in the whole layer of epithelium was determined by observing the entire section. The following scoring system was used:

- 3 - more than 25% of epithelial cells scoring positive
- 2-10–25% of epithelial cells scoring positive
- 1 - <10% of epithelial cells scoring positive
- 0 - no epithelial cells stained

Staining was considered positive if >10% of epithelial cells were stained, i.e. having a score of 2 or 3.

Silver nitrate staining of argyrophilic nuclear organizer regions

AgNOR staining was performed as described by Ploton *et al.*^[21] Several modifications, as described by Lindner,^[22] were made to

the procedure to enhance staining outcome. The modifications are as follows:

1. Reduction of sections with 1% dithiothreitol solution for 10–15 min reduced background staining by 10–15% without having any effect on the specific staining of the NORs. It also decreased the staining of cytoplasmic granules
2. Filtration of formic acid-gelatin solution. This step is to remove any excess gelatin and, in turn, reduce precipitation
3. Treatment of sections with 5% sodium thiosulfate for 5 min. Incubation time was reduced from 10 min to 5 min as prolongation of this step will eventually lead to the gradual removal of reduced silver.^[22]

Counting of argyrophilic nuclear organizer regions

In each case, the number of AgNORs present in each nuclei of the tumor cells was counted by two authors in 100 nuclei using a × 100 oil immersion lens of the light microscope. On each slide, within the same neoplastic area, both authors independently defined the mean AgNOR number by direct count at the microscope, and then the mean AgNOR count was obtained by averaging the AgNOR counts from each author. At x100 magnification, AgNORs were visible both within and outside the nuclei. Clusters of black dots within nucleoli were counted as a single AgNOR and dispersed dots throughout the nucleolus were counted as discrete AgNOR's. By focusing carefully, AgNOR dots were counted; both extranucleolar and intranucleolar dots were included in the counting regime. However, nuclei that overlapped or those with indiscernible AgNORs were excluded from the study.

The labeling in each case was even. In each case, the mean number of total AgNOR dots per case was calculated.^[23]

Statistical analysis

Spearman's correlation coefficient was calculated using SPSS 18 software (SPSS Inc. Released 2009. PASW Statistics for Windows, Version 18.0. Chicago: SPSS Inc) to determine the relationship between the p73 score against tumor differentiation, mean AgNOR counts and tumor grade and between the mean AgNOR count and p73 score.

RESULTS

Patient demographic data and pathological information

The demographic particulars of all 46 patients have been summarized according to the number and percentage as shown in Table 1.

Table 2 shows the number and percentage of tumors according to location and pathological differentiation.

Immunohistochemical staining of p73

In the normal HNSE, p73 staining was present in the basal and parabasal layers which contain more undifferentiated squamous cells. The more superficial layers of the epithelium which have more differentiated squamous cells did not take up the p73 stain [Figure 1]. In HNSCC cases, there was a varying degree of uptake between different tumor grades.

In well to moderately differentiated squamous cell carcinomas (SCCs), p73 uptake was observed in the foci of undifferentiated cells in the periphery of carcinomatous clusters. The central area of tumor islands containing more differentiated cells exhibits no p73 immunoreactivity as shown in Figure 2. In poorly differentiated and undifferentiated carcinomas, p73 immunoreactivity was homogenous. All tumor cells expressed p73 as shown in Figure 3.

Overall, of the 10 cases of well-differentiated SCC, 6 cases (40.0%) had a p73 score of 2 and four cases (50.0%) had a score of 3. Of the 17 cases of moderately differentiated SCC, 6 cases (35.3%) had a p73 score of 2 and ten cases (58.8%) had a p73 score of 3. Of 4 cases (75%) of poorly differentiated SCC, 3 cases had a score of 3. For each grade of differentiation, controls were run in parallel. Interestingly, 1 of the 15 cases of undifferentiated carcinoma was negative for p73 staining. Five cases (33.3%) had a p73 score of 2 and nine cases (60%) had a p73 score of 3 [Table 3].

Table 1: Patient demographic data

Gender	Number (Percentage)
Male	34 (73.9)
Female	12 (26.1)
Age	Number (Percentage)
Median (range)	63 years (35-89)
≥55	37 (80.4)
<55	9 (19.6)
Ethnicity	Number (Percentage)
Chinese	20 (43.5)
Malay	12 (26.1)
Indian	12 (26.1)
Orang Asli	2 (4.3)

Table 2: Tumor location and differentiation status of head and neck squamous cell carcinoma patients

Tumor sites in the head and neck	Number (Percentage)
Nasopharynx	19 (41.3)
Larynx	13 (28.3)
Hypopharynx	4 (8.7)
Oropharynx	4 (8.7)
Nasal cavity	4 (8.7)
Oral cavity	2 (4.3)
Pathological differentiation	Number (Percentage)
Well	10 (21.7)
Moderate	17 (37)
Poor	4 (8.7)
Undifferentiated	15 (32.6)

Spearman's correlation coefficient was calculated using SPSS 18 software to determine the relationship between p73 score against gender, age and tumor differentiation independently. *P* value was found to be >0.05. No statistical significance was found between p73 and tumor differentiation status [Table 4].

Silver nitrate staining of argyrophilic nuclear organizer region

The 46 sections that were successfully stained with AgNOR produced 42 slides viable for analysis [Figures 4-6]. Four slides were excluded from analysis due to sectioning artifacts as well as staining artifacts.

Mean argyrophilic nuclear organizer region counts

The mean AgNOR counts collected from the 42 samples ranged from 1.02 to 4.00. These AgNOR counts were then grouped according to tumor differentiation status. For each grade of tumor differentiation, a new mean was derived and standard deviations were recorded [Table 5].

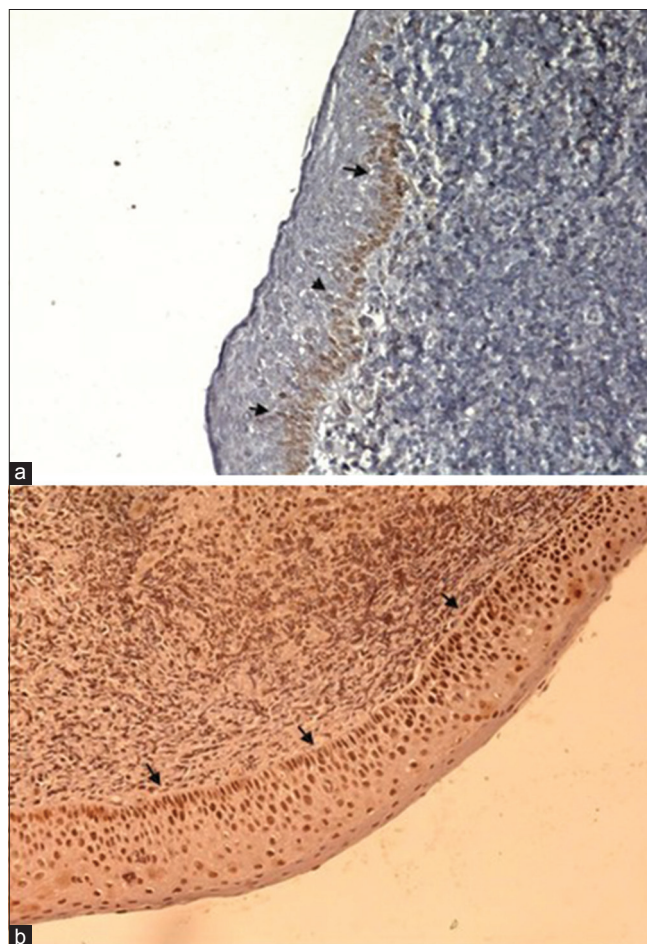


Figure 1: (a and b) Immunohistochemical staining of p73 in control cases. In normal mucosa of the nasopharynx, p73 showed positive staining in the basal and parabasal layer (arrowheads) [IHC stain, ×100]

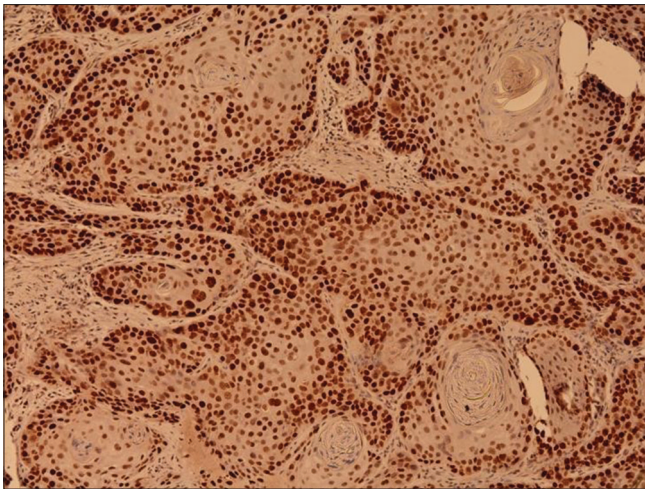


Figure 2: Moderately differentiated squamous cell carcinoma of the vocal cord showing tumor islands of varying sizes with keratin pearl formation. Note the p73 staining occurring only in the peripheries of tumor islands (IHC stain, x100)

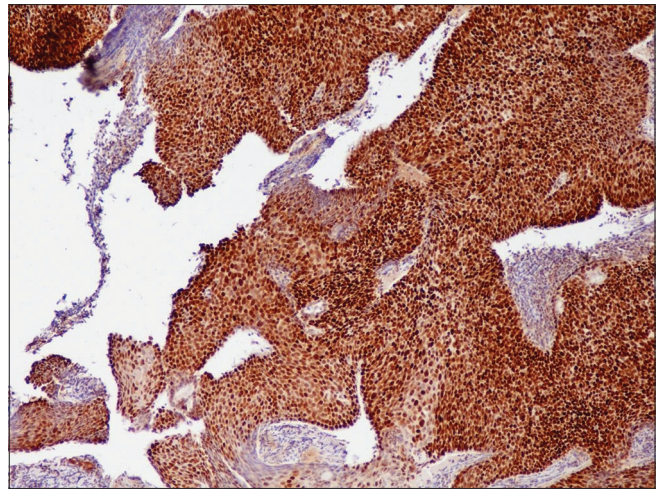


Figure 3: Poorly differentiated squamous cell carcinoma of the nasopharynx showing sheets of tumor tissue and homogenous uptake of p73 (IHC stain, x100)

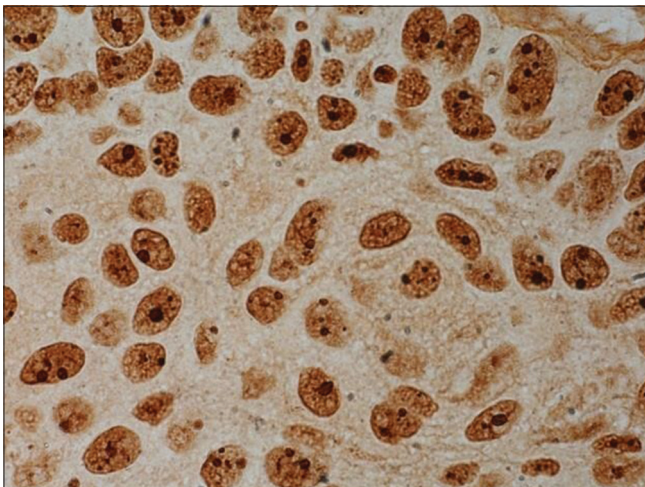


Figure 4: Well-differentiated squamous cell carcinoma of the vocal cord showing small amounts of argyrophillic nuclear organizer regions in each nucleoli (AGNOR Stain, x1000)

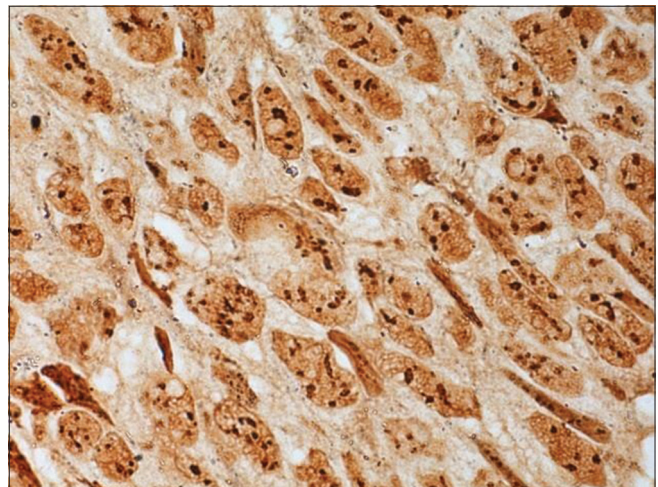


Figure 5: Argyrophillic nuclear organizer region dots in a moderately differentiated squamous cell carcinoma of the nasopharynx (AGNOR Stain, x1000)

Spearman's correlation coefficient was performed to determine the correlation between mean AgNOR counts and tumor grade. A negative correlation was found between mean AgNOR counts and tumor differentiation status, indicating that there was an overall decrease in mean AgNOR counts as the tumor grade progressed from well differentiated to undifferentiated. However, this correlation was not statistically significant as the *P* value was found to be >0.05 [Table 6].

Relationship between mean argyrophillic nuclear organizer region count and p73 expression

The total p73 scores and mean AgNOR counts were obtained from the study in relation to patients' demographic and pathological data [Table 7].

Statistical analysis was performed to determine the Spearman's correlation coefficient. *P* value was found to be >0.05 . No statistically significant correlation was found between mean AgNOR count and p73 score [Table 8].

DISCUSSION

The HNSE, showing basal layers containing stem cells and progenitors to gradually differentiated squamous cells, represents the paradigm of stratified epithelium which is consistently submitted to environmental genotoxic insults resulting from alcohol and tobacco consumption. In turn, this epithelium requires a perfect machinery to control and repair genotoxic damage and eliminate cells harboring mutations.^[16]

Table 3: Overall demographic and pathological data of head and neck squamous cell carcinoma patients against p73 score

Patient characteristics	p73 score (number of patients)			
	0	1	2	3
Gender				
Male	-	2	9	22
Female	-	2	6	4
Age				
<55	-	-	3	6
≥55	-	4	12	20
Ethnicity				
Malay	-	2	3	7
Chinese	-	1	8	10
Indian	-	1	3	8
Orang Asli	-	-	1	1
Tumor location				
Nasopharynx	-	3	7	9
Oropharynx	-	-	1	3
Hypopharynx	-	1	2	1
Larynx	-	-	2	11
Nasal cavity	-	-	2	1
Oral cavity	-	-	1	1
Pathological differentiation				
Well	-	1	4	5
Moderate	-	1	6	10
Poor	-	1	-	3
Undifferentiated	-	1	5	9

Table 4: Correlation between p73 and tumor differentiation

Category	Correlation coefficient	P
Tumor differentiation	0.109	0.483

Table 5: Tumor differentiation of head and neck squamous cell carcinoma patients against argyrophillic nuclear organizer regions counts

Patient characteristics	Mean AgNOR count
Pathological differentiation	
Well	2.44±1.04
Moderate	2.86±0.73
Poor	2.81±1.83
Undifferentiated	2.08±0.56

AgNOR: Argyrophillic nuclear organizer region

Table 6: Correlation between mean argyrophillic nuclear organizer regions counts and tumor differentiation

Category	Correlation coefficient	P
Tumor differentiation	-1.59	0.315

p73, first identified in 1997, shares a high level of homology in the DNA-binding domain with the p53 protein family.^[12] The p73 gene is located on chromosome 1p36.3 and expresses seven differentially spliced C-terminal isoforms, p73 α - η as well as at least four alternatively spliced N-terminal isoforms that contain different parts of the TA. The Δ TAp73 is the collective name for four different p73, isoforms lacking TA include Δ Np73, Δ N0p73, Δ e \times 2 p73 and Δ e \times 2/3 p73.^[12,14,24]

Laetitia et al. showed that immunohistochemical analyses performed on normal tissues (oral cavity, oropharynx,

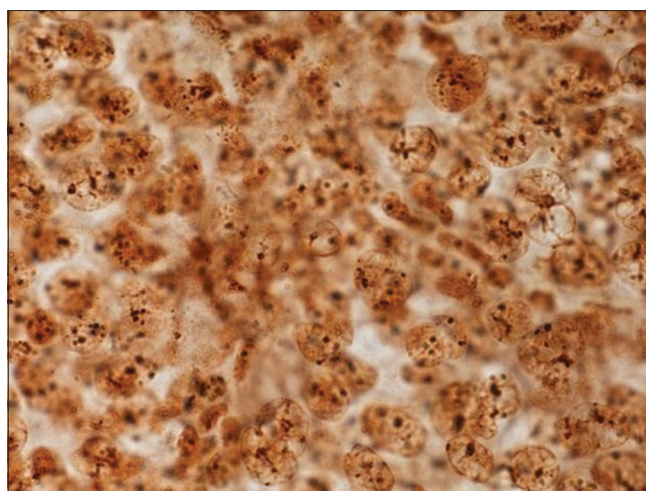


Figure 6: Argyrophillic nuclear organizer region dots of a poorly differentiated squamous cell carcinoma of the soft palate showing overlapping of cells (AGNOR Stain, \times 1000)

hypopharynx and larynx), in 21/21 HNSE (100%), p73 expression was restricted to undifferentiated cells situated in the basal layers of stratified HNSE. The immunostaining was uniformly distributed with a similar intensity in this cell compartment containing keratinocyte stem cells and progenitors, indicating protein expression in both proliferating and dormant cells. In contrast, differentiated cell layers did not show any p73 expression. Conversely, loss of p73 expression is associated with keratinocyte differentiation. Their study showed that P73 α immunostaining in 45 HNSCCs in various sites and presenting various histological types, including well and moderately differentiated tumors, was found to specifically label undifferentiated tumor cells with a similar intensity to that of matched normal HNSE tissue.^[16]

In our study, cells of the HNSE (basal and parabasal layers) took up the immunohistochemical staining, showing that the most undifferentiated areas in the epithelium expressed p73. The more superficial layers showed no staining at all, indicating that differentiated squamous cells in the normal epithelium do not take up p73. This is in line with previous literature that suggests that p73 expression is related to the level of differentiation in cells.^[16]

Most studies on the immunoexpression of p73 were conducted using antibodies to specific isomers of p73 such as p73 α , p73 β and Δ Np73. Chen et al. used a polyclonal antibody against p73 in their study. They used immunohistochemical techniques, in which nuclear staining of p73 protein was detected for a subset of hamster buccal-pouch tissue specimens treated with DMBA for 15 weeks. In their carcinoma samples, p73 immunoreactivity was chiefly observed for the less differentiated cells located at the periphery of carcinomatous clusters.^[25] A generic p73 antibody was used in this study; therefore, comparison with

Table 7: Patient demographic data, pathological data and p73 and argyrophillic nuclear organizer regions' scores

Patient number	Gender	Race	Age	Tumor location	Tumor grade*	p73 score	AgNOR count
1	Male	Chinese	57	Larynx	I	2	3.54
2	Male	Indian	41	Oropharynx	III	3	3.86
3	Male	Indian	60	Hypopharynx	IV	3	2.06
4	Female	Indian	79	Larynx	II	3	3.86
5	Male	Indian	63	Larynx	II	3	2.10
6	Male	Chinese	62	Larynx	II	3	1.82
7	Male	Indian	55	Oropharynx	II	3	1.78
8	Male	Malay	66	Larynx	I	3	2.64
9	Male	Indian	63	Larynx	II	3	ND
10	Female	Malay	39	Nasopharynx	IV	3	ND
11	Male	Chinese	72	Larynx	III	3	3.16
12	Male	Malay	50	Hypopharynx	II	2	3.28
13	Male	Chinese	51	Nasopharynx	II	3	2.72
14	Male	Chinese	74	Larynx	I	3	2.34
15	Female	Indian	62	Larynx	II	3	2.14
16	Male	Malay	57	Nasopharynx	II	1	3.88
17	Female	Indian	64	Oral cavity	I	2	2.30
18	Female	Malay	63	Oropharynx	III	3	3.22
19	Male	Chinese	55	Nasal cavity	I	ND	1.82
20	Male	Chinese	39	Nasopharynx	II	3	3.22
21	Male	Chinese	63	Nasopharynx	IV	3	1.96
22	Female	Chinese	76	Nasopharynx	IV	2	2.32
23	Male	Malay	73	Nasal cavity	I	2	4.00
24	Male	Chinese	63	Nasopharynx	IV	3	3.92
25	Female	Indian	45	Oropharynx	II	2	3.38
26	Female	Orang Asli	46	Nasopharynx	IV	2	2.02
27	Male	Chinese	65	Larynx	II	2	3.36
28	Female	Chinese	65	Nasal cavity	II	2	2.72
29	Female	Chinese	59	Nasopharynx	III	1	1.02
30	Male	Malay	56	Nasopharynx	IV	1	2.72
31	Male	Malay	74	Nasal cavity	IV	3	1.82
32	Male	Malay	35	Nasopharynx	IV	3	3.04
33	Male	Indian	63	Oral cavity	I	3	1.73
34	Male	Malay	37	Nasopharynx	IV	3	1.32
35	Male	Chinese	89	Larynx	I	3	1.02
36	Male	Indian	59	Hypopharynx	IV	2	1.96
37	Male	Orang Asli	57	Nasopharynx	IV	3	2.06
38	Male	Chinese	55	Nasopharynx	IV	3	1.84
39	Male	Chinese	56	Nasopharynx	II	2	ND
40	Female	Chinese	79	Nasopharynx	IV	2	1.30
41	Male	Malay	65	Nasopharynx	IV	2	2.96
42	Male	Chinese	64	Nasopharynx	I	2	2.54
43	Male	Chinese	74	Larynx	II	3	2.00
44	Female	Indian	74	Hypopharynx	I	1	ND
45	Male	Malay	67	Larynx	II	3	1.62
46	Male	Chinese	56	Nasopharynx	II	2	3.26

*Tumor grade according differentiation status as set by the AJCC; I: Well differentiated, II: Moderately differentiated, III: Moderately differentiated, IV: Undifferentiated, ND: No data, AJCC: American Joint Committee on Cancer, AgNOR: Argyrophillic nuclear organizer region

Table 8: Relationship between mean argyrophillic nuclear organizer regions count and p73 score

Variable	Spearman's correlation coefficient	P
Mean AgNOR count p73 score	-0.247	0.152

AgNOR: Argyrophillic nuclear organizer region

different studies was difficult, given the fact that $\Delta Np73$ has antagonistic effects on its counterpart TAp73.

Numerous papers on the diagnostic and prognostic applications of AgNORs in different types of benign, premalignant and malignant tumor tissue have been published in the past years. However, different methodological applications are adopted

by different pathologists due to lack of standardized staining and quantification methods. Hence, AgNOR scores for the same tumor type across different publications are hardly comparable.^[26]

Gupta *et al.* in their study on prostatic lesions found that the mean AgNOR counts in prostatic intraepithelial neoplasia was lower when compared with the prostate carcinoma cases. However, a statistical correlation could not be calculated because of the small number of cases.^[27] Chowdhry *et al.* in their study on the quantitative estimation of AgNORs in normal, dysplastic and malignant oral mucosa showed that in comparison to normal mucosa, a highly significant increase in

small, large and total AgNORs was seen in dysplastic lesions and SCCs. SCCs also showed a significantly higher frequency of AgNOR than dysplasia. Comparing large AgNORs in dysplastic lesions and SCCs, a nonsignificant increase in the mean values was noticed in SCCs. When mean values of total AgNORs were tallied between dysplastic lesions and SCCs, a highly significant increase was found in SCCs.^[28]

Chattopadhyay *et al.* investigated the AgNOR counts in the epithelia of oral mucosa, oral leukoplakia and oral SCC, and found that AgNOR counts in SCC were found to be significantly more than others. A statistically significant difference was found between normal epithelium and leukoplakia, between normal epithelium and SCC as well as between leukoplakia and SCC.^[29] In another study by Silva *et al.*,^[30] a direct association was found between the AgNOR count in oral SCC and the histological grade of tumors.

In a more recent study conducted by Khiavi *et al.*,^[31] a significant statistical difference was found between AgNOR counts in normal epithelium, precancerous lesions and SCC. It was concluded that AgNOR counts was useful in the differentiation of benign and malignant lesions of the oral mucosa. Compared to nucleolar NORs in SCC, the nucleolar NORs were lighter in normal and dysplastic epithelium. The AgNORs in SCCs were larger than those in precancerous lesions, and the AgNORs in precancerous lesions were larger than in the normal epithelium.

In our study, it was found that AgNOR dots appeared to be more uniform in well-differentiated SCCs and became more irregular in size and shape as tumor grade increased. This was concurrent to previous studies conducted by Khiavi *et al.* and Gulia *et al.*^[31,32]

The results for mean AgNOR counts were in discordance with previous literature whereby it has been determined that the mean AgNOR counts were supposed to be increased in higher grades of tumor as opposed to lower grades. Findings by Silva *et al.*, Moradzadeh Khiavi *et al.* and Xie *et al.*^[30,31,33] among many others have determined a direct association between AgNOR count and histopathological grade. In our study, however, the mean count appears to have minimal variation across tumor groups.

It is important to note that staining intensity was markedly affected by room temperature. A staining time of 45 min produced good staining intensity at room temperature of 20°C, but staining was too intense when room temperature increased to 25°C. Therefore, the suggestion by Lindner^[22] to reduce staining time by 2 min for every °C of increase in temperature is about optimum.

Treatment of slides with 1% dithiothreitol for 15 min before staining did not seem to reduce the background staining and staining of NOR-structures as reported by Lindner. This effect was not reproducible by our study.

Relationship between mean argyrophilic nuclear organizer region count and p73 score

Statistical analysis performed to investigate the correlation between mean AgNOR count and p73 score revealed a negative Spearman's correlation coefficient and $P > 0.05$ was found. Therefore, the correlation was statistically insignificant. This is attributed to the small sample size of the study. There were no other studies in literature comparing the relationship between mean AgNOR counts and p73 scores in HNSCC.

Limitations of the study

Our hospital is not a referral center for HNSCC cases; hence, there is limited availability of cases and small sample size in this study. There was also difficulty in retrieving data such as lymph node metastases, distant metastases and social history as this information is not routinely clerked into patient files, and hence this information was not included in our study.

We also do understand that nasopharyngeal carcinomas in this part of the world most likely are EBV-associated undifferentiated carcinomas, and oropharyngeal SCCs are frequently HPV associated. However, we did not perform EBV or HPV testing in our samples, in view of the limited financial budget for the study. This is a significant limitation of this study.

The use of a generic p73 antibody in this study recognizes several isoforms of p73. Hence, it was not possible to determine what isoform of p73 was taken up by the nucleoli of the tumor cells. The use of the p73 scoring system as described made it difficult to differentiate between higher levels of p73 expression.

Unavailability of an image analyzer for morphometric AgNOR count was another limitation of our study. The morphometric method, which consists of a CCD camera mounted on a light microscope and linked to a PC equipped with specific morphometric software is a more objective method and has shown to provide better reproducibility than the manual counting method.

CONCLUSIONS

AgNOR count showed a linear and decreasing trend as the p73 score increases. This correlation, however, is not statistically significant. The lack of a statistically significant correlation cannot exclude the association between p73 expression and

AgNOR counts. The lack of significance in our findings is likely due to the small sample size used.

Recommendations

We recommend future studies with a larger sample size to validate our findings. To the best of our knowledge, this is the first analysis of the relationship of the p73 protein to AgNOR counts in HNSCC.

Acknowledgment

I would like to thank Professor Michael Menke for helping us out with the statistical analysis and Dr. Ibtisam Mohammed, Head of Department of Pathology for providing the paraffin blocks for our study.

Financial support and sponsorship

International Medical University Joint Committee, Project ID number: BMS-I-01/2014 (05), Grant Amount: RM 20,000.

Conflicts of interest

There are no conflicts of interest.

REFERENCES

- Pilch BZ, Bouquet J, Thompson LD. Pathology and genetics of head and neck tumours. World Health Organization Classification of Tumours. Ch. 2. Lyon: IARC Press; 2005.
- Argiris A, Karamouzis MV, Raben D, Ferris RL. Head and neck cancer. *Lancet* 2008;371:1695-709.
- Warnakulasuriya S. Global epidemiology of oral and oropharyngeal cancer. *Oral Oncol* 2009;45:309-16.
- Ferlay J, Pisani P, Parkin DM. GLOBOCAN 2002. Cancer Incidence, Mortality and Prevalence Worldwide. IARC Cancer Base (2002 Estimates). Lyon: IARC Press; 2004.
- Lim GC, Rampai S, Yahaya H, editors. Cancer Incidence in Malaysia 2003. The Second Report of the National Cancer Registry of Malaysia, Ministry of Health Malaysia; 2008. p. 1-141.
- Sanderson RJ, Ironside JA. Squamous cell carcinomas of the head and neck. *BMJ* 2002;325:822-7.
- Liu X, Chen Z, Yu J, Xia J, Zhou X. MicroRNA profiling and head and neck cancer. *Comp Funct Genomics* 2009;2009:837514.
- Schaaij-Visser TB, Brakenhoff RH, Leemans CR, Heck AJ, Slijper M. Protein biomarker discovery for head and neck cancer. *J Proteomics* 2010;73:1790-803.
- Chien CY, Huang CC, Cheng JT, Chen CM, Hwang CF, Su CY. The clinicopathological significance of p53 and p21 expression in squamous cell carcinoma of hypopharyngeal cancer. *Cancer Lett* 2003;201:217-23.
- Harris CC, Hollstein M. Clinical implications of the p53 tumor-suppressor gene. *N Engl J Med* 1993;329:1318-27.
- Ahomadegbe JC, Barrois M, Fogel S, Le Bihan ML, Douc-Rasy S, Duvillard P, *et al.* High incidence of p53 alterations (mutation, deletion, overexpression) in head and neck primary tumors and metastases; absence of correlation with clinical outcome. Frequent protein overexpression in normal epithelium and in early non-invasive lesions. *Oncogene* 1995;10:1217-27.
- Kaghad M, Bonnet H, Yang A, Creancier L, Biscan JC, Valent A, *et al.* Monoallelically expressed gene related to p53 at 1p36, a region frequently deleted in neuroblastoma and other human cancers. *Cell* 1997;90:809-19.
- Yang A, Kaghad M, Wang Y, Gillett E, Fleming MD, Dötsch V, *et al.* p63, a p53 homolog at 3q27-29, encodes multiple products with transactivating, death-inducing, and dominant-negative activities. *Mol Cell* 1998;2:305-16.
- Melino G, De Laurenzi VD, Vousden KH. p73: Friend or foe in tumorigenesis. *Nat Rev Cancer* 2002;2:605-15.
- Osada M, Ohba M, Kawahara C, Ishioka C, Kanamaru R, Katoh I, *et al.* Cloning and functional analysis of human p51, which structurally and functionally resembles p53. *Nat Med* 1998;4:839-43.
- Faridoni-Laurens L, Bosq J, Janot F, Vayssade M, Le Bihan ML, Kaghad M, *et al.* P73 expression in basal layers of head and neck squamous epithelium: A role in differentiation and carcinogenesis in concert with p53 and p63? *Oncogene* 2001;20:5302-12.
- Hanemann JA, Miyazawa M, Souza MS. Histologic grading and nucleolar organizer regions in oral squamous cell carcinomas. *J Appl Oral Sci* 2011;19:280-5.
- Alaeddini M, Khalili M, Targari F, Etemad-Moghadam S. Argyrophilic proteins of nucleolar organizer regions (Ag-NORs) in salivary gland mucoepidermoid carcinoma and its relation to histological grade. *Oral Surg Oral Med Oral Pathol Oral Radiol Endod* 2008;6:758-62.
- Hall PA, Lane DP. p53 in tumour pathology: Can we trust immunohistochemistry? – Revisited! *J Pathol* 1994;172:1-4.
- Chen YK, Hsue SS, Lin LM. Immunohistochemical demonstration of p73 protein in the early stages of DMBA-induced squamous-cell carcinogenesis in hamster buccal pouch. *Arch Oral Biol* 2002;47:695-9.
- Ploton D, Menager M, Adnet JJ. Simultaneous high resolution localization of Ag-NOR proteins and nucleoproteins in interphasic and mitotic nuclei. *Histochem J* 1984;16:897-906.
- Lindner LE. Improvements in the silver-staining technique for nucleolar organizer regions (AgNOR). *J Histochem Cytochem* 1993;41:439-45.
- Elangovan T, Mani NJ, Malathi N. Argyrophilic nucleolar organizer regions in inflammatory, premalignant, and malignant oral lesions: A quantitative and qualitative assessment. *Indian J Dent Res* 2008;19:141-6.
- Müller M, Schleithoff ES, Stremmel W, Melino G, Krammer PH, Schilling T. One, two, three – p53, p63, p73 and chemosensitivity. *Drug Resist Updat* 2006;9:288-306.
- Chen YK, Hsue SS, Lin LM. Differential expression of p53, p63 and p73 protein and mRNA for DMBA-induced hamster buccal-pouch squamous-cell carcinomas. *Int J Exp Pathol* 2004;85:97-104.
- Trerè D. AgNOR staining and quantification. *Micron* 2000;31:127-31.
- Gupta V, Garg M, Chaudhry M, Singh S, Sen R, Gill M, *et al.* Role of cyclin D1 immunoreactivity and AgNOR staining in the evaluation of benign and malignant lesions of the prostate. *Prostate Int* 2014;2:90-6.
- Chowdhry A, Deshmukh RS, Shukla D, Bablani D, Mishra S. Quantitative estimation of AgNORs in normal, dysplastic and malignant oral mucosa. *Biomed Pap Med Fac Univ Palacky Olomouc Czech Repub* 2014;158:282-7.
- Chattopadhyay A, Chawda JG, Doshi JJ. Silver-binding nucleolar organizing regions: A study of oral leukoplakia and squamous cell carcinoma. *Int J Oral Maxillofac Surg* 1994;23 (6 Pt 1):374-7.
- Silva SO, Pretto GK, de Carli JP, Couto Souza PH, Busin CS. Evaluation of proliferative activity in oral squamous cell carcinoma by the AgNOR staining method. *Odonto* 2011;19:115-21.
- Moradzadeh Khiavi M, Vosoughhosseini S, Halimi M, Mahmoudi SM, Yarahmadi A. Nucleolar organizer regions in oral squamous cell carcinoma. *J Dent Res Dent Clin Dent Prospects* 2012;6:17-20.
- Gulia SP, Sitaramam E, Reddy KP. The role of silver staining nucleolar organiser regions (AgNORs) in lesions of the oral cavity. *J Clin Diagn Res* 2011;5:1011-5.
- Xie X, Clausen OP, Sudbø J, Boysen M. Diagnostic and prognostic value of nucleolar organizer regions in normal epithelium, dysplasia, and squamous cell carcinoma of the oral cavity. *Cancer* 1997;79:2200-8.