

## *Streptobacillus moniliformis* Bacteremia in a Pet Shop Employee: Case Report and Literature Review

Kiyozumi Suzuki,<sup>1</sup> Yuji Hirai,<sup>1</sup> Fujiko Morita,<sup>1</sup> Ayako Nakamura,<sup>2</sup> Yuki Uehara,<sup>1,3</sup> and Toshio Naito<sup>1,3</sup>

<sup>1</sup>Department of General Medicine, Juntendo University Faculty of Medicine, <sup>2</sup>Department of Clinical Laboratory, Juntendo University Hospital, and <sup>3</sup>Department of Infection Control Science, Juntendo University Graduate School of Medicine, Tokyo, Japan

A 39-year-old pet shop employee who sustained a bite from one of his store's rats developed fever and arthritis. *Streptobacillus moniliformis* was cultured from the patient's blood, confirming a diagnosis of rat-bite fever. Treatment with standard antibiotics was successful. Although rat-bite fever is commonly considered a zoonosis transmitted by wild or laboratory rats, our case emphasizes that it may be transmitted by pet animals as well.

**Keywords.** arthritis; outpatient parenteral antimicrobial therapy; pet shop employee; rat-bite fever; *Streptobacillus moniliformis*.

Rat-bite fever is a rare zoonosis characterized by fever, rash, and polyarthralgia that can cause serious complications [1, 2]. The illness is classically seen (1) in impoverished persons who live in rat-infested quarters or (2) in laboratory technicians who work with rats. However, rats are becoming increasingly popular as pets, and both sellers and purchasers of pet rats may be at unappreciated risk for this disease.

### CASE REPORT

A 39-year-old previously healthy male Japanese pet shop employee was referred to our hospital with a 5-day history of fever and headache. He also had pain and stiffness in his right elbow. He was bitten on his right thumb by a dumbo rat (variation of *Rattus norvegicus*) at the pet shop 7 days before the onset of symptoms. He did not wear gloves when handling pets and cleaning cages and was frequently bitten and scratched.

On examination, the patient's temperature was 37.8°C. There was a scar on his right thumb from the rat bite (Figure 1A). His right elbow was tender and swollen with decreased range of motion (Figure 1B). He had painful right axillary lymphadenopathy. Magnetic resonance imaging of the right elbow was consistent with arthritis (Figure 1C). There was insufficient synovial fluid to provide a sample. After samples had been obtained for blood culture, empirical outpatient treatment was initiated with ceftriaxone (2 g/day) and oral doxycycline (200 mg/day) for strongly suspected rat-bite fever, and he was intramuscularly administered tetanus toxoid injection.

On the next day, Gram-negative bacilli grew in an anaerobic blood culture bottle after 23 hours of incubation (Figure 1D). The organism was subcultured on 5% sheep blood agar (Nissui) incubated with 10% CO<sub>2</sub> at 35°C, and small, gray-white colonies grew after 3 days. The organism was identified as *Streptobacillus moniliformis* by matrix-assisted laser desorption ionization time-of-flight mass spectrometry using the Biotyper version 3.1 with a score of 2.050. The patient was afebrile within a few days, and his arthritis gradually improved. On the 8th day, echocardiography revealed no findings suggestive of endocarditis, and repeat blood cultures showed no microorganisms. The disc diffusion susceptibility test for *S moniliformis* revealed susceptibility to ampicillin, ceftazolin, cefotaxime, imipenem, and minocycline, based on the cut-off value of *Enterobacteriaceae* shown on the Performance Standards for Antimicrobial Susceptibility Testing M100-S24, issued by Clinical and Laboratory Standards Institute (CLSI) in 2014. Doxycycline was stopped, and ceftriaxone was continued for 2 weeks followed by oral amoxicillin (1500 mg/day) for 2 weeks, and the patient completely recovered.

### DISCUSSION

Rat-bite fever is caused by *S moniliformis* or *Spirillum minus*. *Streptobacillus moniliformis* is more common in North America, whereas *S minus* infection, called *Sodoku* in Japanese, is more common in Asia [1]. These organisms have colonized the nasopharynx in 50%–100% of wild rats and 10%–100% of healthy laboratory rats [3, 4]. They are typically transmitted via bites or scratches, although transmission via contact with other rodents, dogs, and cats have also been reported [1, 2]. Reports of transmission in the absence of known bites or scratches are increasing [2, 5]. Typical nontraumatic exposure is via contact with rat saliva, urine, or feces [1].

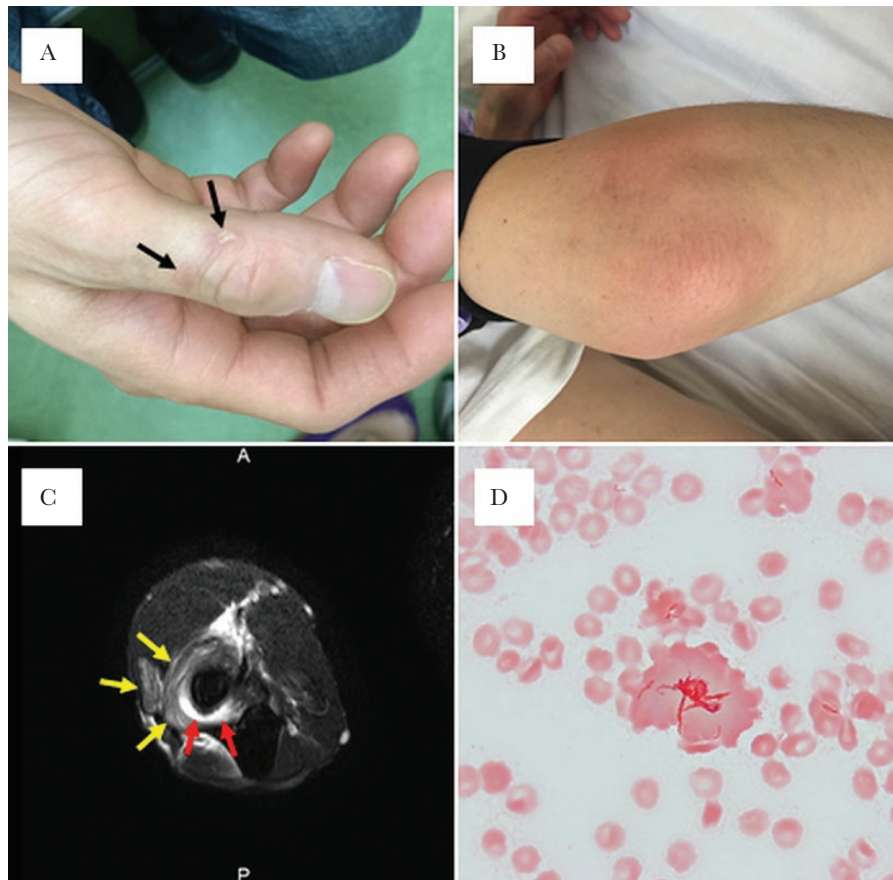
The outcome of rat-bite fever is favorable in treated cases; however, serious complications have been reported [1]. Endocarditis is the most severe complication, with a mortality

Received 29 November 2016; editorial decision 27 February 2017; accepted 28 February 2017.

Correspondence: K. Suzuki, MD, Department of General Medicine, Juntendo University Faculty of Medicine, 2-1-1, Hongo, Bunkyo-ku, Tokyo, 113-8421 Japan (ki-suzuki@juntendo.ac.jp).

Open Forum Infectious Diseases®

© The Author 2017. Published by Oxford University Press on behalf of Infectious Diseases Society of America. This is an Open Access article distributed under the terms of the Creative Commons Attribution-NonCommercial-NoDerivs licence (<http://creativecommons.org/licenses/by-nc-nd/4.0/>), which permits non-commercial reproduction and distribution of the work, in any medium, provided the original work is not altered or transformed in any way, and that the work is properly cited. For commercial re-use, please contact journals.permissions@oup.com. DOI: 10.1093/ofid/ofx038



**Figure 1.** (A) Rat-bite scar (arrows) on the right thumb 19 days after the bite. (B) Swelling and redness in the right elbow. (C) T2-weighted, fat-saturated magnetic resonance imaging showing increasing effusion (red arrows) within the right elbow joint and high intensity of the surrounding soft tissues (yellow arrows) without osteomyelitis. (D) Gram staining from an anaerobic blood culture bottle (BD Bactec 22F) showing pleomorphic filamentous Gram-negative bacilli (magnification,  $\times 1000$ ).

rate of 53% [6]. The treatment of rat-bite fever is intravenous penicillin G for 10–14 days in uncomplicated cases [1, 7, 8] and for 4 weeks in complicated cases [1, 6]. Ceftriaxone is also

successfully used [9–11]. Our patient was successfully treated with outpatient parenteral antimicrobial therapy (OPAT) for *S moniliformis* bacteremia with monoarthritis.

**Table 1. Review of Cases of Rat-Bite Fever in Pet Shop Employees**

Ref.	Age/Sex	Rat Exposure	Underlying Condition	Visiting Time From Onset	Clinical Features	Complications	Blood Cultures	Identification Method	Antimicrobial Treatment	Treatment Duration	Outcome
Present case	39/M	Bite, scratch	None	5 days	Fever, headache, arthralgia, axillary lymphadenopathy	Arthritis	Positive	MALDI-TOF	Ceftriaxone + oral doxycycline; oral amoxicillin	28 days	Cured
[5]	24/M	Scratched by cage	None	9–10 days	Fever, malaise, bodyache, arthralgia, dyspnea, vomiting	Endocarditis, myocardial abscess	Positive	NR	Ampicillin/sulbactam; ceftriaxone; various	45 days	Died
[8]	52/F	Bite	None	2 days	Headache, abdominal pain, diarrhea, lethargy, axillary lymphadenopathy, myalgia, arthralgia	Hypotension, thrombocytopenia, multiple organ failure	Positive	16S rRNA	Ciprofloxacin + metronidazole + vancomycin	12 hours	Died
[15]	60/F	Bite	Breast cancer	21 days	Fever, polyarthralgia	Arthritis	Negative	16S rRNA	Penicillin; oral rifampicin + clindamycin	28 days	Cured

Abbreviations: F, female; M, male; MALDI-TOF, matrix-assisted laser desorption ionization time-of-flight; NR, not reported; rRNA, ribosomal ribonucleic acid.

Historically, rat-bite fever has been reported among laboratory workers and the poor [1, 12]. With the increasing popularity of pet rats, children, pet owners, and pet shop employees are at an increased risk of contracting the infection [1, 2, 13]. Although zoonoses related to pet shops have been reported, pet shop employees have no adequate understanding of the risks and do not take precautions against them [14]. Our patient had been handling rats, flying squirrels, and rabbits with his bare hands. Three other cases of rat-bite fever in pet shop employees have been reported (Table 1). The patients sought medical care 2–21 days after the onset of symptoms. Two patients, who had been previously healthy, died of the infection. The risk of rat-bite fever after a rat bite is approximately 10% [1]. Animal bites are a common problem worldwide, and many cases of rat-bite fever may have been underdiagnosed. The Centers for Disease Control and Prevention (CDC) recommends preventive measures, such as wearing protective gloves, washing hands, and avoiding hand-to-mouth contact after handling rodents or cleaning cages [8]. Pet shop employees should prevent rodent-borne zoonoses and wound infections [3, 7].

## CONCLUSIONS

To the best of our knowledge, our patient is the first pet shop employee with *S moniliformis* bacteremia with monoarthritis who was successfully treated with OPAT. Pet shop employees should recognize pet-associated zoonotic risks and take preventive measures to reduce risks to themselves and

prospective pet owners. Pet shop-associated zoonoses should be recognized as an emerging disease.

## Acknowledgments

**Potential conflicts of interest.** All authors: No reported conflicts. All authors have submitted the ICMJE Form for Disclosure of Potential Conflicts of Interest. Conflicts that the editors consider relevant to the content of the manuscript have been disclosed.

## References

1. Elliott SP. Rat bite fever and *Streptobacillus moniliformis*. Clin Microbiol Rev 2007; 20:13–22.
2. Graves MH, Janda JM. Rat-bite fever (*Streptobacillus moniliformis*): a potential emerging disease. Int J Infect Dis 2001; 5:151–5.
3. Centers for Disease Control and Prevention (CDC). Rat-bite fever - New Mexico, 1996. MMWR Morb Mortal Wkly Rep 1998; 47:89–91.
4. Anderson LC, Leary SL, Manning PJ. Rat-bite fever in animal research laboratory personnel. Lab Anim Sci 1983; 33:292–4.
5. Shvartsblat S, Kochie M, Harber P, Howard J. Fatal rat bite fever in a pet shop employee. Am J Ind Med 2004; 45:357–60.
6. Rupp ME. *Streptobacillus moniliformis* endocarditis: case report and review. Clin Infect Dis 1992; 14:769–72.
7. Wang TK, Wong SS. *Streptobacillus moniliformis* septic arthritis: a clinical entity distinct from rat-bite fever? BMC Infect Dis 2007; 7:56.
8. Centers for Disease Control and Prevention (CDC). Fatal rat-bite fever - Florida and Washington, 2003. MMWR Morb Mortal Wkly Rep 2005; 53:1198–202.
9. Brown CM, Tsai G, Sanchez-Flores X. Oh rats! Fever, rash and arthritis in a young woman. BMJ Case Rep 2015; pii: bcr2015212240.
10. Cunningham BB, Paller AS, Katz BZ. Rat bite fever in a pet lover. J Am Acad Dermatol 1998; 38:330–2.
11. Sato R, Kuriyama A, Nasu M. Rat-bite fever complicated by vertebral osteomyelitis: a case report. J Infect Chemother 2016; 22:574–6.
12. Flannery DD, Akinboyo I, Ty JM, et al. Septic arthritis and concern for osteomyelitis in a child with rat bite fever. J Clin Microbiol 2013; 51:1987–9.
13. Khatchadourian K, Ovetchkine P, Minodier P, et al. The rise of the rats: a growing paediatric issue. Paediatr Child Health 2010; 15:131–4.
14. Halsby KD, Walsh AL, Campbell C, et al. Healthy animals, healthy people: zoonosis risk from animal contact in pet shops, a systematic review of the literature. PLoS One 2014; 9:e89309.
15. Legout L, Senneville E, Mulleman D, et al. Rat bite fever mimicking rheumatoid arthritis. Scand J Infect Dis 2005; 37:532–3.