

Letter to the Editor

A rare case of hyperprogression of nonsmall cell lung cancer in a patient on atezolizumab therapy

DOI: 10.4103/sajc.sajc_166_19

A 55-year-old Hispanic male with a history of hypertension presented with a 4-month history of dry cough along with mild chest pain in 2017 July when computed tomographic (CT) scan revealed right upper lobe (UL) mass with mediastinal adenopathy and innumerable pulmonary nodules. Scans also revealed evidence of superior venacaval syndrome and no evidence of metastasis outside the thorax. The patient had bronchoscopy and biopsy which revealed squamous cell carcinoma. He was treated with chemotherapy (carboplatin and paclitaxel) with radiation followed by consolidation chemotherapy with two cycles of (carboplatin and paclitaxel) with improvement in symptoms. The patient had a subsequent CT scan few weeks after therapy which showed the resolution of pulmonary nodules and significant decrease in size of right UL mass. He was subsequently observed off therapy for 6 months when a repeat

CT scan showed multiple lung nodules and mediastinal lymph node consistent with the recurrence of lung cancer [Figure 1].

The patient was started on atezolizumab, a PDL1 inhibitor approved for the second-line treatment of non-small cell lung cancer (NSCLC), with the development of severe left facial pain 1 week following the first dose of immunotherapy. The patient also had new-onset shortness of breath and hoarseness of voice following the first cycle of immunotherapy requiring hospitalization and high dose of opioids. A repeat CT scan was done when which showed significant worsening of lung metastasis with increasing size of old lesions along with the appearance of new lung metastasis [Figure 2]. The patient was found to have left vocal cord paralysis due to tumor infiltration of recurrent laryngeal nerve based on CT scan of the neck. Considering the drastic worsening of the disease based on the clinical course and radiological findings following immunotherapy, this was deemed as hyperprogression. Immunotherapy was subsequently discontinued and switched back to single-agent nab-paclitaxel, and the patient had significant symptomatic improvement after two cycles of chemotherapy. His shortness

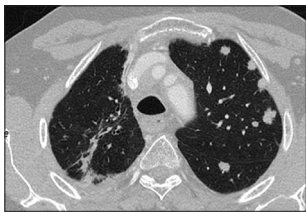


Figure 1: Computed tomography scan before immunotherapy

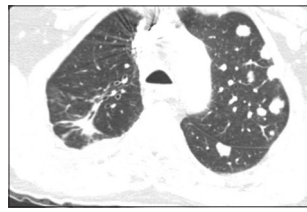

Figure 2: Computed tomography scan after immunotherapy

of breath and left facial pain improved dramatically however vocal cord paralysis persisted. A subsequent positron-emission tomography–CT scan done 8 weeks later showed a mixed response to the therapy.

Immunotherapy has led to a paradigm shift in cancer therapy with a proportion of patients developing drastic and prolonged tumor response; however, tumor flare ups have been anecdotally described since the beginning days of immunotherapy. This was systematically studied first in an article by Champiat *et al.* who reported around 9% incidence of hyperprogression across various tumors in patients treated with PD1 and PDL1 inhibitors.^[1] In their study, hyperprogressive disease (HPD) was defined as a RECIST progression at the first evaluation and as a >2-fold increase of the tumor growth rate between the reference and the treatment periods. It was observed that HPD had no relationship with tumor type or tumor burden and patients with HPD had shorter overall survival (OS). Interestingly, tumor growth rate preimmunotherapy was inversely related to response to immunotherapy and no patients treated with lung cancer had HPD in their study.

A study by Saâda-Bouzid *et al.* examined the same issue specifically in head-and-neck cancer patients. Here, patients treated with nivolumab and pembrolizumab (both PD1 inhibitors) were found to have 29% rate of hyper progression.^[2] HPD was defined as Tumor Growth Rate constant (TGRk) >2 based on the graph of tumor growth rate. Again, it was observed that HPD is associated with shorter progression-free survival and OS. Atypical pattern of immune response in urothelial and renal cell cancer was investigated in a metaanalysis which observed hyperprogression in a substantial number of patients with bladder cancer and one patient with RCC.^[3,4]

Hyperprogression has been reported in NSCLC treated with immunotherapy. There are two case reports of “tumor flare up” which is consistent with hyperprogressive disease in patients treated with nivolumab.^[5,6] Ferrara *et al.* did a retrospective study of 242 patients treated with various immunotherapies and found 16% hyper progression in NSCLC cases treated with immuno-oncologics (IOs).^[7] There were no predictors of HPD in their study, including PDL1 level or tumor mutational burden. Similar to the previous studies, people with HPD were observed to have a shorter OS.

A single-institution study of hyperprogressors (five patients) observed two patients with MDM2/MDM4 amplification, 1 with epidermal growth factor receptor mutation and 1 with mutation in 11q13; all of them were treated with nivolumab or pembrolizumab.^[8]

The genomic profile of cancer patients with HPD was examined by Kato *et al.* in a larger retrospective study.^[9] Consecutive Stage IV cancer patients who received immunotherapies

(CTLA-4, PD1/PD-L1 inhibitors, or other [investigational] agents) had their tumor evaluated by next-generation sequencing were analyzed in the study. Definition of hyperprogression as per Kato *et al.* was

1. Time-to-treatment failure of <2 months
2. Greater than 50% increase in tumor burden compared with preimmunotherapy imaging
3. Greater than or equal to a two-fold increase in progression pace.

The present study found that MDM2/MDM4 amplification and EGFR mutations had a poor outcome and increased tumor growth meeting criteria for hyperprogression when treated with IOs.

The mechanism of hyperprogression is poorly understood with explanations ranging from oncogenic signaling activation to tumor microenvironment changes secondary to IOs. A similar entity called pseudoprogression has been described with IOs where a tumor progression based on RECIST criteria might be seen. Here, the patient is clinically stable or better however is “radiologically worse.” This is well described in melanoma treated with PDL1/PD1 blockers and CTLA4 antagonists and occasionally in other malignancies. These patients can be continued to be treated with immunotherapy with response as efficacious as seen in patients without this radiological phenomenon. The distinction between pseudoprogression, hyperprogression, and natural progression of the disease is important and essentially depends on the change in tempo of the disease and clinical status.

Clinicians should be aware of hyperprogression of malignancies with treatment which are likely to be seen more with the increasing use of IOs. There is a suggestion that age and certain mutations such as MDM2 family and EGFR mutations might predict hyperprogression with immunotherapies. Much has to be studied about hyperprogression and its pathogenesis, but in the light of increasing use of immunotherapy, it is reasonable to assume that more cases are likely to be encountered in the clinical practice.

Declaration of patient consent

The authors certify that they have obtained all appropriate patient consent forms. In the form the patient(s) has/have given his/her/their consent for his/her/their images and other clinical information to be reported in the journal. The patients understand that their names and initials will not be published and due efforts will be made to conceal their identity, but anonymity cannot be guaranteed.

Financial support and sponsorship

Nil.

Conflicts of interest

There are no conflicts of interest.

Sudarsan Vishnu Kollimuttathuillam, Supreet Kaur, Hamid Shaaban, Gunwant Guron

Department of Medical Oncology, St Michael's Medical Center, Newark, NJ, an Affiliate of New York Medical College, Westchester, NY

Correspondence to: Dr. Hamid Shaaban, E-mail: hamidshaaban@gmail.com

References

1. Champiat S, Derclé L, Ammari S, Massard C, Hollebecque A, Postel-Vinay S, *et al.* Hyperprogressive disease is a new pattern of progression in cancer patients treated by anti-PD-1/PD-L1. *Clin Cancer Res* 2017;23:1920-8.
2. Saâda-Bouziid E, Defaucheux C, Karabajakian A, Coloma VP, Servois V, Paoletti X, *et al.* Hyperprogression during anti-PD-1/PD-L1 therapy in patients with recurrent and/or metastatic head and neck squamous cell carcinoma. *Ann Oncol* 2017;28:1605-11.
3. Soria F, Beleni AI, D'Andrea D, Resch I, Gust KM, Gontero P, *et al.* Pseudoprogression and hyperprogression during immune checkpoint inhibitor therapy for urothelial and kidney cancer. *World J Urol* 2018;36:1703-9.
4. Salhan D, Verma P, Basunia M. Unusual presentation of clostridium difficile: Hepatic portal venous gas and gastric emphysema. *Chest* 2016;150:264A.
5. Yoshida T, Furuta H, Hida T. Risk of tumor flare after nivolumab treatment in patients with irradiated field recurrence. *Med Oncol* 2017;34:34.
6. Chubachi S, Yasuda H, Irie H, Fukunaga K, Naoki K, Soejima K, *et al.* A case of non-small cell lung cancer with possible “disease flare” on nivolumab treatment. *Case reports in oncological medicine*. 2016;2016.
7. Ferrara R, Caramella C, Texier M, Audigier Valette C, Tessonnier L, Mezquita L, *et al.* 1306PDHyperprogressive disease (HPD) is frequent in non-small cell lung cancer (NSCLC) patients (pts) treated with anti PD1/PD-L1 monoclonal antibodies (IO). *Ann Oncol* 2017;28(suppl_5).
8. Singavi AK, Menon S, Kilari D, Alqwasmi A, Ritch PS, Thomas JP, *et al.* George B. 1140PDPredictive biomarkers for hyper-progression (HP) in response to immune checkpoint inhibitors (ICI)-analysis of somatic alterations (SAs). *Ann Oncol* 2017;28(suppl_5).
9. Kato S, Goodman A, Walavalkar V, Barkauskas DA, Sharabi A, Kurzrock R. Hyperprogressors after immunotherapy: Analysis of genomic alterations associated with accelerated growth rate. *Clin Cancer Res* 2017;23:4242-50.

This is an open access journal, and articles are distributed under the terms of the Creative Commons Attribution-NonCommercial-ShareAlike 4.0 License, which allows others to remix, tweak, and build upon the work non-commercially, as long as appropriate credit is given and the new creations are licensed under the identical terms.

For reprints contact: reprints@medknow.com

How to cite this article: Kollimuttathuillam SV, Kaur S, Shaaban H, Guron G. A rare case of hyperprogression of nonsmall cell lung cancer in a patient on atezolizumab therapy. *South Asian J Cancer* 2020;9:22.

© 2019 The South Asian Journal of Cancer | Published by Wolters Kluwer - Medknow