

Received: 2020.08.16

Accepted: 2020.11.05

Available online: 2020.12.07

Published: 2021.01.21

A 61-Year-Old Woman with Chronic Iron-Deficiency Anemia Due to a Cameron Lesion and a Response to Oral Application of Combined Poloxamer 407 with Hyaluronic Acid and Chondroitin Sulfate Following Single Treatment with Pantoprazole: A Case Report

Authors' Contribution:

Study Design A
Data Collection B
Statistical Analysis C
Data Interpretation D
Manuscript Preparation E
Literature Search F
Funds Collection G

D 1 Iliyan Emilov Iliev

B 2 Almute Loidl

1 Department of General, Vascular and Visceral Surgery, Steyr Regional Hospital, Steyr, Austria

2 Institute of Pathology, Steyr Regional Hospital, Steyr, Austria

Corresponding Author: Iliyan Emilov Iliev, e-mail: ilijaniliev18s@gmail.com

Conflict of interest: None declared


Patient: Female, 61-year-old
Final Diagnosis: Cameron lesions
Symptoms: Anemia • melena
Medication: —
Clinical Procedure: Gastroscopy
Specialty: Gastroenterology and Hepatology • Surgery

Objective: Rare disease

Background: Cameron lesions are linear erosions and ulcers on the crests of gastric mucosal folds in the neck of a hiatal hernia and can be difficult to diagnose and treat. This report is of a case of chronic iron deficiency in a 61-year-old woman with a late diagnosis of a Cameron lesion, who did not respond to a single treatment with the proton pump inhibitor (PPI) pantoprazole, but was then treated with oral poloxamer 407 with hyaluronic acid and chondroitin sulfate in addition to PPI.


Case Report: We report the case of a 61-year-old woman with recurrent iron-deficiency anemia, first diagnosed 40 years prior to her presentation at our Endoscopy Unit, and an ongoing melena. We discovered an intrahiatal gastric mucosal defect, which we at first treated with proton pump inhibitors and sucralfate. After a follow-up gastroscopy revealed the persistence of the lesion, we decided to incorporate into the treatment a gel-like substance containing, among others, hyaluronic acid and chondroitin sulfate, and observed that the lesion resolved completely.

Conclusions: This report highlights that Cameron lesions should be considered in patients with hiatal hernia who have iron-deficiency anemia and can be diagnosed on upper endoscopy. Further clinical studies are required to determine the role of combined poloxamer 407 with hyaluronic acid and chondroitin sulfate in the management of Cameron lesions.

MeSH Keywords: Chondroitin Sulfates • Esophageal Diseases • Hyaluronic AcidFull-text PDF: <https://www.amjcaserep.com/abstract/index/idArt/928021>
 2551

 2

 2

 28


Background

In 1986, Cameron and Higgins described linear erosions and ulcers on the crests of gastric mucosal folds in the neck of a hiatal hernia, resulting in gastrointestinal hemorrhage [1]. There is insufficient information on Cameron lesions in the published literature. The scarce data available are from single case reports or case series. Unfortunately, there are no randomized controlled studies on this topic. It is no exaggeration to mention that most textbooks in the field of internal medicine and surgery pay no attention to Cameron lesions, which is a fact that we will probably have to change soon. On the one hand, this is due to the small number of ‘Cameron’ patients worldwide and on the other hand because health care specialists do not recognize them. Even if recognized, a tissue sample from Cameron erosions or ulcers is rarely obtained, which explains the insufficient information about their histopathologic characteristics.

We report the case of a 61-year-old woman with chronic iron-deficiency with a late diagnosis of a Cameron lesion, who did not respond to a single treatment with the proton pump inhibitor (PPI) pantoprazole, but was then treated orally with combined poloxamer 407 with hyaluronic acid and chondroitin sulfate in addition to PPI.

Case Report

A 61-year-old woman presented for an outpatient gastroscopy due to ongoing melena. She took no iron supplementation or drugs that could have changed the stool color. The patient reported no abdominal or defecation problems. Previous surgeries included open appendectomy. The patient had psoriasis vulgaris as a single comorbidity and was a non-smoker. A prophylactic treatment with acetylsalicylic acid (ASA) was applied until 2009 because she had a stroke approximately 2 decades ago (the patient provided no medical records verifying this diagnosis).

Two previous gastroscopies (the first at age 21 years and the second approximately 15 years ago) had already been performed because of a chronic ‘intermittent’ iron-deficiency anemia which was first diagnosed about 40 years ago. Both revealed no pathologies. A colonoscopy had also already been performed, with no detectable bleeding sources. After the above-mentioned uneventful endoscopic examinations, the treating physicians attributed the iron deficiency to the excessive menstrual bleeding our patient used to have and prescribed her iron supplementation. Unfortunately, the anemia persisted after menopause. The patient had not taken any iron supplements for 5 years prior to our gastroscopy. Having in mind this medical history, we ordered blood tests. The results are shown in **Table 1**.

Table 1. Laboratory test results of our patient. The tests were performed at the time of the initial, first, and second follow-up gastroscopies.

	Unit of measurement	Initial gastroscopy	First follow-up gastroscopy	Second follow-up gastroscopy	Normal values
WBC	G/L	6.95	5.86	4.19	4.00–9.00
Platelets	G/L	251	221	270	150–400
RBC	T/L	4.43	4.55	4.60	3.80–5.50
Hemoglobin	g/dL	14.9	15.0	14.8	12.0–16.5
Hematocrit	%	40.3	43.1	41.3	36.0–48.0
MCH	pg	33.7	32.9	32.2	27.0–36.0
MCV	fL	90.9	94.8	89.9	80.0–101.0
MCHC	g/dL	37.1	34.8	35.9	30.0–38.0
RDW-CV	%	12.2	12.7	13.9	11.5–15.5
PTT	%	96	100	94	70.0–130.0
INR		1.0	1.0	1.0	
aPTT	sec.	26	25	25	22–35
Fibrinogen	g/L	2.99	2.96	3.14	1.80–4.50
TSH	mcU/mL	0.91	1.53	0.93	0.36–3.60

Table 1 continued. Laboratory test results of our patient. The tests were performed at the time of the initial, first, and second follow-up gastroscopies.

	Unit of measurement	Initial gastroscopy	First follow-up gastroscopy	Second follow-up gastroscopy	Normal values
CRP	mg/L	Negative	Negative	Negative	0–3
K	mmol/L	4.6	3.4	3.6	3.5–5.4
Na	mmol/L	141	139	139	132–148
Cl	mmol/L	107	105	105	95–110
Ca	mmol/L	2.3	2.3	2.3	2.0–2.8
Mg	mmol/L	1.0	1.0	1.0	0.6–1.1
Creatinine	mg/dL	0.7	0.7	0.8	0.5–1.1
eGFR	ml/min/l	>70	>70	>70	70–150
BUN	mg/dL	13	13	12	7–18
Uric acid	mg/dL	4.4	4.2	5.2	2.6–6.0
ASAT	U/L	21	17	23	0–31
ALAT	U/L	20	21	28	0–34
GGT	U/L	18	21	22	0–38
AP	U/L	125	135	119	50–135
Bilirubin	mg/dL	0.9	1.1	1.3	0.2–1.1
Lipase	U/L	116	105	106	73–393
Alpha-amylase	U/L	53	55	48	25–115
Fe	mcg/dL	115	190	119	50–170
Transferrin	g/L	2.29	2.41	2.49	2.00–3.60
Transf. sat.	%	36	56	34	15–55
Ferritin	mcg/L	63	47	57	22–250
Glucose (NF)	mg/dl	87	87	97	60–99

WBC – white blood cells; RBC – red blood cells; MCH – mean cell hemoglobin; MCV – mean cell volume; MCHC – mean cell hemoglobin concentration; RDW-CV – red blood cell distribution width; PT – prothrombin time; INR – international normalized ratio; aPTT – activated partial thromboplastin time; TSH – thyroid-stimulating hormone; CRP – C-reactive protein; K – potassium; Na – sodium; Cl – chloride; Ca – calcium; Mg – magnesium; eGFR – estimated glomerular filtration rate; BUN – blood urea nitrogen; ASAT – aspartate aminotransferase; ALAT – alanine aminotransferase; GGT – gamma-glutamyl transferase; AP – alkaline phosphatase; Fe – iron; Transf. sat. – transferrin saturation; NF – non-fasting.

During our first gastroscopy, after an unproblematic esophageal intubation, we detected an axial hiatal hernia spreading approximately from 37 to 38 cm from the incisors, with a diameter of 2.2 cm. Advancing aborally, we saw multiple small, flat hematin spots which covered the gastric fundus and corpus, and were not present in the antral area. The duodenum was macroscopically intact.

The decisive diagnostic factor proved to be the inversion of the fibroelastic gastroscope, as a small macroscopically visible, not bleeding linear erosion within the hiatal hernia (**Figure 1A**) was detected. Tissue samples were collected, which revealed only signs of carditis.

A therapy with the proton pump inhibitors (PPI) pantoprazole and sucralfate was initiated for 6 weeks (pantoprazole

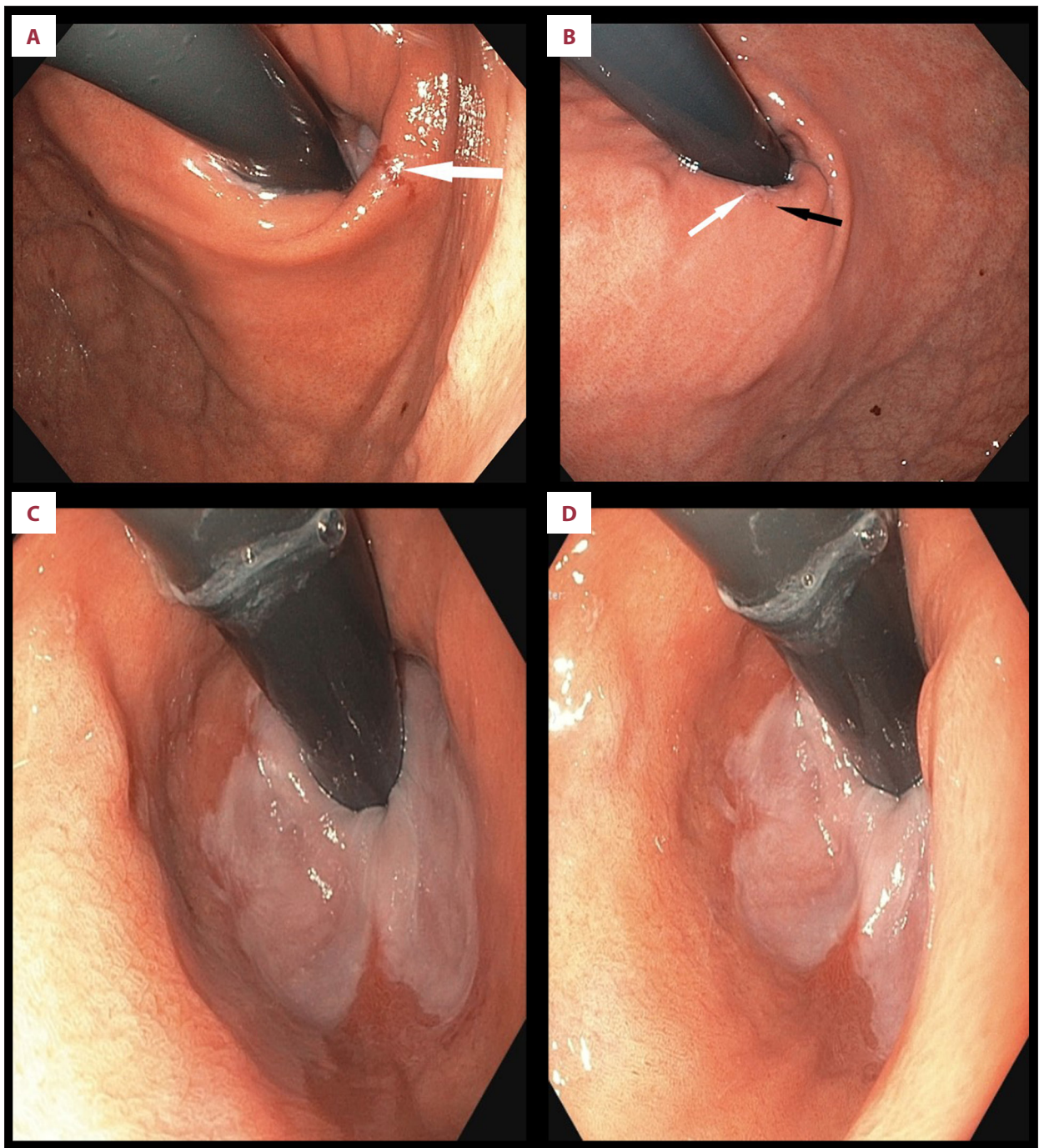


Figure 1. (A) Our patient's Cameron erosion at the time of diagnosis establishment. During the initial gastroscopy, the Cameron erosion presented as a linear mucosal defect (white arrow). After partial gas desufflation the volume and diameter of the sliding hiatal hernia were reduced to provide a better presentation of the lesion and enable sampling. On the left middle and lower part of the image and on the lower right part of the image one can recognize several hematin spots. (B) Our patient's Cameron erosion during the second (first follow-up) gastroscopy. The left half of the erosion (white arrow) is covered by fibrin, and the right half (black arrow) showed inflammatory alterations (microscopically red mucosa). There are several hematin spots on the middle and lower right side of the image. (C) Image from the last (second follow-up) gastroscopy with maximal gas insufflation. The Cameron erosion is resolved. (D) Image from the last (second follow-up) gastroscopy with maximal gas insufflation. The Cameron erosion is resolved.

40 mg b.i.d. for 2 weeks, and afterwards once daily; sucralfate 4 times daily) and an appointment for a follow-up gastroscopy was made.

At the time of the follow-up gastroscopy (6 weeks later), the patient had no complaints and no melena, and all laboratory values were within reference ranges (Table 1). During the endoscopic examination we observed, once more, multiple flat hematin spots in the proximal two-thirds of the stomach. The erosion was still visible, although half of it was covered by fibrin (Figure 1B). We obtained tissue samples from the erosion. We changed the treatment to PPI (pantoprazole 40 mg once daily) and a gel containing, among others, hyaluronic acid, chondroitin sulfate, and poloxamer 407 (4 times daily, 30 min postprandially, and at bedtime) for 3 months.

After the second gastroscopy, a new follow-up endoscopic appointment was made, which could not be kept due to the coronavirus crisis. We contacted the patient on the phone. She had no complaints and no melena, and after the above-mentioned 3-month period took only pantoprazole 40 mg once daily.

Eventually, a second follow-up gastroscopy was performed 7 months after the initial one. It revealed no erosion, with an intact cardiac mucosa (Figure 1C, 1D).

Discussion

Our patient had a Cameron erosion that manifested with recurrent anemia and melena. After not achieving a full recovery under the most commonly described treatment with PPI, we decided to incorporate a combination of hyaluronic acid (HA), chondroitin sulfate (CS), and poloxamer 407 (in addition to PPI) into the therapy, and observed that the Cameron erosion disappeared.

Cameron lesions are gastric mucosal defects of varying sizes localized within hiatal hernias. They were first described by the American physicians Alan J. Cameron and John A. Higgins (Mayo Clinic, 1986), who found a correlation between diaphragmatic hernias and occult gastrointestinal bleeding.

The prevalence of Cameron lesions depends on 2 factors: the size of the hiatal hernia and the size of the hernial sac. Larger hernias are more frequently associated with the development of mucosal defects. Statistically, Cameron lesions are found in 5.2% of all patients with hiatal hernias undergoing gastroscopy, as more than 60% of them present with a single tissue defect. They are diagnosed in up to 50% of all gastroscopic examinations performed for other reasons [2–4].

Etiology and pathophysiology

Cameron lesions are a complex phenomenon with an unclear pathogenesis. It is believed that they occur because of the combined effects of extra- and intraluminal mechanical and chemical factors. Pathogenetic factors are briefly presented in Table 2.

Morphology

Cameron lesions are non-peptic non-GERD-associated mucosal defects occurring on the top of gastric folds over the distal ring of a hiatal hernia (rarely proximally), most often along the lesser gastric curvature. They can be superficial (erosions) or deep ('riding' ulcers). Cameron lesions are typically longitudinal, but can also be oblong or ellipsoid, and never comprise the whole circumference of the hiatal hernia [14,15].

Symptoms

Most patients with Cameron lesions are older women with chronic anemia and large hiatal hernias. Since hiatal hernias are predominantly asymptomatic, they present with signs of overt (melena, hematochezia, hematemesis) or occult (iron-deficiency anemia, positive fecal occult blood test) gastrointestinal bleeding. Some patients have a medical history of recurrent gastrointestinal bleeding, with or without blood transfusions, oral intake of NSAID, or iron supplements. Rarely, they also have a peptic ulcer or esophagitis [4].

Diagnostics

The criterion standard for the diagnosis of Cameron lesions is gastroscopy. Very often, they remain uncovered within an index gastroscopy and are detected during a second-look or repeated gastroscopy ("One only sees what one looks for. One only looks for what one knows." Goethe). That is why each hiatal hernia should be inspected ante- and retrograde with an additional perpendicular presentation of the hernial opening where the diaphragmatic hiatus exerts the highest pressure on the gastric wall (the predominant localization of Cameron ulcers). The gastroscopist should examine the mucosa above and beneath the *Hiatus oesophageus*, since Cameron lesions can migrate upwards or downwards depending on the extent to which the stomach is insufflated. The use of chromoendoscopy and optical magnification can also be helpful. Accompanying pathological findings are sometimes observed, such as mucosal edema, erythematous stomach lining, and ecchymoses on gastric folds.

There are no specific laboratory tests or imaging modalities for detecting the presence of a Cameron lesion. Blood tests could be normal or demonstrate an iron-deficiency anemia. X-ray or computed tomography may be helpful for the diagnostics of

Table 2. Pathogeneses of Cameron lesions. Each factor is accompanied by a short explanation of its significance and role in the development of Cameron lesions.

Commentary	
Presence of a diaphragmatic hernia (axial or paraesophageal)	This is the most important factor. There are no Cameron lesions without a hiatal hernia. Larger hiatal hernias are associated with a greater risk of their occurrence (10–20% in axial hiatal hernias ≥ 5 cm) [4]
Extraluminal rubbing of the upper stomach and lower esophagus against the diaphragmatic hiatus	An important role is played by the permanent extraluminal rubbing of the upper stomach and lower esophagus against the diaphragmatic hiatus (the repeated ascending and descending movement associated with breathing and swallowing) and the intraluminal friction of the mucosal folds within the hiatal hernia against each other and at the level of the distal hernial ring. The gradient between the positive intraabdominal and negative intrathoracic pressure probably provokes an additional sliding movement of the gastro-esophageal junction between both cavities, resulting in mucosal distress with edema, petechiae, and ulcers. This effect is stronger in paraesophageal hiatal hernias
Ratio between hernial opening and hernial size	From the physical point of view, the ratio between the hernial opening (<i>Hiatus oesophageus</i>) and the hernial size appears to be most important. A significant trauma should be expected in smaller hiatal hernias and a greater friction in larger hernias [5]. The configuration of a hiatal hernia may change with time, which is why erosions or ulcers may appear at different locations [6]
Dual-hit hypothesis	Multiple studies showed that the mechanical trauma from outside is insufficient to cause mucosal defects. Cameron lesions occur only when the external compression on the gastric wall is combined with an aggressive influence from inside. According to the so-called 'dual-hit hypothesis' additional intraluminal and mucosal factors also play a substantial role: gastric acid, gastro-esophageal reflux, and the oral intake of NSAID for 3 days/week within a month. One study demonstrated that in large hiatal hernias, intraluminal lesions occur only when the gastro-esophageal flap valve is intact. This valve counteracts the reflux and affects the role of gastric acid [7,8]
Helicobacter pylori	There is no clear correlation between HP and Cameron lesions. Only 1/3 of all patients with Cameron lesions are HP-positive [9–11]
Gastric ischemia and stasis	Additional independent factors for the occurrence of Cameron lesions could be the so-called gastric 'ischemia' and 'stasis'. In some patients, the diaphragmatic hiatus could be narrow enough to cause an intermittent venous stasis in the gastric wall when the diaphragm contracts (e.g., sneezing, coughing, choking). The pathogenesis of Cameron lesions is multifactorial and probably comprises patient's genotype and phenotype, their comorbidities, and the oral intake of drugs. Patients with Cameron lesions often take iron supplements because the gastric stasis tablets and secretions can remain longer in the herniated stomach and cause pressure erosions [12,13]

NSAID – Non-steroidal anti-inflammatory drugs; HP – *Helicobacter pylori*.

complications (e.g., perforation, volvulus, blood clots in the stomach). Under certain conditions, computed tomography angiogram or Tc-99m-labeled red blood cells scintigraphy can detect an active bleeding source (bleeding speed at least 0.5 ml/min and 0.04 ml/min, respectively). The role of capsule endoscopy remains unclear [12,14].

Histopathologic characteristics

To the best of our knowledge, there is only 1 published article containing a description of histopathologic changes in Cameron lesions. Katz et al. describe mucosal alterations due to mucosal vascular obstruction consistent with ischemic gastropathy, such as hemorrhagic infiltrates, fibrin thrombi, inflammatory

response, sanguine micro-suffusions, sloughing of epithelial cells, atrophy of crypts, and coagulation necrosis [16].

Our first tissue sampling revealed mucosal alterations consistent with a minor chronic carditis. The results from the second sampling are shown in **Figure 2**.

Management

The treatment of Cameron lesions (conservative or surgical) should be determined individually [3]. Because of the limited knowledge about their natural history and the small number of patients, modern medicine was unable to create strict guidelines and algorithms for their management. Literature

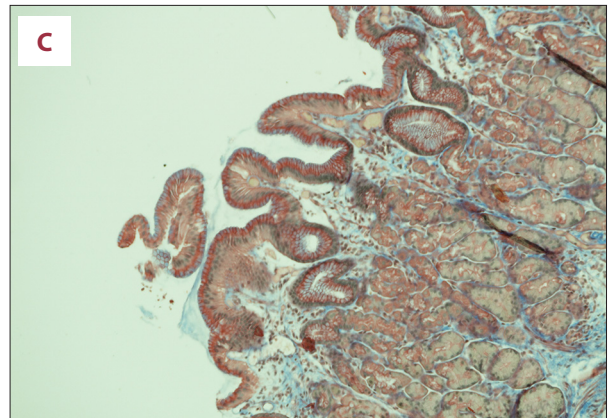
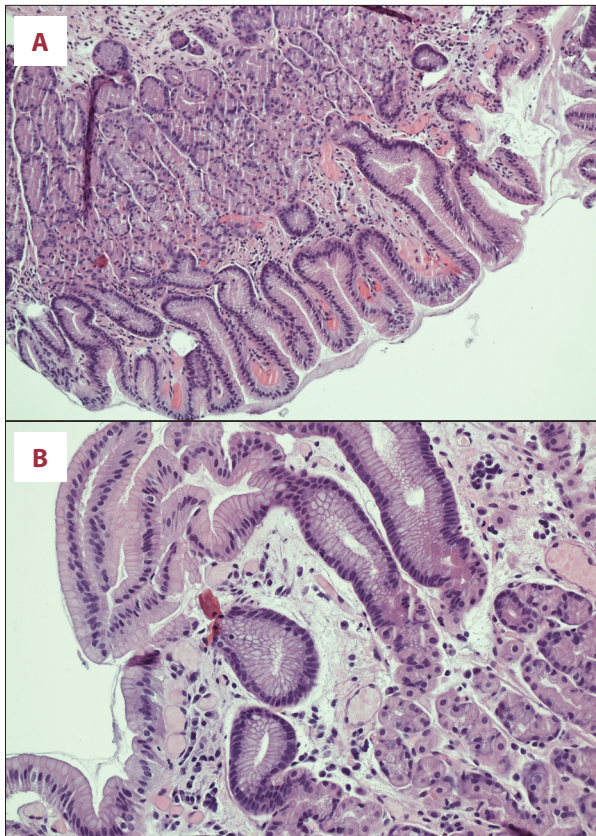


Figure 2. (A) Microscopic image (HE, magnification $\times 100$) from the second tissue sampling: oxyntocardiac mucosa with minimal foveolar hyperplasia. HE: Hematoxylin and eosin staining. (B) Microscopic image (HE, magnification $\times 200$) from the second tissue sampling: focal minor active inflammatory infiltrates in lamina propria with a slight edema and dilated capillaries. No ischemic stigmata were present. (C) Microscopic image (CAB, magnification $\times 100$) from the second tissue sampling: a minimal fibrosis in lamina propria in a single localized area. HP was not detectable. CAB – chromotrope aniline blue staining; HP – *Helicobacter pylori*.

reports range from cases of spontaneous healing to high-dose PPI treatment regimens [8].

The management of Cameron lesions depends on their clinical presentation. Currently, most authors recommend starting PPI administration as soon as the diagnosis is established. If the patient already receives PPIs once daily, their dosage/frequency of administration should be increased. If blood tests show signs of iron deficiency, iron supplementation is required. In case it has already been initiated, the iron dosage should be increased. A single iron supplementation is not sufficient [17]. By means of the above-mentioned treatment, an adequate symptom control is achieved in up to half of the patients with Cameron lesions. Of course, in case of significant bleeding and hemodynamic shock, stabilizing measures should be taken, since Cameron lesions cause life-threatening gastrointestinal bleeding in up to one-third of all patients [11,18].

NSAID intake should be immediately discontinued. Some authors recommend the administration of prokinetic agents [19].

There are no strict criteria for the conversion from conservative to surgical treatment. Some specialists suggest a secondary surgical treatment in case of persistent complaints (e.g., anemia, hospitalization because of recurrent gastrointestinal bleeding or chronic blood loss) or complications (e.g., refractory bleeding,

perforation, volvulus, gastric incarceration) [4]. The main goal of the surgical therapy is to eliminate the mandatory prerequisite for the occurrence of Cameron lesions – the hiatal hernia (there is no Cameron lesion without hiatal hernia.) Possible options are laparoscopic/open fundoplication+gastropexy and the recently developed single-incision transgastric underrunning (SILT) [3,9,20,21].

Endoscopy

Endoscopic hemostasis is a relevant but rarely reported non-surgical treatment option for bleeding Cameron lesions. Band ligation and clipping proved to be effective. A follow-up gastroscopy was not performed in many studies, but could be indicated when complaints persist.

Our patient

After diagnosis establishment, we started a treatment with oral intake of PPIs (pantoprazole 40 mg b.i.d. for 2 weeks and once daily afterwards) in combination with sucralfate 4 times daily, both for 6 weeks. Since the iron panel revealed normal values, no iron supplementation was initiated. PPIs administration aims to inhibit gastric acid production; thus, its possible role in the genesis of Cameron lesions. Sucralfate is a sucrose octasulfate and aluminum hydroxide (AlOH) complex

forming a viscous paste in aqueous acidic media (e.g., in the esophagus, stomach, duodenum). It adheres to defective and intact mucosa through polyvalent bridges between negatively charged sucralfate polyanions and positively charged proteins, which are present in high concentrations in mucosal lesions. It also buffers the gastric acid, inhibits the action of pepsin, and absorbs bile salts. All these properties enable sucralfate to act as an effective barrier counteracting the penetration of the above-mentioned substances. Sucralfate proved to be as effective as antacids or H₂-receptor antagonists in healing peptic ulcers and in animals, but was ineffective in preventing corticosteroid-induced ulcerations. Sucralfate probably stimulates the local prostaglandin E₂ (PGE₂) and prostacyclin (PGI₂) synthesis in gastric mucosa [22,23].

Since the first follow-up gastroscopy showed no improvement, we decided to use a mixed preparation of hyaluronic acid, chondroitin sulfate, and poloxamer 407. In animal models (Yorkshire pigs), this mixture exhibited positive effects on the healing process of scars left after endoscopic mucosal resection (EMR) or endoscopic submucosal dissection (ESD) and had been expected to provoke an early proliferation of collagen and elastic fibers in gastric mucosal defects, thus also contributing to ulcer healing. Furthermore, it is an acceptable low-cost alternative to the existing treatment regimens [24].

Hyaluronic acid and chondroitin sulfate are extensively used in wound treatment. Their role in the therapy of gastrointestinal lesions is a subject of continuous research. Hyaluronic acid is a non-sulfated natural glycosaminoglycan and main component of the extracellular matrix. HA is a hygroscopic macromolecule formed by the polymerization of glucuronic acid and N-acetylglucosamine disaccharide. It interacts with several cell surface receptors of malignant and non-malignant gastric mucosa. HA is involved in human innate immunity and inflammatory processes, as it takes part in leukocyte recruitment and macrophage activation. It induces dendritic cell maturation and promotes cytokine release by dendritic cells and endothelial cells. HA also possesses anti-bacterial, anti-fungal, and antiviral properties and promotes angiogenesis. Topically applied on oral mucosa, it supports tissue hydration in inflammatory processes and mucosal response to tissue injuries that could possibly result in ulcer formation and forms a protective film over exposed mucosal nerve endings, preventing them from overstimulation. Sodium hyaluronate possesses also hemostatic properties when injected in peptic ulcers.

Chondroitin sulfate is a glycosaminoglycan consisting of repeated disaccharide units polymerized into long chains. CS is an effective inhibitor of pepsin-induced damage to stomach and duodenal mucosa and showed potent anti-inflammatory properties in animal models [25–27].

Poloxamer 407 is a water-soluble, non-ionic triblock copolymer that is liquid at room temperature and assumes a gel form at body temperature. It is often used as a drug carrier. It possesses mucoadhesive properties and does not irritate mucosal membranes. Poloxamer 407 showed no direct regenerative or antimicrobial properties but maintains a stable concentration of the substances it carries for a prolonged time [28].

Conclusions

Hyaluronic acid and chondroitin sulfate are widely used in cosmetics because of their skin regeneration properties. They also possess a proven beneficial effect on the healing of acute and chronic wounds. The role of HA and CS in the treatment of gastrointestinal mucosal pathologies has increasingly been examined over the last decade. In accordance with the published literature and the experience with our patient, we hypothesize that they could also be useful for the conservative treatment of Cameron lesions (in combination with PPI, as stated in the summary of product characteristics of the products approved for use in the gastrointestinal tract). They counteract many of the possible organic and chemical pathogenetic factors, leading to its occurrence, but, of course, cannot influence the most important mechanical factor – the hiatal hernia.

In light of the good success of HA and CS in wound healing, we hypothesize the principle that internal wounds (ulcers and mucosal lesions) could be treated like external wounds – treat ulcers like wounds (treat inside like outside). If not achieving a permanent resolution, it could at least gain us some time before surgery to stabilize the patient's condition, which could sometimes be crucial.

This case report highlights that Cameron lesions should be considered in patients with hiatal hernia who have iron-deficiency anemia and can be diagnosed on upper endoscopy. Further clinical studies are required to determine the role of combined poloxamer 407 with hyaluronic acid and chondroitin sulfate in the management of Cameron lesions.

Acknowledgments

The authors would like to express their sincere gratitude to the teams of the Endoscopy Unit, Institute of Pathology, and the Department of General, Visceral and Vascular Surgery of the Steyr Regional Hospital for their help in obtaining and processing all the materials necessary for this article.

Conflicts of interest

None.

References:

1. Cameron AJ, Higgins JA: Linear gastric erosion. A lesion associated with large diaphragmatic hernia and chronic blood loss anemia. *Gastroenterology*, 1986; 91: 338–42
2. Gray DM, Kushnir V, Kalra G et al: Cameron lesions in patients with hiatal hernias: Prevalence, presentation, and treatment outcome. *Dis Esophagus*, 2015; 28(5): 448–52
3. Kapadia S, Jagroop S, Kumar A: Cameron ulcers: An atypical source for a massive upper gastrointestinal bleed. *World J Gastroenterol*, 2012 ;18(35): 4959–61
4. Marine C, Dennis MJ, Gordon VO et al: Severe upper gastrointestinal hemorrhage from linear gastric ulcers in large hiatal hernias: a large prospective case series of Cameron ulcers. *Endoscopy*, 2013; 45(5): 397–400
5. Winsor CWO, Collis JL: Anemia and hiatus hernia. *Thorax*, 1967; 22: 73
6. Kimer N, Schmidt PN, Krag A: Cameron lesions: an often overlooked cause of iron deficiency anaemia in patients with large hiatal hernias. *BMJ Case Rep*, 2010; 2010: bcr0620103129
7. Kaneyama H, Kaise M, Arakawa H: Gastroesophageal flap valve status distinguishes clinical phenotypes of large hiatal hernia. *World J Gastroenterol*, 2010; 16(47): 6010–15
8. Zullo A, Manta R, De Francesco V et al: Cameron lesions: A still overlooked diagnosis. Case report and systematic review of literature. *Clin Res Hepatol Gastroenterol*, 2018; 42: 604–9
9. Darrell M, Gray DM, Kushnir V et al: Cameron lesions in patients with hiatal hernias: Prevalence, presentation, and treatment outcome. *Dis Esophagus*, 2015; 28(5): 448–52
10. Townsend CM, Beauchamp RD: *Sabiston textbook of surgery*. Philadelphia: Elsevier Saunders, 2012
11. Weston AP: Hiatal hernia with Cameron ulcers and erosions. *Gastrointest Endosc Clin N Am*, 1996; 6(4): 671–79
12. Morrissey JF: You see what you look for. *Gastroenterology*, 1986; 91(2): 481–82
13. Winsor CWO, Collis JL: Anemia and hiatus hernia: Experience in 450 patients. *Thorax*, 1967; 22: 73–78
14. Maganty K, Smith RL: Cameron lesions: Unusual cause of gastrointestinal bleeding and anemia. *Digestion*, 2008; 77: 214–17
15. Gupta P, Suryadevara M, Das A et al: Cameron ulcer causing severe anemia in a patient with diaphragmatic hernia. *Am J Case Rep*, 2015; 16: 733–36
16. Jordan K, Sonia B, Jagmohan SS: Histopathological characterization of a Cameron lesion. *Int J Surg Pathol*, 2012 ;20(5): 528–30
17. Weston AP: Hiatal hernia with Cameron ulcers and erosions. *Gastrointest Endosc Clin N Am*, 1996; 6(4): 671–79
18. Moskovitz M, Fadden R, Min T et al: Large hiatal hernias, anemia, and linear gastric erosion: Studies of etiology and medical therapy. *Am J Gastroenterol*, 1992; 87: 622
19. Hernandez GH, Soto ICF, Garcia CAJ: Cameron lesions: Keep in mind in chronic anemia. *J Hepatol Gastroint Dis*, 2016; 2: 2
20. Tan CHN, Kim G, So J et al: Single-incision laparoscopic transgastric under-running and closure of Cameron ulcers in acute gastrointestinal bleeding. *J Gastrointest Surg.*, 2018; 22(3): 553–56
21. Panzuto F, Di Giulio E, Capurso G et al: Large hiatal hernia in patients with iron deficiency anaemia: A prospective study on prevalence and treatment. *Aliment Pharmacol Ther*, 2004; 19: 663
22. Arronson JK: *Meyler's Side Effects of Drugs. The international encyclopedia of adverse drug reactions and interactions*, 16th edition. New York, Elsevier Science, 2016
23. Nagashima R: Mechanisms of action of sucralfate. *J Clin Gastroenterol*, 1981; 3(Suppl. 2): 117–27
24. Córdova H, Cuatrecasas M, García-Rodríguez A et al: Successful outcomes of a new combined solution of hyaluronic acid, chondroitin sulfate and poloxamer 407 for submucosal injection: animal survival study. *Endosc Int Open*, 2019; 7(4): E576–82
25. Kappor P, Sachdeva S, Sachdeva S: Topical hyaluronic acid in the management of oral ulcers. *Indian J Dermatol*, 2011; 56(3): 300–2
26. Ianniti T, Morales-Medina JS, Merighi A et al: A hyaluronic acid- and chondroitin sulfate-based medical device improves gastritis pain, discomfort, and endoscopic features. *Drug Deliv Transl Res*, 2018; 8(5): 994–99
27. Cho YK, Kim CS, Kim SY et al: The hemostatic effect of endoscopic sodium hyaluronate injection in peptic ulcer bleeding. *Hepatogastroenterology*, 2007; 54(76): 1276–79
28. Giuiliano E, Paolino D, Fresta M, Cosco D: Mucosal applications of poloxamer 407-based hydrogels: An overview. *Pharmaceutics*, 2018; 10(3): 159