



Since January 2020 Elsevier has created a COVID-19 resource centre with free information in English and Mandarin on the novel coronavirus COVID-19. The COVID-19 resource centre is hosted on Elsevier Connect, the company's public news and information website.

Elsevier hereby grants permission to make all its COVID-19-related research that is available on the COVID-19 resource centre - including this research content - immediately available in PubMed Central and other publicly funded repositories, such as the WHO COVID database with rights for unrestricted research re-use and analyses in any form or by any means with acknowledgement of the original source. These permissions are granted for free by Elsevier for as long as the COVID-19 resource centre remains active.

Available online at www.sciencedirect.com

ScienceDirect

Biomedical Journal

journal homepage: www.elsevier.com/locate/bj

Brief Communication

Bilateral lentiform and caudate nucleus lesions in a child with COVID-19: A case report

Q4

Q3 Nihal Akçay^{a,*}, Figen Bakırtaş Palabıyık^b, Esra Şevketoğlu^a^a Department of Pediatric Intensive Care Unit, Bakırköy Dr. Sadi Konuk Research and Training Hospital, University of Health Sciences, Istanbul, Turkey^b Department of Pediatric Radiology, Bakırköy Dr. Sadi Konuk Research and Training Hospital, University of Health Sciences, Istanbul, Turkey

ARTICLE INFO

Article history:

Received 22 April 2022

Accepted 31 May 2022

Available online xxx

Keywords:

Caudate nucleus

Lentiform nucleus

Child

COVID-19

ABSTRACT

Neurological complications are frequently mentioned in the published reports regarding the 2019 coronavirus (COVID-19) disease. Especially encephalopathy draws attention as the leading symptom or complication of Covid-19 in some reports. This article discussed a 3-year-old patient with bilateral lentiform and caudate nuclei involvement on brain imaging, who presented with mental status changes and acute muscular weakness, possibly due to COVID-19. To the best of our knowledge, this case is the first one showing pathological signal enhancement and edema in bilateral lentiform and caudate nuclei associated with COVID-19.

Introduction

Coronavirus disease 2019 (COVID-19) which is caused by severe acute respiratory syndrome coronavirus 2 (SARS-CoV-2) has infected more than 490 million people and caused more than 6 million deaths worldwide as of 8 April 2022 [1]. There has been an increase in central and peripheral nervous system involvement reports in COVID-19. These neurological complications have included encephalopathy, meningoencephalitis, ischaemic stroke, cerebral venous thrombosis, seizures, acute necrotizing encephalopathy, Guillain-Barré syndrome (GBS), cerebellitis, reversible splenic lesion, microhemorrhages, and posterior reversible encephalopathy syndrome [2–7]. We

present a 3-year-old patient with COVID-19 who presented mental status changes and acute muscular weakness, who has pathological findings on electroencephalogram (EEG) and magnetic resonance imaging (MRI).

Case

A 3-year-old previously healthy boy presented to the emergency department with fever, gaze-fixed, and muscular weakness over the last two days. He had a low-grade fever (38 °C) and cough for the past ten days. He was admitted to our pediatric intensive care unit (PICU) due to the development of encephalopathy with a change in mental status. At

* Corresponding author. Department of Pediatric Intensive Care Unit, Bakırköy Dr. Sadi Konuk Research and Training Hospital, University of Health Sciences, Istanbul, 34093, Turkey.

E-mail addresses: dmihalakcay@gmail.com (N. Akçay), figen_dr@yahoo.com (F.B. Palabıyık), caglaes@gmail.com (E. Şevketoğlu).

Peer review under responsibility of Chang Gung University.

<https://doi.org/10.1016/j.bj.2022.05.009>

2319-4170/© 2022 Chang Gung University. Publishing services by Elsevier B.V. This is an open access article under the CC BY-NC-ND license (<http://creativecommons.org/licenses/by-nc-nd/4.0/>).

Please cite this article as: Akçay N et al., Bilateral lentiform and caudate nucleus lesions in a child with COVID-19: A case report, Biomedical Journal, <https://doi.org/10.1016/j.bj.2022.05.009>

the time of admission, vital signs were determined as follows; body temperature was 37.7 °C, heart rate was 132 beats/min, blood pressure was 96/65 mm Hg, respiratory rate was 28 breaths/min, and oxygen saturation in room air was 95%. On neurological examination, Glasgow Coma Scale was 11 (E 3, V 4, M 4), and the bilateral pupillary light reflex was present. Meningeal irritation findings were positive. His bilateral lower and upper extremity muscle weakness evaluation was 2/5, while Babinski's reflex was positive, and deep tendon reflexes were absent. In admission, SARS CoV-2 real-time reverse transcription-polymerase chain reaction (RT-PCR) was examined with a nasopharyngeal swab, and the SARS-CoV-2 blood antibody test was found to be negative. His father had a fever and cough for four days, and his SARS Cov-2 RT-PCR was positive.

Our patient's brain MRI was shown a symmetrical pathological signal increase and edema in bilateral lentiform and caudate nuclei [Fig. 1]. Laboratory findings showed that C-reactive protein 7 mg/L, procalcitonin 9.03 ng/ml, hemoglobin 10.2 g/dL, leukocyte 19.410/mm³, lymphocyte 3.730/mm³, thrombocyte 661.000/uL. The other laboratory parameters were in normal ranges. According to the results obtained from a successful lumbar puncture for diagnosis, pleocytosis was not detected in the cerebrospinal fluid (CSF) analysis, CSF protein level was 15 mg/dL, and serum glucose level was 134 mg/dL, while CSF glucose level was 80 mg/dl. SARS-CoV-2

PCR test and antibody level studied from cerebrospinal fluid were obtained negative. Prophylactic antimicrobial treatment for viral or bacterial encephalitis was started with cefotaxime, vancomycin, and acyclovir. Background EEG activity showed a diffuse delta pattern. Levetiracetam treatment was initiated after he sustained an episode of convulsions. In addition to antibiotherapy, intravenous immunoglobulin (IVIG) (1 g/kg for 2 days) was administered, and physical therapy was also started. No positive results were obtained from the meningitis and encephalitis panel which included *Cryptococcus neoformans/Cryptococcus gattii*, Cytomegalovirus, Enterovirus, *Escherichia coli* K1, *Haemophilus influenza*, Herpes simplex virus 1, Herpes simplex virus 2, Human herpesvirus 6, Varicella zoster virus, Human parechovirus, *Listeria monocytogenes*, *Neisseria meningitidis*, *Streptococcus agalactiae*, and *Streptococcus pneumonia*. Autoimmune encephalitis panel, including AMPA-R1 Ab, AMPA-R2 Ab, and anti-NMDA-R-Ab, CASPR2 Ab. (VGKC), Ig11 Ab. (VGKC) and GABA-R-Ab was negative. CSF culture was sterile. Metabolic tests, including urine organic acids, blood and CSF amino acids, tandem mass spectrometry, ammonia, and lactate levels were found to be normal. On the 8th day of treatment and follow-up, it was seen that the SARS-CoV-2 antibody became positive. On the 12th day, brain MRI showed that edema and pathological signal changes were significantly regressed at the bilateral caudate and lentiform nuclei [Fig. 2]. On the 15th day, the

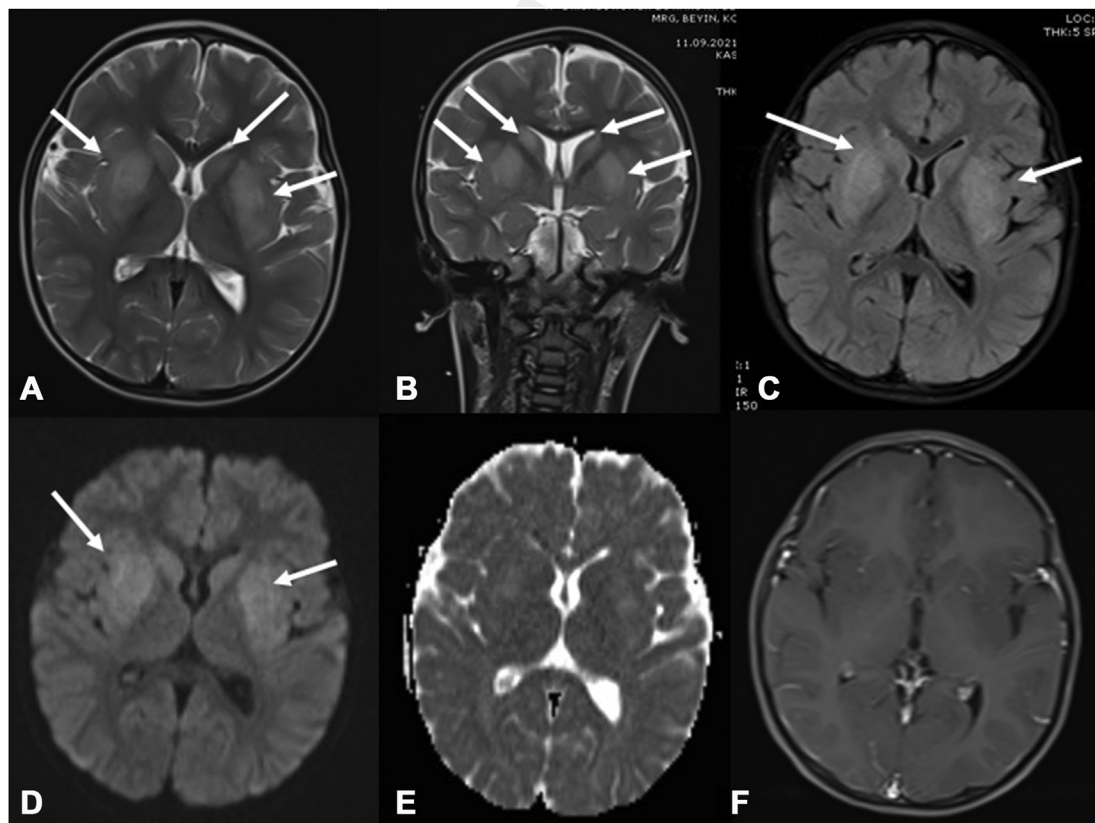


Fig. 1 In the cranial MRI examination of the case; Symmetrical pathological signal increases and edema were observed in bilateral lentiform and caudate nuclei in T2W axial (A), coronal (B) sections, and FLAIR(C) sequences. Diffusion-weighted sequence (D) and ADC mapping (E) show increased diffusion in these localizations, and no contrast enhancement was detected after contrast administration (F).

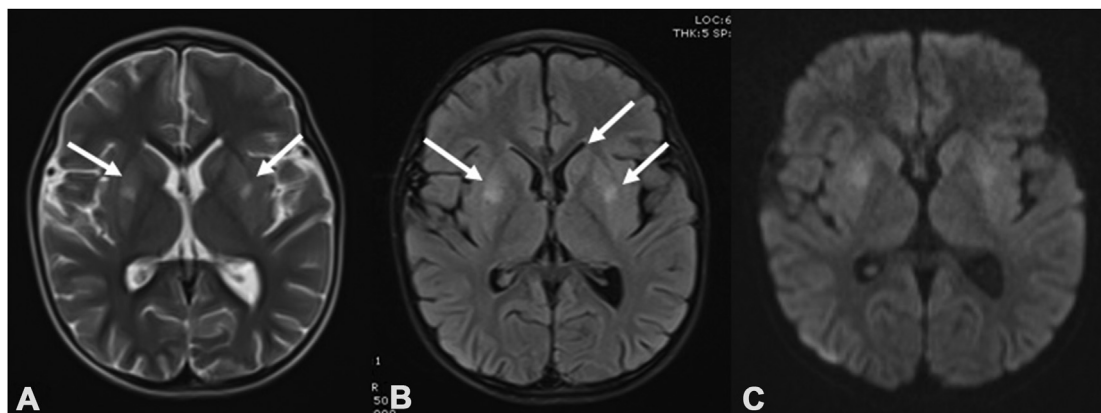


Fig. 2 In the cranial MRI examination of the case 12 days later, it is observed that edema and pathological signal changes at the level of bilateral caudate and lentiform nuclei have decreased significantly.

SARS-CoV-2 antibody became positive and the antibody level has risen. On the 16th day, he was discharged from the hospital without weakness of the neck, flexor, and extensor muscles of the upper extremities and the lower extremities of 5/5. It was observed that reflexes remained normal in the follow-up. Written informed consent for publication was obtained from the parents on behalf of the patient.

Discussion

We, herein, report a previously healthy child who had bilateral lentiform and caudate nucleus lesions associated with COVID-19. We think, our patient had a viral load that was already low enough to not test positive at the time of admission, but the later antibody-positive tests showed there indeed was a SARS-CoV-2 infection. In this period, the most commonly detected variant was delta in Turkey. The Delta variant is associated with higher viral loads, higher rates of hospitalization and ICU admission, mortality, and higher odds of oxygen requirement [8].

A retrospective study revealing neuroimaging manifestations associated with COVID-19 described eight distinctive neuroradiologic patterns. The most frequent MRI findings were signal abnormalities located in the medial temporal lobe, hemorrhagic lesions, and extensive and isolated white matter microhemorrhages [9]. In a recent study, brain imaging of children with COVID-19 who developed encephalopathy showed that; the most common findings in children were ADEM-like changes in the brain, myelitis, and neural enhancement. The incidence of stroke in children is less, compared to adults. The splenic lesion was predominantly observed in children with multisystem inflammatory syndrome in children (MIS-C) [10]. Gonca et al. reported two children had reversible splenic lesions with encephalopathy associated with MIS-C [4]. Akcay et al. showed two ADEM patients who were resistant to intravenous immunoglobulin and high-dose steroid therapy, their main central nervous system symptoms were seizure and encephalopathy. One patient developed cortical laminar necrosis [6]. One of the most frequently reported neurological manifestations is

COVID-19-associated GBS. Akcay et al. showed an acute motor axonal neuropathy patient who is a variant type of Guillain-Barre Syndrome (GBS) associated with COVID-19 [7]. Neurological and radiological findings related to COVID-19 continue to be reported. One of the most recently reported radiological findings is a case of cerebellitis associated with MIS-C [5].

COVID-19 associated with neurological manifestations is likely to leave permanent neurological damage. Furthermore, its treatment is yet to be clear [11]. The patients with neurologic manifestation were treated with corticosteroids, IVIG, and therapeutic plasma exchange. Further research has had variable outcomes [2–10]. Besides, we treated with IVIG, our patient was discharged from the hospital with normal mental status and without weakness of all muscles.

In conclusion, we contributed by reporting a patient with COVID-19-related lentiform and caudate nucleus involvement, which has not been reported in the literature before.

Consent

The written informed consent to publication has been obtained from the parents.

Data availability state

All data of the patient are stored in the data recording system of our hospital.

Authors' contributions

- Literature search: N.A., and F.B.P.
- Study design: N.A. and E.S.
- Manuscript preparation: N.A., and E.S.
- Review of the manuscript: N.A., and E.S.
- Contribute to management: N.A., F.B.P., and E.S.

Funding

This research did not receive any grant from the public, commercial, or not-for-profit sector funding agencies.

Conflict of interest

The authors declare no conflict of interest.

REFERENCES

- [1] COVID-19 Map, Johns hopkins coronavirus resource center. <https://coronavirus.jhu.edu/map.html> (accessed April 8, 2022).
- [2] Paterson RW, Brown RL, Benjamin L, Nortley R, Wiethoff S, Bharucha T, et al. The emerging spectrum of COVID-19 neurology: clinical, radiological and laboratory findings. *Brain* 2020;143:3104–20.
- [3] Harapan BN, Yoo HJ. Neurological symptoms, manifestations, and complications associated with severe acute respiratory syndrome coronavirus 2 (SARS-CoV-2) and coronavirus disease 19 (COVID-19). *J Neurol* 2021;268:3059–71.
- [4] Bektaş G, Akçay N, Boydağ K, Şevketoğlu E. Reversible splenic lesion syndrome associated with SARS-CoV-2 infection in two children. *Brain Dev* 2021;43:230–3.
- [5] Akçay N, Oğur M, Menentoğlu ME, Sofuoğlu AI, Boydağ Güvenç K, Bakirtaş Palabiyik F, et al. Acute cerebellitis in MIS-C: a case report. *Pediatr Infect Dis J* 2022;41:e16–8.
- [6] Akçay N, Bektaş G, Menentoğlu ME, Oğur M, Sofuoğlu AI, Bakirtaş Palabiyik F, et al. COVID-19-associated acute disseminated encephalomyelitis-like disease in 2 children. *Pediatr Infect Dis J* 2021;40:e445–50.
- [7] Akçay N, Menentoğlu ME, Bektaş G, Şevketoğlu E. Axonal Guillain-Barre syndrome associated with SARS-CoV-2 infection in a child. *J Med Virol* 2021;93:5599–602.
- [8] Long B, Carius BM, Chavez S, Liang SY, Brady WJ, Koyfman A, et al. Clinical update on COVID-19 for the emergency clinician: presentation and evaluation. *Am J Emerg Med* 2022;54:46–57.
- [9] Kremer S, Lersy F, de Sèze J, Ferré JC, Maamar A, Carsin-Nicol B, et al. Brain MRI findings in severe COVID-19: a retrospective observational study. *Radiology* 2020;297:E242–51.
- [10] Lindan CE, Mankad K, Ram D, Kociolek LK, Silvera VM, Boddaert N, et al. Neuroimaging manifestations in children with SARS-CoV-2 infection: a multinational, multicentre collaborative study. *Lancet Child Adolesc Health* 2021;5:167–77.
- [11] Bholā S, Trisal J, Thakur V, Kaur P, Kulshrestha S, Bhatia SK, et al. Neurological toll of COVID-19. *Neurol Sci* 2022;43:2171–86.