

Received: 2010.03.26  
Accepted: 2010.04.06

## Computed tomography angiography reveals the crime instrument – case report

Anna Banaszek<sup>1</sup>, Maciej Guziński<sup>2</sup>, Marek Szaśiadek<sup>2</sup>

<sup>1</sup> Student Scientific Group at the Department of General Radiology, Interventional Radiology and Neuroradiology, Wrocław Medical University, Wrocław, Poland

<sup>2</sup> Department of General Radiology, Interventional Radiology and Neuroradiology, Wrocław Medical University, Wrocław, Poland

**Author's address:** Marek Szaśiadek, Department of General Radiology, Interventional Radiology and Neuroradiology, Wrocław Medical University, Wrocław, Borowska 213 Str., 50-556 Wrocław, Polska, e-mail: mareks@rad.am.wroc.pl

### Summary

<b>Background:</b>	The development of multislice CT technology enabled imaging of post-traumatic brain lesions with isotropic resolution, which led to unexpected results in the presented case
<b>Case Report:</b>	An unconscious, 49-year-old male with a suspected trauma underwent a routine CT examination of the head, which revealed an unusual intracerebral bleeding and therefore was followed by CT angiography (CTA). The thorough analysis of CTA source scans led to the detection of the bleeding cause.
<b>Conclusions:</b>	The presented case showed that a careful analysis of a CT scan allows not only to define the extent of pathological lesions in the intracranial space but it also helps to detect the crime instrument, which is of medico-legal significance.
<b>Key words:</b>	brain • stab wound • computed tomography angiography
<b>PDF file:</b>	<a href="http://www.polradiol.com/fulltxt.php?ICID=878524">http://www.polradiol.com/fulltxt.php?ICID=878524</a>

### Background

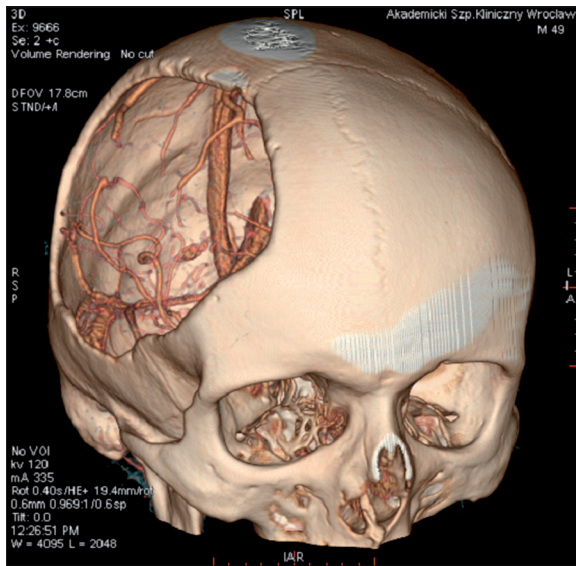
Computed tomography (CT), as a widely available and a low invasive method, constitutes a routinely applied diagnostic tool in the diagnostic imaging of craniocerebral traumas and brain strokes. It allows for the detection of the posttraumatic changes in the structure of the skull (owing to the application of a bone window), as well as for evaluation of the extent of brain injuries. Owing to the introduction of the multislice CT technology, it is now possible to visualise hyperdense haemorrhagic foci with a *submillimeter resolution*, in any of the planes, and to perform high-quality angio-CT scans when trying to exclude bleeding from a malformation.

In case of the presented patient, application of the above mentioned imaging method in the course of routine emergency procedures led to unexpected results

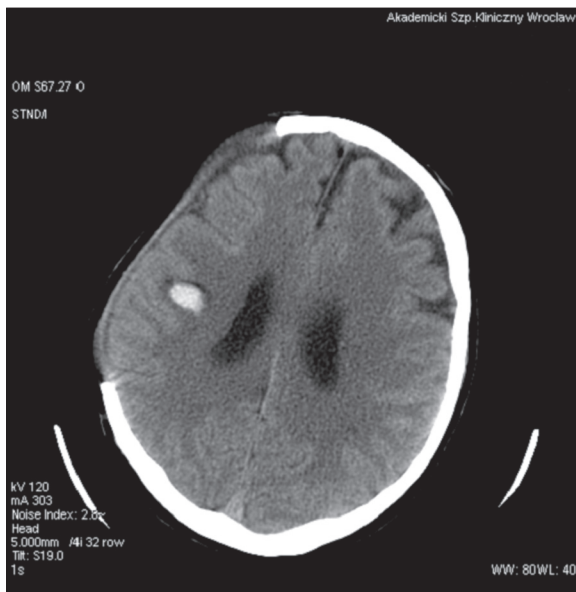### Case Report

A 49-year-old man, found lying on the floor of his flat, was transported to the admission room of a clinical

hospital in Wrocław. A preliminary physical examination performed by a physician on duty revealed some posttraumatic haemorrhagic lesions of the scalp. Due to the patient's condition and suspicion of an injury or a stroke, an immediate CT of the head was carried out. The results were unexpected. The most noticeable lesion was an extensive, right-sided bone defect in the skull, most probably due to a *frontoparietotemporal craniectomy* (Figure 1). Moreover, CT revealed a subarachnoid haemorrhage in the basal cisterns, cerebropontine angle and Sylvian fissure. On the right, there was a distinct, streaky, hyperdense focus of haemorrhage, stretching from the parietal cortex to the III ventricle (Figure 2). The integuments covering that site were slightly elevated. Due to that non-standard image of the haemorrhagic focus, a CT angiography was performed to localise the source of bleeding. The examination did not reveal vascular malformations but the MIP images (Maximum Intensity) projections, especially in the frontal plane, showed that the haemorrhagic focus in the right hemisphere assumed a streaky shape, which led us to the suspicion that the source of injury could be a stab wound inflicted with a

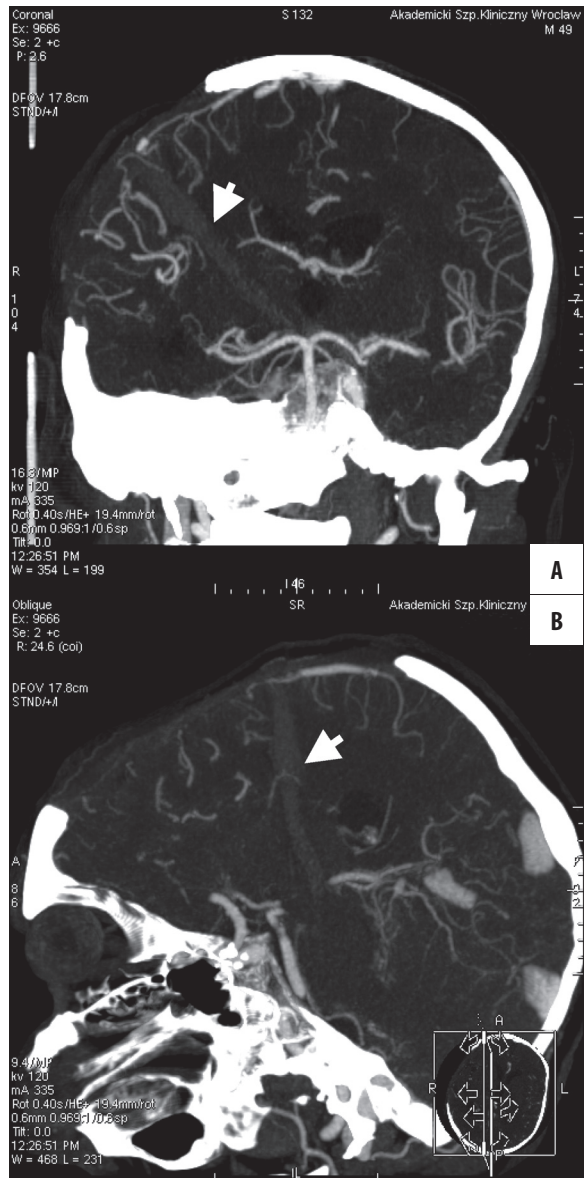


**Figure 1.** Status post an extensive right-sided craniectomy, VR reconstruction.



**Figure 2.** CT examination without contrast administration: haemorrhagic focus on the right side.

sharp instrument (Figure 3A,B). In order to verify this assumption, a close forensic examination of the scalp was conducted in the admission room. The examination revealed a linear incision of approx. 15 mm. Its distance from the margin of the craniectomy hole overlapped with location of the peripheral part of the aforementioned hyperdense structure relative to the hole. This confirmed the connection between the skin incision and the site of intracerebral bleeding. Due to these facts, there arose a strong suspicion that the brain injury was not accidental. As a result, a knife found at the site of the incident, next to the patient, which had not been connected with the patient's state so far, was secured as a potential crime instrument. The size of its blade corresponded strictly to the streak of hyperdense blood. The above presented radiological and clinical data were reported to the police.



**Figure 3.** CTA: a hyperdense streak of blood, stretching from the subcutaneous layers to the III ventricle (arrows). Frontal plane (A) and sagittal plane (B), MIP reconstruction.

### Discussion

Revealing the crime instrument, and thus establishing the cause of the patient's severe condition, was possible thanks to the application of a 64-slice computed tomography as a diagnostic technique. With this examination, it is possible to collect data from the whole studied structure (e.g. head) with a close resolution (of less than 1 mm), in all three dimensions, within 10–20 seconds. Depending on what is needed, the image of an examined anatomical structure may be subjected to analysis with different graphic applications, which may lead to acquisition of high-quality secondary reconstructions in a any of the planes. This was the sensitivity, isotropic resolution and reconstructive options of the 64-slice CT scanner that helped us to obtain those extraordinary data.

Although in the presented case, the examination was performed before the cause of the patient's state was revealed, generally, CT examinations constitute a basic imaging method applied in the diagnostics of penetrating craniocerebral injuries [1,2]. CT allows for evaluation of the extension of brain injuries, detection of potential foreign bodies remaining in the wound, or diagnosis of further complications, as well as lesions requiring an immediate neurosurgical intervention. Very often, penetrating traumas of the head cause injuries of blood vessels and lead to formation of posttraumatic vascular lesions. This is why CT examinations require extension with CT angiography [2]. The advantage of the CTA is its minimal invasiveness and possibility of its conduction immediately after a standard CT examination, without any special preparation of the patient. This is important when the patient suffered a penetrating head injury, i.e. is in a severe clinical condition, most of the time.

In Poland, penetrating craniocerebral traumas are relatively rare, mainly because of a low popularity of firearms. At the same time, the rate of penetrating injuries inflicted with a low kinetic energy (e.g. stab wounds from a knife) is higher than in the literature of Western Europe origin [3]. It is quite common that penetrating injuries result from criminal or suicidal acts and radiological findings are useful in forensic investigations and criminal proceedings. Forensic medicine is a field in which different imaging examinations are frequently used [4]. This concerns also the process of identification of the crime instrument on the basis of the

connection between the wounded area found on CT and the size of a blade [5], as in the case presented above.

Most of the penetrating craniocerebral traumas caused with the use of a low kinetic energy are knife wounds, although the list of objects that could possibly lead to such injuries is long: nails, screwdrivers, needles, scissors, keys, fan blade, etc. [6]. The temporal squama and the roof of the orbit constitute two regions where penetration is easier, as the osseous tissue is thinner within these structures. Nevertheless, penetrating injuries occur in other parts of the skull with the same frequency [5]. The reported case seems extraordinary when compared to other cases, presented by authors [6–10]. This is because the brain tissue suffered a direct injury, which was only possible due to a concomitant extensive defect of the skull, following craniectomy. Vague circumstances of the injury, as well as no external bleeding, and the presence of an unusual CT image make this case an interesting diversity in everyday work of a radiologist.

## Conclusions

With a constant development of the multislice CT technique, the number of its applications increases. Identification of crime instruments with a CT is a domain of forensic medicine. However, as the above presented case showed, this may also happen during a routine hospital duty of a radiologist.

## References:

1. Offiah C, Twigg S: Imaging assessment of penetrating craniocerebral and spinal trauma. *Clin Radiol*, 2009; 64(12): 1146–57
2. Pruitt BA Jr: Management and prognosis of penetrating brain injury: Neuroimaging in the Management of Penetrating Brain Injury. *J Trauma*, 2001; 51: S7–11
3. Czyżewski P, Blok T, Błaszczak M et al: Urazy penetrujące – rzadkie przypadki obrażeń głowy i mózgu. *Neuroskop*, 2006; 8: 53–60
4. Urbanik A, Chrzan R, Woźniak K et al: Post-mortem CT examination – own experiences. *Pol J Radiol*, 2009; 74(4): 55–63
5. Bauer M, Patzelt D: Intracranial stab injuries: case report and a case study. *Forensic Science International*, 2002; 129: 122–27
6. Iwakura M, Kawaguchi T, Hosoda K et al: Knife Blade Penetrating Stab Wound to the Brain. Case Report. *Neurol Med Chir*, 2005; 45: 172–75
7. Kennedy UM, Geary UM, Sheehy N: Intracranial stab wound: a case report. *Eur J Emerg Med*, 2007; 14: 72–74
8. Chui M, de Tilly LN, Moulton R et al: Suicidal stab wound with a butter knife. *CMAJ*, 2002; 167: 899
9. Satyarthee GD, Borkar SA, Tripathi AK et al: Transorbital penetrating cerebral injury with a ceramic stone: Report of interesting case. *Neurol India*, 2009; 57: 331–33
10. De Jongh K, Dohmen D, Salgado R et al: "William Tell" Injury: MDCT of an Arrow Through the Head. *AJR*, 2004; 182: 1551–53