



## Case report

## Refractile foreign material deposits and alveolar hemorrhage in crack cocaine smoker



Robert Sogomonian<sup>a,\*</sup>, Hassan Alkhawam<sup>a</sup>, Viral Gandhi<sup>c</sup>, Feras Zaiem<sup>b</sup>,  
Emma A. Moradoghli Haftevani<sup>d</sup>, Terence McGarry<sup>e</sup>

<sup>a</sup> Department of Medicine, Icahn School of Medicine at Mount Sinai, Elmhurst, NY, USA

<sup>b</sup> Mayo Evidence Based Practice Center-Mayo Clinic, Rochester, MN, USA

<sup>c</sup> Division of Pulmonary and Critical care Medicine, Allegheny General Hospital, USA

<sup>d</sup> Ross University School of Medicine, USA

<sup>e</sup> Department of Pulmonary/Critical Care, Icahn School of Medicine at Mount Sinai, Elmhurst, NY, USA

## ARTICLE INFO

## Article history:

Received 24 June 2015

Accepted 7 July 2015

## Keywords:

Cocaine

Alveolar hemorrhage

## ABSTRACT

Recreational use of alkaloid free-base cocaine, also known as crack cocaine, has reached epidemic proportions in the United States. Inhalation of crack cocaine is known to cause a variety of pulmonary complications. Herein we present a case of diffuse alveolar hemorrhage (DAH) and particulate foreign matter deposition in the setting of crack cocaine inhalation.

© 2015 The Authors. Published by Elsevier Ltd. This is an open access article under the CC BY-NC-ND license (<http://creativecommons.org/licenses/by-nc-nd/4.0/>).

## 1. Introduction

Recreational use of alkaloid free-base cocaine, also known as crack cocaine, has reached epidemic proportions in the United States. Inhalation of crack cocaine is known to cause a variety of pulmonary complications. In this particular case, we were able to expose alveolar depositions with foreign material on pathological images after cocaine smoke inhalation. We present a case of diffuse alveolar hemorrhage (DAH) and particulate foreign matter deposition in the setting of crack cocaine inhalation.

## 2. Case report

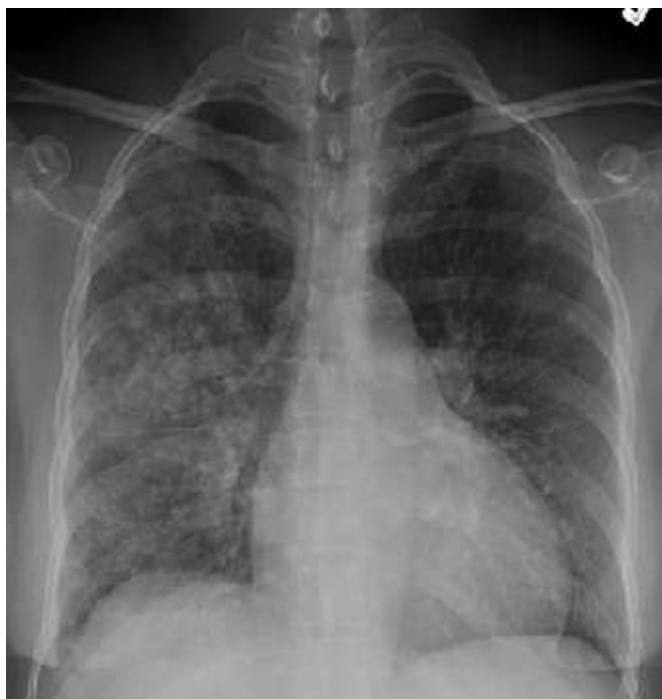A 50 year-old African-American female prisoner with history of Human Immunodeficiency Virus infection, diabetes mellitus and asthma was brought into the Emergency Department with acute onset of shortness of breath, subjective fever and cough productive of blood-streaked sputum. She reported tobacco

smoking as well as cocaine and marijuana use, including binge crack inhalation 2 days prior. She was febrile; other vital signs were unremarkable. Lung auscultation and cardiac exam was normal. Laboratory results were significant for a hemoglobin level of 8.4 g/dL, normal serum creatinine level, and a CD4+ count of 592 cells/ $\mu$ L. Serum lactate dehydrogenase level was 252 U/L (normal range 90–225). Urinalysis was normal. Chest radiography showed diffuse interstitial and alveolar infiltrate involving the entire right lung with right upper lobe predominance (Fig. 1). Empiric antibiotics were started for community-acquired pneumonia. Chest computed tomography showed an extensive right upper lobe quasi-nodular ground-glass infiltrate and a similar but less severe process in the right lower lobe (Fig. 2). Microbiologic evaluation, including routine cultures, legionella and histoplasma urine antigens, as well as sputum mycobacterial smears, was ultimately negative. Bronchoscopy showed diffuse edema of the airways without active hemorrhage. Bronchoalveolar lavage (BAL) fluid samples were non-hemorrhagic. Transbronchial biopsy demonstrated alveolar hemorrhage with refractile foreign material deposits (Fig. 3). There was no evidence of pneumocystis.

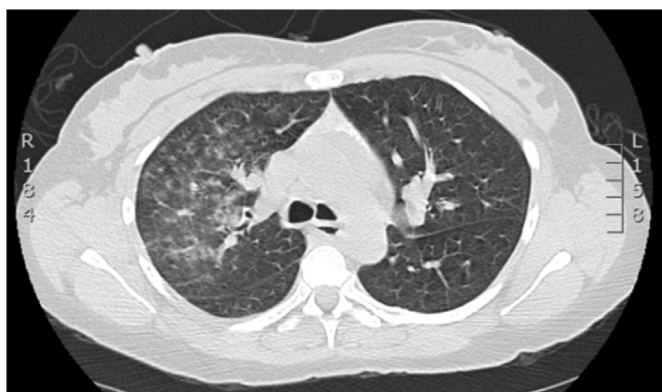Our patient received symptomatic treatment with albuterol, acetaminophen, and codeine. Antibiotics were stopped after biopsy results were obtained. Lack of further exposure to cocaine while in

\* Corresponding author. Department of Medicine, Icahn School of Medicine at Mount Sinai (Elmhurst), 97-01 Broadway, Elmhurst, NY 11373, USA.

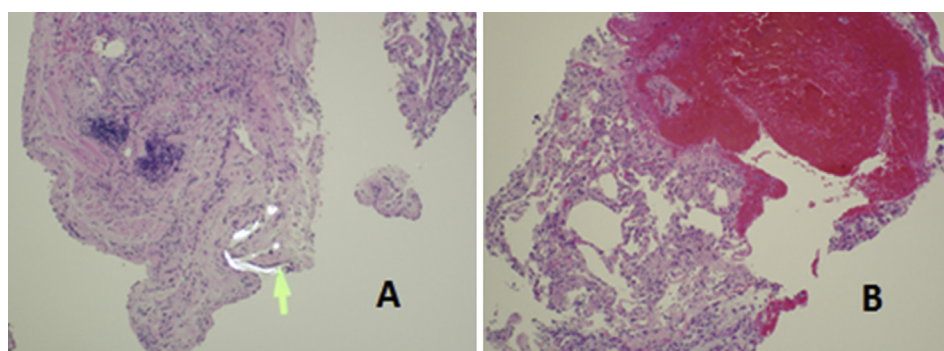
E-mail address: [Robert.Sogomonian@mssm.edu](mailto:Robert.Sogomonian@mssm.edu) (R. Sogomonian).



**Fig. 1.** Chest radiology shows right upper lobe predominant interstitial alveolar pattern.



**Fig. 2.** Chest computed tomography impressive for right upper lobe ground-glass and nodular infiltrates.



**Fig. 3.** A: Refractile foreign body deposition (arrow) visualized under high powered polarized microscopy, with fibrotic tissue changes. B: Prominent alveolar hemorrhage with emphysematous changes and widened interalveolar septi.

hospital facilitated the resolution of her DAH. She was successfully discharged to the jail's infirmary.

### 3. Discussion

Diffuse alveolar hemorrhage (DAH) is a life-threatening disease which refers to hemorrhage originating from pulmonary microvasculature, rather than from parenchymal abnormalities or bronchial circulation. Many causes could lead eventually to DAH such as; systemic vasculitis-ex. Wegener Granulomatosis and Goodpasture Syndrome-, Systemic Lupus Erythematosus (SLE), mitral stenosis and toxic exposure. Cocaine is the most common toxic cause of acute diffuse pulmonary hemorrhage [1].

Pure cocaine was first isolated in the 1880s and nowadays cocaine accounts for more reports to the Drug Abuse Warning Network (DAWN) than marijuana or hashish [2]. According to the United Nation Office on Drugs and Crime, 0.3–0.4% of the global population aged 15–64 years reported having used cocaine at least once in 2012. The prevalence of users in Americas is 1.2%. While the cardiovascular complications of cocaine use are well-known, the pulmonary effects and complications such as DAH may not be that familiar.

Diffuse alveolar hemorrhage (DAH) clinical syndrome consists of cough, dyspnea, hemoptysis and low hematocrit. However, 33% of patients will not have hemoptysis, despite the active alveolar bleeding [3]. Fever and some systemic complaints may be present, depending on the etiology of the DAH. The physical exam may be quite nonspecific. However, most patients will have crackles on lung auscultation.

Chest x-ray will reveal patchy alveolar infiltrates which may start in a focal pattern and become more diffuse with time. Pulmonary hemorrhage manifestate on high resolution CT scan as a ground-glass opacities that may be associated with interlobular septal thickening. However, the diagnosis is established when bronchealveolar lavage (BAL) from the same location are progressively hemorrhagic. Transbronchial biopsies were historically suggested; however, the tissue samples are very small and most of the time the patient is too ill to undergo biopsies.

DAH should be considered a medical emergency due to the significant morbidity and mortality associated with delayed treatment. If not managed and treated well, it could lead to respiratory failure and diffuse pulmonary infiltrates [4]. Management includes maintenance of oxygenation, ventilation, and symptomatic care. Patients with airway compromise may require endotracheal intubation. Systemic glucocorticoids may be used based upon the potentially life-threatening nature of DAH, the response to glucocorticoids described in our case report, with evidence of an

inflammatory component in the few patients who underwent lung biopsy [5].

## References

- [1] M.E. Bailey, A.E. Fraire, S.D. Greenberg, J. Barnard, P.T. Cagle, Pulmonary histopathology in cocaine abusers, *Hum. Pathol.* 25 (1994) 203–207.
- [2] Drug Abuse Warning Network (DAWN). [www.samhsa.gov](http://www.samhsa.gov).
- [3] M.R. Zamora, M.L. Warner, R. Tuder, M.I. Schwarz, Diffuse alveolar hemorrhage and systemic lupus erythematosus. Clinical presentation, histology, survival, and outcome, *Med. Baltim.* 76 (1997) 192–202.
- [4] H.R. Collard, M.I. Schwarz, Diffuse alveolar hemorrhage, *Clin. Chest Med.* 25 (2004) 583–592.
- [5] S.B. Iskandar, B. Abi-Saleh, R.L. Keith, R.P. Byrd Jr., T.M. Roy, Amiodarone-induced alveolar hemorrhage, *South Med. J.* 99 (2006) 383–387.